

Lak
C11
II
II
1915

RC
71.5
C11
v.2

Library
OF THE
New York State Veterinary College

Cornell University Library
RC 71.5.C11
v.2
Differential diagnosis ...
3 1924 000 317 721
vet

The original of this book is in
the Cornell University Library.

There are no known copyright restrictions in
the United States on the use of the text.

http://www.archive.org/details/cu31924000317721

DIFFERENTIAL DIAGNOSIS

VOLUME II

PRESENTED THROUGH
AN ANALYSIS OF 317 CASES

BY

RICHARD C. CABOT, M. D.

ASSISTANT PROFESSOR OF CLINICAL MEDICINE, HARVARD UNIVERSITY MEDICAL SCHOOL, BOSTON
CHIEF OF THE WEST MEDICAL SERVICE

AT THE



MASSACHUSETTS GENERAL HOSPITAL

PROFUSELY ILLUSTRATED

PHILADELPHIA AND LONDON
W. B. SAUNDERS COMPANY
1915

NY.2 UC Lib.

NY8348

Copyright, 1914, by W. B. Saunders Company

RC
71.5
C11
V.2

PRINTED IN AMERICA

PRESS OF
W. B. SAUNDERS COMPANY
PHILADELPHIA

PREFACE

THE first volume of this work dealt with the symptom *pain*, and with eleven other common symptoms. In the present volume the same plan has been carried further. Nineteen other symptoms have been selected, analyzed, and illustrated. I have profited much from the study of the *Index of Differential Diagnosis*, by Herbert French and other writers, an admirable book published in 1912, since my first volume appeared. To the writers of that book I gratefully acknowledge my indebtedness.

As in the previous volume, I have received very substantial help from Dr. James H. Young, and from my secretaries, Miss Alice O'Gorman, Miss Mary F. Foote, and Miss Florence Painter.

R. C. C.

1 MARLBOROUGH ST., BOSTON, MASS.

December, 1914.

TABLE OF CONTENTS

CHAPTER I

ABDOMINAL AND OTHER TUMORS

		Page
General Considerations		17
Case No.		
1.	Pregnancy	27
2.	Echinococcus Cyst of Liver	28
3.	Adenocystoma of Ovary; Thrombosis of Vena Cava Inferior	29
4.	Myeloid Leukemia	31
5.	Nephroptosis; Congenitally Deformed Kidney; Corset Lobe of Liver	34
6.	(*a*) Hypernephroma (?); (*b*) Cervical Rib	37
7.	Osteitis Deformans	39
8.	Pelvic Cancer, probably Ovarian	41
9.	Malignant Lymphoma (Lymphoblastoma—Mallory)	45
10.	Hydronephrosis	49
11.	Glanders	52
12.	Phantom Tumor	65
13.	Malignant Lymphoma of the Retroperitoneal Glands (Lymphoblastoma—Mallory)	68
14.	Axillary Abscess	69
15.	Lymphoid Leukemia	70
16.	Lymphoid Leukemia; Abdominal Masses and Ascites	72
17.	Cancer of the Tail of the Pancreas with Extension to the Spleen, Liver, and Glands	74
18.	Multiple Lipomata	76
19.	Extra-uterine Pregnancy	77
20.	Gumma of Thigh	79
21.	Tuberculous Peritonitis	80
22.	Cancer of the Cecum	85
23.	Syphilis	86
24.	Malignant Lymphoma (Hodgkin's Disease, Mallory's Lymphoblastoma)	88
25.	Aortic Aneurysm	92
26.	Syphilis	93
27.	Syphilitic Gumma of the Sternum	95
28.	Gumma of the Frontal Bone	97
29.	Gastric Cancer	99
30.	Gastric Cancer with Metastasis in a Supraclavicular Lymph Node	101
31.	Syphilis	104
32.	Syphilitic Periostitis of Cranial Bones	106
33.	Chronic Family Jaundice (Hemolytic Jaundice)	110
34.	Cancer of the Cecum and Appendix	115
35.	Walled-off Abscess about Gall-bladder	116
36.	Kidney Stone; Pyonephrosis	119

Case No. Page
37. Phantom Tumor ... 121
38. Melanotic Sarcoma of Liver ... 123
39. Hypernephroma ... 126
40. Lymphoblastoma ... 127
41. Echinococcus of Liver ... 131

CHAPTER II

VERTIGO

General Considerations ... 134
Physiologic Vertigo ... 134
Pathologic Vertigo ... 136
Is There a Gastric Form of Vertigo? ... 139

Case No.
42. Chronic Nephritis in an Excessive Smoker ... 139
43. Aneurysm of the Thoracic Aorta ... 140
44. Chronic Interstitial Nephritis (Arteriosclerotic Type); Uremia ... 142
45. Endothelioma of the Dura in the Posterior Fossa of the Skull ... 144
46. Typhoid Fever ... 146
47. Labyrinthine Disease ... 147
48. Addison's Disease ... 147
49. Heat Stroke ... 150
50. Alcoholism; Cirrhosis (?); Syphilis (?) ... 151
51. Chronic Glomerular Nephritis ... 152
52. Hysteria in a Syphilitic ... 153
53. Cerebellar Cyst; Arteriosclerosis ... 154
54. Cerebral Syphilis ... 155
55. Cerebral Syphilis ... 156
56. Miliary Tuberculosis with Tuberculous Meningitis ... 159
57. Myocardial Weakness; Arhythmia ... 160
58. Arteriosclerosis ... 162
59. Addison's Disease ... 163
60. Arteriosclerosis ... 165
61. Cerebellar Tumor ... 167
62. Miliary Tuberculosis ... 168
63. Ménière's Disease ... 170
64. Syphilis ... 172
65. Otosclerosis; Labyrinthitis ... 173

CHAPTER III

DIARRHEA

General Considerations ... 175
Causes and Types of Diarrhea in Adult Life ... 175
Difficulty of Distinguishing Acute from Chronic Enteritis and Colitis ... 176
Causes of Diarrhea ... 178
Types and Diagnosis ... 183

Case No.
66. Pericecal Tuberculosis ... 185
67. Tuberculous Enteritis ... 187
68. Fat Intolerance; Abdominal Tumor (Lymphoblastoma?) ... 189
69. Neurasthenia ... 193
70. Cancer of the Bladder ... 194

CASE NO. PAGE
71. Appendix Abscess ... 197
72. Tuberculous Peritonitis and Enteritis ... 198
73. Infectious Colitis; Otitis Media ... 200
74. Cancer of the Sigmoid ... 201
75. General Infection due to Bacillus Coli; Typhus Fever ... 202
76. Meddlesome Surgery ... 204
77. Food Diarrhea ... 206
78. Tuberculous Peritonitis ... 208
79. Chronic Colitis; Starvation ... 211
80. Colitis of Unknown Cause ... 214
81. Chronic Diarrhea from Bad Habits ... 215
82. Chronic Colitis (Tuberculous?) ... 216
83. Chronic Glomerular Nephritis and Acute Endocarditis ... 220
84. Amebic Dysentery ... 223
85. Bilharziasis ... 225
86. Plumbism; Tabes; Morphinism ... 227
87. Pernicious Anæmia ... 230
88. Pernicious Anemia ... 233
89. "Leather-bottle Stomach" (Diffuse Carcinoma) with Cancerous Peritonitis 235
90. Stricture of Rectum (Syphilitic?) ... 237
91. Typhoid Fever ... 238
92. Constipation with Mucous Colitis ... 240
93. Trichiniasis ... 241
94. Ulcerative Colitis ... 243
95. Amebic Dysentery ... 244
96. Diarrhea of Unknown Cause ... 245
97. Typhoid Fever ... 246
98. Ulcerative Colitis ... 248

CHAPTER IV

DYSPEPSIA

GENERAL CONSIDERATIONS ... 250
WHAT IS SIMPLE INDIGESTION? ... 257
CASE NO.
99. Duodenal Ulcer with Contracted Scar ... 258
100. Chronic Glomerular Nephritis ... 261
101. Cancer of the Stomach ... 265
102. Chronic Glomerular Nephritis ... 268
103. Hysteria (Insanity?) ... 270
104. Cancer of the Gall-bladder ... 272
105. Gall-stones ... 273
106. Brain Tumor ... 275
107. Bad Dietetic Habits; Constipation ... 277
108. Chronic Glomerular Nephritis ... 278
109. Hydronephrosis ... 279
110. Cancer of Vater's Papilla ... 281
111. Pregnancy ... 283
112. Chronic Plumbism (?) ... 285
113. Kidney Stones; Left Pyonephrosis ... 287
114. Bad Dietetic Habits ... 288
115. Cancer of the Bile-ducts ... 290
116. Acute Gastric Indigestion ... 292

Case No. Page
117. Meddlesome Surgery; Mysterious Fever ... 294
118. Alcoholism ... 301
119. Social Maladjustment; Arteriosclerosis ... 302
120. Amyloid Nephritis; Ulcerative Enterocolitis; Purulent Bronchitis ... 304
121. Phthisis ... 306
122. Cirrhosis of the Liver; Syphilis (?) ... 308
123. Chlorosis; Social Maladjustment ... 310
124. Peptic Ulcer ... 312
125. Gastric Crisis in Tabes Dorsalis ... 314
126. Gall-stones in the Cystic Duct; Arteriosclerosis ... 316
127. Alcoholism; Chronic Peritonitis ... 318
128. Tabes Dorsalis ... 321
129. Psychoneurosis ... 323
130. Phthisis ... 325
131. Acute Indigestion (from overeating) ... 327
132. Cancer of the Stomach ... 328
133. Phthisis ... 330
134. Pernicious Anemia ... 333
135. Myeloid Leukemia ... 334
136. Cancer of the Cardiac End of Stomach ... 336
137. Addison's Disease ... 338
138. Gastric Cancer; Ovarian Fibroma ... 341
139. Nervous Dyspepsia; Starvation ... 344
140. Adhesions about Gall-bladder and Colon; Fibroid of Uterus ... 346
141. Gastric Crises of Tabes Dorsalis ... 348

CHAPTER V

HEMATEMESIS

General Considerations ... 350
Case No.
142. Peptic Ulcer; Mitral Stenosis ... 350
143. Cancer of Stomach; Ovarian Fibromata ... 353
144. Cirrhotic Liver; Internal Hydrocephalus; Hemophilia ... 357
145. Cirrhosis of the Liver ... 360
146. Menstrual Vomiting ... 361
147. Tabes Dorsalis; Gastric Crisis ... 361
148. Peptic Ulcer ... 364
149. Splenic Anemia ... 365

CHAPTER VI

GLANDS

General Considerations ... 369
Enlarged Glands and What Simulates Them ... 369
Clinical Groupings ... 373
Nomenclature of Glandular Tumors ... 374
What Other Lumps May Be Mistaken for Glands? ... 374
Gland Puncture ... 374
Case No.
150. Branchial Cyst ... 375
151. Lymphoblastoma (Hodgkin's Disease) ... 376
152. Cancer of the Thyroid ... 379

Case No. Page
153. Lymphoblastoma ... 380
154. Lymphoid Leukemia ... 381
155. Lymphoid Leukemia ... 384
156. Syphilitic Aortitis ... 386
157. Septic Adenitis ... 388
158. Neuroblastoma of the Neck, etc ... 389
159. Tabes Dorsalis; Thyroid Enlargement ... 391
160. Lymphoblastoma ... 393
161. Multiple Myeloma ... 394
162. Acute Lymphoid Leukemia ... 396
163. Tuberculous Adenitis and Tonsillitis ... 399
164. Tuberculous Adenitis ... 401
165. Malignant Lymphoma (Lymphoblastoma) ... 402

CHAPTER VII

BLOOD IN THE STOOLS (MELENA)

General Considerations ... 406
Case No.
166. Cancer of the Rectum ... 408
167. Typhoid Fever ... 410
168. Ulcerative Colitis ... 411
169. Cancer of Stomach with Diffuse Infiltration and Contraction ... 413
170. Bilharziasis ... 414
171. Amebic Dysentery ... 415

CHAPTER VIII

SWELLING OF THE FACE

General Considerations ... 417
Case No.
172. Tertian Malaria ... 419
173. Actinomycosis of the Jaw ... 420
174. Mumps ... 421
175. Trichiniasis ... 422
176. Trichiniasis ... 424
177. Empyema of the Antrum ... 424
178. Erysipelas ... 425
179. Edema with Erythema; Vasomotor Ataxia ... 426
180. Acute Nephritis ... 427
181. Syphilitic Laryngitis with Stenosis: Deep Cervical Cellulitis (Ludwig's Angina) ... 428
182. Chronic Glomerular Nephritis ... 430

CHAPTER IX

HEMOPTYSIS

General Considerations ... 432
Case No.
183. Mitral Stenosis; Phthisis ... 434
184. Phthisis ... 438
185. Lobar Pneumonia ... 440
186. Phthisis ... 443

Case No. Page
187. Congenital Heart Disease ... 445
188. Abscess of the Lung; Septicemia ... 447
189. Phthisis (?) ... 451
190. Abscess of the Lung ... 452
191. Hysteria (?) ... 455
192. Incipient Phthisis ... 460
193. Arteriosclerotic Nephritis; Pulmonary Apoplexy ... 462
194. Arteriosclerosis; Glomerular Nephritis ... 463

CHAPTER X

EDEMA OF THE LEGS

General Considerations ... 465
Local Causes of Edema ... 465
Varieties and Sites of Edema ... 466
Edema in Convalescence ... 466
Case No.
195. Cirrhosis of the Liver (Syphilis?) ... 466
196. Phlebitis; Arteriosclerosis ... 469
197. Flat-foot ... 470
198. Pernicious Anemia ... 471
199. Trichiniasis ... 473
200. Endocarditis ... 475
201. Phlebitis; Pulmonary Infarct ... 477
202. Chronic Glomerular Nephritis ... 479
203. Syphilis; Myocardial Insufficiency; Tabes; Paralysis of the Vocal Cords ... 481
204. Erythema Multiforme ... 481
205. Alcoholic Neuritis with Edema ... 482
206. Acute Nephritis; Cervical Adenitis ... 483
207. Alcoholic Neuritis; Myocardial Weakness ... 484
208. Cirrhosis of Liver; Arteriosclerosis; Subacute Glomerular Nephritis ... 485
209. Arteriosclerosis; Weak Heart ... 487
210. Elephantiasis ... 488
211. Phthisis; General Miliary Tuberculosis; Tuberculous Peritonitis ... 491
212. Acute Glomerular Nephritis ... 493

CHAPTER XI

FREQUENT MICTURITION AND POLYURIA

General Considerations ... 495
Case No.
213. Diverticulitis Perforating the Bladder; Syphilis ... 496
214. Cystitis; Streptococcus Infection ... 499
215. Anemia; Debility ... 501
216. Pyelonephritis ... 502
217. Vesical Calculus ... 504
218. Neurasthenia ... 505
219. Pyelonephritis ... 506
220. Tuberculous Peritonitis ... 509
221. Tuberculosis of the Kidney and Bladder ... 510
222. Tuberculosis of the Kidney and Bladder ... 512
223. Chronic Glomerular Nephritis; Arteriosclerosis; Myomalacia Cordis ... 515

CASE NO. PAGE
224. Albuminuria and Glycosuria, Cause Unknown ... 518
225. Malignant Disease of the Ovary ... 519
226. Chronic Nephritis (Syphilitic?) ... 521
227. Colon Bacillus Infection of the Urinary Tract ... 522
228. Cystitis (Tuberculous?) ... 524
229. Bilateral Pyonephrosis; Secondary Anemia ... 525
230. Gonorrheal Pyelitis; Prostatitis; Arthritis ... 528
231. Cancer of the Bladder ... 529
232. Obstructing Prostate; Arteriosclerosis ... 530
233. Chronic Interstitial Nephritis ... 532
234. Diabetes Insipidus; Congenital Syphilis ... 533
235. Diabetes Mellitus ... 535
236. Diabetes Mellitus; Hemorrhoids; Secondary Anemia ... 536

CHAPTER XII

FAINTING

GENERAL CONSIDERATIONS ... 541
CASE NO.
237. Chronic Lead-poisoning ... 542
238. Hemorrhage from Duodenal Ulcer ... 545
239. Chronic Glomerular Nephritis ... 546
240. Arteriosclerotic Nephritis ... 548
241. Arteriosclerosis; Cerebral Hemorrhage ... 550
242. Arteriosclerosis; Stokes-Adams Disease ... 552
243. Pernicious Anemia ... 553
244. Hysteria ... 555
245. Hysteria ... 557

CHAPTER XIII

HOARSENESS

GENERAL CONSIDERATIONS ... 559
CASE NO.
246. Acute Laryngitis; Syphilis (?) ... 560
247. Hysterical Aphonia ... 562
248. Thoracic Aneurysm ... 563
249. Papilloma of the Larynx ... 566
250. Mediastinal Neoplasm (?) ... 567
251. Recurrent Laryngeal Paralysis; Aneurysm (?) ... 570
252. Aneurysm ... 571
253. Syphilis of the Larynx ... 573

CHAPTER XIV

PALLOR

GENERAL CONSIDERATIONS ... 575
CASE NO.
254. Gastric Cancer ... 575
255. Acute Lymphoid Leukemia ... 578
256. Chlorosis ... 580

Case No. Page
257. Pernicious Anemia ... 581
258. Subdiaphragmatic Abscess (Secondary Anemia) ... 582
259. Pernicious Anemia; Arsenic-poisoning; Arteriosclerotic Nephritis ... 585
260. Chronic Glomerular Nephritis (Streptococcus Origin?) ... 588
261. Gastric Ulcer ... 590
262. Acute Glomerular Nephritis; Syphilitic Aortitis ... 592
263. Bothriocephalus Latus ... 594

CHAPTER XV

SWELLING OF THE ARM

General Considerations ... 597
Case No.
264. Phlebitis ... 597
265. Osteomyelitis of the Humerus ... 599
266. Phlebitis, Cause Unknown ... 600
267. Dilated Aortic Arch; Phlebitis; Edema Due to Pressure ... 601
268. Tuberculous Pericarditis with Effusion ... 603
269. Adherent Pericardium; Mitral Stenosis ... 608
270. Pellagra ... 610

CHAPTER XVI

DELIRIUM

General Considerations ... 612
Case No.
271. Typhoid Fever ... 613
272. Postfebrile Psychosis ... 615
273. Arteriosclerosis ... 616
274. Postfebrile Psychosis ... 617
275. Exhaustion Psychosis ... 619
276. Tertian Malaria ... 621

CHAPTER XVII

PALPITATION AND ARHYTHMIA

General Considerations ... 622
Etiology ... 624
Summary ... 624
Case No.
277. Myocardial Weakness; Hypertension ... 624
278. Neurosis ... 625
279. Paroxysmal Tachycardia ... 626
280. Dysthyroidism ... 628
281. Mitral Stenosis ... 629
282. Pernicious Anemia ... 630
283. Dysthyroidism ... 633
284. Cardiac Neurosis (Tobacco?) ... 634
285. Sinus Arhythmia (Cardiac Neurosis) ... 635
286. Dysthyroidism ... 636

CHAPTER XVIII

TREMOR

PAGE

GENERAL CONSIDERATIONS 639

CASE NO.

287. Alcoholism 640
288. Paralysis Agitans 642
289. Multiple Neuritis (?); Syphilis 643
290. Hysteria 645
291. Multiple Sclerosis 646

CHAPTER XIX

ASCITES AND ABDOMINAL ENLARGEMENT

GENERAL CONSIDERATIONS 649
CLINICAL STATISTICS OF ASCITES 654
ASCITES WITH SOLID TUMORS OF THE OVARY 655
ASCITES WITH CYSTIC TUMORS OF THE OVARY 655
ASCITES WITH UTERINE FIBROMYOMA 655

CASE NO.

292. Hepatic Syphilis 656
293. Papillary Cystadenoma of the Ovary 657
294. Syphilis; Syphilitic Liver (?) 658
295. Syphilitic Nephritis 661
296. Chronic Adhesive Pericarditis 663
297. Cirrhosis of the Liver 666
298. Cirrhosis of Liver (Syphilitic?) 671
299. Tuberculous Peritonitis and Salpingitis 674
300. Cirrhosis of the Liver; Thrombosed Portal Vein 676
301. Ovarian Fibroma 677
302. Tuberculous Peritonitis 678
303. Chronic Glomerular Nephritis 679
304. Cirrhosis of the Liver 680
305. Pericardial Adhesions 681
306. Ovarian Cyst 682
307. Syphilis 683
308. Neoplastic Peritonitis (Lymphoblastoma) 684
309. Chronic Appendicitis with Abscess; Pylephlebitis 685
310. Syphilitic (?) Cirrhosis 687
311. Tuberculous Peritonitis 689
312. Chronic Glomerular Nephritis; Arteriosclerosis; Myomalacia Cordis with Thrombi 690
313. Fibromyoma of the Uterus 695
314. Gaseous Distension 697
315. Ovarian Cyst 698
316. Cancer of the Liver 700
317. Obesity 703

INDEX 705

DIFFERENTIAL DIAGNOSIS

CHAPTER I

ABDOMINAL AND OTHER TUMORS

THE diagnosis of abdominal tumors is in most cases either easy or impossible; but it is never easy unless one has a considerable knowledge of what tumors are likely to occur in each of the regions of the abdomen, unless one has taken a careful history and made the ordinary manual exploration of the mass. In addition, laboratory examinations and *x*-ray exposures are sometimes of importance.

Of these methods, direct palpation of the tumor may be the most or the least important of all. Sometimes it tells us a good deal, but usually what it tells us is interpreted and enlarged very considerably by what we have learned to expect. For example, an epigastric tumor is almost always cancer of the stomach. Should such a tumor occur in a child, we should, of course, seek some other diagnosis; but, then, such a tumor very rarely does occur in a child.

Certain regions of the abdomen are much more prone to contain tumors than others; in other words, the diseases which produce tumor in the abdomen are chiefly those of the pelvis and pelvic organs, those of the stomach, liver, and kidneys. Tumors of the left hypochondrium are comparatively rare, and almost invariably turn out to be connected with the spleen or left kidney. In the right hypochondrium we have not only those connected with the liver and gall-bladder, but those connected with the hepatic flexure of the colon, with the pyloric end of the stomach, with the right kidney, as well as retroperitoneal and glandular masses which often push the liver forward and are hidden behind it. It should always be remembered that a doubtful tumor, seemingly springing from the liver, may, in fact, be a normal liver pushed downward and forward by some growth behind it. Some of the most humiliating mistakes that I have known have been due to forgetting this point.

If ascites is present, our diagnosis is much simplified, as there are comparatively few tumors often associated with ascites. Such

Abdominal Tumors

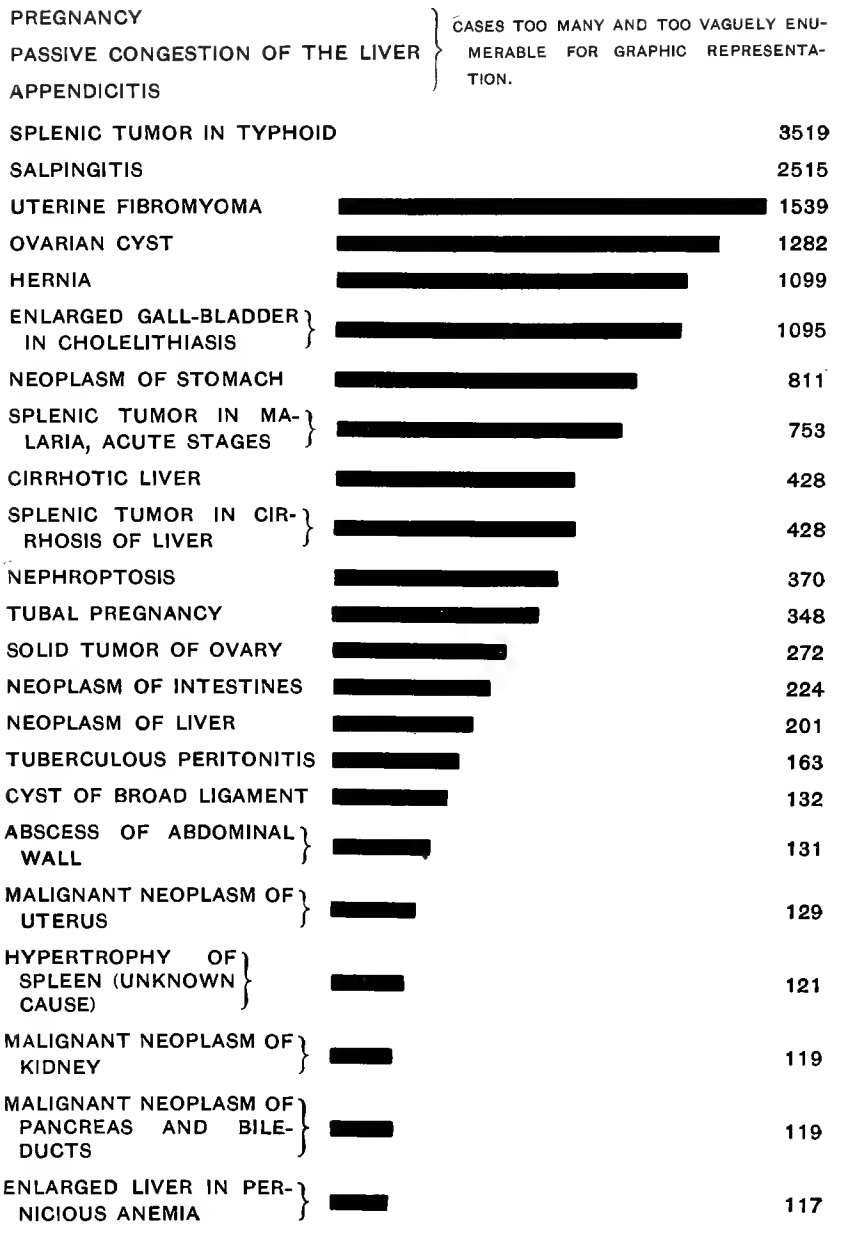
PREGNANCY
PASSIVE CONGESTION OF THE LIVER
APPENDICITIS
CASES TOO MANY AND TOO VAGUELY ENUMERABLE FOR GRAPHIC REPRESENTATION.
SPLENIC TUMOR IN TYPHOID 3519
SALPINGITIS 2515
UTERINE FIBROMYOMA 1539
OVARIAN CYST 1282
HERNIA 1099
ENLARGED GALL-BLADDER IN CHOLELITHIASIS 1095
NEOPLASM OF STOMACH 811
SPLENIC TUMOR IN MALARIA, ACUTE STAGES 753
CIRRHOTIC LIVER 428
SPLENIC TUMOR IN CIRRHOSIS OF LIVER 428
NEPHROPTOSIS 370
TUBAL PREGNANCY 348
SOLID TUMOR OF OVARY 272
NEOPLASM OF INTESTINES 224
NEOPLASM OF LIVER 201
TUBERCULOUS PERITONITIS 163
CYST OF BROAD LIGAMENT 132
ABSCESS OF ABDOMINAL WALL 131
MALIGNANT NEOPLASM OF UTERUS 129
HYPERTROPHY OF SPLEEN (UNKNOWN CAUSE) 121
MALIGNANT NEOPLASM OF KIDNEY 119
MALIGNANT NEOPLASM OF PANCREAS AND BILE-DUCTS 119
ENLARGED LIVER IN PERNICIOUS ANEMIA 117

Diagram I.

ABDOMINAL TUMORS—*Continued*


TUMOR OR HYPERTROPHY OF LIVER (UNKNOWN CAUSE) 113
ENLARGED GALL-BLADDER IN CHOLECYSTITIS 105
PYONEPHROSIS 103
TUBERCULOUS KIDNEY 101
NEOPLASM OF PERITONEUM 95
SPLENIC TUMOR IN PERNICIOUS ANEMIA 90
CARCINOMA OF GALL-BLADDER 88
SPLENIC TUMOR IN MYELOID LEUKEMIA 88
ENLARGED LIVER IN MYELOID LEUKEMIA 84
ENLARGED LIVER IN CHRONIC PERICARDITIS 82
HYDRONEPHROSIS 73
SPLENIC TUMOR IN HODGKIN'S DISEASE 70
RENAL CALCULUS (WITH HYDRONEPHROSIS) 67
ABSCESS OF LIVER 66
ENLARGED LIVER IN RICKETS 63
ENLARGED LIVER IN HODGKIN'S DISEASE 60
PARANEPHRITIC ABSCESS 59
ACUTE INTESTINAL OBSTRUCTION 57
ENLARGED LIVER IN LYMPHOID LEUKEMIA 51
MALIGNANT NEOPLASM OF ABDOMINAL WALL 49
HYPERTROPHY AND TUMOR OF OVARY (UNKNOWN CAUSE) 48
ENLARGED LIVER IN SUPPURATIVE PYLEPHLEBITIS 48
SPLENIC TUMOR IN LYMPHOID LEUKEMIA 45
INTUSSUSCEPTION 45

DIAGRAM I—*Continued.*

are cirrhosis of the liver, syphilis of the liver and spleen, tuberculous peritonitis with omental or glandular masses presenting as tumor, retroperitoneal cancerous metastases from neoplasm of the stomach, gall-bladder, or pelvic organs. Lastly, a small percentage of the cases of uterine fibroid and ovarian cyst are complicated by ascites. The list just given is not a very short one, but it has this characteristic, that a majority of its members can, as a rule, be easily excluded and thus a diagnosis of the cause of ascites arrived at.

The most important inquiries in relation to abdominal tumors are the following:

(1) Duration and present symptoms, including pain, soreness, and the various disturbances of function (gastric, intestinal, biliary, urinary).

(2) The location of the tumor, with especial reference to its connection with one or another abdominal organ.

(3) Its size, shape, and consistency.

(4) Its mobility and respiratory mobility.

(5) The determination of its relation to the stomach and colon: (*a*) through inflation of these organs, (*b*) through the observation or history of peristalsis and intestinal noise.

Aside from these five methods of examination we must study:

(*a*) The urine.

(*b*) The blood, especially in relation to the Wassermann reaction, the presence of anemia, leukemia, or leukocytosis. Rarely one must also search for the complement fixation in relation to hydatid disease or gonorrhea.

(*c*) The stomach contents.

(*d*) The urine.

(*e*) The *x*-ray findings after a bismuth meal, a bismuth enema, or the injection of a silver salt to the pelvis of the kidney.

(*f*) The temperature chart.

In the urine the most important points are the presence of blood or of pus. In the feces, the presence of blood, pus, or parasitic eggs.

A knowledge of the relative frequency of abdominal tumors is an essential part of their diagnosis. Some guides to such a knowledge may be obtained from the diagrams which follow. (See Diagrams I, II, III, IV, V, VI, VII.) Combining the knowledge thus obtained with a careful history of the case, and especially with the direct and indirect evidence touching the function of the different abdominal organs, we may arrive at a diagnosis in the majority of cases.

Causes of Tumors Involving the Abdominal Wall

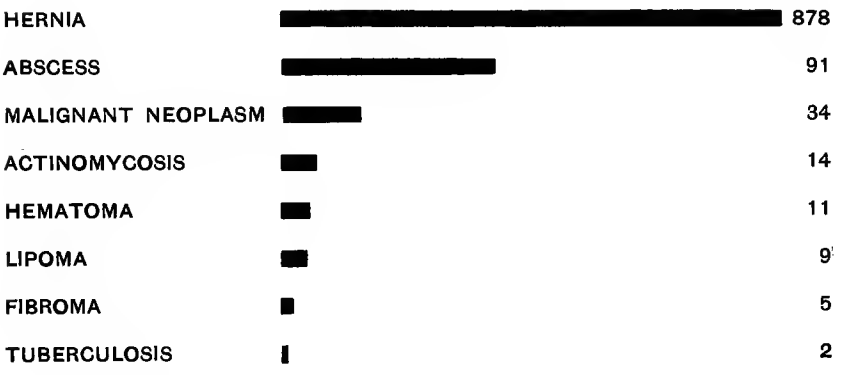

Diagram II.

Tumors of the Kidney



Diagram III.

Tumors of the Liver

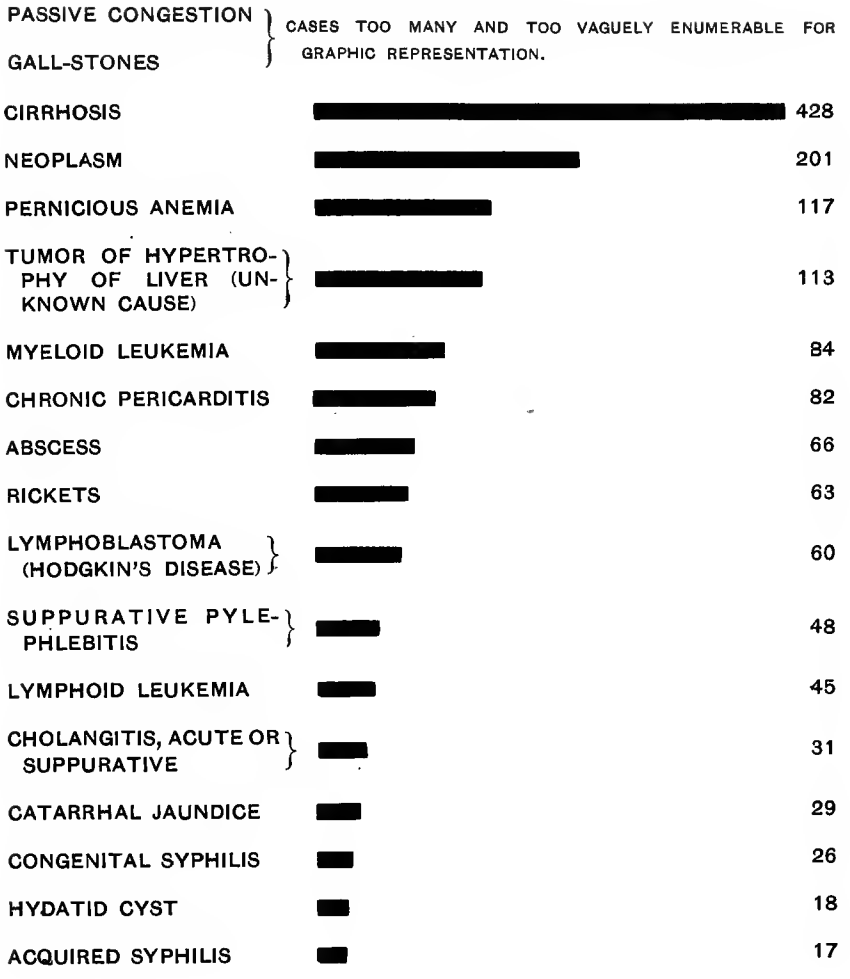

Diagram IV.

Tumors Involving the Uterus, Ovaries, or Tubes

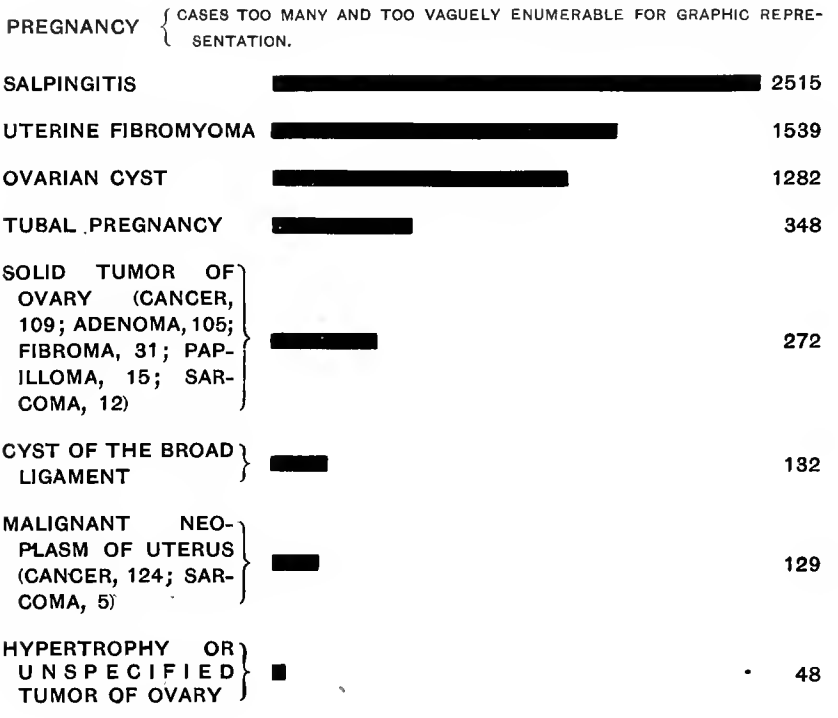

Diagram V.

Causes of Tumors Involving the Intestines and Peritoneum

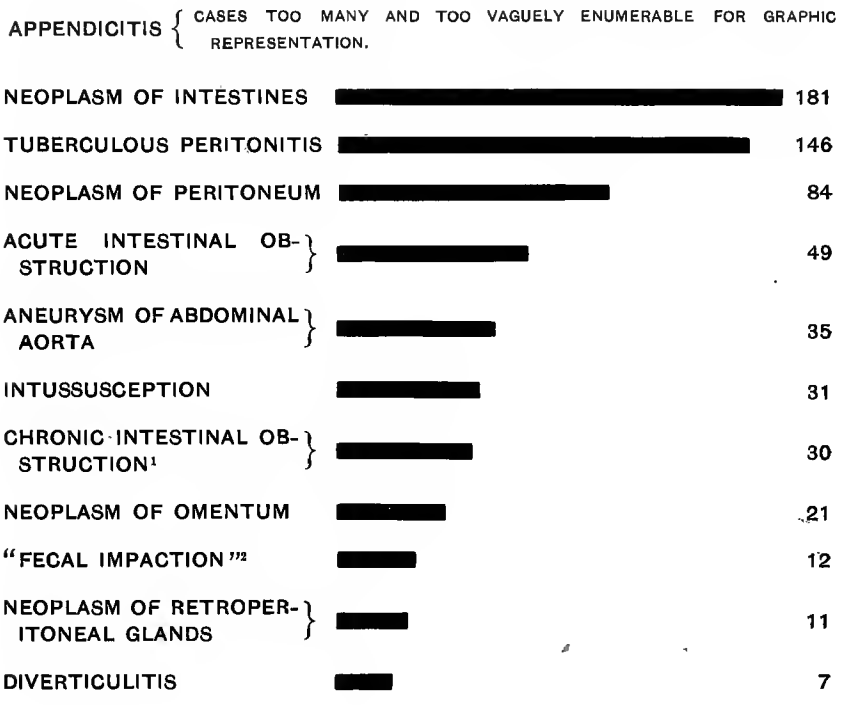

[1] Excluding cases known to be of neoplastic origin.

[2] Cause unknown; some organic cause (stricture, tumor) is almost invariably present.

Diagram VI.

Causes of Splenic Tumor

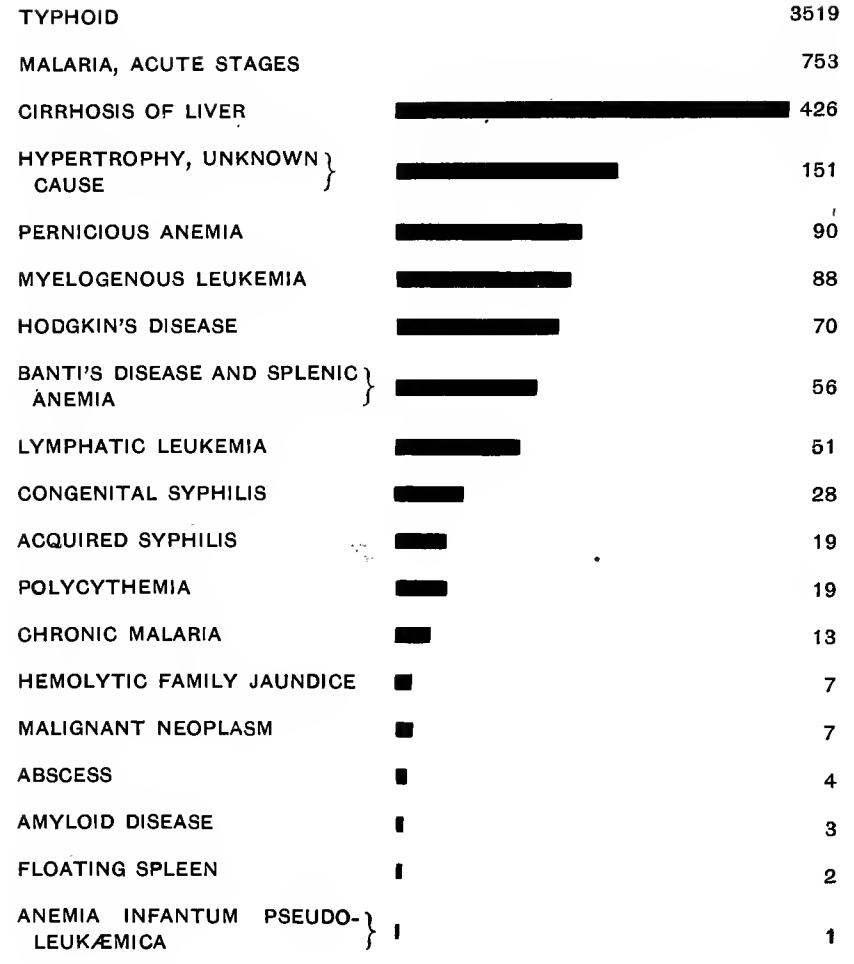

Diagram VII.

Yet, as I said at the outset, there are a number of cases which will utterly escape us despite the use of all the methods and precautions above suggested. I have seen, for instance, a tumor of the tail of the pancreas which could not by any possibility have been recognized during life. Such baffling tumors are, fortunately, not very common, but they will occur in the experience of every one who sees many patients. Among pelvic tumors diagnosis is frequently impossible, partly because several of the alternative possibilities may give precisely the same history, the same data on palpation, and the same laboratory findings; partly also because these supposed alternatives may all be present at once. One breaks one's heart to distinguish a fibroid tumor from a cystic ovary, or a salpingitis from an extra-uterine pregnancy, and then at operation finds both the diseases present at once. Such mistakes are not often very serious, for what we have chiefly to decide is whether an exploratory operation is necessary or not.

Case 1

A waitress of twenty-seven entered the hospital March 29, 1909. The patient has two children, the youngest four years old. She had a miscarriage two years ago, and was operated on at that time; she has never felt well since. She had typhoid in the Massachusetts General Hospital two years ago. Her menstruation comes every twenty-four days. The last period was three weeks ago.

Three days ago she fell, striking the right side. At 9 o'clock last night, without warning or pain, there was a gush of bright blood from the vagina. She went to bed and had continuous flowing for an hour or more, with slight staining since then.

Physical examination was negative, save for a tumor above the pubes, firm, smooth, rounded, not tender, about the size of a grapefruit. There were no masses or tenderness in either culdesac, but the mass described was easily felt and was apparently continuous with the cervix. It was freely movable. The urine, temperature, and pulse normal. Dr. Brewster thought the patient probably pregnant and advised waiting a month. She left the hospital April 2d, but re-entered April 15th, having been at the Waverley Convalescent Home until the day before, when she thought she felt a lump drop down in her abdomen. She also said she felt as if she was "going to bust." On examination, the tumor reached from just above the umbilicus to the pubic bone; it was freely movable from side to side, dull on percussion. The vagina was bluish, the

cervix soft and "taken up." There was no demonstrable milk in the breasts.

Discussion.—With no cessation of menstruation, one naturally does not consider pregnancy in this case until other and more obvious alternatives have been ruled out. A distended bladder is the first possibility to be excluded. Such a condition is not common in women except after anesthesia or other causes of coma. In the present case the use of a catheter promptly made us certain that the bladder was not distended.

Fibroid tumors are not common in women of this age, are rarely so smooth and symmetric, and are often well recognized by the patient herself as of long duration before it seems necessary to consult a physician. Fibroid tumors are often associated with metrorrhagia, such as was present in this case, and this possibility cannot be ruled out. There is no way of being any surer as to diagnosis unless Abderhalden's test can be tried. When the present case was seen Abderhalden's work had not been published, but it is in cases such as this that the serum diagnosis of pregnancy is most valuable.

Outcome.—On the 20th it seemed that parts of the fetus could be distinctly felt, and being assured that there was no tumor, but only pregnancy, the patient felt better, slept well, and was able to leave the hospital on the 23d. During most of her stay the temperature ranged between 99° and 99½° F. In due time she gave birth to a normal child.

Case 2

A Greek of twenty-seven, employed in an automobile shop, entered the hospital December 23, 1909. The patient came here from Greece seven years ago. He has never been sick until the present illness, and denies the use of alcohol. About a month ago he felt a little pain in the region of the liver and noticed a very considerable mass in that region. The mass has steadily increased in size ever since, and for two weeks he has had enough pain there to disable him from work and disturb his sleep. The pain is worse at night.

Physical examination shows marked bulging of the lower right ribs, and a smooth, firm mass, dull on percussion, extending from the fourth intercostal space in the nipple line to the umbilicus and as far as the left nipple line. No thrill or crepitus is felt over the mass. There is no edema. Blood and urine negative.

Discussion.—The essentials of this case are as follows: A mass, which appears to be an enlarged liver, has been noticed for a month

by a young Greek. He has watched it grow considerably within that time. He is unusually young for cancer or any other malignant disease of the liver. Moreover, we have no evidence of disease in the stomach or in any other organ whence the neoplasm could have been carried to the liver by metastasis.

Syphilis or cirrhosis of the liver are possible diagnoses, but neither of these diseases often causes as much pain as appears to have been present here. There is no reason to suppose that the mass is due to leukemic, amyloid, or fatty infiltration.

If these diseases are excluded, it is natural to consider the possibility of hydatid disease, especially as the patient is Greek. For the association of Greeks with sheep and sheep dogs, in their own country, is well known to be a potent source of hydatid disease. Nevertheless, nothing better than a tentative diagnosis could have been made in this case, unless additional evidence could be obtained by testing for deviation of the complement. The absence of eosinophilia is notable.

Outcome.—Operation, January 6th, showed presenting in the wound a large liver, in which there was a cyst the size of a lemon. This cyst was shelled out whole. A 4-inch incision was then made in the anterior surface of the liver and another large cyst with a thick white wall bulged through the wound and ruptured, with the escape of a large quantity of yellow fluid. This cyst turned out to be about the size of a grape-fruit and was removed entire. A third cyst, bulging against the diaphragm from the upper surface of the right lobe, was about the size of a baseball. This cyst was ruptured into the cavity of the larger cyst and its sac was removed through the original liver wound. On further examination, a fourth cyst, about the size of a baseball, was felt in the left lobe of the liver, but was not removed. The fluid removed at operation from the cyst looked like serum, but *contained no albumin.* The patient recovered fairly well from the operation, but developed pneumonia and died January 14th. The autopsy, January 16th, showed echinococcus cyst of the liver, double chronic pneumonia, and purulent bronchitis; fibropurulent pleuritis on the right, obsolete tuberculosis of the bronchial lymphatic glands, enlargement of the spleen, and chronic perisplenitis.

Case 3

A housekeeper of fifty-seven entered the hospital January 21, 1908. Three years ago the patient began to have indigestion and simul-

taneously uterine flowing at very irregular intervals. About three months ago she noticed that her lower abdomen was hard. For many years she has had varicose veins in the right leg and for ten years has worn an elastic stocking. A week ago she woke up in the night with severe pain in the right leg. This pain has continued since and has disturbed sleep. For three days it has confined her to bed.

Physical examination was essentially negative except as related to the abdomen, in the lower part of which was a large, nodular, tender, rounded mass, extending from the pubic bone to a point 3 inches above the umbilicus, and from the right flank to a point 4 inches to the left of the median line. It was dull on percussion and slightly movable. The rest of the abdomen was negative. On the inner surface of the right lower leg was an area of redness and swelling, extending from the shin around to and past the median line behind, and from the ankle nearly to the knee. On the inner portion of this were several large blue veins; within the area firm, venous trunks could be felt and could be traced from there up past the knee, on the inner side. The urine was negative. The blood showed a leukocytosis varying from 20,000 at entrance to 36,000 on the 5th of February and accompanying a slight febrile reaction (Fig. 1). After that it gradually declined, although on the 12th of March it was still 19,000. On the 21st of March it was 10,000. On the 23d a vein, large, firm, and slightly tender, could be traced from the *left* knee to the groin. There was a good deal of edema of the leg and thigh. This increased up to the first week in February, then began to go down. The thigh measured 24 inches as against 17 on the other side. On the 21st of February the patient was delirious and disorientated, with marked weakness and a poor pulse. On the 23d free fluid was demonstrable in the abdomen. On the 8th of

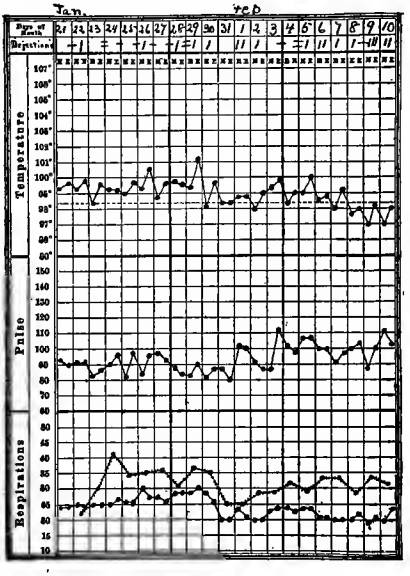

Fig. 1.—Chart of Case 3.

March there was slight divergent strabismus and extensive edema of the skin of the back, extending up to the midscapular region, and associated with dulness and râles at the bases of the lungs. On the 29th of March the eyes were a little puffy in the morning. Meantime the patient had steadily emaciated. The superficial veins over the abdomen were beginning to enlarge.

Discussion.—Fibroid of the uterus, complicated by a phlebitis of the leg, is naturally the first thing to consider in this case. The leukocytosis is naturally to be explained as a result of the phlebitis.

Later on in the course of the case, however, when ascites was demonstrated, mental symptoms appeared, and the edema extended up the thorax, it became clear that the inferior cava must have become blocked. This accident is very rarely associated with fibroid of the uterus. The rarity of this combination and the steady emaciation of the patient might have led us to change our diagnosis. Nevertheless, up to the time of death, no such change was made, and the case was believed to be one of uterine fibroid with complicating phlebitis.

Outcome.—The patient showed but little change except for gradual failure, and on the 23d of May she quietly died. Autopsy showed multilocular adenocystoma of the right ovary. Thrombosis of the inferior vena cava, of the iliac veins, and their tributaries; slight chronic interstitial nephritis; senile degeneration of the myocardium; small myomata of the uterus; ascites; double hydrothorax.

Case 4

A hardware merchant of thirty-four entered the hospital March 15, 1908. The patient's mother died at forty-six of apoplexy, one sister of Bright's disease, otherwise the family history is negative. His own health and habits have been excellent.

Six months ago he began to have a cough with considerable sputa and pain in the arms and legs. At the same time he noticed enlargement of the abdomen. It felt "a little crowded." These symptoms have continued without much change, but have not prevented him from working in his store until three and a half weeks ago, when the cough ceased and he noticed in the left side of his abdomen a bunch as large as a croquet ball and tender, especially when he coughed. He went to bed at his doctor's suggestion and the tumor and tenderness disappeared. Two weeks ago he was again up, but felt worn out. Six days ago a second bunch appeared in his right side, about as large as the first, but more tender. From this time the abdomen

has steadily enlarged. He has noticed no change in color, but his bowels have been loose for six months, moving, as a rule, four times a day. Four or five weeks ago he had a nosebleed. Two weeks ago the abdomen was tapped, but no fluid obtained. Yesterday morning he began to notice that the light hurt his right eye, which felt as if it were bulging out.

Physical examination shows fair nutrition, mucous membranes pale. The right eye protrudes farther than the left, and its move-

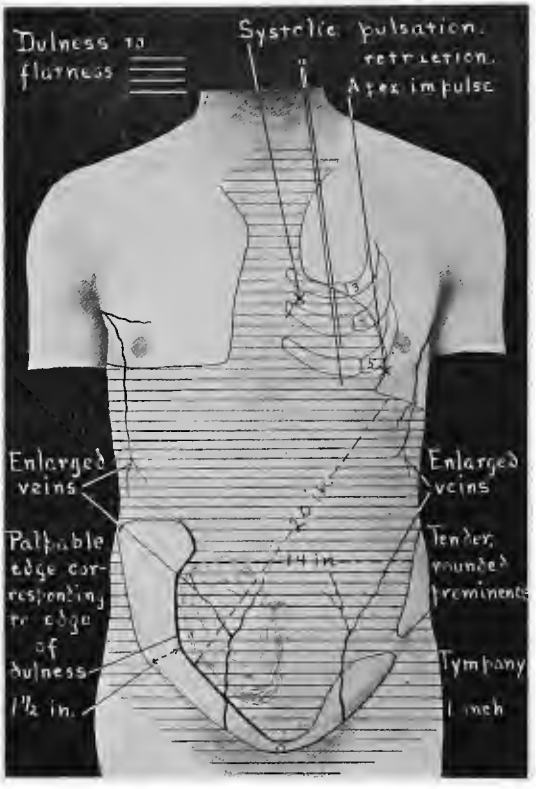

Fig. 2.—Physical signs in Case 4.

ments are markedly limited in all directions. The pupils are normal. There is systolic pulsation in the suprasternal notch. The heart's impulse is seen and felt in the fifth space, $2\frac{1}{4}$ inches outside the nipple line; right border $1\frac{1}{2}$ inches to the right of midsternum. In the third left space, near the sternum, systolic pulsation is visible and palpable. Substernal dulness $2\frac{1}{2}$ inches wide at the second interspace. No murmurs. First apex-sound forcible. Blood-pressure 125 mm. Hg. Lungs negative save for dulness at the bases, especially the right, and

occasional moist râles. The abdomen is prominent, navel flushed, and the veins well marked. It is flat on percussion and everywhere resistant, except for small areas of tympany and softness in the flanks (Figs. 2 and 3). In the right lower quadrant there is a very tender, rounded prominence, rising above the hard, smooth surface of the surrounding parts. A somewhat similar enlargement is noticed in the left upper quadrant. The whole mass moves very slightly with respiration. The liver edge is not felt, there is no edema, no glandular enlargement. Reflexes normal.

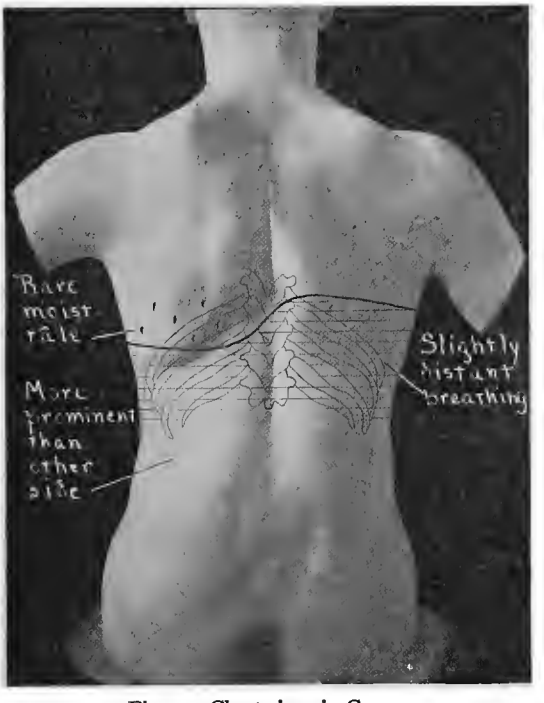

Fig. 3.—Chest signs in Case 4.

Discussion.—A bunch in the left upper quadrant usually represents some disease of the spleen or kidney. Organic disease of the stomach or pancreas very seldom gives us a *tumor* in this vicinity, though gastric flatulence is a frequent cause of *pain* in this spot. Occasionally we have pain and tumor in this region from cancer of the splenic flexure of the colon. The association of tumor with diarrhea in this case makes the possibility of intestinal cancer more considerable, since it must never be forgotten that the intestinal cancer produces diarrhea as often as it does constipation.

With the appearance of the second bunch on the other side of the abdomen and also of a source of pressure behind the right eyeball, we are forced to suppose that more than one focus for disease is present and, therefore, that cancer of the intestine is improbable. If the mass were a hypernephroma, these second bunches might represent metastases; or, if the blood turned out to be normal, a malignant lymphoma would be a possibility. Indeed, the symptoms and tumor masses are strikingly similar to those that I have seen in some cases that turned out to be malignant lymphoma. Everything must rest, in such a case, upon the results of blood examination.

Outcome.—The blood showed 2,680,000 red cells; hemoglobin, 70 per cent.; white cells, 290,000. Differential count showed: polynuclears, 51 per cent.; myelocytes, 42 per cent.; lymphocytes, 2 per cent.; eosinophiles, 2.5 per cent.; mast cells, 2.5 per cent. The urine showed a slight trace of albumin with many fine and coarse granular casts, otherwise negative. Treatments by *x*-ray were begun at once and by the 18th the eye had returned to its normal position and moved freely. The fundus oculi showed a few small hemorrhages in the right retina, more on the left. By the 4th of April the patient was free from pain and showed very great subjective improvement. The blood, however, had not essentially changed. He left the hospital that day.

Postscript.—A rare feature of this case is the association of multiple glandular tumors (for apparently that is what we are dealing with) with a blood-picture ordinarily associated with the myelogenous (not with the glandular) form of leukemia. Ordinarily the bone-marrow—not the lymph-glands—is the seat of the trouble in cases showing such a blood-picture as this.

Case 5

A German housewife of forty-six entered the hospital August 22, 1908. The patient's family history and past history are negative. She passed the menopause three months ago. Eighteen months ago she began to have headache and vomiting in attacks lasting from a few hours to a few days and increasing in frequency. The vomiting came usually after meals and consisted of food. No blood; no preceding nausea. The appetite has remained good. The headache came always on the top of the head and has recently needed morphin for relief. She had lost much in weight and strength. She occasionally felt backache and a dull ache in the right side of the abdomen.

In the evenings she had noticed a slight swelling of the ankles. No nocturia.

Physical examination (including the urine and blood-pressure) is negative, save for the abdomen. Just inside the right anterior superior spine of the ileum is a fairly soft, tender, movable mass, about 7 cm. in diameter. Near this mass the right kidney can also be felt, but the two are separate. Dr. C. A. Porter made diagnosis of cancer of the cecum (Fig. 4).

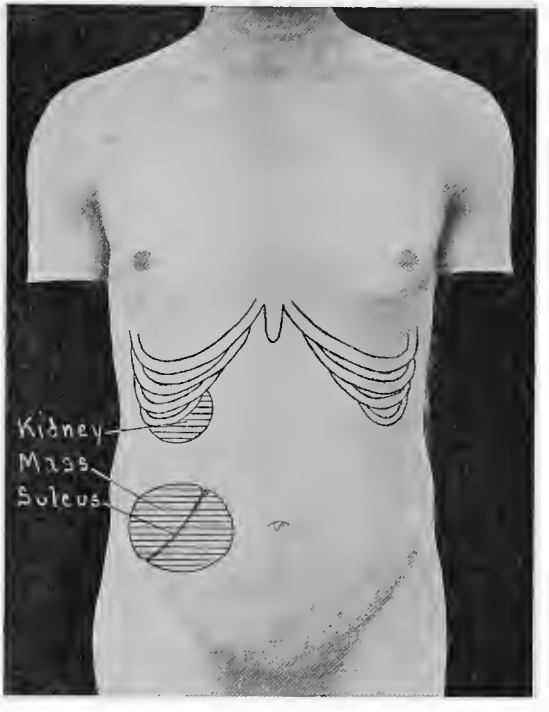

Fig. 4.—Physical signs in Case 5.
The lower mass ultimately proved to be a displaced kidney. The upper mass was not a kidney as we thought, but a "corset lobe" of the liver.

Discussion.—The headache, loss of weight, vomiting, and edema make us think of nephritis first of all, but the negative urine and normal blood-pressure exclude this. Our attention, then, is concentrated upon the mass or masses felt in the right upper quadrant. Against the diagnosis of cancer of the cecum is the fact that there have been no symptoms referable to the intestine, no marked constipation, no pain localized at the cecum, no intestinal noise or visible peristalsis, and, so far as we know, no blood in the stools. It must

be remembered, however, that cancer of the cecum is sometimes an extraordinarily latent disease, covering considerable periods of time. Several patients whom I have studied and in whom cancer of the cecum has been proved by operation, have assured me that the lump which I felt prior to the operation had been there for several years without producing any other symptoms. I have myself studied such a lump, discovered by a patient, utterly symptomless, and finally proved to be cancer after I had watched it (the patient refusing operation) throughout nearly a year's time. Further evidence on this question of cecal cancer might be obtained by bismuth *x*-ray examination, which in 1908 we were not carrying out; also by repeated tests of the feces for occult blood. Malignant lymphoma of the small intestine (ordinarily called sarcoma) cannot, so far as I see, be positively excluded. Such tumors, in my experience, are much more movable than was the tumor present in this case. They are often multiple and usually give rise to some intestinal symptoms, the absence of which in this case has already been mentioned.

Can this mass be connected with the liver? It seems decidedly too far to the right to be a distended gall-bladder, unless we assume that in some mysterious way a gall-bladder is dislocated far from its normal position.

Malignant disease involving the liver usually produces an enlargement of the whole organ and shows multiple nodules, provided that it is accessible to physcial examination at all. A single circumscribed mass, like that here represented, is not at all common in hepatic neoplasms.

Syphilis of the liver might produce such a tumor. One would expect, however, if syphilis were present, to feel other lobules or masses, the result of scarring of the liver substance by gummata. Further evidence might be obtained by a Wassermann reaction.

Tumors of the omentum (which are usually metastatic) are among the most freely movable of all the abdominal tumors, and are seldom if ever found fixed near the spine of the ileum.

If we assume that the physical examination is correct and that the right kidney is entirely separate from the tumor mass, we cannot further discuss an involvement of the kidney itself. It might well be, however, that we were mistaken in believing that the kidney could be clearly differentiated from the tumor. In that case, hydronephrosis, cystic kidney, renal tuberculosis, and hypernephroma would all need to be considered. There is nothing in the urine to indicate any renal disease and nothing in the history to indicate

tuberculous infection or neoplastic cachexia. If cystic kidney were present, we should usually be able to feel a similar mass upon the other side, since this disease is almost invariably bilateral and congenital. The question of hydronephrosis might be settled by taking an *x*-ray plate after the injection of collargol into the renal pelvis.

Outcome.—On the 3d of September the abdomen was opened. The cecum was found normal, but behind it was a mass which seemed to be a low-placed kidney. A lobe of the liver projected downward like a tongue, assuming the shape and position of the normal kidney (Fig. 4). The stomach, pylorus, duodenum, gall-bladder and ducts, the pelvic organs, the intestines, and the left kidney were examined and found normal. The posterior wall of the peritoneum was then opened and the right kidney exposed. The kidney was found to be large, irregular in shape, and the vessels and ureter placed high in the anterior wall. A partial nephropexy was done. The patient recovered well from the operation, but a few days later nausea returned. On the 9th of September a peristaltic wave was seen sweeping across the middle of the abdomen, where it appeared that a large coil of intestine was pushed forward and fixed. In Dr. Codman's opinion this was the duodenum. Washing out the stomach gave some relief. The patient was advised to lie continuously on the right side and on the abdomen. A good deal of relief resulted from this, and by the 13th the patient was taking liquids well by mouth and steadily gaining. On the 26th of September she left the hospital apparently well. October 7, 1909, the patient reported at the accident room in perfect condition. The diagnosis stands as congenitally deformed kidney, gastromesenteric ileus. The upper mass, supposed to be the kidney, was apparently a "corset lobe" of the liver, while the lower mass was the kidney itself.

Case 6

A housewife of seventy entered the hospital August 28, 1908. The patient's mother and one brother died of consumption; otherwise the family history and past history are good. For the past year she has had some general abdominal pain, not severe or localized, not preventing work or sleep. Appetite fair; bowels very costive. She had several short attacks of vomiting and has lost much in weight and strength.

Six days ago she began to have severe pain in the right side of the abdomen, but has remained up and about until today, and has not vomited. Food does not seem to influence the pain.

Physical examination shows poor nutrition and pallor. Above the middle of the left clavicle is a small, hard, round, pulsating tumor, 3 cm. in diameter. (The patient had never noticed it.) The heart's impulse extends 13 cm. to the left of midsternum, 2 cm. outside the midclavicular line. There is no enlargement to the right. The action is somewhat irregular. A rough systolic murmur is heard at the apex and in the axilla. The systolic blood-pressure is 160 mm. Hg. Lungs negative. Filling the right upper quadrant of the abdomen and extending below the umbilicus is a hard, tender, irregular mass,

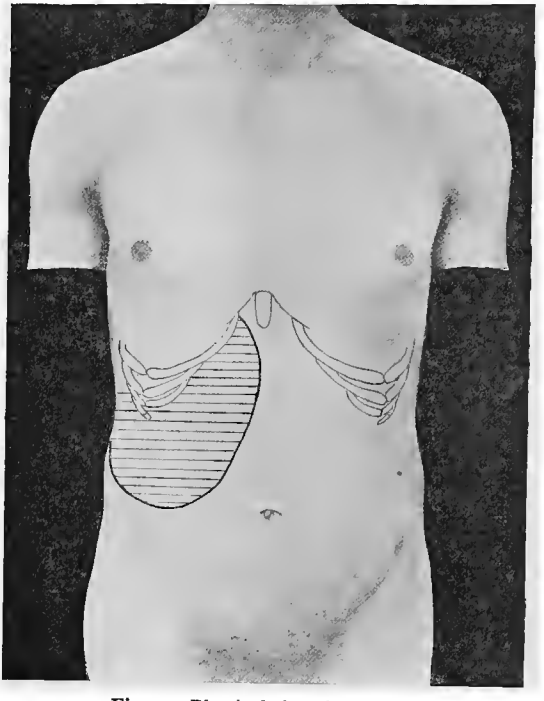

Fig. 5.—Physical signs in Case 6.

palpable bimanually, not descending with inspiration (Fig. 5). Otherwise the abdomen is negative. There is a slight edema of the lower legs. Blood and urine normal. No fever in a week's observation.

Discussion.—The history gives us no clue at all. We know that the patient has lost weight, but at her age this helps us very little. The pulsating tumor above the clavicle should suggest, to anyone who has ever seen a similar case, that we are dealing with a displaced subclavian artery crossing a cervical rib. This is practically the

only common cause of pulsating tumors in the neck. Aneurysms very seldom present at this point, that is, in or outside the mid-clavicular line. They are almost always in the vicinity of the supra-sternal notch, when they extend above the thoracic cavity.

A soft pulsating neoplasm, probably metastatic, deserves merely to be mentioned. Such a tumor is very rare. The diagnosis between this and a misplaced subclavian artery can easily be made by *x*-ray examination.

Beyond this we have to deal with the tumor in the right upper quadrant and flank. From a diagnostic point of view, the most important facts about this tumor is that it does not descend with inspiration and that we have no evidence of its connection with the liver. Its size and position correspond much more nearly with a tumor connected with the kidney than with any other growth. To determine this point more accurately, the colon should be inflated. If the inflated colon comes in front of the tumor, the latter is, in all probability, connected with the kidney. On statistical grounds we should assume that if it is a renal tumor, it is probably a hyper-nephroma.

The patient, no doubt, has some arteriosclerosis, both in and beyond the renal vessels. The heart is doubtless hypertrophied and dilated and its walls weakened. There is no reason to believe that any valvular lesion exists. Murmurs like those here described are very common in hearts which turn out at autopsy to be quite free from any valvular lesion.

Outcome.—The inflated colon traversed the tumor; *x*-ray showed bilateral cervical ribs. The left subclavian artery traversed one of these. Operation (for possible *hypernephroma*) was refused, and the patient left the hospital on the 2d of September.

Case 7

A housekeeper of forty-five entered the hospital September 16, 1908. Two years before entrance the patient noticed prominence in the region of each collar-bone, and for one year has thought that the right side of the face was swollen. She has had indigestion for a long time when she is careless as to diet. If she is careful she has no trouble. Three months ago she began to lose weight and strength. Her usual weight being 144 pounds, she has fallen within a short time to 132 pounds. She has a desire to regurgitate food after a good many meals. Her family history is negative, likewise her past history, except for an attack of sharp pain in the right hypochondrium eighteen

years ago. This was called "inflammation of the liver," was not accompanied by jaundice, and passed off within a few days.

Physical examination shows poor nutrition, slight pallor, pupils, glands, and reflexes normal. In the region of the right temple is a slight prominence, hard, not tender, apparently connected with the bone. The left clavicle is prominent and apparently thickened throughout. Scattered over the face there are numerous areas of erythema, 2 mm. in diameter. There are a few larger areas on the chin covered with fine, white scales. The heart is negative save for a soft, systolic murmur at the apex, not transmitted. The left pulse is slightly greater than the right; otherwise both are negative. The lungs are normal. The edge of the liver can be felt below the ribs, and in the epigastrium there is an indefinite resistance. The upper border of liver dulness is at the sixth rib. The edge of the spleen is felt 4 cm. below the ribs. There are dilated veins on both legs and slight soft edema of the ankles. The tibiæ seem rather rough and irregular. Systolic blood-pressure, 115 mm. Hg. Blood and urine negative. Slight irregular fever as shown in the accompanying chart (Fig. 6). Tube-examination showed apparently a small amount of food in the fasting stomach. On inflation, its upper border was at the ensiform; the lower border $4\frac{1}{2}$ cm. below the navel. No additional information about the abdomen was obtained through this inflation. Microscopic examination of the fasting contents showed that what had been taken for food was not such, mucus and epithelial cells making up the whole residue. Guaiac test was negative and free HCl present. After a test-meal the stomach contents showed free HCl, but too small an amount to be tested quantitatively.

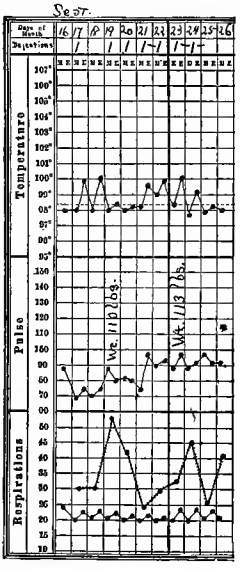

Fig. 6.—Chart of Case 7.

Discussion.—Prominence of the collar-bones and of one temple, associated with loss of weight, are apparently the essential data in this case. There are also facts suggesting enlargement of the spleen and liver, and possibly some syphilitic or other type of periostitis on the shin bone. The history of fever and the negative results of stomach examination are also of importance.

So slow an enlargement of both collar-bones is not likely to be

due to syphilis. Syphilitic lesions of the collar-bone are generally unilateral and circumscribed. They are apt to be associated either with tenderness or areas of softening, such as were absent in this case.

Metastatic neoplasms dependent upon hypernephroma or some other distant focus are very rarely bilateral or symmetric. Moreover, we have nothing to suggest the presence of any primary focus of malignant disease.

Rachitis and other congenital malformations can be excluded only by *x*-ray examination. Everything in the case points to this method of examination as the most important step next to be taken. The *x*-ray should include the tibiæ, as well as the collar-bones. I may add that the findings shown in the outcome, presently to be mentioned, were wholly unexpected to me and, I think, to all who saw the case.

Outcome.—After the time of entrance the edge of the liver was never felt again, though the spleen could always be felt; *x*-ray plates were taken of the whole bony skeleton, and no changes found except in the clavicles, which showed lesions of osteitis deformans in the opinion of Drs. Dodd and of E. A. Locke, whose experience with this disease is more extensive than that of any living observer. The patient left the hospital September 26th, considerably relieved, having gained $3\frac{1}{2}$ pounds.

Case 8

A housekeeper of fifty entered the hospital October 15, 1908. For three months the patient has had severe headaches, constipation, and loss of appetite. For a week she has had pain in the left lower quadrant, never sharp, not influenced by food, not preventing sleep, often relieved by lying on the right side. She thinks there has been some fever. Her family history and previous history are negative. She has six well children and two dead. Her youngest child is seventeen. Catamenia ceased two months ago.

Physical examination showed good nutrition and was otherwise negative save for a blowing systolic murmur at the apex, and a harsh systolic murmur at the base, of the heart. Physical examination of the chest was negative. In the right lower quadrant was a hard, smooth, tender mass, extending to the navel and to the median line (Fig. 7). The cervix uteri was pushed upward and forward, the fundus not felt. In the posterior culdesac was a hard, slightly nodular mass, the size of a lemon. This could also be felt by rectum.

The mass shown in the diagram could be felt bimanually. The blood and urine were negative. The temperature was as shown in the accompanying chart (Fig. 8). On the 19th of October the abdomen was more relaxed and the mass was of the shape shown in Fig. 9. Active carthasis produced no change in it. Menstruation began October 17th.

Discussion.—We are confronted here with a pain in the left lower quadrant. In men such pain ordinarily means cancer of the sigmoid or diverticulitis of the same region. Tumors due to hernia

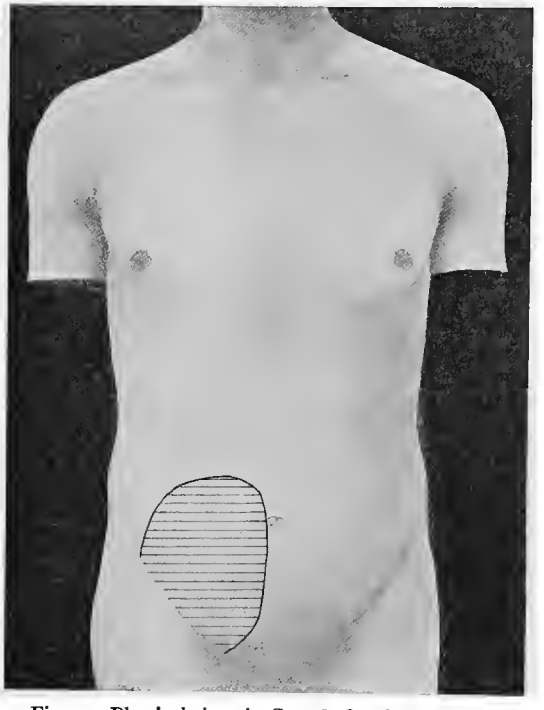

Fig. 7.—Physical signs in Case 8, October 15, 1908.

or to swollen glands are lower down. In women we have to consider not only these diseases, but those arising from the pelvis.

When we come to the physical examination, we find a mass not in the left, but in the right, lower quadrant. Such findings often lead us to disregard the history, assuming that the patient must have been mistaken, but, as the outcome of this case shows, such assumptions are dangerous. Indeed, I think the habit of disregarding the history, provided it is carefully taken, is a very disastrous one. Physicians should cultivate the sort of psychic judgment which en-

ables them to distinguish, better than many "scientifically trained" physicians do, the occasional patient whose words are valueless, and the much commoner patient whose words are precious as guides, but need a good deal of interpretation. A lack of skill in history taking seems to me to mislead us more often than faulty physical examination.

Naturally, one first considers here some tumor arising from the pelvic organs, especially from the uterus or ovary. The mass is obviously too large for any inflammatory exudate starting from a tube. It might conceivably arise from the pelvic bones, but such tumors are very rare. That it is not at all influenced by active catharsis renders doubly sure our natural assurance that it is not connected with the intestine. In view of its situation—very much to one side of the median line—and considering the position of the cervix and the mass in the posterior culdesac, it seems more than probable that the tumor originates in an ovary.

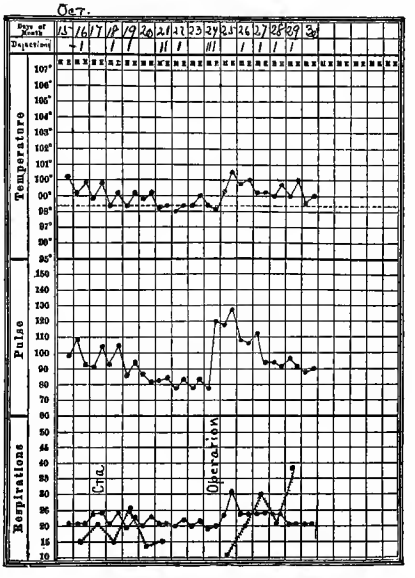

Fig. 8.—Chart of Case 8.

Outcome.—The mass was believed by the surgeon to be multiple uterine fibroids, but at operation, October 24th, two ovarian cysts, purple and about the size of a child's toy balloon, were found connected with each ovary. Each was pedunculated, and the cyst on the right had a double twist of its pedicle, but had not ruptured. The uterus was normal. The gall-bladder was distended and full of stones, but was not molested. The cysts were removed. Microscopic examination by Dr. W. F. Whitney showed that both ovaries were replaced by multilocular cysts, one dark red and filled with hemorrhagic fluid, the other a cystoma, one portion of which was thickened and looked slightly medullary. This latter portion was made up of dense connective tissue in which were some gland-like growths, lined with epithelial cells. Diagnosis, cyst adenoma. The patient made an excellent recovery and left the hospital November 11, 1908, apparently in excellent condition.

Second Entry.—She entered again October 20, 1910, having remained well in the previous two years until September, 1910, when she began to have diffuse abdominal *cramps*, with more than usual constipation, so that the bowels moved only about every three days, although without medicine. Eight days ago she had an especially severe attack of cramps and next morning vomited a small amount of blood. Yesterday and today she again vomited, this time greenish material. Her bowels have now had no movement for seven days. Her chief complaint at present is of a burning sensation at the ensi-



Fig. 9.—Signs in Case 8, October 19, 1908.

form. For the past month she thinks her skin has been growing yellow and her urine more red. At times of late she has had severe sweating, but does not think she has lost any weight.

Physical examination showed poor nutrition, no jaundice, markedly distended abdomen, tympanitic in the lower half, slightly tender throughout, no shifting dulness or fluid wave. Pelvic examination showed a round, hard, slightly nodular mass, pushing the cervix up behind the pubes and filling all the vaults, but not tender. The patient's blood and urine were normal. On the 21st of October the

abdomen was again opened and the pelvis and lower abdomen found filled by a growth surrounding and infiltrating the intestinal walls. The peritoneum was covered with small nodules, a few of which were excised for diagnosis. Microscopic examination showed a solid mass of epithelial cells in small plexuses. Diagnosis: "Cancer." The patient recovered well from the operation and left the hospital on the 28th of October, 1911. A letter sent March 13, 1913, was returned marked "Dead."

Postscript.—In connection with what was said above as to the values and errors of the patient's own account of his troubles, I call attention to the statement made by this patient at her second entry, that her skin had been growing yellow and her urine red. I have found these particular statements peculiarly misleading. One is apt to take them as evidences of jaundice with bile in the urine, but they are more often the patient's way of expressing the fact that his skin is yellow or anemic rather than jaundiced, and that he happened to notice unusual concentration of his urine, with the natural increase of color associated with such concentration. At the time of the second entry it seems reasonable to believe that the patient's symptoms were due to intestinal obstruction, depending on the mass described in the latter part of the preceding paragraph.

Case 9

A shoemaker of fifty-three entered the hospital November 12, 1908. The patient's family history and past history were not of importance. His habits were good.

Eight years ago lumps appeared in the left side of his neck. After the first few months they have not enlarged further. A year ago additional lumps, larger than the first group, appeared in the neck. At the same time other lumps appeared in both axillæ and groins. Nine months ago a lump appeared in the rectum and one in the region of the gall-bladder.

Three weeks ago the abdomen began to swell, and soon after the legs also. A week ago, in the Out-patient Department, he was tapped and 2200 c.c. of ascitic fluid removed; specific gravity, 1011; sediment, lymphocytic. The patient's best weight was 180 pounds a year and a half ago. Just before the abdomen began to enlarge he weighed 160 pounds. His appetite is now good; he feels in most respects well and complains of no pain.

Physical examination shows fair nutrition, moderate pallor. The right pupil is slightly larger than the left. Both react normally.

All the reflexes are normal. The heart's apex is seen and felt in the fifth interspace, 12 cm. to the left of midsternum and $1\frac{1}{2}$ cm. outside the nipple line. There is a soft systolic murmur in the pulmonary area; otherwise nothing abnormal on auscultation. The lungs are negative. Abdomen prominent, navel bulging. Dulness in the flanks, shifting with change of position. Below the right ribs is a hard, smooth mass, internal to the mammary line, not adherent to the skin, not moving with respiration. In the hypogastric region another mass is shown in the diagram of November 12th (Fig. 10). Below

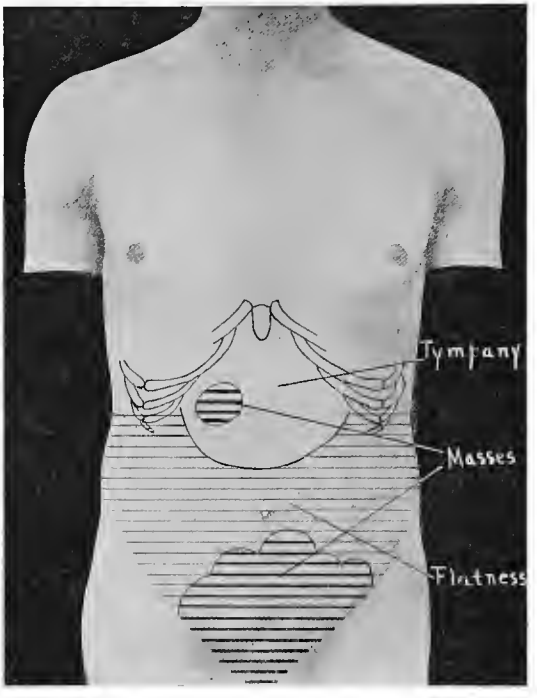

Fig. 10.—Tumors and ascites in Case 9.

the angle of the jaw, on the left, is a mass of glands, 8 by 10 cm., and elsewhere in the neck, axillæ, and groins are lumps the size of a bean to that of a hickory nut. The epitrochlear glands are palpable. The liver and spleen not felt. By rectal examination a nodular mass, half the size of a man's fist, pushes inward on the posterior and right wall. Blood and urine negative.

Discussion.—With multiple lumps in the abdomen and also in the neck, axillæ, and groins, the "snap diagnosis" would naturally be Hodgkin's disease (a term the value of which I shall discuss in a

moment), but first one should exclude, if possible, tuberculosis and syphilis as causes of general glandular enlargement.

Tuberculosis rarely, if ever, produces glandular enlargement lasting eight years without any suppuration. It would be almost certain to produce fever if it were as extensive as the physical signs indicate. If the ascitic fluid were part of a tuberculous process, the specific gravity should be in the vicinity of 1020.

As regards syphilis, there are few if any cases on record showing glandular enlargements of anything like this size in the neck, axillæ, and groins, as well as in the abdominal glands. So extensive a process, if due to syphilis, would probably show cutaneous, oral, osseous, or visceral changes. In this case, therefore, it seems to me that syphilis can easily be ruled out, but it should be borne in mind that when glandular enlargement occurs only in the neck, the confusion of syphilis and tuberculosis is not unusual. I have recently seen, with Dr. Abner Post, a case of syphilitic adenitis of the neck which had been treated for months as tuberculosis. The Wassermann reaction and the results of treatment soon made it clear that the adenitis was syphilitic.

After excluding these two diseases, the affection often known as Hodgkin's disease is naturally the next to be considered. To me it has become increasingly clear, of late years, through the studies of the most accomplished histologists, that there is no proper distinction to be drawn between the various tumors known as Hodgkin's disease, lymphosarcoma, malignant lymphoma, and lymphatic leukemia, except that in the latter case there is a continuous circulating metastasis in the blood, whence the term "leukemia." Why it is that in certain cases this blood metastasis takes place, while in other cases, histologically identical, there is no multiplication of cells in the blood-stream, no one has yet explained. Meantime, it seems well to abandon the attempt to distinguish the various types of disease whose names I have just listed. Minor differences there may be. Clinical varieties, so far as the rate of progress is concerned, there certainly are. A case of malignant lymphoma, with or without leukemia, may remain confined to a few small neck glands for years without any appreciable harm to the general health. In other cases the spread of the disease and the constitutional effects are fearfully rapid. Between these two extremes there is every grade of transition.

To render the diagnosis certain beyond any doubt and to exclude syphilis and tuberculosis finally, a gland should be excised in every case like that just described. The operation could be done under local anesthesia and is of no risk to the patient. It should be remem-

bered, however, that occasionally in the vicinity of tuberculous or otherwise diseased glands one often finds a simply hyperplastic gland, which when excised throws no light upon the diagnosis. Abdominal glands excised from the vicinity of a cancerous tumor often give us this sort of misleading and disappointing evidence, and seem to tell us that the tumor is not malignant when we have every reason to believe that it is, and when its course often proves it to be so.

Outcome.—A gland was excised from behind the ear and showed structure of a malignant lymphoma (lymphoblastoma—Mallory). Coley's serum, every second day, in increasing doses, was given, beginning with $\frac{1}{4}$ minim and working up to 12 minims. A febrile reaction, sometimes carrying the temperature as high as 104° F., followed most of the injections. The patient often has a chill lasting an hour. The abdomen was tapped on the 23d and 82 ounces of brownish-red fluid obtained. It was tapped again on the 4th of December, when 86 ounces of similar fluid were removed; specific gravity, 1015. Smear of the sediment showed mostly epithelial cells. On the third tapping, December 7th, 115 ounces of the same fluid were obtained. After this the abdomen continued to drain until the 11th of December, at which time the patient began to be somewhat drowsy. By the 14th the abdomen was again filled, but when the needle was inserted the fluid would not run, though it drained freely from the tap-hole.

About this time diuretin, 15 gr. four times a day, was begun, and the amount of urine rose to 65 ounces, with considerable improvement in the edema of the legs. On the 20th he was again tapped, but only 12 ounces obtained. The tympany now extended fairly well into the flanks and but little fluid could be obtained. Upon the 23d 17 ounces were removed. On the 28th a loud friction-rub was heard in the left axilla and *x*-ray showed shadow over the whole left side of the chest. Another course of diuretin was given, beginning December 26th, 15 gr. four times a day. The urine rose to 62 ounces and a large amount continued to be passed for three days more. On the 29th of December 7 pints of fluid were removed from the abdomen, after which he felt better and had less edema of the legs; 50 more ounces of fluid were removed January 2d; specific gravity, 1011. At this time and for two weeks previously *x*-ray treatment was used. Other tappings occurred: on the 9th of January, 6 pints; on the 14th, 106 ounces; on the 19th, 96 ounces. The patient grew steadily worse and was discharged on the 21st of January. He died soon after at home.

Case 10

A housewife of thirty-nine entered the hospital September 9, 1905. Her family history is negative, her past history not remarkable. She has had three children, the youngest six years old. Her menstruation is irregular; it often lasts ten days. The last period lasted two weeks.

Five years ago she began to have dull aching pain in the region of the left hip which lasted ten days and then left her. Ten days ago she had sudden pain in the left side of the chest, following an attack of indigestion. It was sharp at the beginning. It is now dull. Between the attack five years ago and the present one there have been some seizures similar to the first. She thinks in the attacks that she passes less urine than ordinary, and after them, more.

Physical examination was not remarkable, except that in the upper left quadrant there was a sense of resistance and slight tenderness and on deep breathing the tip of the kidney (or spleen?) was palpable. An indefinite mass below this was felt, which seemed to be about the size of a lemon. Pelvic examination showed in front of the uterus, in the median line, behind the pubes, a hard mass the size of an egg. The uterus was retroverted; not otherwise remarkable. The urine averaged 35 ounces in twenty-four hours; specific gravity, 1020; slightest possible trace of albumin; a few hyaline and fine granular casts, some with red cells adherent. The blood showed 30 per cent. hemoglobin; red cells, 2,400,000; leukocytes, 4000. The stain smear showed all the characteristics of secondary anemia. During the first week of her stay in the hospital the temperature was slightly and irregularly elevated at times, the highest point reached being 100.8° F.

Discussion.—The spleen or the left kidney are the only organs which often produce a mass like that here described. Assuming that we were correct in feeling a mass behind the spleen, we must be dealing with the left kidney. We have also to account in some way for the mass behind the pubes and for the marked secondary anemia. Both these facts would lead us to suppose that we were dealing with a neoplasm from which metastasis has taken place. Since hypernephromata are specially prone to form bony metastases, one might surmise that the hypergastric lump is connected with the pubic bone and represents such a metastasis. Non-malignant lesions of the kidney, such as cyst or tuberculosis, seem improbable on account of the marked anemia which is not often found in these diseases. Reasoning in this way, the clinical diagnosis of the case, prior to operation, was hypernephroma with menorrhagia.

Outcome.—September 13th the cervix was dilated and the uterus was steamed forty minutes, then wiped out with gauze. On the 18th of September the hemoglobin was 35 per cent.; September 29th hemoglobin 55 per cent. September 30th an incision was made from just above the left anterior superior spine of the ileum for 5 inches, upward and outward. Sections carried down behind the peritoneum, and a cystic tumor was revealed in the region of the kidney. The cyst was ruptured with the escape of clear fluid. No kidney substance and no ureter were found. Nothing was removed. The patient did well and left the hospital October 19, 1905. November 20, 1906, the patient reported by letter that she had improved steadily until March, 1906, and at that time seemed perfectly well.

Soon after that her former symptoms recurred and have persisted since. December 20, 1908, she writes that she has aching in the left side, just above the hip-bone, following down toward the groin, also a backache and "a large bunch reaching toward the pit of the stomach." She has attacks of gastric distress lasting from a day to a week, accompanied by a scanty urination and vomiting.

She re-entered the hospital February 9, 1909, stating that for the past year she had many attacks of pain so great as to produce nausea for several days at a time. In these attacks a mass appears in the left hypochondrium and gradually increases in size. At first it is only the size of a walnut, later as large as the fist. Later it extends into the flank and grows tender. While it is enlarging, very little urine is passed, but by pressing upon the mass the patient can cause it to disappear. Simultaneously she feels urine accumulating in the bladder and can then pass about a pint, which is clear and without sediment. Despite these symptoms her general health has much improved since her last operation.

Physical examination is essentially negative except for a mass in the left hypochondrium (Fig. 11), which is smooth, round, fluctuant, not tender, moves an inch with respiration, and is felt bimanually in the flank. Cystoscopy by Dr. Lincoln Davis showed a normal bladder. From the right ureter indigocarmin was excreted within fifteen minutes. The left ureter excreted no coloring-matter whatever during half an hour's observation. On the 14th of February the mass in the left hypochondrium increased in size during the day so that at night it was the size of a grape-fruit and showed two definite lobes. It was painful and fluctuant. By manipulation the size of the mass was considerably decreased and the pain relieved. February 16, 1909, the old scar was reopened and a large cystic

tumor ruptured, with the escape of a pint of fluid resembling urine. This time the remains of the kidney and ureter were found and removed. Examination by Dr. W. F. Whitney showed a kidney with a very large dilated pelvis, one end of which extended into a large sac; the ureter very small. The patient did well after operation and left the hospital on the 18th of March, 1909. March 24, 1910, the patient reported by letter that she has been perfectly well since operation and does all the work for a family of five. When in the hospital she weighed 104 pounds; now, 120 pounds.

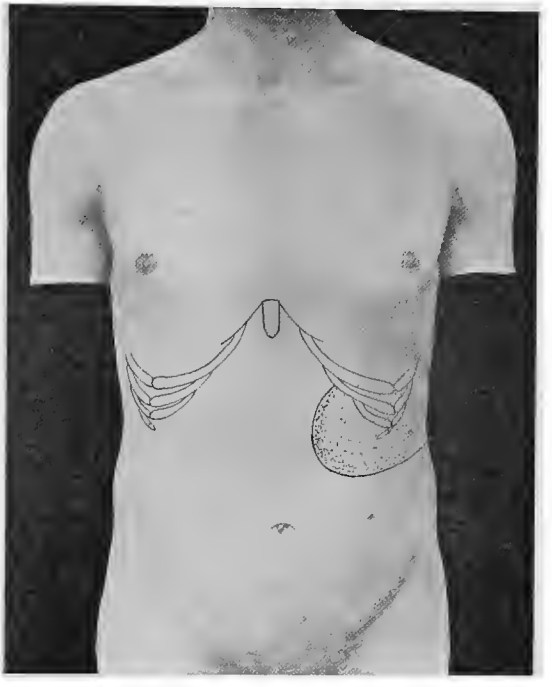

Fig. 11.—Mass felt in Case 10.

Postscript.—The symptoms which the patient presented during her second visit to the hospital were obviously those of intermittent hydronephrosis. Presumably, therefore, that disease was the cause of her symptoms throughout, and the supposed cyst, opened at the first operation, was a hydronephrotic sac. The cause of the anemia was probably the menorrhagia. As the patient has now been under observation for five years, it seems very improbable that any type of malignant disease is present. As to the mass felt near the pubic bone at the first examination, I can only say that it was forgotten for some time, and when looked for again was not to be found!

Case 11

A laborer of forty-five entered the hospital February 4, 1909. Family history and past history not interesting, and the patient's habits good. Four weeks ago the patient felt perfectly well. He was then obliged to work for the whole of one day in the wet, cleaning out

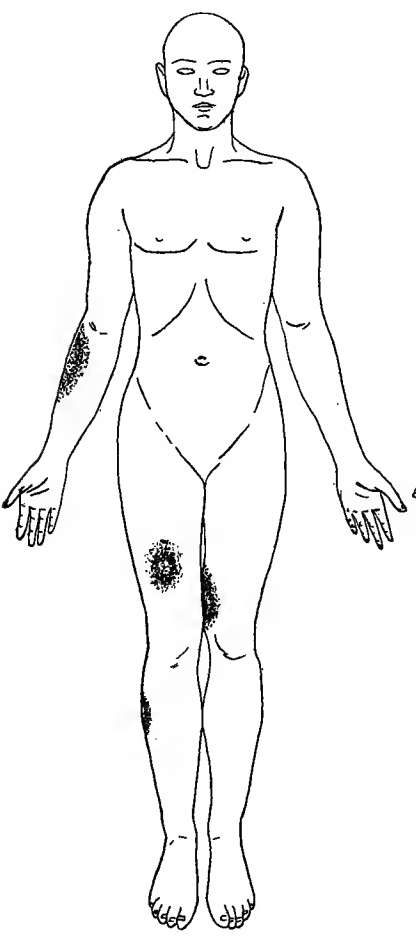

Fig. 12.

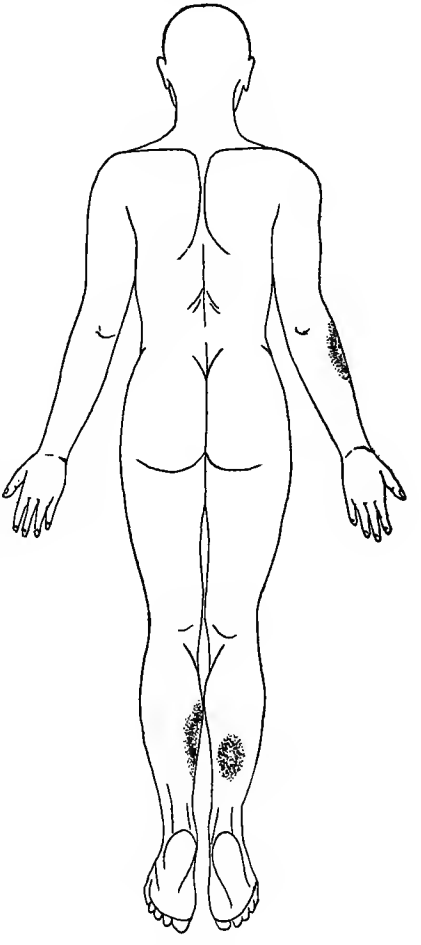

Fig. 13.

a cess-pool. The next day he felt all right, but the day after he began to have pain in the left calf and in the inside of the left knee, especially on getting up in the morning. This pain compelled him to stop work and increased in the subsequent days. Lumps upon his legs were first noticed four weeks ago. For the last two weeks the pain has become somewhat "deadened," as he says, and the swelling is less

marked. Nevertheless, he has been confined to his bed practically all the time in the last four weeks. He has no digestive symptoms, no cough, no loss of weight. He sleeps poorly.

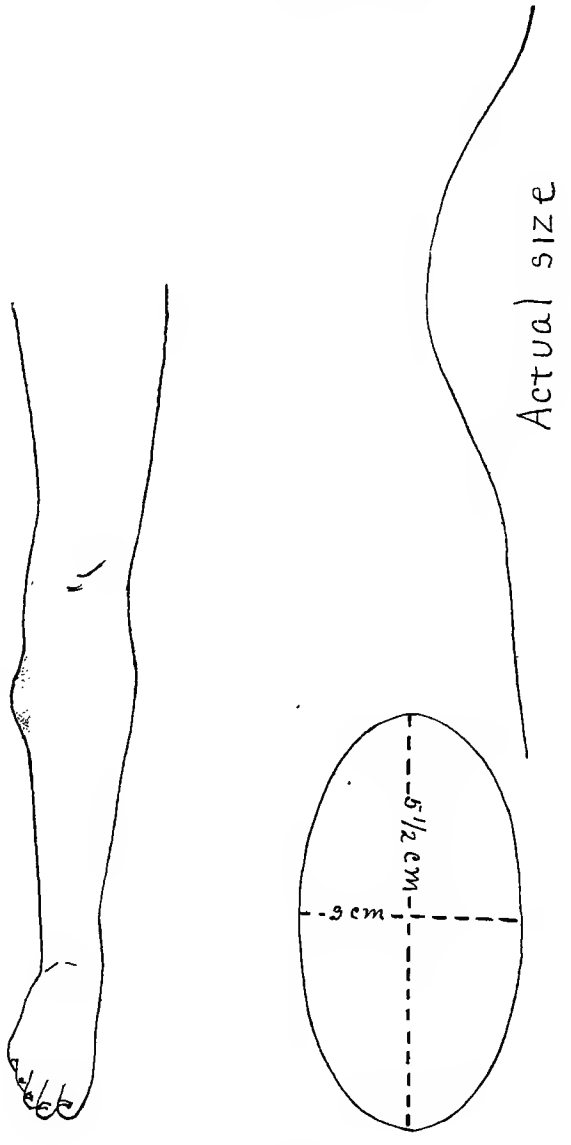

Fig. 14.

Physical examination shows good nutrition. Pupils, glands, and reflexes negative. Chest and abdomen negative. On the right thigh, in the middle of the anterior aspect, is a hard, tender mass,

apparently not connected with the skin, nor with the blood-vessels or the bones. There is no fluctuation in the mass, but it has no sharp limits. The size and situation of this and the other swellings present in the case is shown in the accompanying diagrams (Figs. 12, 13, 14). There was considerable muscular tremor of the calves and thighs. When the patient stood, one of the masses became bluish red. The course of the temperature is shown in the accompanying chart (Fig. 15). The blood and urine showed nothing abnormal. Drs. Mixter and Brewster could make no diagnosis. Dr. H. C. Baldwin thought it probably myositis, and noted increased muscular irritability. Dr. F. S. Burns said, "I think that trichiniasis and dermatitis coccidioides should be considered." A swelling on the nasal septum was examined by Dr. J. P. Clark and found to be nothing but a slight deviation covered by a superficial excoriation.

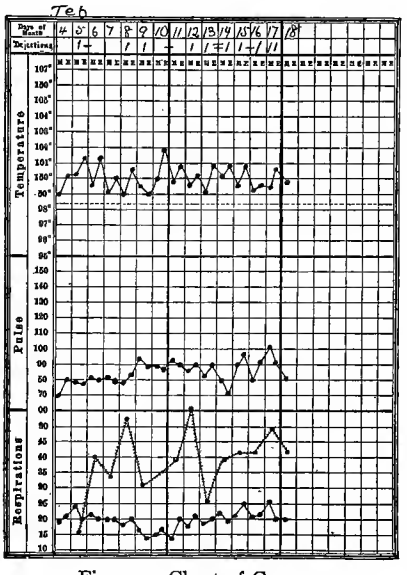

Fig. 15.—Chart of Case 11.

Discussion.—In view of the obscurity of the diagnosis in this case and of the great variety of opinions expressed about it (I have quoted only a few of them here), it seems well to make a survey of the whole list of affections which are known to produce multiple subcutaneous lumps. Such a list is as follows:

1. V. Recklinghausen's disease, or neurofibromatosis.
2. Nodular lipomatosis ("adiposis dolorosa"), with or without pain.
3. Syphilis, in the form of periostitis or gumma.
4. Tuberculosis, especially osseous and periosteous.
5. Sepsis with embolic abscesses.
6. Rheumatic nodes.
7. Erythema nodosum.
8. Urticarial lesions, with or without associated hemorrhages.
9. Angiomata or lymphangiomata.

10. Malignant lymphomata, with or without leukemia. (Such growths can arise from the minute lymph-follicles present in the deeper layers of the skin and in the subcutaneous tissues).
11. Carcinomatosis.
12. Multiple exostoses (or enchondromata).
13. Coccidioidal granuloma.
14. Scurvy.
15. Myositis.
16. Actinomycosis.
17. Glanders.
18. Leprosy.

Differential Diagnosis and Outcome.—Trichiniasis does not produce such swellings. The encysted embryos produce no palpable enlargement of the muscles. Further discussion of the above list of possibilities will follow when we have disposed of this case. The course of procedure was as follows: Within a few days one of the tumors upon the arm showed distinct fluctuation. A needle was introduced and a thick pus obtained. There were many trabeculæ running across the cavity. On the 10th two more tumors were aspirated and about 2 ounces of blood-stained pus obtained from each. On microscopic examination well-preserved leukocytes, but no organisms, were seen. Dr. James H. Wright reported that the smear preparations and cultures from the pus showed a bacillus not inconsistent with the bacillus of glanders in morphology and cultural peculiarities. A guinea-pig which had survived subcutaneous injections of the pus was given a fresh culture intraperitoneally. Two days later the animal died, and autopsy showed numerous white nodules varying in diameter from a fraction of a millimeter to several millimeters, adherent to the peritoneum in the great omentum, in the testicles, and elsewhere. In one of these nodules bacilli like the bacillus of glanders were found. Diagnosis, glanders.

With these facts in our possession, the patient was carefully questioned in relation to his association with horses, but no such history could be obtained, though he admitted that he had slept in horse blankets. On the 18th he was transferred to the surgical service, where he *ran a continuous fever* between 99° and 100° F. *for four months.* The pulse during this time ran between 80 and 100. The abscesses were very slow in healing. April 8th a large slough was removed from the left leg. May 11th Dr. C. A. Porter, under whose care the patient was, thought there was thrombosis in the iliac vessels,

with establishment of a collateral circulation by way of the epigastric vessels. May 15th a new nodule appeared upon the arm (Fig. 16). The old wounds upon the arm were practically healed and that upon the leg was gradually getting well. May 20th the patient was discharged to the Out-patient Department.

Fig. 16.—"Farcy bud" with gangrene.

The patient re-entered the hospital December 30, 1909, with a persistent ulcer in the calf of the left leg, all his other wounds having healed properly (Fig. 17). This ulcer was removed with a considerable margin of skin and its base cureted. As there was some contraction of the foot on this side, the Achilles tendon was cut. The patient left the hospital January 7, 1910.



Fig. 17.—Glanders ulcer in Case 11.

February 22, 1913, Dr. H. Lincoln Chase, of Brookline, Mass., reports that patient is very well and working, though there is still a small unhealed ulcer on one calf, probably corresponding to the lesion shown in Fig. 17. All the other subcutaneous abscesses have wholly healed.

1. *Neurofibromatosis.*—Returning now to the list of diseases producing subcutaneous lumps, neurofibromatosis usually presents

no difficulties of diagnosis whatever. It is a rare disease, and, if not congenital, appears usually early in life, and has generally existed for many years practically unchanged before we have any opportunity of seeing the patient. The appearance of the nodules is seen in Fig. 18. The number of nodules often runs into the hundreds or into the thousands. They ordinarily cause the patient no pain or other trouble, and he seeks advice from curiosity or apprehension. They do not disturb nutrition or general health, and the patient often

Fig. 18.—Neurofibromatosis. The mother, sister, and daughter of this patient all had the same disease (Bryan).

lives to old age. A few of them are sometimes sensitive to pressure. Occasionally nodules within the spinal canal or cranium may give rise to serious symptoms by means of their pressure. The tumors are soft, sometimes pedunculated, ordinarily not larger than a chestnut. Occasionally they may reach enormous size. Histologically they are composed of nerve substance and fibrous tissue in varying proportions. Patches of brown pigmentation on or near the tumors are frequent. Some of the nodes may contain so little nerve tissue

that they are practically fibromata, but there is no need to establish a separate disease entity for the purpose of covering these slight variations from the ordinary type.

2. *Nodular Lipomatosis.*—The ordinary subcutaneous fatty tumor so frequently seen and so harmless, is sometimes present in considerable numbers and in varying sizes. The different types and varieties of this trouble have been described and photographed by Dr. Irving P. Lyon.[1] As a rule, these lumps are wholly symptomless and painless, and the physician is consulted only because the patient wants to be reassured. Occasionally, however, they are quite painful, like the larger areas and deposits of fat first described by Dercum under the term "adiposis dolorosa." There is no sharp line to be drawn between the small, discrete, painless lipoma—single or multiple—and the extensive, sometimes symmetric, deposits of fat tissue—sensitive or insensitive—over various parts of the body. The diagnosis of this condition rests upon the feel, the lobulation and position of the tumors, their long persistence without change and usually without any symptoms whatever, and, in the last resort, upon histologic examination of an excised specimen.

3. *Syphilitic periostitis* may affect a number of bones simultaneously and thus give rise to multiple lumps. It is often painful or tender. The connection with bone can usually be demonstrated by palpation. The absence of suppuration, the evidence of syphilis elsewhere in the body, and the presence of a Wassermann reaction are the most helpful points in diagnosis. *Gummata* arising in the subcutaneous tissues are not likely to remain long without ulcerations, hence they are not often seen as subcutaneous lumps. They are recognized by the presence of other evidences of syphilis and by the exclusion of the other possibilities now under discussion.

4. *Tuberculosis.*—This lesion does not often give rise to difficulties in diagnosis, as it is very prone to involve the skin and lead to sinus formation and suppuration. Slow-healing sinuses, leading to necrotic bone, are more often tuberculous than anything else. Occasionally they may be due to septic osteomyelitis. Other lesions of tuberculosis in the glands or internal viscera or the genito-urinary tract are often present. The *x*-ray appearances are ordinarily characteristic. A negative Wassermann reaction may be of great value, and in young children a positive tuberculin reaction is also useful. In older persons it is almost or quite useless, as a considerable portion of them give a positive reaction, whether they are actively diseased or not.

[1] The Archives of Internal Medicine, July, 1910, vol. vi, pp. 28–120.

5. *Sepsis with Embolic Abscesses.*—The evidences of acute inflammation and the rapid accumulation of pus ordinarily makes the diagnosis clear. In any doubtful case, incision and culture should clear up the doubt.

6. *Rheumatic nodes* are practically confined tendons and aponeuroses (Figs. 19, 20, 21, 22, 23, and 24). One sees them on the tendons of the wrists, about the knuckles and near the elbow-joints and knee-joints, on the forehead near the roots of the hair, and about the occiput. They are practically always connected with other manifestations of that form of streptococcus infection usually called acute

Fig. 19.—Rheumatic nodes on the forehead. These wholly disappeared in two weeks.

or subacute rheumatism. Endocarditis is almost invariably present. It follows, therefore, that they are usually seen in children, rarely in adults. They are very hard and almost invariably painless, averaging the size of a small pea, but their most characteristic feature is the remarkable fact that although they are so hard that it seems they must last forever, they may absolutely disappear within a few days or weeks, only to be followed by new crops. Eventually they disappear for good and all, and if the patient conquers his endocarditis he may remain in full health. They are apt to be confused with the bony outgrowths known as Heberden's nodes which appear on the terminal joints of the fingers, and, once established, last for life. The

latter have no connection with streptococcus disease, rheumatism, or endocarditis.

7. *Erythema Nodosum.*—Red, painful, sensitive lumps appear suddenly upon the flexor surfaces of the forearms and lower legs,

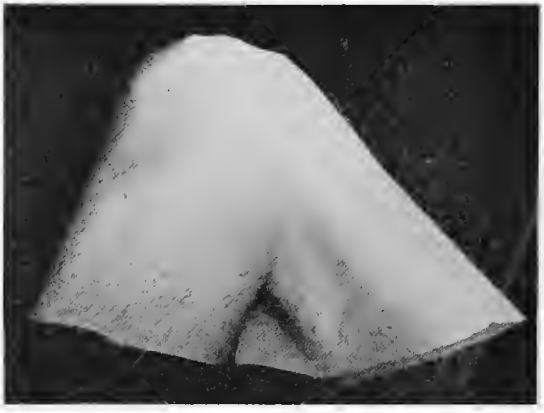

Fig. 20.—Rheumatic nodes on elbow. Same case as Fig. 19.

rarely elsewhere (Fig. 24.) They are almost never suppurated and ordinarily disappear within a few weeks. In most cases they are associated with joint disturbances and often with endocarditis. They are usually believed, therefore, to represent one more manifestation of the picture of streptococcus infection above referred to.



Fig. 21.—Rheumatic node on wrist-tendon. Same case as Figs. 19 and 20.

8. *Urticaria*, or *hives*, is recognized by its severe itching, its rapid appearance and disappearance, and other well-known characteristics not needing further description here. It may be associated with joint manifestations, and when it occurs within the intestine,

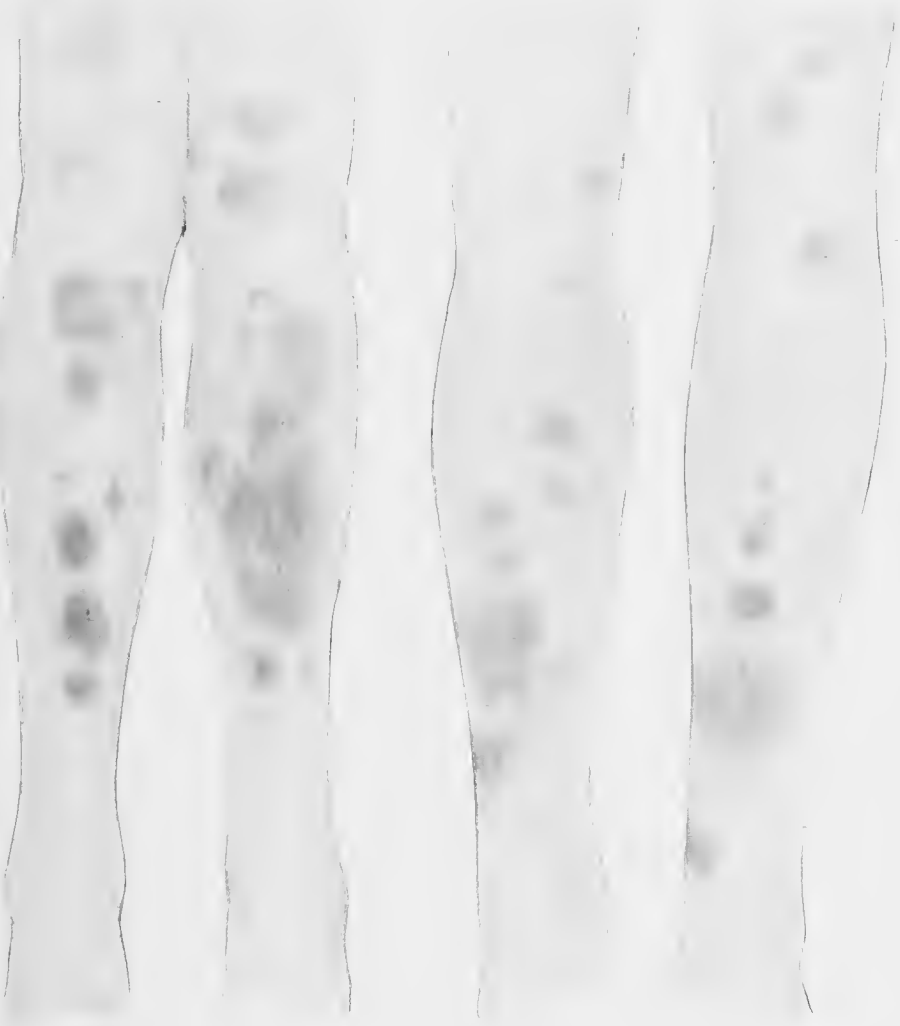

CASE 1.

Female, age 24, 6th day of the illness.

CASE 2.

Female, age 61, 17th day of the illness.

Fig. 24.—Erythema nodosum (from C. Hegler, Ergeb. d. Inn. Med., 1913, p. 620).

may be operated upon for appendicitis, as in the case described in Vol. I, p. 447. Similar lesions in the bronchial mucous membrane may also give rise to acute respiratory symptoms. (See Vol. I, pp. 73, 447.)

9. *Angiomata* are generally bright red and make clear their nature by their color. They are not often much raised above the surface.

Fig. 22.—Rheumatic nodes on finger-tendons.

Between them and the ordinary birth-mark there are all grades of transition. Lymphangiomata seldom produce discrete lumps, but rather misshapen enlargements of a part; for example, of the hand and forearm or of the foot. They fade off into the tissues around them. As a rule, they are congenital or of very long standing before a medical man sees them. They cause no symptoms, and advice is sought

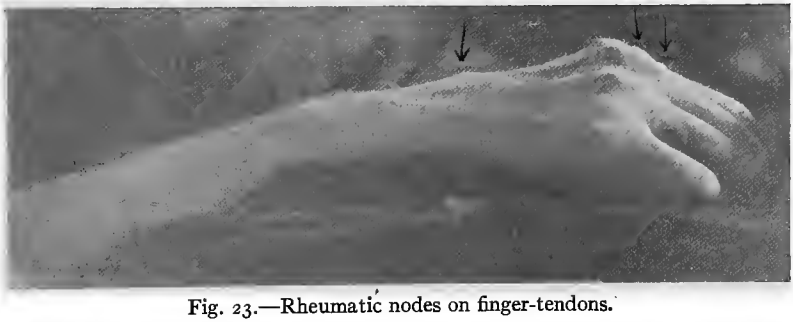

Fig. 23.—Rheumatic nodes on finger-tendons.

on account of the disfigurement. Occasionally we find combinations of angiomata and lymphangiomata.

10. *Malignant Lymphomata.*—So long as malignant lymphomata remain confined to the ordinary sites of lymphatic enlargement—the neck, the axillæ, groins, mesentery, etc.—they are not likely to be confused with any of the lumps which I am discussing at present.

Occasionally, however, and especially in the leukemic varieties of lymphoma, we have nodules in the subcutaneous tissues (Fig. 25). The nature of these will not be suspected unless the blood is examined or unless one is excised for histologic study. They present no distinguishing characteristics on physical examination. They are very rare.

Fig. 25.—Photograph of a water-color drawing of skin nodules in a case of myelemia. (By kind permission of Drs. H. D. Rolleston and Wilfred Fox.)

11. *Carcinomatosis.*—Multiple foci of cancer arising in the skin, as well as in the internal organs, sometimes present a clinical picture very difficult of recognition.

A clerk of thirty-five, who handles raw pork and sometimes eats it, entered the hospital May 13, 1913. Ten years ago he had syph-

ilis. Now he has had fever, backache, leg ache, cough, and diarrhea of two and one-half weeks' duration. The entrance diagnosis was syphilis cerebrospinal. Physical examination (including the urine) was negative save for two small subcutaneous nodules on his chest, each surrounded by a hemorrhagic area. The blood showed 3,200,000 reds, gradually falling to 2,752,000. No achromia or deformities. May 25th, 12 normoblasts per 100 leukocytes (*i. e.*, 1320 per cubic millimeter). Polynuclear leukocytosis (80 per cent.) at entrance, gradually falling to 60 per cent. Eosinophils, 3 per cent.; the rest lymphocytes. The total leukocyte count varied from 10,000 to 18,000.

During the next two weeks he sank and died without any new symptoms except the appearance of firm, insensitive, irregularly shaped subcutaneous nodules in various parts of his body. The largest was 1.5 cm. in diameter. The Wassermann reaction and blood-culture were negative. There was a good deal of bleeding from the nose and rectum. Coagulation-time (venous blood) eight to sixteen minutes. The clinical diagnosis was lymphatic leukemia. Autopsy showed carcinoma of the liver, lungs, pancreas, spleen, mesentery, adrenals, pelvic cavity, epicardium, pleura, sternum, vertebræ, pelvic bones, and subcutaneous tissue; also vegetative endocarditis (mitral), with infarcts of the spleen and subcutaneous hemorrhages.

12. *Multiple Exostoses.*—Aside from the enlargements of the terminal finger-joints (Heberden's nodes), and the similar but less striking enlargements near the articular surfaces of the other long bones, the occurrence of multiple exostoses is very rare. Most of what is known upon the subject has been recently summarized by Dr. Channing C. Simmons in his article on "Localized Osteomyelitis of the Long Bones," which appeared in the "Boston Medical and Surgical Journal" of May 1, 1913.

13. *Coccidioidal granuloma* is a rare disease practically confined to California and difficult to distinguish from *blastomycosis*. It seldom presents subcutaneous lumps at the time when it comes under observation, as the lesions are very prone to involve the skin, to break down and produce chronic abscesses or lesions, from which the characteristic yeast-like budding organisms can be easily obtained, in the great majority of cases. Lesions very similar to those of tuberculosis may also be found in all the organs which tuberculosis attacks. The diagnosis depends upon the exclusion of syphilis, tuberculosis, and malignant disease, and upon the presence of characteristic organisms on coverslip examination.

14. *Scurvy.*—Over the shins, forearms, and near the insertion of any tendon there may occur in scurvy subcutaneous hemorrhages, very slow of absorption and producing slightly raised tumors, not unlike those of syphilis or tuberculosis. The diagnosis of such tumors is, however, perfectly easy in the majority of cases, owing to the other evidences of scurvy in the patient and owing to the conditions of diet revealed by the history. Such swellings are usually very tender and painful.

15. *Myositis.*—Those who practice massage probably have a much greater practical knowledge of myositis than anyone else, but as masseurs seldom have an adequate medical training, they have not yet succeeded in getting their observations thoroughly recognized by medical men. Every experienced masseur can tell us how often subcutaneous *indurations* are discovered during the course of a treatment, and how, as a result of repeated rubbings, these indurations may be removed. Occasionally such forms of localized myositis form visible and palpable lumps, especially about the occiput, where the neck muscles are inserted. They are much larger than rheumatic nodules, and they are much less differentiated from the surrounding tissues and often much less tender. Their exact relation to rheumatic and streptococcic infection is not clear. Indeed, very little is known of them, as very few histologic examinations have been made.

Besides these forms of low-grade inflammation, there have been reported, especially by Japanese observers, a good many cases of suppurative myositis occurring in discrete foci in various parts of the body. Such foci are to be differentiated from glanders only by bacteriologic examination. From ordinary subcutaneous abscesses they are distinguished by their deeper position. Outside of Japan very few such cases are on record.

16. *Actinomycosis*, involving the subcutaneous tissues, usually occurs about the jaw, in the neck, or over the elbows. It seldom produces lumps, but forms a bluish, porky, suppurating sinus indistinguishable from tuberculosis of gland or bone unless careful microscopic examination of the discharge is made by an expert. The disease is very rare and is usually mistaken for tuberculosis or chronic osteomyelitis.

17. *Glanders.*—When the disease has become generalized and is no longer confined to the mucous membranes, it often manifests itself by subcutaneous abscesses, the so-called "farcy buds" of the veterinarian, which must be remembered in human as well as in equine

glanders. The diagnosis rests upon the history of a nasal discharge in one closely associated with horses, and upon the microscopic examination and culture of the pus obtained from the lesions.

18. In *leprosy* the nodules are almost all upon the exposed parts, especially upon the hands and face, though it is believed that the disease most often starts in the nasal cavities. No description of the disease will be attempted here, but it should be remembered as among the possible causes of subcutaneous lumps, especially when these occur in the sites just mentioned.

Aside from the causes of subcutaneous lumps just listed, we may mention the epiphyseal enlargements of *rickets* ordinarily seen at the wrists, ankles, and near the sternum. The deposits of sodium biurate in *gout* sometimes advance along the tendons to a considerable distance from the joints. The pigmented nodes of melanotic sarcoma are usually secondary to similar growths in the eye or the liver, but are sometimes mistaken for moles or warts. Multiple wens about the scalp or about the genitals sometimes give rise to a good deal of doubt and apprehension on the patient's part, and even a physician is sometimes in doubt as to their nature unless he investigates their contents and recognizes the greasy, sebaceous material with which they are filled. I recently mistook a soft metastatic neoplasm of the scalp for a wen.

Case 12

A housewife of twenty-nine entered the hospital February 23, 1909. The patient was sent in from the Out-patient Department with a diagnosis of "retroperitoneal cyst (?)." The patient's husband died eight months ago of phthisis. The patient took entire care of him. Her family history is good, but since the age of sixteen she has had paroxysmal epigastric pain in attacks lasting a few minutes at short intervals for periods of three or four days and recurring at intervals of weeks or months. She sometimes has to go to bed with these attacks. Occasionally the pain is in the lower abdomen. It does not radiate, has no relation to meals, and is never associated with jaundice or changes in the urine. It is often accompanied by vomiting.

Eight years ago her appendix was removed in the hopes of relieving the trouble, but no relief followed. Her appetite is good, her bowels habitually constipated. Her menstruation is irregular, often skipping a period.

Two years ago she noticed that her corsets seemed abnormally tight about the waist, especially just below the ribs in front. Soon

after this a swelling became visible and palpable in the epigastric region. This tumor has increased considerably in size in the past year and the whole abdomen seems somewhat larger. The tumor also seems to be growing firmer. It throbs and beats. Her weight has been slightly increasing for a year. For the past six weeks her face has been puffy, especially about the eyes, and she is somewhat short of breath, which she accounts for as due to the pressure of the tumor.

Physical examination shows good nutrition, many small papules over the back, shoulders, and neck. Pupils, glands, and reflexes

Fig. 26.—Signs in Case 12.

normal. When she lies on her left side a faint presystolic roll can be heard at the apex; otherwise the heart is not abnormal. The lungs are negative. Between the ensiform and the navel is a rounded, tense prominence, about 5 by 7 inches, dull on percussion in its upper two-thirds. During examination the tumor seems to vary somewhat in size. The rest of the abdomen is tympanitic except in the flank, where there is dulness, not shifting with change of position. No fluid-wave can be demonstrated and there are no other masses. The epigastric tumor is moderately tender. No respiratory mobility can be demonstrated. There is notable tenderness in both costovertebral

angles. Leukocytes, 8500; hemoglobin, 90 per cent. Urine normal. No fever in ten days' observation. The possibilities considered were retroperitoneal cyst, connected with the pancreas or kidney, hour-glass stomach, lipoma of the abdominal wall, and phantom tumor. Inflation of the stomach showed that the tumor was displaced or overridden by it (Fig. 26). The capacity of the stomach was 40 ounces. After a test-meal free HCl was 0.09 per cent.; total acidity, 0.2 per cent.

Discussion.—The history gives us nothing definite. The essentials of physical examination are the epigastric tumor of long duration, occurring in a well-nourished woman of twenty-nine. Such a tumor obviously presents something out of the ordinary, for epigastric tumors ordinarily occur in emaciated old people (cancer of the stomach) and are not of long duration.

We must consider a pancreatic cyst, which is a benign, slow-growing affair, and may occur at any age. Such a cyst can be recognized only by ruling out, through extensive examination, any disease of the stomach, liver, and spleen, and then by tapping the cyst and examining its fluid for the presence of pancreatic ferments. If the function of the pancreas is seriously interfered with, we may have glycosuria or fatty stools, In this case the urine and the feces were normal. There was no evidence of disease of the stomach, liver, or spleen. The tumor was not tapped for reasons apparent in the outcome.

Retroperitoneal new-growth, ordinarily malignant lymphoma, would probably have been associated with ascites, emaciation, and pain. Other tumors would, in all probability, be demonstrable within or without the abdominal cavity. The blood might show leukemic characteristics.

The excellent condition of the patient makes us wonder whether the mass may not be in the abdominal wall. A mass of fat or one of the bellies of the rectus sometimes becomes perceptibly prominent, and leads the patient, as well as the physician, to suppose that some disease exists. These possibilities could not be excluded in this case. No positive diagnosis was made.

Outcome.—On the 3d of March the patient was etherized and the tumor wholly disappeared, promptly reappearing when she came out of the ether. Apparently it was a "phantom tumor." She left the hospital on the 4th of March.

Case 13

A woman of sixty-two entered the hospital April 21, 1909. A year ago she had an attack called "inflammation of the bowels." She has also had two previous attacks, rather vaguely dated. In each she had diarrhea, without blood, but with much pain in the left side of the abdomen. Since the last attack, a year ago, she has never been strong, and has never been free from pain in the left side of the abdomen. For four or five months this pain has been quite severe at times, occasionally cramp-like. Hot applications relieve it.

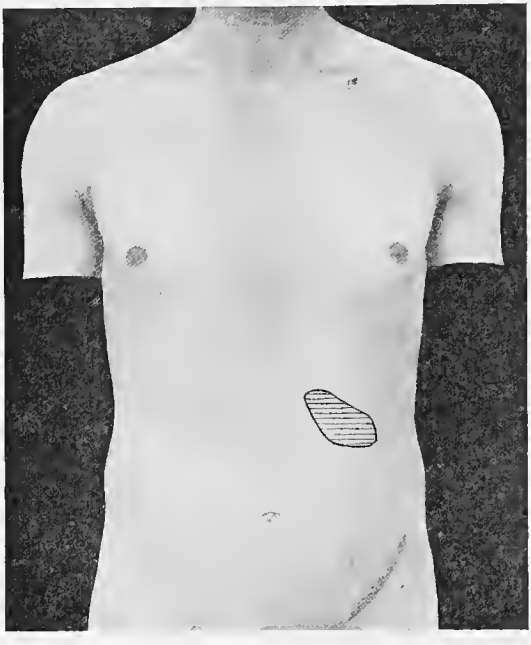

Fig. 27.—Mass felt in Case 13.

Nearly a year ago she noticed in the region of pain a lump the size of her fist. For some time she has been losing weight and strength, and for a year she has done no regular work. Her appetite is good except when the pain is bad; then she vomits everything. Her bowels move daily.

Physical examination shows fair nutrition and is in all respects negative except as relates to the upper left quarter of the abdomen, where there is a hard, irregular, slightly movable mass, not descending with respiration, slightly tender. The colon traverses it (Fig. 27). Blood, urine, and feces normal. No fever in a week's observation.

Discussion.—Diarrhea and crampy pain in an emaciated patient of sixty-two, with a lump in the left upper quadrant, suggests at once a carcinoma of the splenic flexure. The fact that the bowels move daily does not exclude such a disease. The absence of blood in the feces is more definite evidence against cancer of the colon. Still more important as negative evidence is the fixity of the tumor and its size. So extensive a neoplasm connected with the intestine would almost certainly have given rise to marked obstructive symptoms.

May not the tumor be connected with the kidney? That the colon traverses it is wholly in favor of such a supposition, and the negative condition of the urine does not rule it out, though with a tumor of so great a size one would expect a hematuria sooner or later.

Tumors arising in the tail of the pancreas are rare, and if they attained so great a size would probably show some deficiency of pancreatic function, manifested in the stools or urine.

Retroperitoneal tumors arising from the prevertebral glands often give rise to ascites and to fever. The amount of pain associated with them varies greatly. It is often not greater than in this case. After considerable study and after excluding, so far as possible, the other alternatives considered above, I made the diagnosis of retroperitoneal neoplasm in this case.

Outcome.—Dr. C. A. Porter thought the tumor retroperitoneal, possibly sarcoma of the pancreas, the fixedness of the mass suggesting this. April 25th Dr. Porter opened the abdomen and found a tumor, the size of two fists, springing from the retroperitoneal tissues on the level with the lower border of the left kidney. Further exploration showed in the pelvis a hard, irregular mass, the size of an orange, apparently connected with the left ovary. The left broad ligament was thickened and nodular. Between the first tumor and the pelvic mass just described there was another retroperitoneal swelling, about 2 inches wide and nodular. The gastro-intestinal tract was wholly uninvolved. No attempt was made to remove the mass. There was no vaginal examination previous to operation. The patient recovered from the operation and left the hospital on the 13th of May, but died seven weeks later, after much suffering.

Case 14

An automobile repairer of twenty-four entered the hospital December 7, 1911. The patient's family history is negative and he has had no previous disease. For the past three weeks he has noticed a lump in his right armpit. It caused no pain or discomfort until a

week ago. Since then the pain has been increasing and now he is unable to work. For a month he has noticed some headaches, but no defect in sight. His eyes have not been examined.

Physical examination is negative, except for the right axilla, where there is a soft, tender, rounded mass of doughy consistency, about the size of a large plum.

Discussion.—A lump in the right armpit, noticed for three weeks, painful for one week only, is not at all likely to be due to any form of neoplasm. Such growths, if occurring in the axilla, are almost invariably bilateral and accompanied by similar tumors in the neck and groins.

Much more probable is a tuberculous or septic type of adenitis. The absence of any evidence of tuberculosis in any other part of the body and the good previous history and family history make us incline toward a septic type of adenitis. Deep axillary abscesses, which have already been referred to on pages 334 and 484 of Vol. I, should be recognized as a distinct clinical entity of insidious course, and are often unrecognized because the pus is situated so deeply, pressing into the foreground swollen glands which often engross the physician's attention and mask the existence of any other disease.

Outcome.—December 8th the axillary mass was cut open and 2 ounces of thick yellow pus removed, revealing the tumor proper. Complete dissection was carried round the tumor, cleaning out the entire axillary structures, including the brachial vein. The mass thus removed was hard and about 4 by 4 cm. Microscopic examination showed lymph-nodes with slight hypertrophy of the lymphoid elements and a hemorrhagic infiltration of the surrounding tissues. The glands varied in size from that of a pea to an English walnut. The microscopic diagnosis was chronic inflammation. The patient promptly recovered and left the hospital on the 11th of December. There has been no recurrence (1914).

Case 15

A coachman of thirty-seven entered the hospital June 10, 1909. Five years ago the patient noticed a mass in the left side of his abdomen. He is quite sure that that lump is the same which is now palpable there. For the first two years this grew steadily in size. He then began to have *x*-ray treatment and has had it two or three times a week for the past three years. Under this treatment he has felt very well and has worked until three weeks ago. About six months ago he began to cough, and this symptom continues.

Three weeks ago he began to feel weaker and had to give up work. During this period his throat has been sore and swollen. He has also had dyspnea and edema of the feet. At the beginning of this illness, five years ago, he weighed 180 pounds, with clothes; now, 152 pounds, without clothes. The following notes from the out-patient record show his condition three years ago: October 6, 1906, Weight, 160 pounds; hemoglobin, 70 per cent. The liver reaches from the sixth rib to a point 8 cm. below the costal margin. Spleen 16 cm. below the costal margin, in the nipple line and 6 cm. to the right of the umbilicus. White cells, 49,200; red cells, 4,072,000; lymphocytes, 95 per cent. February 7, 1907, White cells, 11,300; lymphocytes, 75 per cent. Spleen much smaller. April 30, 1907, White cells, 8200. May 8, 1908, Hemoglobin, 90 per cent. The liver still reaches 2 cm. below the costal margin. August 2, 1908, White cells, 11,200; lymphocytes, 89 per cent. April 9, 1909, White cells, 20,000; hemoglobin, 85 per cent.; lymphocytes, 98 per cent.

Physical examination June 10, 1909, showed fair nutrition, slight pallor, slight enlargement of the tonsils, moderate enlargement of the cervical, axillary, inguinal, and epitrochlear glands. The heart was negative, save for a blowing, systolic murmur, loudest at the apex, transmitted to the axilla. Lungs negative. The liver edge was felt 6 cm. below the ribs, in the nipple line. Its dulness extended to the sixth rib above. Its surface was slightly tender. The lower edge of the spleen was 20 cm. below the costal margin; its right border at the umbilicus; its surface hard, slightly irregular, not tender. There was moderate soft edema of the lower legs, a considerable discoloration of the skin over the shins and over the spleen. The red cells during the month of his stay in the hospital gradually declined from 1,750,000 to 750,000. The white cells at entrance were 19,000; fell a week later to 13,000; then gradually rose to 20,000. The lymphocytes made up from 95 to 99 per cent. of all the white cells present. Most of them were of the smaller type, but the large forms grew more numerous toward the end of the patient's stay.

At entrance there was some achromia, but this disappeared gradually, and toward the last of his stay the color-index was decidedly high. Examination of the fundus oculi showed numerous hemorrhages throughout the retina of each eye. The temperature during the first three weeks of his stay ranged most of the time between 99° and 100° F., rarely touching normal. In the fourth week it became subnormal. The patient was given atoxyl solution, 5 minims subcutaneously, once a day. Later this was omitted and 15 minims of the

green citrate of iron were administered subcutaneously every second day. Still later Fowler's solution was tried.

Discussion.—When a man notices a lump in his abdomen it is generally a spleen. An enlarged liver is not nearly so often found, and tumors of the stomach are rarely found by the patient himself. In women, pelvic tumors, especially uterine fibromyoma, are more apt to be found by the patient herself.

The enlarged spleen thus found, if it occurs in a temperate climate, is most often due to leukemia. The blood examination of this case leaves no doubt that leukemia of the lymphoid type is the diagnosis. Attention may be called to the following points:

First, The long duration of the case under *x*-ray treatment. It seems to me very doubtful whether this patient would have lived and worked three years after the diagnosis was made unless he had had the advantage of *x*-ray treatment.

Second, The long latent period of the disease. The mass was noticed at least five years before his present entry to the hospital. I have seen at least three patients with lymphoid leukemia and enlarged cervical lymph-nodes who stated very positively that these lymph-nodes had been present for thirty or forty years, *i. e.*, since childhood. Presumably the blood during the greater part of this period was normal. In other words, the tumors which Dr. F. B. Mallory teaches us to call lymphoblastoma[1] often remain for many years non-leukemic. Why they finally begin to discharge cells into the blood we do not know.

Third, Note that the liver as well as the spleen is considerably enlarged, yet was not noticed by the patient himself.

Outcome.—Despite all attempts at drug treatment, the patient lost ground steadily, and by the 4th of July had considerable ascites. The patient desired to go home, and left the hospital on the 7th of July.

Case 16

A baker of forty-five, a Scotchman, entered the hospital July 16, 1909. After an uneventful life the patient began ten months ago to have severe, steady pain in the right side of the abdomen. He became so weak that he went to bed for a month, though the pain was gone in about two weeks. When he got up his legs began to swell and have remained swollen ever since, though he has regained some strength. He has been unable to work for ten months. Six months ago he

[1] Principles of Pathologic Histology, Frank B. Mallory, p. 326, W. B. Saunders Co., 1914.

noticed enlargement of the abdomen. He has coughed all his life, he says; no more now than previously. It is his habit to take four or five drinks of whisky a day. The present swelling in his legs began also ten months ago. His usual weight is 140 pounds, with clothes; at entrance, 128¾ pounds, without clothes.

Physical examination shows poor nutrition and pallor. The cervical, submaxillary, axillary, and inguinal glands are enlarged, some to the size of a pigeon's egg, some to the size of a hen's egg. The heart's impulse extends 2 cm. outside the nipple line, the right border 3½ cm. from midsternum. There is a slight systolic murmur at the apex transmitted to the axilla. Pulmonic second sound is not accentuated. The lungs are negative save for flatness, absent breathing, and fremitus below the angle of each scapula behind.

The abdomen shows tumor masses, one in the suprapubic and right iliac region, another under the right ribs. There is also a suggestion of a mass in the neighborhood of the navel. The rest of the abdomen is occupied by fluid. The veins over the abdomen are considerably enlarged.

During six weeks' observation the patient had no temperature, but gradually lost 5 pounds. The urine was negative. The blood showed red cells 2,760,000 at entrance, and this figure did not vary much during the period of observation. The hemoglobin gradually rose from 65 to nearly 80 per cent. The white cells ranged from 85,000 to 100,000, over 95 per cent. of them being small lymphocytes, with a few per cent. of large lymphocytes. The red cells showed considerable achromia, slight deformities, no nucleated forms.

Discussion.—In view of the blood examination, there can be no considerable doubt of the diagnosis in this case. It differs from the last case, notably, in the presence of pain. In my experience pain is much more apt to be present in those cases of leukemia arising from abdominal tumors outside the spleen and liver or from thoracic tumors. When the main growths are in the cervical, axillary, or inguinal lymph-glands or are confined to the spleen and liver, the patient does not usually complain of pain, but when, as in the present case, we have masses arising from the abdominal lymph-glands and pressing forward beneath the abdominal wall, pain is usually more or less troublesome. The association with ascites is to be expected, since the enlarged glands and extraglandular masses surround and compress the vascular root of the mesentery.

The commonness of these lymphoblastic tumors without leukemic blood has been concealed, to a certain extent, from our recognition on

account of complications in terminology. We have called them sarcoma, lymphosarcoma, and laid stress upon the particular organ in which they arise. But if their fundamental similarity in structure is recognized, it will be seen that tumors of this general type, the type which may or may not be associated with leukemic blood (lymphemia), are not at all uncommon.

Note that in this case the hemoglobin showed considerable improvement, but the patient did not. Such discrepancies are not infrequent and remind us that the blood represents, after all, only a minor feature of the disease. In some cases the patient gets much better, although his blood remains unchanged.

Outcome.—The patient had *x*-ray treatment, but showed no considerable improvement, and left the hospital August 25th.

Case 17

A farmer of thirty-eight entered the hospital August 5, 1909. The patient has an excellent family history and has always been well and strong until last fall, when he was operated upon for appendicitis. His habits are good. He denies venereal disease.

After the operation he did not regain his strength, and began to notice that any considerable exertion caused an ache in the right side of his abdomen, though there was no sharp pain such as he had had before the operation. This ache has gradually become continuous and now disturbs sleep. Occasionally the ache extends to the right leg or to the genitals. For one month he has had to pass urine four or five times daily and once or twice at night. Eating seems to increase his discomforts and his appetite is poor. He thinks he has lost 5 or 6 pounds in the last two months. He has always lived in New England.

Physical examination shows emaciation, yellowish skin, but no definite jaundice. Pupils, glands, and reflexes negative. Chest negative save for flatness, diminished breathing, diminished fremitus, and fine moist râles at the base of each lung below the angle of the scapula. The abdomen shows dulness in the flanks not shifting with change of position. In the right lower quadrant are bunches, probably from a hernia in the scar of the old appendix operation. The liver dulness extends from the sixth rib to a point 2 cm. below the ribs, 12 cm. below the ensiform. Its smooth, non-tender surface can be indistinctly made out. The smooth edge of the spleen can also be felt 2 cm. below the ribs in the nipple line. Later a shifting of the dulness in the flanks was demonstrable on change of position and a

mass was made out in the right iliac region. This mass was about the size of half a lemon, egg shaped, slightly irregular in surface, fixed, not tender. Examination of the urine and stools showed nothing abnormal. The blood was also negative. The course of the temperature during twenty days' observation is shown in the accompanying chart (Fig. 28). The patient's girth at the umbilicus was 87 cm. before tapping, August 10th, when 2 quarts of fluid were removed. After this no new masses were felt, but the edge of the spleen and the lump in the right groin were very distinct and there was a visible and palpable mass in the epigastrium, probably part of the liver, and descending freely with respiration. The tap fluid measured 1850 c.c. with a specific gravity of 1008; differential count: lymphocytes, 65 per cent.; endothelial cells, 35 per cent.

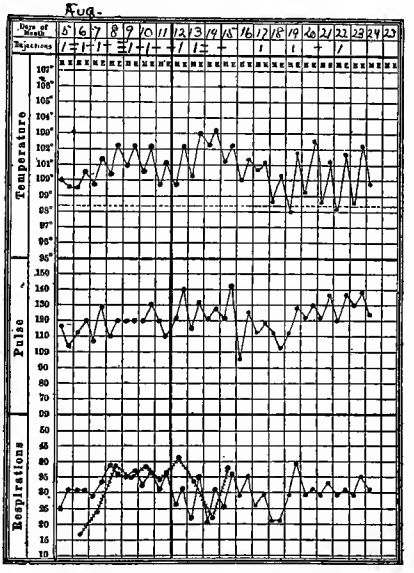

Fig. 28.—Chart of Case 17.

Dr. Wilder Tileston made a diagnosis of hepatic cirrhosis, luetic or alcoholic in origin, with tuberculosis of the lung. The blood showed red cells, 1,500,000; white cells, 5000; hemoglobin, 40 per cent.; differential count, normal. Marked achromia, some stippling and deformity of the red cells. No nucleated forms. August 15th a transfusion of blood was done, after which there was slight icterus and the urine was bile stained. The red count rose to 2,300,000. Dr. Tileston at this time regarded the case as Banti's disease. Dr. C. A. Porter thought it was probably malignant disease.

Discussion.—The history gives us no clue, although it suggests that the trouble is probably abdominal. The chest signs indicate nothing more definite than a high position of the diaphragm. Despite the opinions of the distinguished consultant, who suggested cirrhosis or Banti's disease, it seems to me that attention should naturally be concentrated upon the mass felt in the right iliac region. Neither cirrhosis nor Banti's disease can account for this mass. It is situated in the vicinity of the cecum and its association with a continued fever suggests tuberculosis. I do not see how this disease can be

positively excluded, but the characteristics of the tap fluid are not at all those which we would expect in tuberculous disease of the peritoneum. A specific gravity of 1008 corresponds rather with a dropsical effusion or a pressure fluid than with exudate accompanying tuberculosis of the peritoneum.

Cancer of the cecum is also a possibility, but it is not probable, because we have no symptoms pointing distinctly to the intestine, no evidence of obstruction, and no diarrhea. Cancer of the cecum usually remains for a considerable period without forming extensive metastases, and the presence of ascites, which would have to be referable to such metastases, is, therefore, somewhat against cancer of the cecum.

A lymphoblastoma, involving the spleen, liver, and abdominal lymph-glands, would seem to fit the facts better than any other diagnosis. In view of the blood examination, this tumor must be supposed to be of the non-leukemic type, sometimes called Hodgkin's disease.

Outcome.—The patient left the hospital August 24th and died September 14th. Autopsy showed malignant disease in the tail of the pancreas, with extension to the spleen, very slight involvement of the liver, but considerable deposits in the retroperitoneal and thoracic glands.

Case 18

A jeweler of thirty-seven entered the hospital January 1, 1912. The patient has been well except for children's diseases until five weeks ago, when he lost his voice for a few days and felt so weak and listless that he stayed in bed for a week, coughing up much phlegm at that time. He still has a slight cough. Two years ago he noticed a tumor in the region of his loin about the size of a lemon. This tumor seemed to cause him pain when he lay down or sat for any length of time. He now has a cluster of three bunches upon his left forearm which cause a drawing pain when he chops wood. Other similar bunches have been noticed in various parts of his anatomy in the past ten years, but have given no trouble.

Physical examination is negative save for moderately enlarged tonsils, elongated uvula, a chronic pharyngitis, and innumerable subcutaneous tumors with which the patient's body was almost covered. They were firm, freely movable, not tender, varying in size from that of a walnut to that of a duck's egg. Both arms are also covered by these nodules, but there are none upon the legs.

Discussion.—When a patient has had bunches in or under his skin in various parts of his body for ten years, without any noted increase in their size, we can only suppose that a neurofibroma, an angioma, or a lipoma is present. The more malignant types of tumor mentioned in the discussion of case No. 11 can be excluded. So far as I am aware the non-leukemic lymphoblastomata, while they may involve the skin, never last so long as these without producing more marked symptoms. Further evidence as to the nature of these lumps can only be obtained by excising one.

Outcome.—Three small nodules upon the forearm were dissected out under ether anesthesia, and another group in the left back below the twelfth rib, just outside the erector spinæ muscles. Examination of these tumors by Dr. W. F. Whitney showed nothing but fat tissue.

Case 19

A housewife of twenty-four entered the hospital August 7, 1909. The patient has had an uneventful past history, has one child, and has had no miscarriages. Her menstruation has always been painful. She has had no regular period for two months, but some flowing for three weeks.

Three weeks ago, while ironing, she felt as if something suddenly slipped down in the pelvis, and immediately felt sharp pain there and down the left leg. She felt faint and lay down, with much relief. Since then she has not been free from pain, though it has usually been only a dull ache. At times, however, it has been so sharp as to awake her from sleep or to cause vomiting. These attacks are relieved by morphin. Of late she has several times felt chilly or feverish. Her appetite is good, bowels loose; she sleeps only with drugs.

Physical examination shows good nutrition and color. Pupils, glands, and reflexes normal. Abdomen negative except as shown in Fig. 29. White corpuscles, 13,400; hemoglobin, 85 per cent. Urine negative. Temperature, 99.5° F. at entrance. Pulse, 80.

Discussion.—The essential points in this case are the irregularity of menstruation, the sudden onset of pelvic pain and presence of pelvic tumor, without signs of peritoneal inflammation. The two pelvic diseases which most often begin *suddenly* and present a tumor on examination are extra-uterine pregnancy and the torsion in the pedicle of an ovarian cyst. Pyosalpinx may, of course, begin suddenly, yet not, as a rule, so suddenly as in the present case. The amount of tenderness and fever is usually greater in salpingitis than

in the present case. It is notable that the patient has good color and a normal hemoglobin. Were there any extensive hemorrhage or peritonitis, the color and hemoglobin would probably be poor.

Since menstrual irregularities are somewhat more often associated with extra-uterine pregnancy than with ovarian cyst, the latter diagnosis seems less probable in this case.

Outcome.—Operation, August 9th, showed a large blood-stained mass in the left tube. The left tube and ovary were removed, also

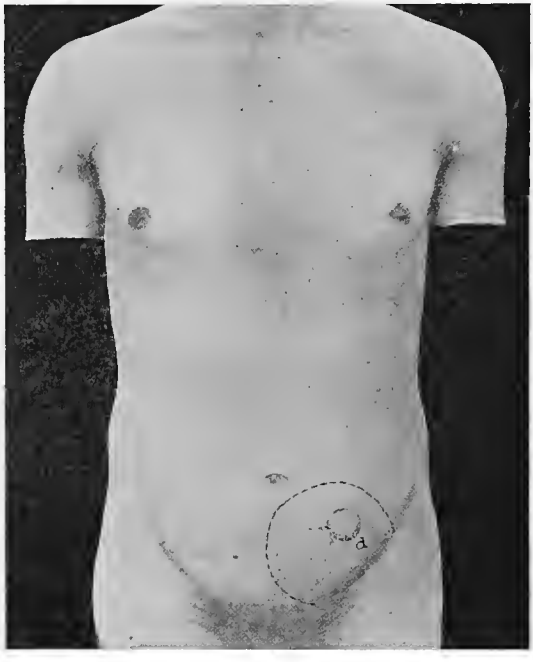

Fig. 29.—The dotted outline shows the dull area. The area labeled *a* was resistant and tender.

the appendix. Pathologic examination showed a mass the size of an orange, made up of a thickened tube, much blood-clot, and the ovary. Microscopic examination shows thickening of the walls of the tube with engorgement of the vessels and some inflammatory reaction, also a few structures suggesting villi, but no positive signs of pregnancy. Nevertheless the case was considered one of extra-uterine pregnancy. The patient made an uneventful recovery and left the hospital on the 23d of August.

Case 20

An unmarried girl of twenty-five was sent into the surgical wards with an Out-patient Department diagnosis of "sarcoma of the thigh," November 3, 1911. The patient had never been sick before, but had a cataract removed from the right eye a year ago at the Carney Hospital. At that time she had enlarged glands in the groins and first noticed contractions of the cords behind the knee. The inguinal glands have grown steadily, but have not been severely painful, though the discomfort from them has sometimes kept her awake. For a month she has not worked. She has lost in the past year 15 pounds in weight.

Physical examination shows good nutrition. The pupil of the left eye showed an irregularity corresponding to the operation above referred to. The other pupil normal. Mouth and glandular structures negative. Chest and abdomen negative. Over the left thigh, beginning just below the groin and extending down the anterior and internal surface about 14 cm., is a tender swelling, not connected with the superficial tissues, not fluctuant, and apparently beneath the superficial muscles. An *x*-ray showed no involvement of the bone.

Discussion.—The tumor in this case occupies an unusual position. One sees in this situation a glandular mass extending downward from the inguinal lymph-chain, thrombosed veins, inflammatory exudates originating in an osteomyelitis of the femur, and malignant tumors springing from the same bone. The latter, however, would present a much larger, more diffuse growth. Lymphoblastoma, involving the inguinal glands, would probably appear elsewhere, and is rarely so tender. Such glandular masses would be very unlikely to seem so deeply situated beneath the superficial muscles.

A phlebitis should show involvement of the vein above and below the point described in this case. It would hardly be possible for a phlebitis to be confined to a space 14 cm. in length.

Since the *x*-ray shows no involvement of the bone, it is not likely that we are dealing with an exudate springing from an osteomyelitis.

Herewith I have excluded all the possibilities suggested in the first place, and must confess that I was at a loss to make a diagnosis, and was quite unprepared for the lesions shown in the outcome.

Outcome.—Operation on the 10th of November showed a mass involving the muscle tissue and not incapsulated. The tissue was white and fibrous, strongly suggesting sarcoma. A piece the size of the palm of the hand was removed. Examination by Dr. W. F.

Whitney showed dense fibrous tissue, in the midst of which there were irregular areas of cheesy material. On the edge of this cheesy degeneration were lines of round-cell infiltration and in the adjacent tissue small vessels with marked proliferation of the intima. In one of these vessels a slightly cellular nodule, lying just beneath the intima. In several places there were large scattered giant-cells. Diagnosis, gumma. Wassermann reaction positive; 0.6 gm. of "606" was given intravenously, and iodid of potash, 5 to 30 gr., three times a day. The patient left the hospital on November 29, 1911. December 6 1912, she was seen and was apparently in perfect health.

Case 21

A colored boy of fifteen, employed in a shoe factory, entered the hospital January 19, 1910. The patient's family history and past history were negative until last May, when his abdomen got large

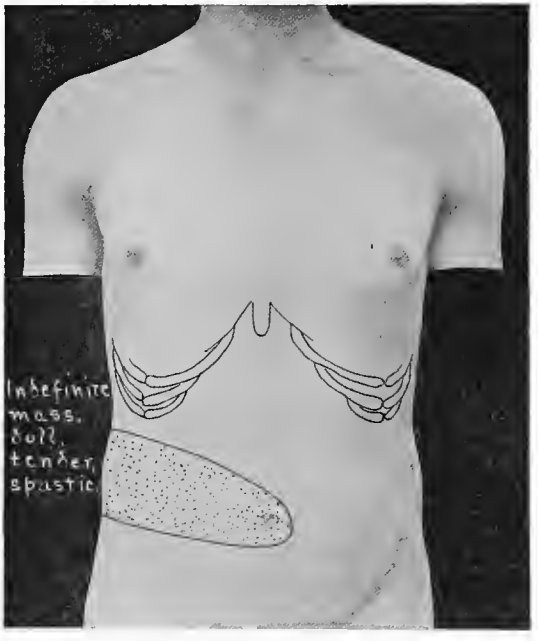

Fig. 30.—Mass felt in Case 21, January, 1910.

and tight; on the 19th it was opened and much fluid removed, with great relief. He then remained well all summer and up to a month ago, when he began to have pain in the region of the scar and to the right of it. This pain was always worse at night, especially after a heavy supper. It usually came about three hours after eating and lasted four or five hours. His appetite and digestion were good, bowels

regular. He had no cough until within the past two days. For three weeks he has been much troubled by itching all over his trunk.

Physical examination showed fair nutrition. At the right pulmonary apex behind there were fine crackles, with cough, and over the left clavicle the breathing was abnormally high pitched. The heart was normal. The abdomen was slightly full and spastic, especially in the right half, where there was an indefinite mass, as shown in the accompanying diagrams (Figs. 30, 31, 32). The temperature as in the accompanying chart (Fig. 33). During his two months' stay

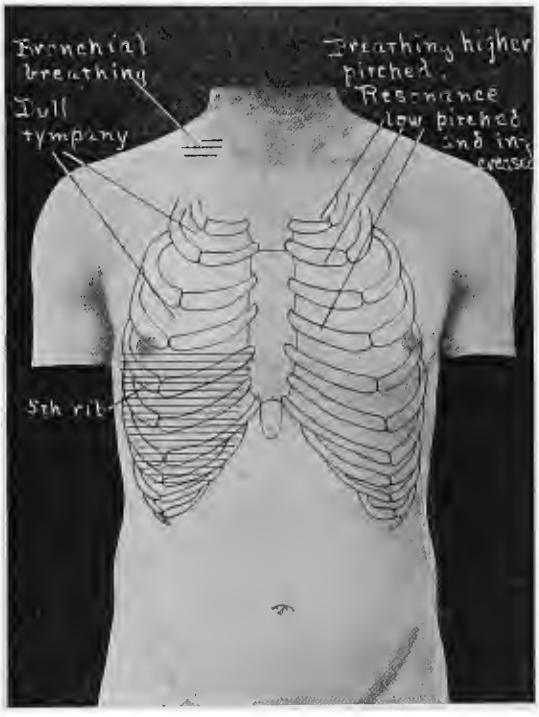

Fig. 31.—Chest signs in Case 21, January, 1910.

in the hospital he slowly lost weight. At entrance it was 111½ pounds; at discharge, 104 pounds. He was perfectly comfortable, as a rule, but unless his bowels were kept very free he had attacks of sharp pain in the right lower quadrant, relieved by glycerin enema. He did not improve in any respect and was sent, on the 17th of March, to the Lakeville Sanitarium. His itching was due to scabies.

He entered the Massachusetts General Hospital again July 5, 1910, coming there straight from the sanitarium, where he had gained 6 pounds and for two months had less pain. The condition of his

abdomen is shown in Fig. 34. In other respects he was practically as before. Operation was advised, and in view of the lower temperature (Fig. 35) and the negative blood and urine, he was transferred to the surgical wards.

Discussion.—In view of the soundness of the heart and kidney in this case, one can scarcely consider with seriousness any diagnosis except tuberculous peritonitis. This is by far the commonest cause of free fluid in the abdomen in a boy of fourteen. Malignant disease, especially lymphoblastoma, is possible, but rare.

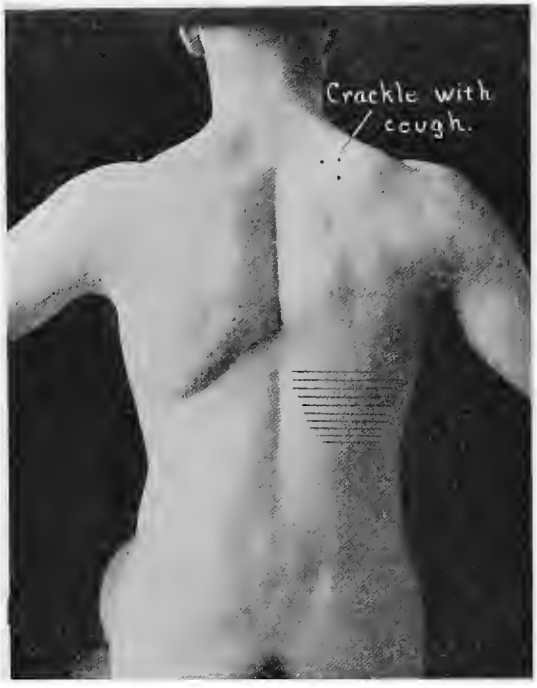

Fig. 32.—Chest signs in Case 21, January, 1910.

At the time of his second entry, when a tumor was present, there could no longer be any question of any diagnosis except the two already mentioned, and the duration of the illness, together with the existence of fever, makes tumor very improbable. The fact that there has been a gain in weight and improvement in the general condition makes it practically certain that he is not suffering from malignant disease.

Outcome.—On the 19th of July the abdomen was opened with some difficulty, owing to adhesions between the intestines and the abdominal wall. The tumor proved to be a mass of large and small

intestines matted together about the cecum. Numerous miliary tubercles were scattered over the intestine and on the parietal peritoneum. The remainder of the peritoneal cavity was not explored, owing to numerous adhesions. The boy recovered well from the

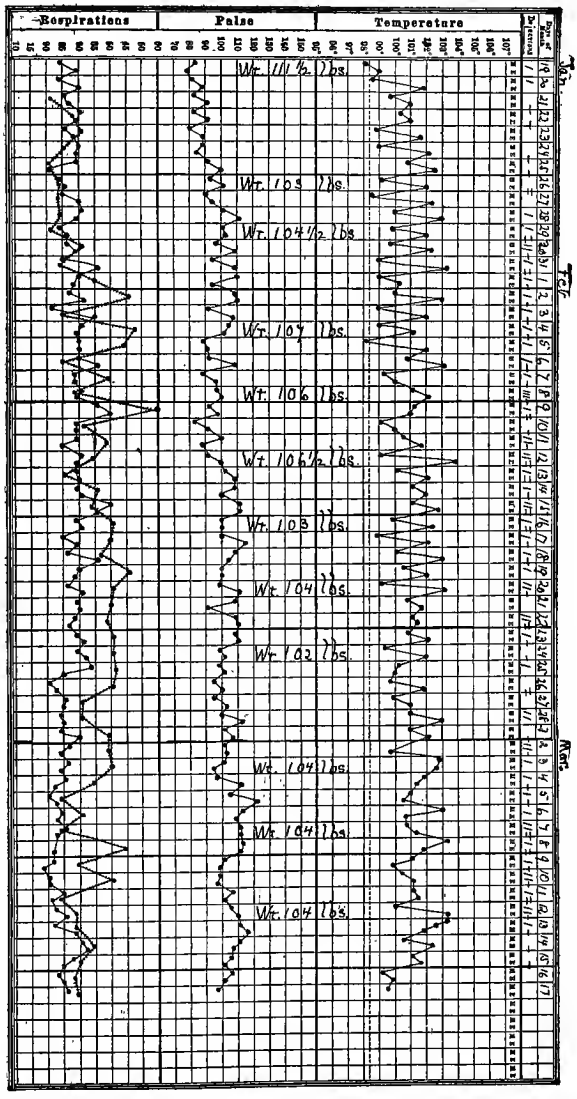

Fig. 33.—Chart I of Case 21.

operation, but continued to run a temperature between 100° and 101° F. until his discharge, August 1st.

The patient was seen February 19, 1913. He was then at work, eating ravenously, sleeping well, and free from fever. His bowels

moved three or four times daily and the movements were rarely solid. When he left the hospital he weighed 104 pounds; at this time he

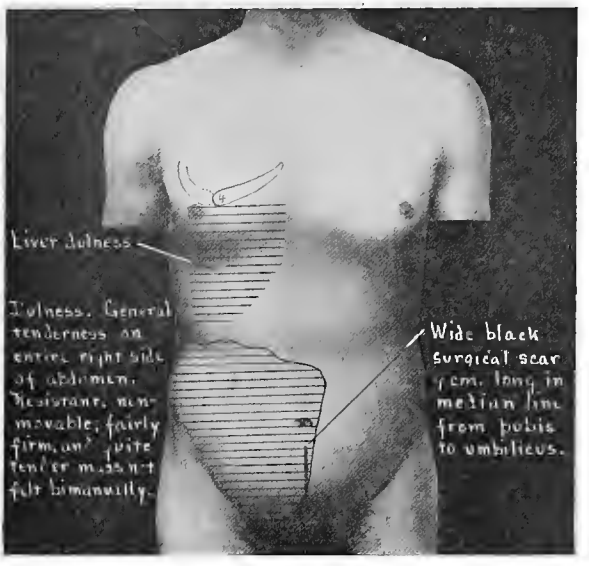
Liver dulness
Dulness. General tenderness on entire right side of abdomen. Resistant, non-movable, fairly firm, and quite tender mass not felt bimanually.
Wide black surgical scar 7 cm. long in median line from pubis to umbilicus.

Fig. 34.—Signs in Case 21, July 5, 1910

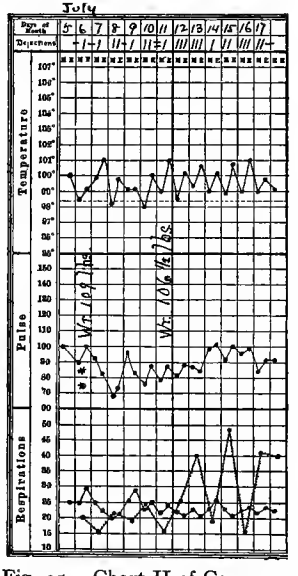

Fig. 35.—Chart II of Case 21.

weighed 120 pounds. There was still a fistulous opening at the site of the last operation.

Case 22

A farmer of fifty-seven entered the hospital January 28, 1910. The patient's mother died of tuberculosis, otherwise his family history is good. He has had indigestion for ten years, beginning sixteen years ago and ending six years ago. He denies venereal disease and has good habits.

Six months ago he began to notice soreness in the right lower quadrant of the abdomen, with occasional attacks of dyspepsia, and soon after this he felt a mass in the region of the soreness. He thinks it has grown slightly since that time. Three weeks ago he lost his appetite and for three days vomited almost everything and had more pain than usual. The vomiting grew less and ceased four days ago, since when he has felt comfortable, though weak. Bowels slightly irregular, but he now eats and sleeps fairly well. Last spring he weighed 165 pounds, with clothes; September 6th, 151 pounds, with clothes; now 129 pounds, without clothes. He stopped work three weeks ago. For some time he has had attacks of sharp pain, lasting two or three minutes, after meals, and accompanied sometimes by rumbling noises, sometimes brought on by pressure upon the abdomen. For the last three weeks he has needed laxatives to make his bowels move.

Physical examination shows fair nutrition, considerable sallow pallor, though his hemoglobin reads 90 per cent. and the stained smear is normal. Pupils, glands, and reflexes normal. Chest normal. In the right lower quadrant is a hard, nodular mass, slightly tender and movable on palpation. In the flank peristalsis is visible near it (Fig. 36). Blood and urine negative. Temperature normal for a week.

Discussion.—A mass in the region of the cecum, coming on at the age of fifty-seven, with disturbances of intestinal function, is strong presumptive evidence of malignant disease of the large intestine. In a younger person tuberculosis might produce the same symptoms, although the intestinal symptoms of pericecal tuberculosis are rarely as marked as in this case. A renal tumor might show itself in this part of the abdomen, but would hardly be associated with such marked intestinal symptoms as this patient presents.

Regarding the variety of neoplasm, we have only to distinguish between carcinoma (epithelioblastoma) and malignant lymphoma (lymphoblastoma). The latter tumor, which is ordinarily called sarcoma when met with in this site, is much less common than the

former in a patient of fifty-seven. On the whole, I think the diagnosis of cancer of the cecum is satisfactorily clear.

Outcome.—On the 5th of February the patient's abdomen was opened. A considerable amount of clear, dark yellow fluid escaped. At the ileocecal valve a large, firm, freely movable mass was found, with extensions running down into the pelvis and up toward the liver. Several loops of intestine were adherent to it. A bit was excised

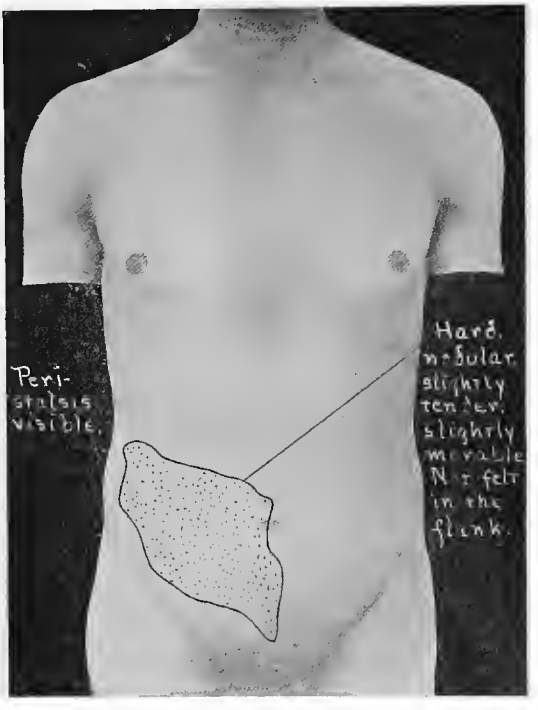

Fig. 36.—Mass felt in Case 22.

for diagnosis and the abdomen then closed. Microscopic examination by Dr. J. H. Wright showed adenocarcinoma.

The patient left the hospital February 15, 1910, and gradually failed at his home, dying March 26th. During the last months of his life he lived almost entirely on buttermilk.

Case 23

A maid of thirty entered the hospital April 4, 1910. For many years the patient has noticed tender swellings over the left clavicle and on the forehead. Four weeks ago she began to have headaches. Two weeks ago she began to get hoarse. For five days she has had

rapidly increasing dyspnea, otherwise she has had no respiratory symptoms. Her husband has had consumption for two years. Her family history and past history are negative. She has six healthy children. She is now nursing a healthy five months' baby. Eleven years ago she had a miscarriage at eight months. She has had four healthy children since.

Physical examination shows good nutrition. The right pupil is slightly irregular and is larger than the left. Both react normally. No glandular enlargement. Chest, abdomen, and reflexes negative. On each frontal eminence is a tumor about 2 cm. in diameter. On the left clavicle is a similar rounded enlargement, and on the external condyle of the left humerus is a swelling the size of an English walnut, somewhat tender. On the left leg, below and outside the knee-cap, is a fluctuant mass 5 cm. in diameter. In the middle of the left tibia is a deep dry ulcer $\frac{1}{2}$ cm. in diameter. There is forward bowing of the right tibia 8 cm. below the knee pan and the lower portion of this tibia is much thickened laterally.

The patient was greatly troubled by dyspnea at entrance and showed evidence of laryngeal stenosis. The Wassermann reaction was positive. Otherwise the blood was normal. Ten examinations of sputa for tubercle bacilli were negative, as were the feces. There was no fever.

Discussion.—Here we are dealing with a case presenting multiple fluctuant lumps. Among the possibilities are wens, fatty tumors, abscesses due to pyogenic cocci, glanders, tuberculosis, syphilis, neoplasm, and, as bare possibilities, coccidioidal granuloma, blastomycosis, and actinomycosis.

If we are to make one diagnosis covering all the functional disturbances present in this patient, we can exclude at once wens, lipomata, glanders, and pyogenic abscesses, as those cannot well be a part of any general pathologic process which produces hoarseness, bony lesions, and dyspnea. Tuberculosis, syphilis, and the other lesions mentioned might account for all the other symptoms. The family history of tuberculosis makes that especially deserving of consideration, but the site of the lesions, especially their presence on the clavicles and the changes in the tibiæ, are not at all characteristic of tuberculosis. Moreover, a tuberculosis which has produced so many external lesions is likely to have involved the lungs by this time. Against malignant disease are the patient's age and the involvement of the bones. Against syphilis we have nothing except the fact that the patient has six healthy children, and that fact, on the whole, is a much less important one

than those which have been mentioned as militating against the other diagnoses previously discussed. On the whole, syphilis seems the most probable diagnosis. Coccidioidal granuloma, blastomycosis, and actinomycosis can only be excluded by a careful examination of the discharge from the lesions, but they are all very improbable.

Outcome.—Under mercurial inunctions and potassium iodid the dyspnea rapidly improved, but on the 4th of April again became so distressing that tracheotomy was considered. After April 5th the dyspnea steadily improved and by the 14th was almost gone. The patient went home on the 19th, much relieved.

Case 24

A tailor of thirty-seven, born in Russia, entered the hospital March 2, 1910. The patient complained chiefly of pain in the left hypochondrium, with loss of appetite and fatigue on slight exertion. The pain was worse after meals, and especially bad at night, when it often woke him up. In the past six months he has lost 24 pounds and much strength. Since he was a boy he has been in the habit of passing urine one to four times in the night. Since February 5th he has been unable to work and has been in bed. Two weeks ago his physician noticed a mass in the left upper quadrant.

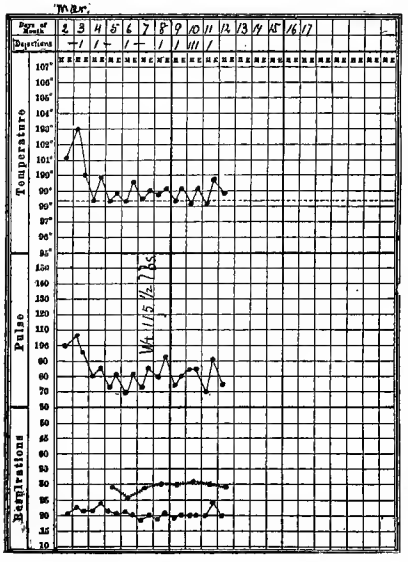

Fig. 37.—Chart I of Case 24.

For as long as he can remember he has taken three whiskies and three beers a day, but has had no previous illness. His family history is good. He has three children living and well. His wife has had no miscarriage.

On the patient's entrance to the hospital his temperature was 101.2° F., which rose the next morning to 103° F (Fig. 37). His nutrition was good, but he showed distinct pallor. Under each ear, between the mastoid process and the jaw-bone, was a smooth, tender gland. A few other flattened glands were felt in the left axilla. In both groins glands the size of large beans were felt. The

heart's apex extended 2 cm. outside the nipple line by percussion, but was never seen nor felt. Right border of dulness 2 cm. from midsternum. Pulmonic second sound seemed somewhat accentuated and there was a very soft systolic murmur at the apex. The lungs were normal. A rounded edge, apparently belonging to the spleen, was felt 7 cm. below the left ribs and could be traced into the flank. Percussion dulness extended up under the ribs so that the vertical diameter of the organ was in the vicinity of 17 cm. Its horizontal diameter was 25 cm. The red cells numbered 3,450,000; white cells, 10,700; hemoglobin, 75 per cent. Of the leukocytes, 38 per cent. were polynuclears, 44 per cent. large lymphocytes and transitional cells, 18 per cent. small lymphocytes.

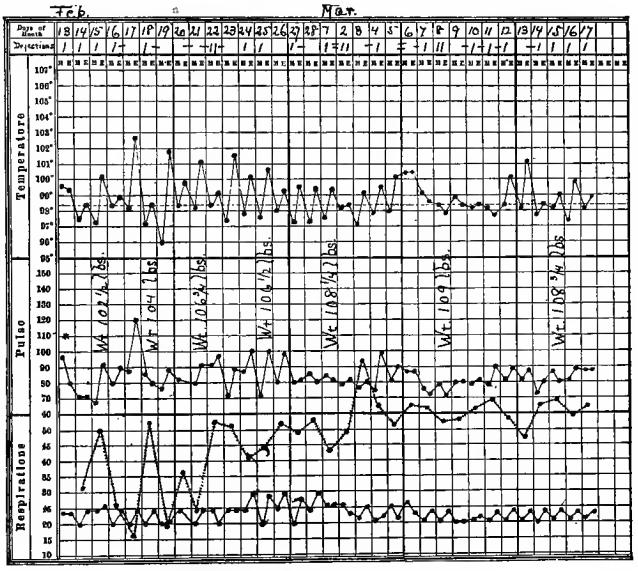

Fig. 38.—Chart II of Case 24.

On the 3d of March I noted that the mass in the splenic region was deeper and more rounded than is the rule when one palpates a large spleen. The glandular enlargement seemed to me demonstrable only in the groins. The blood-platelets numbered 122,000. The patient complained of pain in the region of the spleen. The urine averaged 30 ounces in twenty-four hours, with a specific gravity in the neighborhood of 1014. The sediment contained a small amount of pus on every examination. By the 9th of March the polynuclear cells had risen to 48 per cent.; lymphocytes were 47.9 per cent., 40 per cent. being of the large type; eosinophils made up the remainder.

The blood-platelets were 209,000. A swathe entirely relieved the complaint of pain in the region of the spleen. No medication except laxatives was given.

He left the hospital on the 12th of March and did not re-enter until a year later, February 13th; he said that he had done well all through the summer and autumn; three months ago he began to have chills followed by headaches, but, so far as he knows, by no fever. He sweats freely each night and sleeps poorly. He thinks his spleen is growing larger. It hurts him to lie on the left side.

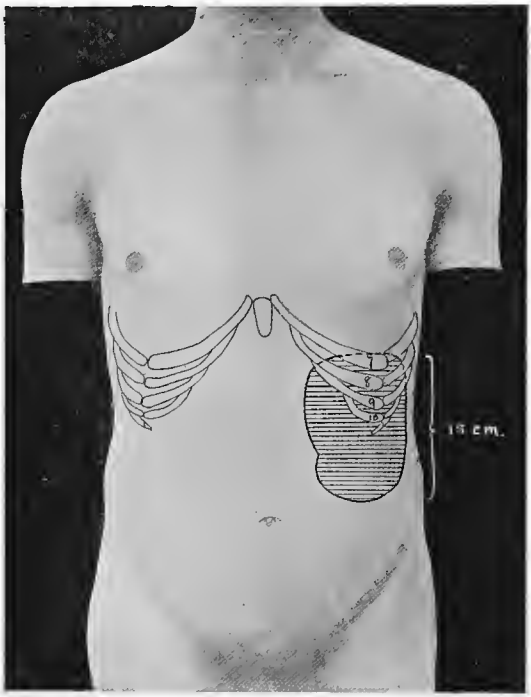

Fig. 39.—Spleen in Case 24.

He has done no work for fifteen months and has been in bed for three months. Fifteen months ago he weighed 165 pounds. He lost a good deal of weight during the time of his previous stay in the hospital; next he gained 22 pounds during last summer, but has lost rapidly in the last three months. His weight, without clothes, February 15, 1911, was 102½ pounds.

Nevertheless, he was now fairly nourished and did not look sick. His pupils were normal. The cervical lymph-nodes were not enlarged. In the right axilla there was a gland the size of an almond. The

inguinals were as large as beans. The condition of the spleen was as shown in Fig. 39, and did not appear to exceed that previously measured. The heart showed the same lesions previously noted. The knee-jerks were both reduced; in fact, they were present only on reinforcement. There was no edema. During the two months of this his second stay in the hospital his red corpuscles remained in the vicinity of 3,000,000, though they gained slightly in the last two weeks. His hemoglobin rose from 60 to 85 per cent. The course of his white corpuscles is seen in Fig. 40. The red cells showed marked achromia with some abnormal staining and stippling, also considerable variations in size and shape. About 20 per cent. of the lymphocytes were of the small type, the rest large. The patient had *x*-ray treatment every other day and improved very markedly. His temperature was elevated for the first two weeks and a half. After that it was normal. Systolic blood-pressure, 110 mm. Hg. The urine, as before, showed considerable pus in the sediment, but 20 minims of this sediment injected into a guinea-pig produced no results. The Wassermann reaction was unsatisfactory.

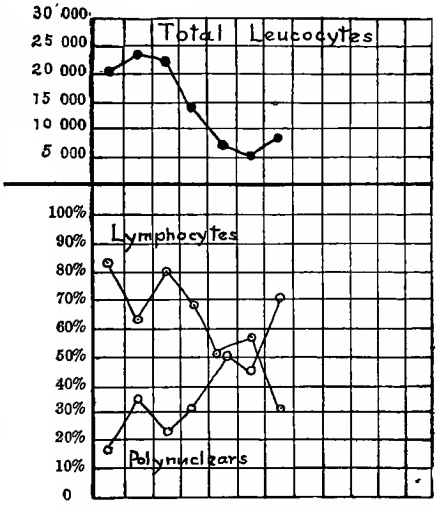

Fig. 40.—Chart of white corpuscles of Case 24.

Discussion.—The essentials of this case are a dyspepsia of long duration in an alcoholic patient, associated with emaciation and an apparently habitual nocturia. The physical examination shows especially a mass in the left hypochondrium strongly suggesting the spleen, a general glandular enlargement, and a curious blood-picture, involving an increase of lymphocytes.

There can be little doubt, I think, that the tumor is a spleen. The blood-picture is not precisely characteristic of any known disease. It is most suggestive of a transition from a non-leukemic to a leukemic form of lymphoblastoma. The case is a most interesting one, because just this transition is very rarely observed. Despite all that has been written by Bunting, Lazarus, and others, we have today no characteristic blood-picture for the greater part of the duration of the disease formerly known as Hodgkin's disease, and now more generally

known as malignant lymphoma or lymphoblastoma. The lymphocytic increase described by the writers just mentioned is not always present and the blood is often essentially normal. In the present case there is certainly an increase in the number of lymphocytes and especially in the larger varieties. This increase is hardly enough to deserve the name of leukemia, but might be called subleukemic. Without much doubt the typical leukemic blood-picture will appear later.

Outcome.—He left the hospital on the 21st of March, promising to report at the Out-patient Department.

The patient was seen in February, 1913, and said he was getting on very fairly. He had some trouble with headache and pain in the splenic region and was unable to work, but when at rest had no considerable discomforts. The blood showed practically the same picture as when last examined.

Case 25

A stationary engineer, a Swede, of forty, entered the hospital March 26, 1910. The patient's family history is good. He had a chancre without other symptoms seventeen years ago. His habits are good. Two years ago he had a slight swelling to the left of his breast bone. It varied a good deal in size, appearing and disappearing, first on one side and then on the other side of the breast bone. Nevertheless, he has considered himself well and has done his usual work until last December. During that month he was examined at the Boston Dispensary and states that nothing abnormal was found. Since that time the tumor near the breast bone has appeared again. He has had no severe pain anywhere except nagging discomfort in both arms and shoulders, not associated with exertion. For over a year he has noticed some shortness of breath on severe exertion. Otherwise he has had no symptoms.

Physical examination showed that the left pupil was larger than the right. The heart's apex extended 2 cm. outside the nipple line, the right border 5 cm. from midsternal line. The sounds were rather muffled and there was a soft systolic murmur at the apex, not transmitted. Aortic second slightly accentuated. Systolic blood-pressure, 145 mm. Hg. Over the upper part of the sternum and to the right of it was a conical swelling the size of half a lemon, tense, elastic, and pulsating in all directions. A diastolic shock was clearly felt over it. The right pulse was barely palpable; the left, of good volume, slightly increased tension. Both were regular. The blood-pressure tested in the left radial

was 30 points higher than in the right. This discrepancy slightly diminished in the next month and markedly in the succeeding month, so that at the time of his discharge, May 15th, the two pressures were practically identical. Between the spine of the right scapula and the median line was an area the size of the palm where bronchovesicular breathing and egophony were made out, but there was no dulness there. There was at no time any thrill or murmur over the mass near the sternum, and the absence of pain was quite striking.

Discussion.—Aneurysm or mediastinal tumor are practically the only conditions which deserve consideration here. Tuberculosis is altogether improbable. Against aneurysm is the absence of all pain and the absence of any palpable thrill or audible murmur. The two last signs, however, are not infrequently wanting in aneurysm.

In favor of aneurysm are the presence of a syphilitic history, the condition of the pupils, and the definite pulsation palpable over the tumor. All of these conditions might coexist with a neoplasm, but such a coincidence is improbable.

Outcome.—Hypernephroma with metastasis was considered, although the blood and urine were normal. At times the right hand was colder than the left. The Wassermann reaction was positive. On the 6th of April the tumor was about half the size it had been at entrance. Potassium iodid, 20 gr. three times a day, had been given in the interval, together with mercurial inunctions. Operation was advised, but refused; *x*-ray, taken at entrance, showed a shadow $14\frac{1}{2}$ cm. in diameter, and on the 30th of April there was no change in this shadow. Later the aneurysmal tumor increased to its former size and remained there until the time of his discharge, May 16th.

The patient died at his home March 10, 1912. During the last six months of his life he was subject to spells of choking, and it was in one of these spells that he died very suddenly.

Case 26

An ironworker of thirty-three entered the hospital August 25, 1910. Two or three years ago the patient first noticed a hard mass in the left hypochondrium. It has grown steadily since, and in the last year he has lost 15 pounds. It is only in the last six months, however, that he has felt a gradually increasing fatigue at his work as an iron molder. His appetite and sleep are good, his bowels regular, and, save for weakness, he still feels well.

Nine years ago he had a chancre and took "blood medicine" for a year thereafter under the advice of a druggist. He had no skin erup-

tion or sore throat. Four years ago he was married and has two healthy children. His wife has had no miscarriage. His habits are good. He has lived in New England practically his whole life.

Physical examination shows good nutrition, pupils slightly non-circular, but reacting normally. Lymph-nodes somewhat enlarged in the axillæ, groins, and epitrochlear region, not in the neck. At the angle of the right jaw is a pigmented scar, 3 by 5 cm. There is visible lateral pulsation in the brachial arteries and the arterial walls are palpable between beats. The chest is negative. The belly is

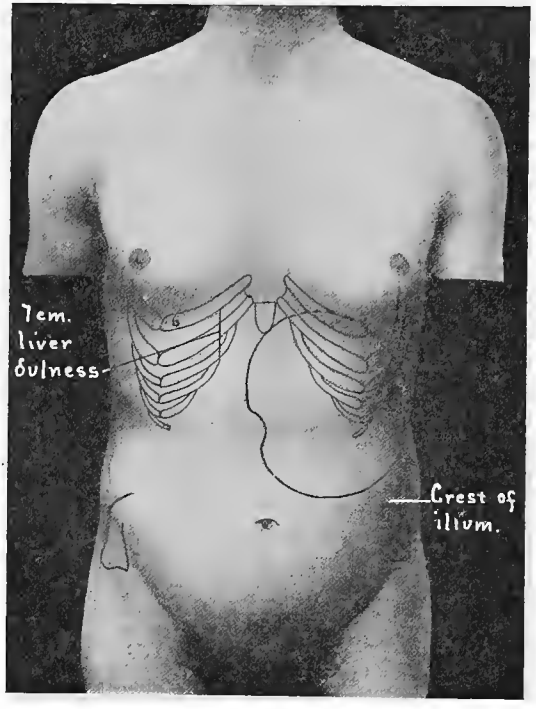

Fig. 41.—Mass felt in Case 26.

negative, except that in the left hypochondrium there is a firm, non-tender mass with a sharp edge, descending with respiration, easily felt bimanually, not traversed by the inflated colon (Fig. 41). There is a scar, with evidence of loss of substance, on the frenum. The right shin is much bowed and thickened in the upper half, but smooth.

Banti's disease, splenic anemia, syphilis, and leukemia were considered, but the blood showed no evidence of the latter disease, the white cells numbering 3600 with 56 per cent. of polynuclears, 1 per cent.

eosinophils, and the rest lymphocytes. Red cells numbered 4,000,000, hemoglobin 70 per cent., no nucleated forms. The stools showed no reaction to guaiac. Urine negative. Weight, 141 pounds at entrance; 146 pounds at discharge, two weeks later. The temperature was occasionally elevated in the afternoon, once to 99.5° F., once to 100.5° F. As a rule it was normal. Daily *x*-ray treatment to the spleen had no considerable effect upon its size. On the 1st of September a high-pitched inspiration and a few crackling râles were heard below the right clavicle, and in the right back, near the angle of the scapula, inspiration was also somewhat high pitched. The fundus oculi was normal.

Discussion.—In summary, this patient presents an enlarged spleen, a general glandular enlargement, a scar on the frenum, a slight degree of secondary anemia, and a thickening of the right shin-bone. Syphilis is the only disease that easily accounts for all these facts, although malaria is much commoner than syphilis as a cause of splenic enlargement. This patient certainly had no acute or present malarial affections and, in view of his residence, there is no probability of any chronic malaria or any tropical disease such as might cause enlargement of the spleen.

Lymphoblastoma (Hodgkin's disease) produces just such a spleen and such a simple adenitis, but would not account for the scar on the frenum nor for the changes in the shin.

Banti's disease and splenic anemia cannot be excluded, but these are diagnoses which should never be made unless syphilis can, with all reasonable probability, be excluded, and such exclusion is certainly not yet possible here.

Against syphilis we have no evidence except the healthiness of the patient's children. This cannot be considered evidence of any importance. The bunch of râles and the changes in respiration noticed on September 1st lead us to speculate as to whether tuberculosis may not cause some, if not all, of his symptoms. These pulmonary signs, however, were not constant and it was impossible to lay much stress upon them.

Outcome.—The patient did well under antisyphilitic treatment and left the hospital on the 10th of September.

Case 27

A porter of thirty-eight entered the hospital November 7, 1910. The patient was in the New York City Hospital two years ago for swelling and pain in his ankles. He had chancre fourteen years ago,

after which he doctored for two or three months, but took no inunctions. Ten years ago his hair gradually fell out. Five years ago there were red spots on his hands and over his body; these lesions soon disappeared when he took mercury to the point of salivation. He has been married two years. His wife has had no children and no miscarriage. He takes a pint of whisky a week.

For about one year he has had frequent headaches, which are unusual for him. They are bilateral or frontal, and confined mostly to

Fig. 42.—Lump described in Case 27.

the afternoon and evening. He uses his eyes a good deal and has had no examination of them. Later, in September, 1910, for the first time in his life, he had a fit just when leaving his shop at the end of the day. He fell unconscious and remained so for ten minutes, nearly or quite motionless. After resting fifteen minutes he seemed to be as well as usual, but since then has had four similar attacks, the last one today at noon. Though he is always conscious of the immediate approach of the seizure, he has never been quick enough to lie down before he fell, and has bruised himself several times. He has never bitten his tongue or passed urine during an attack.

Three weeks ago he first noticed a lump on his breast bone. It has rapidly increased in size since then and has become tender. His appetite, digestion, and sleep are good and he feels well in most respects.

Physical examination shows good nutrition. The right pupil is greater than the left, irregular in shape, and does not react either to light or distance. The left pupil reacts slightly to distance, not at all to light. The lymph-glands are enlarged in the neck and groins. Knee-jerks and plantars are normal. The heart and lungs negative, likewise the abdomen. There is a large scar on the frenum with a considerable area of erosion. The skull is smooth. The right shin shows thickening and elevation in the lower third. In the region shown in Fig. 42 is a rounded eminence, 1½ cm. in height, slightly painful on palpation, showing no thrill or pulsation. Percussion over it is resonant.

On the night of entrance he had a convulsion lasting three minutes.

Discussion.—Such a lump upon the sternum might be due to tuberculosis, to a neoplasm, to aneurysm or gumma, but the rest of the patient's history should incline our judgment strongly in favor of one of these alternatives and against the rest. The condition of the pupils, of the glands, of the shin-bone, when taken in connection with the sudden onset of headaches and fits and with the syphilitic history, makes it obligatory that we should exclude syphilis by the therapeutic tests before seriously considering any other disease. If syphilis is the underlying disease, the tumor is, in all probability, a gumma, since there is no other evidence of aneurysm.

The headaches and fits may be the result of an early dementia paralytica or of a syphilitic meningitis. Between these two possibilities one could decide only by a study of the patient's mental condition and by the subsequent course of the case.

Outcome.—The next day 6 mg. of "606" was given intramuscularly. This produced great pain and no demonstrable change in the tumor. Wassermann reaction was positive. He left the hospital on November 15th.

Case 28

A man of thirty-two, a manufacturer of *x*-ray apparatus, entered the hospital November 16, 1910. The patient came for treatment for swelling over the right eye. His general health has been ordinarily good. He had typhoid fever at twelve years and has been subject to

nasal catarrh for many years. He had all the evidences of syphilis fourteen years ago and was treated with mercury for a year or more. He uses whisky occasionally to excess. Early in September, 1910, he suddenly fell unconscious and remained so for an hour. Afterward he felt dazed and vomited twice in the evening, but walked a mile and a half to his train without help. Next day he had in the right half of the forehead a severe pain, which has continued ever since, though less in intensity. He got no relief from hot-water bag or cracked ice. His eyesight was excellent. Since his first unconscious attack he has had several other attacks at intervals of several weeks. In the latter part of September a swelling appeared above the right eyebrow. It gradually increased in size and became tender. As the swelling increased the headache lessened in intensity, but for the past two days it has again become aggravated. At the onset of these troubles the patient was working very hard and sleeping very little. His appetite was also poor and he lost about 20 pounds, which he has since regained. He now eats ravenously.

On physical examination the man did not look sick and was well nourished. The right pupil was greater than the left and was irregular in outline. Both reacted normally. Glands and reflexes not abnormal. Aortic second sound not accentuated. Systolic blood-pressure, 145 mm. Hg. Chest and abdomen otherwise normal. There was a scar on the frenum and the right epididymis was slightly thickened and nodular. His shins were smooth, but showed depressed and pigmented scars. Over the right eyebrow was a soft oval tumor, about 1 by 2 inches. It was tender and fluctuant throughout. The bone about the periphery of the tumor was roughened and raised.

Discussion.—Summarizing the patient's history, we have here evidence of a syphilitic infection, followed fourteen years later by headaches, fits, and a swelling over the right eye. Physical examination shows abnormal pupils, a scar on the frenum, a thickening of the epididymis, scars on the shins, and a soft tumor on the frontal bone. Taken together, all of this evidence points very strongly toward the diagnosis of syphilitic gumma.

The scars on the shins are very possibly due to trauma or to varicose ulcers. We should be very careful not to attribute syphilis to any patient merely or largely on the evidence of shin scars. I do not believe there are any characteristic peculiarities by which we can distinguish shin scars of syphilis from those produced by the other causes just named.

Outcome.—He was given "606" November 16th, and within sixteen hours the tumor had decreased two-thirds in size and lost its tenderness. On the 21st about 1 ounce of pus was discharged from one nostril. It contained, apparently, no spirochetes. On this date the frontal tumor was apparently gone. The patient gained 4 pounds, and was discharged on the 23d.

Case 29

An Italian housewife of forty-two entered the hospital March 31, 1911. The patient's father died at fifty-seven of "abscess near the heart." One brother died of cancer of the intestines. One sister died of shock. Three brothers and one sister are living and well. No other cancer in the family except that noted. The patient has been married eight years, has two living children, and has had two miscarriages.

The patient's general health has never been very good. At nine she had ulcerations of the cornea, which healed at fifteen, and she has been troubled with her eyesight at intervals ever since. At twenty-three she had another illness characterized by vomiting, diarrhea, and fainting spells. She has had loose movements of the bowels at times ever since. She has had frequent attacks of tonsillitis. Her tonsils were removed two years ago, the operation being followed by a severe attack of bronchitis.

For twelve years she has been troubled with eructations of gas and sharp epigastric pain occurring about an hour after meals, sometimes associated with vomiting. She has never vomited blood. This trouble is benefited by liquid and other soft diet. There is no relief from soda. Since Christmas she has had severe intermittent headache, especially when tired, not associated with vomiting. This headache has been better for the past month since she has been dieting and resting. Her appetite is good, her bowels move daily. She has done her usual housework until two weeks ago. Up to seven years ago she worked as a seamstress.

Five years ago she first noticed a mass in the epigastrium, and since then she has observed a slow increase in its size. There is no pain associated with it except when she is indiscreet in her diet, but she says that all her life she has been bothered by pain in the left ovary. She thinks in the course of the last two years she has lost 10 or 12 pounds in weight.

Physical examination shows good nutrition, a garrulous, nervous patient. Pupils, glands, and reflexes normal. Chest negative except

for a soft, blowing, systolic murmur over the whole precordia, best heard at the apex. The right kidney is felt with ease. Reaching across the epigastrium in the region shown in Fig. 43 is a hard, irregular, very movable tumor, free from tenderness, about 5 cm. above the navel. There is also tenderness in the left ovarian region. Blood-pressure, 115 mm. Hg. Weight, without clothes, 121 pounds at entrance; 122½ pounds two weeks later. Blood and urine negative. Fundus oculi negative. Two examinations of the stools were made, one showing a negative guaiac reaction, the other a positive reaction.

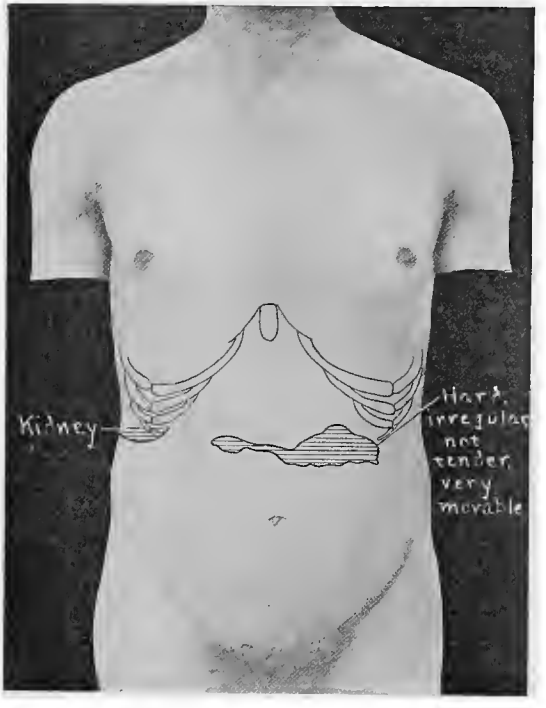

Fig. 43.—Mass felt in Case 29.

The gastric secretions are normal. The stomach was inflated and found to be in normal position and apparently above the tumor, which seems to be attached to the greater curvature. The colon seems to have no connection with the tumor.

Discussion.—What were the nature of the illnesses which this patient had at fifteen and at twenty-three? I can form no reasonable conjecture. We learn only that she has had a tendency to bowel trouble, and that for the past twelve years she has been having a dyspepsia which does not correspond symptomatically to any single,

well-marked clinical type. That is, it is not strikingly characteristic of gastric cancer, gastric ulcer, or any other clinical entity. The most notable fact in the case is the presence of the epigastric mass which the patient has noticed for five years. Such a combination of facts is very unusual. A mass noticed in this situation for a few months or even for a year is common enough, but slow-growing tumors are very rarely found in the epigastrium. Those connected with the pancreas and with the abdominal wall are almost the only exceptions to this statement. We have no right to say that cancer of the stomach cannot exist for five years and produce such a tumor as is here described, but certainly such a history is very rare, especially as the patient has lost only 10 or 12 pounds, and those in the last two years.

It is quite possible, however, that the tumor which she has felt (assuming that her statement is correct) was originally a perigastric exudate, originating in a peptic ulcer which later became cancerous. Pathologists are sharply divided on the question whether or not peptic ulcer often becomes cancerous, and no authoritative solution of the question can be given at the present time.

Lesions originating in the pancreas or in the abdominal wall can be ruled out in this case: the first, because the tumor is very movable; the second, because it was demonstrably unconnected with the abdominal wall. Under these conditions gastric cancer seems the most probable diagnosis, despite the prolonged history, despite the absence of emaciation, and the negative results of gastric examination. I regret that no bismuth *x*-ray test was made in this case.

Outcome.—April 15th the abdomen was opened, and immediately below the epigastric incision, which was in the median line, there presented an elongated mass of hard, fused glands which were situated in the omentum, along the greater curvature of the stomach, which region was also itself infiltrated with neoplastic tissue. Large hard glands were also felt around the pylorus. The pylorus was free and there was no infiltration for a distance of 2 inches above it. The flanks and pelvis were normal. No operation was done. The patient promptly recovered and left the hospital on the 23d.

She lived until March 9, 1912, dying gradually from exhaustion.

Case 30

A farmer of forty, an Italian, entered the hospital April 14, 1911. The patient's family and past history show nothing of interest. He had felt perfectly well until January, 1911, when he began to have

epigastric pain which has persisted since and is increased by food. Six weeks ago he noticed a lump and pain above his left clavicle. For several weeks he has taken only liquids. He never vomits. His weight in November was 145 pounds, with clothes; now, 104½ pounds, without clothes.

Physical examination shows obvious loss of weight, though the patient cannot be said to be emaciated. The pupils react sluggishly to light, normally to distance. Over the left clavicle is a mass the size of a chestnut, hard, freely movable, not tender. No other

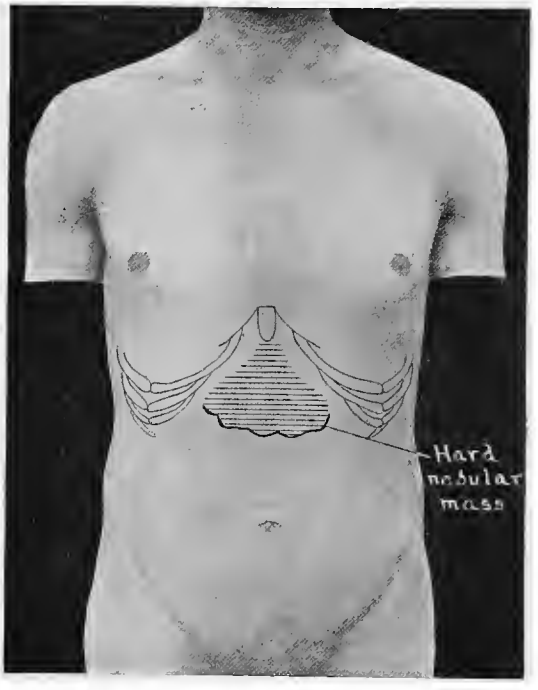

Fig. 44.—Mass felt in Case 30.

evidence of glandular enlargement. The chest is negative, save for a few groaning râles at the right apex. Abdomen shows a hard, nodular mass in the epigastrium (Fig. 44). This mass moves freely with respiration and fades out into an indefinite resistance which disappears below the costal margin. Only its lower edge is distinctly felt. The knee-jerks and Achilles' jerks are not obtained, even on reinforcement. There is slight edema along the shins. Blood and urine negative.

The patient's temperature during the first week in the hospital

rose to 99.5° F. every evening except two, when it went to 100° and to 100.5° F. During the second week of his stay the temperature was normal. Blood-pressure, 105 mm. Hg. at entrance; 130 mm. Hg. ten days later. The stomach-tube showed no food in the fasting stomach, and after a test-meal the stomach contained no hydrochloric acid and the wash-water was positive to guaiac. There were no sarcinæ.

Discussion.—The essential points in this case are:

First, A history of three months' dyspnea with loss of weight and with masses in the epigastrium.

Second, A painful lump noticed for six weeks over his left collar-bone.

Third, An Argyll-Robertson pupil and an absence of knee-jerks.

Fourth, A slight fever.

Tabes should be our first thought when a patient with such pupils and reflexes as this patient presents complains of *any* sort of abdominal discomfort. The mass over the clavicle might quite conceivably represent a syphilitic adenitis, and the mass in the epigastrium the edge of a syphilitic liver. This diagnosis is all the more probable because of a slight fever. It is to be regretted that no Wassermann test was done in this case. Certainly syphilis cannot be excluded without such a test and without trying the effects of antisyphilitic treatment.

Gastric cancer might well account for the mass in the epigastrium and, by metastasis, for the lump above the clavicle. The stomach symptoms arising suddenly in a patient who has never had stomach trouble before and who is now forty years old, certainly suggest cancer, but cancer will not account for the condition of the pupils and reflexes, and if we decide to call the case one of cancer we must also make a diagnosis of early tabes dorsalis as a separate malady.

Tuberculous peritonitis is suggested by the presence of fever and by the patient's race, since this disease is especially common among the Italians in Boston and its vicinity. The mass in the epigastrium might represent the rolled-up omentum, which is not uncommon in tuberculous peritonitis. It is unusual, however, to see the disease in a patient of this age. Most of the cases of tuberculous peritonitis in Italians appear in children or, at any rate, before the thirtieth year.

Cirrhosis of the liver would produce just such a mass and would account for the patient's stomach symptoms. It is not common in the Italian immigrants, as one sees them in New England, but this is not nearly sufficient to exclude the disease. The lack of any enlarge-

ment of the spleen is the most important consideration against cirrhosis.

The four possibilities just mentioned seem to me all that need to be seriously considered. Were the urine not normal, one might need to consider a uremic type of stomach trouble, such as often appears in the arteriosclerotic variety of chronic nephritis and less often in the chronic glomerular forms.

All things considered, gastric cancer with tabes seemed, to those who saw this patient in the hospital, the most probable diagnosis.

Outcome.—Under cocain the supraclavicular gland was removed. Examination by Dr. J. H. Wright showed metastatic adenocarcinoma. The patient's epigastric pain was so great that he needed morphin from time to time and his bowels could only be moved by strong cathartics. He left the hospital on the 29th, having lost 2 pounds during his stay.

Case 31

An engraver of fifty-seven, born in Turkey, entered the hospital May 23, 1911. He complained of lumps upon his skull and in his abdomen. He says his father died because he was not fed enough by his wife, who was too stingy. The lady in question is living and well, as are two brothers. The patient has four healthy children and his wife has had no miscarriages. He has never been sick before, has excellent habits, and denies venereal disease. The patient says he is in perfect health, and only on this understanding furnishes us the following facts: He has always been much interested in astronomy and has ideas about the creation of the universe. These he regards as of highest importance, and the responsibility of these ideas, combined with his exhausting occupation as an engraver, has much to do, he thinks, with his present condition. Two years ago, while working night and day (as he had to engrave both for the day and the night editions of his paper), he noticed some lumps upon his head, and at his doctor's advice took a trip to Turkey. This was in the fall of 1909, and after it all the lumps disappeared and he busied himself in explaining to his bewildered countrymen that Halley's comet would miss the earth by some 80,000,000 miles. When the comet verified this prediction, he returned to this country and took up his work in the fall of 1910. At this time another group of lumps appeared. They have grown but little since their appearance, and, except for one behind the left ear, are not tender. He has no actual pain, though the discomfort asso-

ciated with the lumps is worse if he gets hungry. His appetite, he says, requires attention, but, if properly cared for, is excellent. Tender steak and rice pudding are his mainstays. More vulgar foods are promptly and painlessly ejected, especially if he sings too soon after eating. He has lost no weight. He usually weighs 155 pounds. His bowels are regular. He sleeps well and declares emphatically that he is well.

Physical examination shows good nutrition and excellent facial color. Scattered over the scalp are many low, firm, painless, rounded elevations, about 4 cm. in diameter, not sharply circumscribed, not attached to the skin, but firmly adherent to the parts beneath them. There is slight tenderness over the left mastoid. Pupils, lymph-nodes, and reflexes negative. Chest negative save for a late, blowing systolic murmur, best heard at the apex. The abdomen shows shifting dulness in the flanks. The liver dulness extends from the fifth rib, nipple line, to a point 7 cm. below the ribs, where a smooth, rounded, insensitive edge is felt. The spleen is considerably enlarged by percussion and its smooth edge is felt 12 cm. below the ribs. The shaft of the right humerus, near its lower end, of each ulna near its lower end, and of the femur near its upper end, show some enlargement. The *x*-ray shows marked increase in the density of the skull and of the affected long bones, with much roughening of the periosteum, but no rarefaction. Wassermann reaction was strongly positive. Blood and urine negative. Systolic blood-pressure 150 mm. Hg. No fever in three days' observation. Weight, 135 pounds.

Two members of the staff considered the disease osteitis deformans. Dr. J. H. Wright considered all the lesions, both in the spleen, liver, and bones, due to syphilis. The late Dr. R. H. Fitz thought hypertrophy of the liver and spleen quite independent. The latter represented to him the chronic splenic tumor of the Levantine races. He expressed no opinion as between osteitis deformans and syphilis. The patient would stay in the hospital but a short time, as he felt so well. He was given iodid of potash, 15 gr. three times a day, and allowed to leave on the 19th.

Discussion.—The positive findings in this case are an ascites, with enlargement of liver and spleen, lesions involving several bones and a number of subcutaneous areas, and a positive Wassermann reaction. Enlargement of the spleen is very common in Turks, Syrians, and Levantines generally, but enlargement of the liver does not usually go with it and requires some other explanation.

Syphilis is the only diagnosis which can explain all the facts.

The patient would not consent to the excision of a subcutaneous nodule. Without this, no further certainty could be arrived at.

As regards the mental symptoms, one should be careful and hesitate seriously before attributing such unusual ideas as this patient exhibits to mental disease. In the average American, such ideas would probably be abnormal, but we should be slow to put our local stamp upon all other nations or to interpret their imaginative flights in terms of our own literal-minded habits.

Syphilis, then, is the most reasonable hypothesis on which to base treatment. It should be observed that this patient did not receive antisyphilitic treatment while in the hospital.

Outcome.—The patient returned to Turkey June, 1911, and died there in October of the same year. Headache was his chief complaint. The bones of his forehead and wrists are stated to have been swollen, but caused no suffering. He died quietly, without pain.

Case 32

A housewife of thirty-eight entered the hospital July 2, 1910. The patient's mother died of Bright's disease and one sister of tuberculosis of the bowels. Otherwise the family history is good. The patient herself was always well until her marriage. Her first pregnancy ended in a miscarriage at seven months. Eight years ago she had times of being very weak and pale. Five years ago she did not menstruate for eleven months. Three years ago she had some hard bunches, the size of half a hen's egg, tender and painful, upon her arms and legs and on her head. These grew slowly and disappeared slowly. While they were enlarging they were exceedingly painful. Several times before and since this they have come and gone, but have never been as severe as they were three years ago. They were never red or discolored. The positions of the lesions, as described, are shown in Figs. 45, 46.

Through the spring of this year she has been troubled by general weakness and tiredness and sometimes has felt too weak to walk. From time to time she has had sudden attacks of sharp pain in the right side of the abdomen, radiating to the groin, and followed by soreness between the attacks. She never has them when she stays in bed. She has never had jaundice, vomiting, or urinary symptoms in connection with these attacks, and has done her housework for five people until recently. She used to weigh 114 pounds, with her clothes; now 81 pounds, without clothes.

Physical examination showed poor nutrition, a waxen skin, pale

lips. Pupils and reflexes normal. There were a few small glands in the neck, many in the axillæ and groins, of the size of peas. Chest negative save for a few fine crackles at the left base. The arterial walls were apparently thickened. The abdomen was negative. The tip of each kidney was palpable. Wassermann reaction

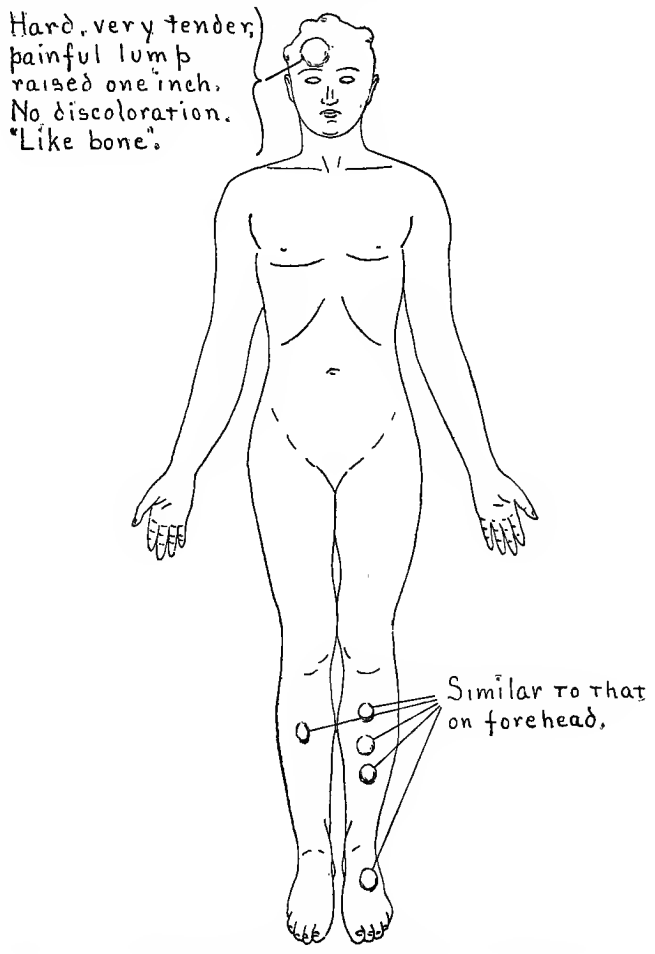

Fig. 45.—Diagram of described lesions existing over a period of a year or more, three years ago.

negative. Urine averaged 60 ounces in twenty-four hours, with a specific gravity of 1010 to 1014, no albumin, no sugar. No fever in a month's observation. Blood-pressure, 120 mm. Hg., systolic. Red cells on three examinations ranged in the vicinity of 3,800,000; hemoglobin, 65 per cent.; leukocytes, 5000 to 7000. Differential count,

normal. Slight achromia and deformities of the reds. Of ten examinations of the feces, two showed a slight reaction to guaiac. The cause of her anemia and other symptoms remained obscure. Skin tuberculin test was positive; *x*-ray showed slight thickening of the cortical bone on the anterior surface of the right tibia.

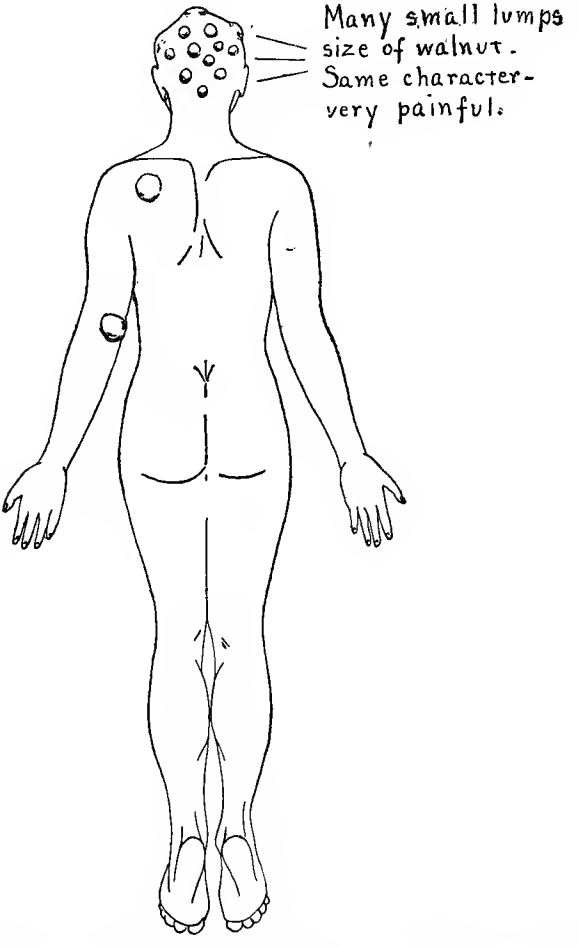

Fig. 46.—Diagram of described lesions existing over a period of a year or more, three years ago.

Discussion.—This patient, suffering from anemia, emaciation, an abdominal pain of the type often associated with renal colic, gives a history of small, tender bunches, which have appeared and disappeared in various parts of her body. Examination of the abdomen is negative and there is no Wassermann reaction. The latter test threw

us disastrously off the track at the time of this patient's first entrance to the hospital. Such symptoms as she had had, when associated with the *x*-ray findings in the right tibia, should have led us to push antisyphilitic treatment, whatever the blood showed. I am sure that we are often lead astray in this way by negative Wassermann reactions, which are, of course, nothing like so significant and so important, as guides to action, as positive reactions.

The positive tuberculin reaction, in the absence of fever and in a woman of her age, was, of course, a matter of no importance.

At the time of her second entry the Wassermann reaction had become strongly positive, and the mental symptoms, presumably of syphilitic meningitis, made the diagnosis unusually clear. The promptness and thoroughness of her recovery under antisyphilitic treatment is only what we have a right to expect in cases of this type.

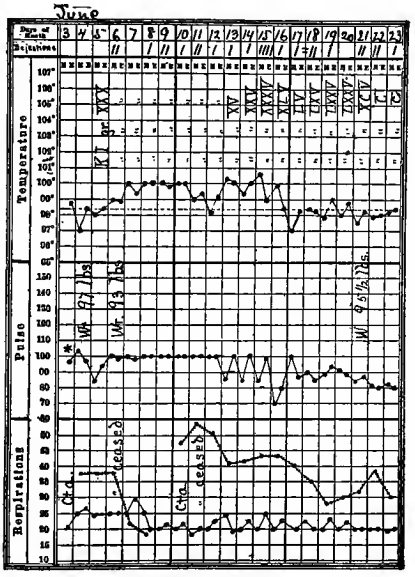

Fig. 47.—Chart of Case 32.

Outcome.—The patient had an operation done for double femoral hernia, after which she left the hospital, August 10th. She returned June 3, 1911, having taken up her housework immediately on her discharge and continued it as best she could ever since, though with great exhaustion. For the past month she has had to lie down part of each day. Nevertheless, in October, 1910, her weight reached 128 pounds. Since then it has markedly failed. All winter she has had hard, tender lumps upon her head which have changed lately in size. She has slept very poorly for some weeks.

Physical examination shows a thin, exhausted woman, with loose, dry skin, and marked pallor. Over the left eye are two elevated, rounded areas, about 4 cm. in diameter, covered by very tense skin, tender, hard, not fluctuant. Near the right ear are two more, about the same size. The pupils are not circular, but react normally. There seems to be a general thickening of the left humerus. Chest and abdomen negative. No edema. Red cells, 4,000,000; hemo-

globin, 85 per cent. The course of the temperature is shown in Fig. 47. Wassermann reaction now strongly positive. Urine negative. Her husband states that she has been very irrational and restless at night for some days before entrance, and this state continued and was aggravated, so that by the 10th of June she was delirious most of the time, carrying on conversations with imaginary persons and constantly trying to get out of bed; *x*-ray showed typical syphilitic changes in the skull and other bones. On the 20th she had become rational again, but could not remember being brought to the hospital or anything during the first week of her stay there. The patient is a nurse, and there is reason to believe the infection was acquired in the performance of her professional duties. The amount of iodid of potash administered is indicated upon the chart. By the 24th of June she seemed to be in very good condition and was discharged.

The patient was seen in January, 1913, and reported that she had had various ups and downs since leaving the hospital eighteen months previously. The periostitis upon the forehead had bothered her off and on, especially at the time of the menstrual period, and there had been swellings upon the arms and legs. Her general health had been fair. She had had no salvarsan.

Case 33

A Swedish housewife of thirty-four entered the hospital April 27, 1911. One of the patient's sisters "died at thirty-four of an enlarged spleen." This is now precisely the patient's age. There are no other known cases of enlarged spleen in the family and no other points of interest in the family history. When seventeen the patient had a severe attack of pain in the region of the gall-bladder and was jaundiced at that time; she thinks she has been yellow at varying intervals since. The patient has had no menstruation for the past four months. She suspects pregnancy. She has known that she had a large spleen since she was twelve years old. The lump gradually grew until the patient was nineteen, but not since that time. She has never had any pain or any other symptoms with it. At the present time her only symptoms are weakness and loss of weight. She has an excellent appetite and worked until yesterday. There has been no morning vomiting.

Physical examination showed a well-nourished patient, very pale, and with a yellowish cast. The scleræ showed jaundice. Pupils, reflexes, and glands normal. No unusual pigmentation of the breasts. Harsh systolic murmur at the base of the heart, transmitted to the

apex and axilla. Pulmonic second sound slightly accentuated. No evidence of cardiac enlargement. Pulses and arteries not remarkable. Lungs negative.

The abdomen was distinctly distended below the navel, especially on the right side. The edge of the spleen extended 5 cm. below the navel and a notch was felt on its median border. There was no tenderness. On the right lower quadrant deep palpation outlined a rounded resistance, dull on percussion (Fig. 48).

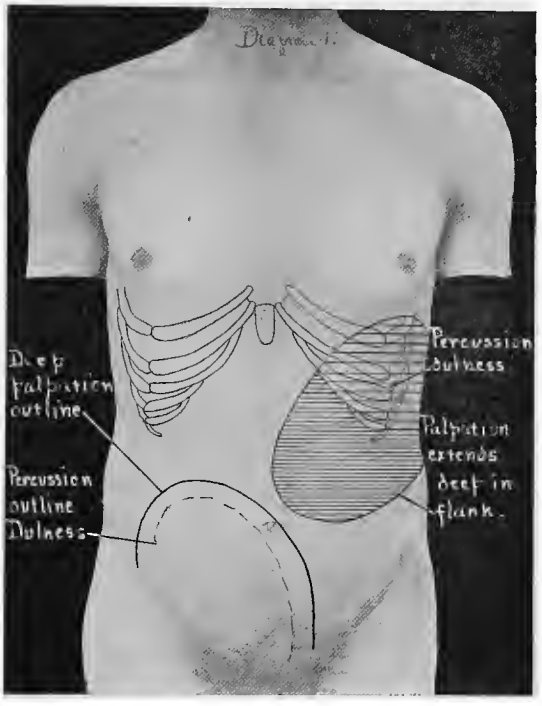

Fig. 48.—Signs in Case 33, April 27, 1911.

The uterus appeared to be symmetrically enlarged and about the size of an orange. Blood-pressure, 115 mm. Hg.; urine negative. Blood as described below. Stools always negative to guaiac. Urine negative. No bile. Wassermann reaction negative. After purgation the mass on the right side seemed larger, more movable, and quite distinct from the fundus uteri. The mass felt cystic to the examining hand. The cervix uteri was normal and there were no concomitant evidences of pregnancy. During two months' observation temperature, pulse, and respiration remained normal. The patient gained 3 pounds. There was no change in the size of the uterus. She left

the hospital June 14th and returned July 10th. There had been then no considerable change in her condition and no menstruation. Fetal movements could now be felt and there was a placental souffle in the right lower quadrant. The fetal heart was not heard. Secretion was expressed from the enlarged breasts. The cervix was slightly elongated and softened.

At this time she remembered that one maternal aunt was always very pale, but not yellow, and died in middle age of heart trouble and chronic cough. She stated that she herself was very pale before

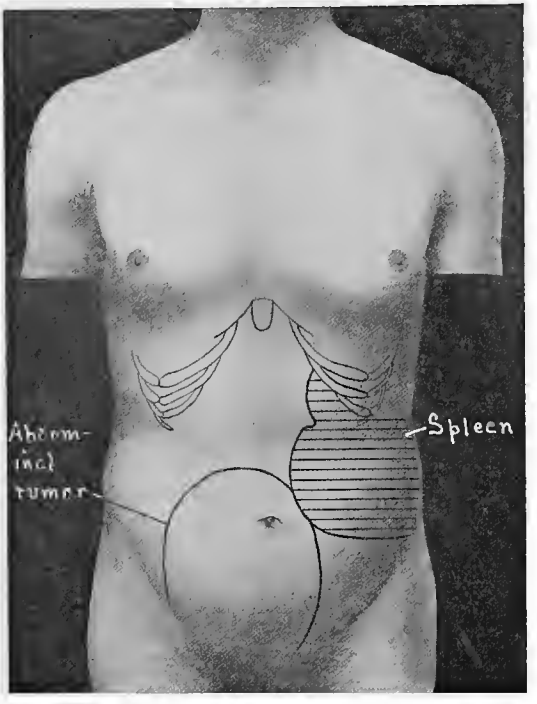

Fig. 49.—Condition of patient July 10, 1911.

the appearance of the splenic enlargement, but did not become yellow until that time. She has noticed no change in the color of the stools and has had no severe attacks of diarrhea. She is never unduly somnolent, and has had no articular pains and no very definite stomach symptoms. She has had some indigestion brought on by strong emotion or by worry, and she thinks that at such times her yellowness becomes more pronounced.

Slight edema of the legs was noticed at this time. The number of red corpuscles ranged close to 2,000,000, for the three weeks of her

stay in the hospital; hemoglobin about 60 per cent., leukocytes 6000. Smear showed slight achromia, many large well-stained red cells, slight variations in shape, considerable variations in size, many stippled and abnormally stained cells. On the 29th of July four normoblasts and one megaloblast were seen. The condition of the abdomen July 10th is shown in Fig. 49. The red cells showed increased fragility, in that hemolysis began in the patient's blood when a $\frac{5}{10}$ per cent. saline solution was added. She left the hospital August 2d.

This patient's sister was persuaded to enter the hospital for observation. Her spleen was also considerably enlarged (Fig. 50).

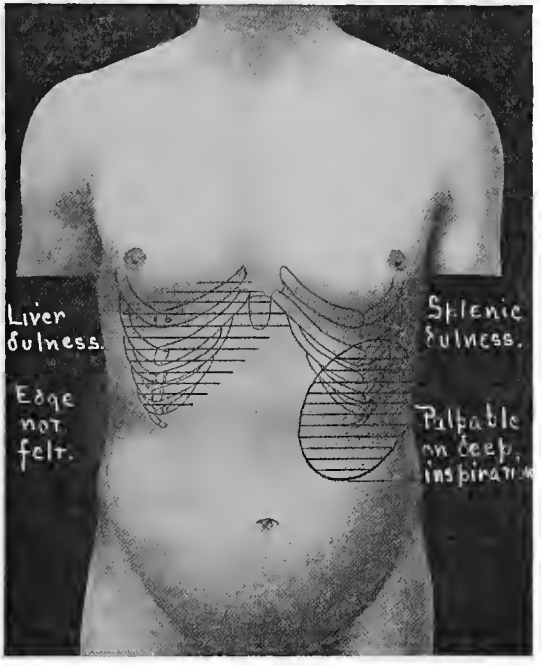

Fig. 50.—Signs in patient's sister.

Red cells, 3,300,000; white cells, 7000; hemoglobin, 65 per cent. Smear practically the same as her sister's. The reds showed increased fragility. Wassermann reaction negative. Urine negative. This patient has been yellow since twenty, but has always been up to her work. Her present age is thirty-six and she complains of nothing. The spleen extended from the eighth rib, midaxillary line, to a point 4 cm. below the ribs.

Discussion.—Clearly, the abdominal tumor present in this case

represents an enlarged spleen associated with that ill-defined but most interesting disease variously known as family jaundice, congenital jaundice, acholuric jaundice, hemolytic jaundice, etc. Doubtless some cases of this type merge into those called by that equally vague term, Banti's disease (splenic anemia), or into the Hanot type of cirrhosis. There is nothing, however, in this case to suggest any involvement of the liver, and without that none of the diagnoses just mentioned could be justified.

The chief interest in cases of this type is the very notable degree of success which has followed splenectomy in this and in all other types of anemia demonstrably associated with pathologic hemolysis and an enlarged spleen. While this operation, splenectomy, has within the past year been used quite unjustifiably in other diseases associated with anemia and with enlarged spleen, and while there is no justification for attempting it in pernicious anemia, in leukemia, or in any case of well-developed liver cirrhosis, it certainly is of great value in typical cases of splenic anemia and in some phases of the disease represented in the case just discussed.

I append here some details descriptive of the stained smears of the patient's blood at different stages of her disease:

April 27th. Smear shows considerable variation in size, but only slight variation in shape of red blood-corpuscles. No achromia, six normoblasts, no megaloblasts seen. No stippling.

May 2d. Variation in size very marked, variation in shape slight; marked polychromatophilia, with many coarse and fine stippled cells.

May 8th. Same. Blasts fewer.

May 11th. Still considerable variation in size. Variation in shape not marked, but greater than before. Stippling rare. Eleven normoblasts and one megaloblast in count of 100 cells.

May 20th. No notable change except disappearance of blasts.

June 6th. Still great variation in size, very little variation in shape, four normoblasts.

Outcome.—The patient was seen in February, 1913, eighteen months after she had left the hospital, and seemed to have improved very notably. Her weakness and anemia began to leave her about four months after her hospital experience, and from that time on she has felt pretty well and has done all the housework for a family of two. Her menstruation has been absent for the past three months. She has no pain, no cough, and an excellent appetite.

Case 34

A motorman of thirty-eight entered the hospital July 25, 1911. The patient's family history and past history show nothing of interest, though he has had constipation and indigestion for years. When constipated he has gas and epigastric heaviness after meals, his tongue is coated, and he feels tired and sleepy. When the bowels move, these symptoms disappear entirely.

For ten months he has noticed constant soreness and a tender lump in the right lower quadrant. The lump was at first soft, but

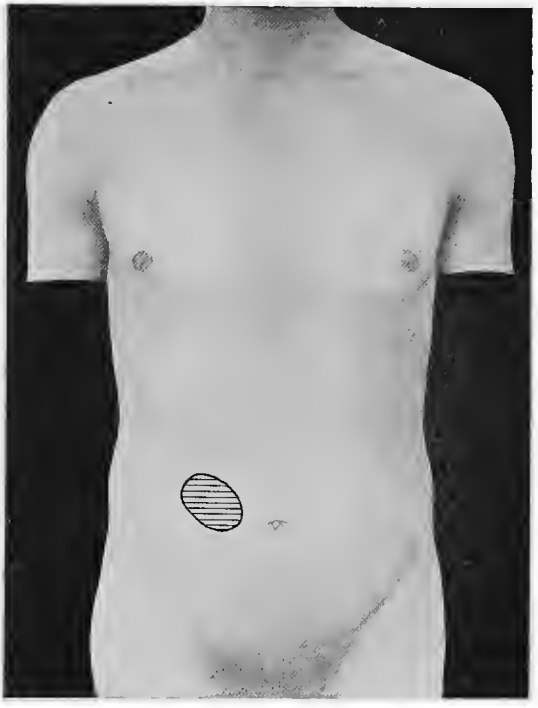

Fig. 51.—Lump felt in Case 34.

has grown harder and more easily palpable. It troubles him more when he is constipated and when he walks much, but he never has what he calls "real pain" there. Six months ago this symptom prevented his working for two weeks, and three weeks ago he was disabled during a period of hot weather. Over the whole abdomen he had severe cramp-like pains which followed the drinking of a large amount of ice-water. He thinks that the size of the lump has not increased since he first noticed it. It has always been about as large as a hen's

egg. The patient eats and sleeps well, but has chronic constipation of moderate severity.

Physical examination shows a patient who is the picture of health and is altogether negative except as concerns the abdomen (Fig. 51), where there is a mass the size of a hen's egg, somewhat tender, not moving with respiration, slightly dull on percussion. Otherwise the abdomen is also negative. The blood and urine show nothing abnormal. The patient had no temperature in three days' observation.

Discussion.—With a lump in the region of the cecum one has always to consider especially cancer of the cecum, appendix abscess, and pericecal tuberculosis. The latter disease does not often begin in a man of this age. It would also probably be associated with some fever and the palpable mass would be less sharply outlined and circumscribed.

An appendix abscess would hardly persist so long unchanged. Ten months without more variation in symptoms or signs is a very long period for an appendix abscess.

Against cancer of the bowel we have nothing except the fact that the patient is the picture of health. It seems extraordinary that a cancer which has existed as long as we have reason to believe it has in this patient should have affected the patient's general condition to so trifling an extent. This consideration led me to think that a pericecal exudate, dependent upon an inflamed appendix, was the most probable diagnosis.

Outcome.—On the 28th of July the abdomen was opened and the cecum found to be involved in a hard mass of tissue, apparently not inflammatory, but more like malignant disease. This mass extended up about 1 inch into the bowel, which was bound to the mass. The base of the appendix was apparently normal. Its tip was lost in the mass above mentioned. A bit of the tumor was excised, and when examined in frozen section seemed to be not inflammatory or tuberculous, but probably new-growth. There was no obstruction and further operation was deemed inadvisable. No further examination of the tumor is on record. The patient had an uninterrupted convalescence and left the hospital on the 14th of August.

The patient died at his own home January 26, 1913. There was no autopsy.

Case 35

A housewife of forty-three entered the hospital July 25, 1911. Her family history and past history are negative. For the past four

years she has noticed an occasional soreness in the right hypochondrium, usually at night when changing her position in bed. This motion sometimes is followed by a sharp, brief stitch.

Two years ago she had an attack of vomiting in the night, not accompanied by pain, and leaving her as well as ever after a day or two. Four weeks ago she awoke at night with nausea, but without pain, and vomited almost constantly until morning. This vomiting recurred the following night and was accompanied by fever and recurring chilly sensations. There has been no jaundice, but since the

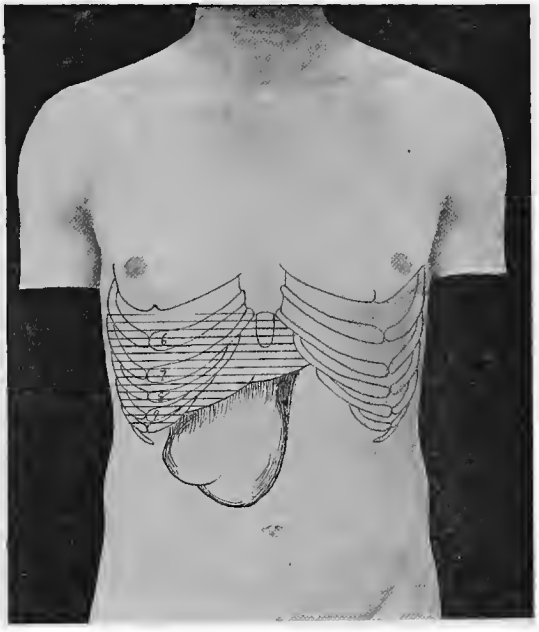

Fig. 52.—Mass felt in Case 35.

attack she has felt weak, has had no appetite, has lost 16 pounds in weight, and has become conscious of a lump in the upper right corner of the abdomen which occasionally is somewhat painful.

Physical examination shows obesity, no jaundice, pupils, glands, and reflexes normal. The chest is negative save for a soft systolic murmur, loudest at the apex, transmitted over the precordia and to the anterior axillary line. Aortic second is greater than the pulmonic second. Peripheral arteries not abnormal. Systolic blood-pressure, 135 mm. Hg. In the right upper quadrant is an irregular, smooth, rounded mass, descending with inspiration, but very slightly movable laterally. A blunt edge, apparently the liver, is felt in the flank. There

is no tenderness to speak of. The mass is dull on percussion. The upper border of liver dulness is at the sixth rib (Fig. 52). Leukocytes, 12,000; hemoglobin, 85 per cent. Urine negative. Fever during ten days' observation usually reaches 99.8° F. at night. The patient has lost 10 pounds in these ten days. No fluctuation or elasticity is detected. Bimanual transmission to the back is clear. Such pain as she has is referred to the right groin and the right iliac region. The mass is believed to be a dilated gall-bladder and the cause suspected to be cancer.

Discussion.—When a fat, middle-aged woman complains of stitch-like pain in the region of the gall-bladder, extending over a period of four years, one necessarily considers gall-stones before studying any other possibility. Some affection of the gall-bladder is made more probable by the presence of a lump, such as is shown in Fig. 52. It is an unusual and rather inexplicable feature of the case that her pain seems to be associated especially with change of position. Unusual, also, is the occurrence of attacks of nocturnal vomiting, without abdominal pain. Moreover, we do not expect a distended gall-bladder to be palpable bimanually, as an enlarged kidney is, with one hand in the lumbar region below the last rib.

Despite these unusual features, it seems to me that in diagnosis we can certainly go so far as to say that some trouble in or about the gall-bladder is the most probable solution of our problem. It remains to inquire whether we are dealing with a neoplasm, a distention of the gall-bladder from stone in the cystic duct, or with an inflammatory exudate in or about that viscus. The absence of jaundice encourages us to believe that there is no neoplasm present. The presence of fever favors an infection. Beyond this, I do not see that we have grounds for further diagnostic speculation.

Outcome.—Operation, August 5th, showed that the mass was made up largely of omentum adherent to the liver above. The liver edge extended almost as low as the navel. The adhesions between the liver and the omentum were broken through and 1½ ounces of thick pus was evacuated either from the gall-bladder or from the region immediately about it. Several stones, the size of filberts, were found in the gall-bladder and in two crypts in the gall-bladder walls, as though ulceration had taken place. One pocket which extended upward from the junction of the gall-bladder with the cystic duct was especially difficult to empty of its three or four stones. After this normal bile welled up from the gall-bladder. With constant drainage and removal of all stones the patient made an excellent recovery and

left the hospital on the 29th of August. A year later, September 4, 1912, the patient reported entirely free from pain, jaundice, or other symptoms pointing to the biliary tract.

Case 36

A housewife of fifty-four entered the hospital August 8, 1911. There was nothing of interest in her family history. She had "grip" a year, and again six months, ago. She has had twelve children and one miscarriage.

For ten years she has had occasional brief attacks of cramp-like pain in the left side of the abdomen, but it has never been severe and

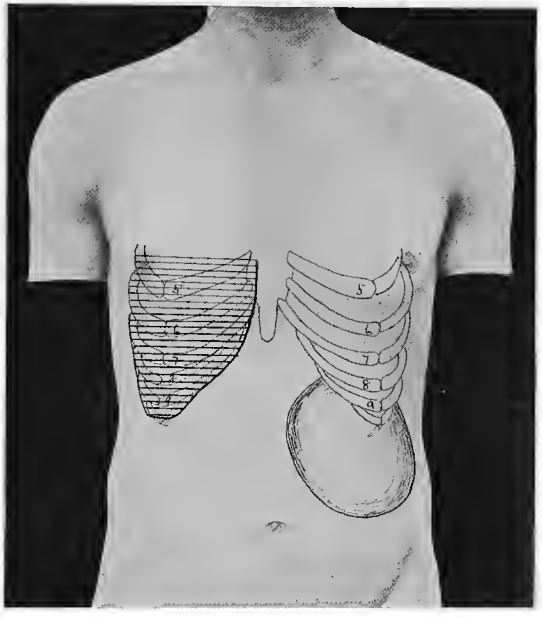

Fig. 53.—Tumor felt in Case 36.

has never troubled her much. Two years ago, after the menopause, she began to lose flesh, and then noticed a large, hard lump in the left hypochondrium. This lump has increased in size since then, and the cramps in the same region have become more frequent and more severe, sometimes shooting across to the right side of the abdomen or into the left flank and back. This pain lasts, however, but a few minutes, though there is a heavy, dragging sensation in the same region most of the time. Since the menopause, two years ago, she has lost 50 pounds and considerable strength. Her appetite is good.

She has no indigestion or vomiting, and though her bowels are constipated she has never had to stop work.

For sixteen years she has noticed that her urine is turbid and milky in appearance, but it has never caused any pain or been passed with abnormal frequency or in abnormal amount. She passes it once in the night.

Physical examination is negative save as relates to the abdomen, where in the left upper quadrant a hard, rounded mass is felt, dull on percussion, extending under the left costal margin, slightly tender, immovable with respiration or under pressure (Fig. 53). The inflated colon traverses this lump. Apparently it has a sharp edge and a notch on the inner side. The urine averages 35 ounces in twenty-four hours; specific gravity, 1016; a sediment estimated at 4 per cent. pus (by volume).

Discussion.—When a patient has had a turbid urine for sixteen years and a left-sided stomachache for ten years—the latter finally associated with a palpable lump, gradually increasing in size for the past two years—one can hardly help suspecting some benign disease of the kidney, even though, as in this case, there has been a loss of strength and of much weight—"50 pounds"—and even though the palpable mass in the left hypochondrium has a sharp edge and a notch. The latter observation would tend to make us think we were dealing with a splenic enlargement, but against this is the presence of a demonstrable pyuria; also the fact that the inflated colon traverses the mass.

In view of the facts last mentioned, it seems to me clear that the proper diagnosis in this case is of some chronic non-malignant disease of the kidney. The pyuria makes it very probable that this disease is either a tuberculous or a non-tuberculous pyonephrosis. Cystoscopy should make the diagnosis more certain and give us a material with which, through pathologic tests, we can settle the question of a tuberculous or a non-tuberculous lesion.

Outcome.—Cystoscopy showed a ribbon of pus coming from the left ureter, especially when pressure was exerted over the mass in the left side. The right ureter was catheterized and a urine of normal constituency obtained. The phthalein test showed that the color appeared in nine minutes. Dr. Hugh Cabot had no doubt that the tumor was a pyonephrosis and that the right kidney would support life. Twenty minims of the sediment from the urine were injected into a guinea-pig August 13th. Autopsy on this pig September 20th showed nothing abnormal. Bacteriologic examination of the urine from the right

ureter showed no growth. The leukocytes numbered 7500; hemoglobin, 75 per cent. In ten days' observation the temperature rarely rose above 99° F. The systolic blood-pressure was 120.

Operation, October 17th, showed a great deal of dense, inflammatory tissue beneath the costovertebral angle. With great difficulty the kidney was dissected free from the inflammatory mass above described. This mass was so gristly that a sharp pair of heavy scissors were necessary to dissect the kidney free.

The pathologist's examination may be summed up as follows: The kidney measured 14 by 12 cm. On section it was filled with pus and contained many abscess-cavities surrounded by fibrous and fatty tissue. In one portion there was a large branching stone, firmly embedded in the kidney substance. Microscopic examination showed no recognizable kidney structure.

Case 37

An unoccupied American girl of eighteen, who has always lived in New England, entered the hospital October 27, 1908. The patient was recommended to the hospital by Dr. W. M. Conant for relief of an epigastric tumor. Two sisters and one brother have died of tuberculosis of the lungs. The parents, two sisters, and three brothers are living and well. Her menstruation began at twelve years and was regular for the first six months. Since then it has been very irregular, the intervals varying from two to seven weeks. At the time of the period or just before it she notices sharp pain in the region of her epigastric tumor. This pain lasts until she has finished menstruation. The pain radiates to the region of the spleen. She has had a little intermenstrual flowing, lasting from one-half to one hour, coming perhaps once a week. With this flow there is also pain in the region of the tumor.

The tumor above referred to has been noticed for about three years, but the patient's pain has troubled her much longer. In the past three years the mass has been gradually enlarging, especially in the last five months, and with its growth it has become more painful, until now it is associated with a constant dull ache and with pains darting to the left. There have been occasional attacks of vomiting both before and since the time at which this tumor was discovered. These attacks are not now more frequent than they were three years ago. They usually come about three hours after eating and the expelled fluid is green and frothy. The bowels are regular. A small amount of food satisfies her; any more causes nausea. She has never

been jaundiced. She thinks of late she has been losing weight, as her clothes seem to be too loose for her.

Physical examination shows excellent nutrition, normal pupils, normal chest, sluggish reflexes, no enlarged glands.

The epigastrium is occupied by a tumor mass of the size, apparently, of an infant's head. It is symmetric, save at the costocartilaginous junctions of the sixth, seventh, and eighth ribs on the left, where there is a smaller swelling about the size of a hen's egg. The larger tumor mass is somewhat soft. The smaller one, which seems to be attached to the ribs, is also soft. The entire left lower quadrant is hyperresonant. Light percussion over the larger tumor shows relative dulness. Heavy percussion gives resonance. Moderate pressure on the epigastric mass elicits some pain. Vaginal examination is negative. The inflated colon apparently overlies the tumor. The blood and urine are negative.

During most of her three weeks' stay in the hospital the patient's temperature reached 99° or 99.5° F. each evening. Twice it rose a little above 100° F. There was no free fat in the stools. The Cammidge test was negative. Dr. F. B. Harrington considered the case a pancreatic growth and advised operation. Dr. Hugh Cabot considered it a cyst, connected either with the pancreas or the mesentery, or possibly a hydatid. Dr. Maurice H. Richardson considered it a pancreatic cyst caused by impaction of a stone in the canal of Wirsung. Dr. Wilder Tileston considered it a phantom tumor.

Discussion.—From reading this case and noting especially the long duration of the symptoms, the good nutrition of the patient, and the presence of a large tumor near the liver, one's first thought might easily be of a hydatid cyst. Against this, however, is the patient's residence. So far as I know, up to the present time, no case of hydatid disease originating in New England has ever been reported. Most of the patients that I have seen have been Greeks.

The strong tuberculous family history and the slight fever might make us conjecture that a tuberculous peritonitis, producing a mass of adherent intestinal coils, has caused the tumor, but I have never heard of a tumor so large as this in tuberculous peritonitis, and the absence of fever is against it.

The situation of the mass favors a pancreatic cyst, but we have no further evidence to bolster up this case. Functional tests of the pancreas should at least be tried before any such diagnosis is made.

On the 2d of November a stomach-tube was passed, with the result that when pressure was made over the epigastrium a large

amount of gas was expelled through the tube and the tumor completely disappeared. The stomach was then inflated and found to be of normal size. After the injected air had been again expelled no tumor could be felt, but after withdrawal of the tube the swelling immediately reappeared; *x*-ray examination was apparently negative. On the 3d of November the abdomen was opened, but absolutely nothing abnormal was found in any part of it. The patient made an uneventful recovery and left the hospital November 19, 1908.

This case seems to me of special value because we were not content in seeing the tumor disappear after the passage of a stomach-tube, but went on to final proof through exploratory incision. Just what a phantom tumor means it is not easy to say. Doubtless the swallowing of air and its retention in the stomach is the most important element, but it is hard to see how this air can remain in the stomach throughout the processes of digestion.

The slight fever in this case is interesting and tends to prove that we may have fever in the absence of all known pathologic processes, the so-called neurotic fever.

Case 38

A reed-chair maker of thirty-eight entered the hospital March 6, 1912. His family history and past history are not of special interest. The patient occasionally goes off on a spree, perhaps three times a year. On these occasions he drinks mostly beer. Otherwise his habits are good. Four months ago he began to have attacks of pain in his right hip, knee, or ankle, the pain shooting from one point to the other and lasting from four to eight hours, gradually subsiding. Up to four weeks ago he had had seven of these attacks. Each of them forced him to quit work and remain quiet for two or three days, and each attack was followed by numbness in the leg and a difficulty in extending it.

Three months ago he first noticed a painless swelling on one of his right ribs. This has remained stationary in size. Four weeks ago he observed a bulging in the right hypochondrium and a constant slight pain there. Both have steadily increased. For three months he has had vomiting attacks two or three times a week and ejected moderate amounts of greenish fluid, but never any food or blood. His bowels have required cathartics for the last four months, and even with cathartics he often goes two or three days without movements. He has noticed nothing abnormal about the stools. He has never been jaundiced. His appetite has been poor. He has

had, so far as he knows, no fever. Four months ago he weighed 165 pounds, now 167 pounds, though he is quite sure he has lost flesh. He has done no work for four weeks.

Physical examination shows a marked loss of subcutaneous tissue. The right eye is missing. The left pupil is slightly irregular, but reacts well. Over the third right rib, in front, is a firm, nodular, tender mass, the size of an egg, apparently attached to the rib, but not to

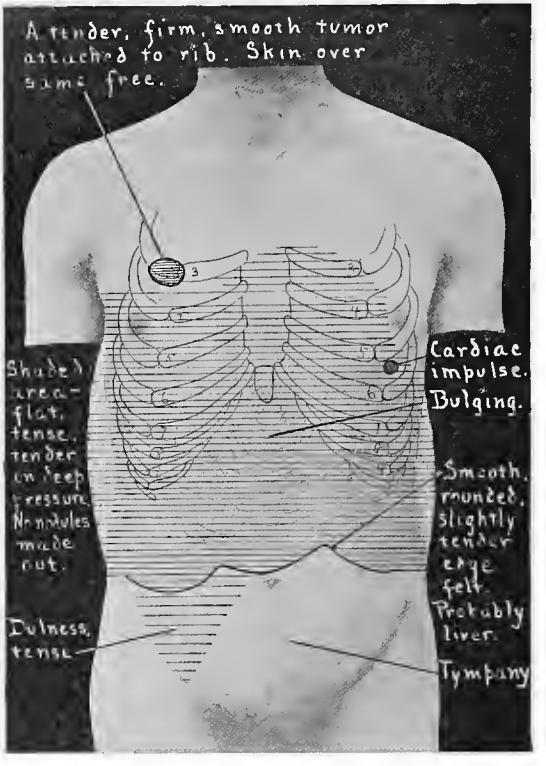
A tender, firm, smooth tumor attached to rib. Skin over same free.
Shaded area - flat, tense, tender on deep pressure. No nodules made out.
Dulness, tense
Cardiac impulse. Bulging.
Smooth, rounded, slightly tender edge felt. Probably liver.
Tympany

Fig. 54.—Signs found in Case 38.

the overlying skin. The condition of the lungs and abdomen is shown in Fig. 54.

Save for slight edema of the ankles the extremities are negative. The knee-jerks obtained only on reinforcement. Blood-pressure, 165 mm. Hg, systolic. The urine at entrance seems to be negative, but is somewhat turbid. There is no Bence-Jones albumose. Red cells, 5,120,000; white, 17,200 at entrance, 24,400 March 8th. Polynuclears, 80 per cent. Slight achromia of the red cells, hemoglobin 70 per cent. Wassermann reaction negative. Feces negative. The

patient's girth over the most prominent part of the epigastric tumor is 98.5 cm. Diagnosis at entrance seemed to be hypernephroma or sarcoma with a possibility of cyst, involving the liver or pancreas. *x*-Ray showed the diaphragm very high on both sides and the heart slightly enlarged on the left, but there was no evidence of bony involvement. The right eye had been removed three years previously after an injury from a piece of steel.

Discussion.—A nodular mass, occupying the site of the liver, is the most important fact in this case. Apparently this mass has existed at least three months. Whether or not it is connected with the sciatic pains which appeared a month earlier we cannot say. Possibly those pains were associated with the patient's alcoholism. Possibly they may be tabetic, as the condition of the pupils and knee-jerks should make us suspicious of a latent tabes, although the Wassermann reaction is negative.

The presence of a lump over one rib suggests a metastasis, and makes us think at once of the tumor which most often produces bony metastasis, namely, hypernephroma. It is not at all impossible that a large renal tumor might push forward to the anterior abdominal wall, displacing the liver to one side, but such occurrences are rare, and there is nothing in the urine to support the hypothesis of hypernephroma.

The lump on the rib might be a myeloma, though such tumors are usually multiple and are usually associated with the Bence-Jones body in the urine. Only histologic examination could make us positive on this point.

Nodular tumors in the region of the liver should always make us think of the possibility of melanotic sarcoma, especially if the patient has had anything wrong with his eye, for in this organ, as is well known, such tumors are most apt to originate. Despite the positive statement in the history of this case that the eye was removed on account of trauma, one of the physicians who saw the patient insisted on believing that we were dealing with a melanotic sarcoma of the liver, secondary to a similar growth in the eye. This chain of reasoning leads us to consider the possibility of finding melanuria in the urine. Such a test should certainly be made, for although in most cases the discoloration of the urine makes itself obvious, this is not always so.

Outcome.—Dr. J. H. Wright considered the growth a melanotic sarcoma, originating in the eye, with metastases in the liver and pectoral region. The urine was examined for melanin and positive tests obtained March 9th and 17th. Syphilis was also considered. On the 9th there was slight shifting dulness in the abdomen. The

tumor over the rib was opened and found to consist of thin-walled capsule, containing grayish, grumous material. The rib surface was eroded and the sac seemed to lead up between the ribs. No microscopic examination is recorded.

The patient lost ground rapidly and died on the 22d. There was no autopsy.

Case 39

A suspender maker of sixty-two entered the hospital June 25, 1912. The patient states that he "had the pox thirty years ago" and has had a group of pimples every summer since. About two years ago he first noticed an easily movable lump, the size of a hen's egg, just below the left costal border. This has gradually grown to its present size, without producing any symptoms. He has worked steadily, but five weeks ago, while lifting a trunk, he strained himself. Since then he has been steadily running down. The mass is now tender on pressure and there is a constant dull ache in it, with occasional attacks of sharp pain radiating to the back and left groin. The pain has no relation to food or to the passage of urine or feces. For the past month he has lost much weight and strength and is now in bed much of the time. Appetite is poor; bowels move every one to three days. He has noticed nothing abnormal about his urine.

Physical examination shows moderate emaciation, many acne papules and pustules, mucous membranes slightly cyanotic. Inguinal glands slightly enlarged. Chest negative. In the left hypochondrium is a smooth, hard, rounded, slightly movable tumor, filling out the flank and pushing up the ribs. Impulse exerted upon it is felt in the left lumbar region. The inflated colon lies between the tumor mass and the abdominal wall. The urine shows numerous pus-cells and a good deal of mucus, no blood. The blood is normal. Blood-pressure, 135 mm. Hg., systolic; 80 mm. Hg., diastolic. No fever in three days' observation. Wassermann reaction negative. Feces negative.

Discussion.—In view of the syphilitic history, it is worth questioning, for a moment, whether the lump in the left hypochondrium may possibly represent a gumma of the left lobe of the liver. The negative Wassermann reaction is somewhat against this, and the large mass and characteristic situation of the tumor makes it much more probable that we are dealing with a kidney.

Apparently the lump has existed in this region for at least two years, although the patient's health was good until five weeks ago. It is not at all probable that the strain mentioned in the history has

anything to do with making the patient run down. Presumably the change which occurred five weeks before he entered the hospital was not due to any external cause, but rather to the natural progress of the disease. Our belief that the lesion is connected with the kidney is strengthened by the fact that we have no symptoms referable to the other organs which most often cause symptoms in the left hypochondrium, viz., the stomach, the spleen, and the colon.

Assuming, then, that we are dealing with a renal tumor, associated with pus in the urine, pyonephrosis is the first thing to be considered. The absence of fever and leukocytosis are somewhat against this supposition. It is also unusual to encounter a case of pyonephrosis the symptoms of which originated at the age of sixty. Nevertheless, without a cystoscopic examination, we cannot exclude renal suppuration.

Against renal tuberculosis the same reasons just given hold good, yet this disease cannot possibly be excluded without further examination.

Renal neoplasm was considered the most probable diagnosis by all those who saw the case. The absence of a hematuria does not militate against this diagnosis, as blood appears in the urine in cases of hypernephroma only when the growth reaches the renal pelvis.

Outcome.—On the 29th the abdomen was opened and a tumor the size of a child's head presented in the left hypochondrium. While removing this tumor the spleen was torn and there was a considerable hemorrhage, controlled by packing. This damage was so great that the spleen had to be removed. After the ether was removed the patient stopped breathing, but promptly began again. He recovered well from the ether, but died on the 4th of July. Examination of the tumor showed it to measure 19 by 24 cm., with a smooth surface. It consisted of a firm, thick capsule, enclosing a putty-like mass, with a large amount of bloody fluid. Microscopic examination showed a richly cellular tumor with numerous large necrotic areas. The cells were of rather small size, with deeply eosin-staining protoplasm, and deeply staining nuclei. These cells were embedded in firm, fibrous tissue and had a papillary arrangement on connective-tissue stalks of various widths. The diagnosis was hypernephroma. The spleen was normal.

Case 40

A Greek mill hand of twenty-four, born in Turkey, was seen November 10, 1913, complaining of abdominal pain. Family history,

past history, and habits negative. In the past three months he has had ten attacks of colicky umbilical and epigastric pain, with vomiting at a variable interval after meals. Duration usually three or four hours; last night, eight hours. The pain is not relieved by food, pressure, or posture. Morphin has been used in three attacks. Vomiting and hot applications give some relief. Vomitus not characteristic. Much gas after food. He has lost much weight and has done no work for three months.

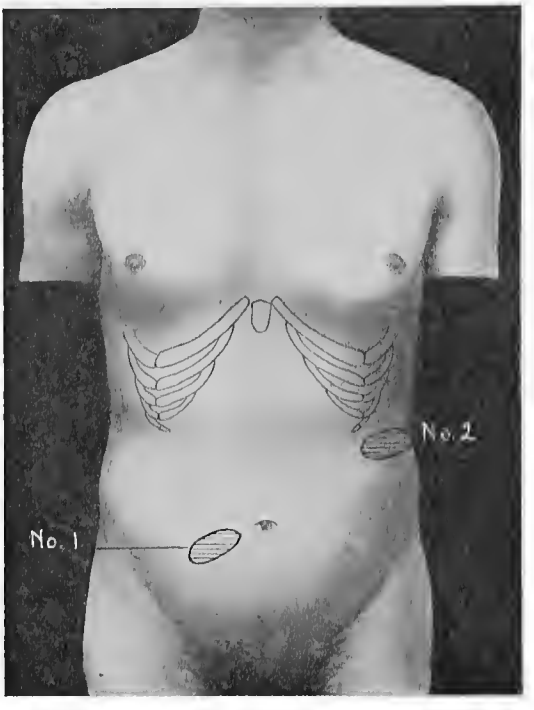

Fig. 55.—Masses felt in Case 40, November 24, 1913. The same lumps can be identified by their numbers in Fig. 56.

On physical examination a hard lump, the size of a walnut (Fig. 55, No. 1), is felt to the right of and below the navel. In the vicinity of the descending colon is another mass the size of a small egg (Fig. 55, No. 2). Both masses at times disappear. No visible peristalsis. Left epididymis slightly thickened. Pupils normal. Knee-jerks absent. Other reflexes and the rest of visceral examination negative. Guaiac test positive in fasting gastric contents and after test-meal. Free HCl absent. No stasis. Six stools guaiac-negative. Bismuth *x*-ray showed a small, high stomach, with irregular peristalsis, especially at lesser

curvature, where the outline also shows shortening and irregularity. Pyloric sphincter and duodenal cap not abnormal. Bismuth enemata gave negative results.

Blood and urine negative. Wassermann negative; *x*-ray of chest negative. Blood-pressure 100, systolic; 80, diastolic. Pulse, temperature, and respiration normal for three weeks' observation. Bowels move well.

Clinical diagnosis: Dr. R. I. Lee, Gastric ulcer of lesser curvature. Dr. E. A. Codman, Chronic intussusception.

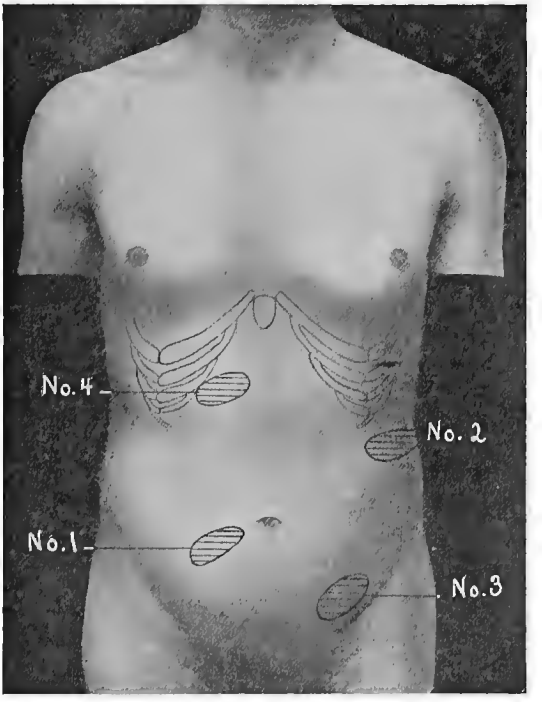

Fig. 56.—Lumps felt December 1, 1913.

November 24th masses are felt as in Fig. 55. An oil enema produces a tremendous mass of feces. November 25th he had severe colicky pain all day, with hard, distended belly. Morphin and atropin relieved the pain. Masses were still clearly felt. November 27th, after test-meal, free HCl 0.04; total acidity 0.027; guaiac test positive. On the 28th there were two more lumps (Fig. 56, Nos. 3 and 4). Tuberculous glands was the diagnosis most considered, with malignant disease second.

Discussion.—A great many diagnoses were considered by members

of the attending staff in this case. At the beginning of his hospital stay, before the tumor masses had made themselves obvious, our chief evidence of disease was the *x*-ray and the finding of blood in the stomach-contents. From these facts a peptic ulcer was suspected. Later, when the tumors have made their appearance, but appeared to be curiously fugitive—shifting their place from day to day—the idea of a chronic intussusception was entertained. Earlier still, the colicky epigastric pain, leading to the use of morphin, had made us consider gall-stones.

After the administration of the oil enema and the evacuation of a very large amount of feces the question of fecal impaction was considered, although, I think, wrongly. I have yet to be convinced that fecal impaction, without some organic disease producing a previous intestinal stenosis, ever produces any important symptoms or tumors. Fecal impaction seems to me largely a diagnostic myth, especially when considered as a possible cause of intestinal obstruction. In the vast majority of cases in which I have known it to be considered in differential diagnosis, it has turned out, as the present case did, to involve some very different diagnosis as the true one.

Multiple tuberculous tumors, due to adenitis or adherent intestinal coils (tabes mesenterica), was the diagnosis made by the majority of those who saw this case. It was almost the only common disease which could produce such an assembly of lumps as finally made themselves felt.

The alternative supposition of malignant disease was also upheld by several members of the staff, but the patient seemed hardly sick enough, and few of us had seen so many tumors in any type of neoplasm involving the intestine.

Outcome.—December 1, 1913, he was transferred to the Surgical Wards. Meantime he had been home and had secured from his attending physician a diagnosis of "pyloric stenosis." Dr. W. N. Conant first made diagnosis of tuberculous peritonitis. Under ether the lower lump (No. 1) was easily felt, and was so hard that the diagnosis was promptly changed to malignant disease of the gut. Incision over it showed this lump to involve the intestine and adjacent mesentery. The lump was 3 inches long, $1\frac{1}{2}$ inches wide, spool shaped. The bowel above it was thickened and dilated; below it, normal (Fig. 56).

In the splenic region another tumor (No. 2), also involving the gut, was found. It was as large as the fist, hard and nodular. In handling, it broke, and excision was necessary. End-to-end intestinal anas-

tomosis was done. No. 1 was side tracked by a lateral anastomosis. No. 3 was felt in the left inguinal region, but was not connected with gut. Dr. Whitney's report showed a round-cell sarcoma (*i. e.*, lymphoblastoma).

December 27th, after an uneventful convalescence, the patient went home.

Case 41

A Greek of twenty-two entered the hospital February 21, 1914. His family history was negative. He denies venereal disease. Seven years ago he felt a pain and non-tender lump in the right side of belly, under the belt. The lump disappeared in a week or so. Two years ago he had a similar attack and lump. Four and a half months ago he had headache, "yellow skin," fever, and nausea. The fever left in a few days. At this time he felt a lump in the right upper quadrant, not tender, not constant. The "jaundice" ceased in one month. Soon after he noted pain in left upper quadrant, worse on exertion, but never severe. He lost some strength, but kept at work until a week ago, when he gave up on account of left-sided pain and distention. He was costive, but noticed no blood or tarry stools. Appetite and sleep good; no loss of weight.

Physical examination showed no jaundice, no emaciation. There was a scar in neck, 5 by 1 cm. [From this point a mass was removed when he was a child.] The contour of the right lower axilla was slightly more full than the left. There was a high-pitched musical systolic murmur over the whole precordia, not heard in the axilla. The first sound was obscured by it. The pulmonic second was greater than the aortic second and double. The apex shifted 3 cm. with change of position. There were three nodules on the liver edge and extending over its surface, which was not tender, and moved freely with respiration (Fig. 57). There was an extensive scar on the outer lower right leg, just below the knee. Rectal examination showed above the prostate an irregular nodular mass, 2 to 3 cm. in diameter, projecting into the rectum, immobile, and attached to the anterior wall. The "liver mass" extends through to back. It did not feel like a cyst. Dr. W. H. Smith made a preliminary and tentative diagnosis of hypernephroma or liver neoplasm, but the home officer records that the patient "Looks too well nourished for malignant." Stomach-tube examination was negative; *x*-ray was negative. Blood and urine negative. Wassermann negative.

The following diagnoses were also considered: (1) Distended gall-

bladder; (2) cyst or tumor of kidney; (3) cyst or tumor of the under part of right lobe of liver. Bismuth *x*-ray examination of the stomach showed "pressure on lesser curvature from some tumor outside digestive tract."

February 27th a collargol plate showed apparently some pathologic process in right kidney.

March 6th the record states: "He has had no pain while here. Weight of evidence is for lesion of kidney."

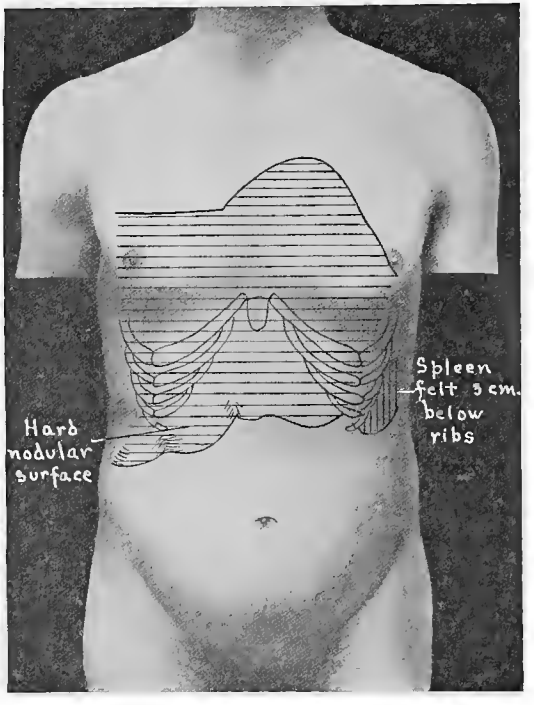

Fig. 57.—Masses felt in Case 41.

Discussion.—The most important points about this case were the following:

The occurrence of a mass in the right hypochondrium, known to be of long duration, associated with good nutrition, in a Greek. Were the patient older and of the other sex, his history of jaundice and pain in the region of the gall-bladder would have made it necessary for us to put gall-bladder disease first among the diagnostic possibilities. Against this, however, is the actual condition which was felt in the region of the liver. Unless we were wholly mistaken, it was a sharp edge and not a round sac which we felt in the right hypochondrium.

Supposing that we were correct in our belief that a nodular enlargement of the liver existed, there are really but three reasonable possibilities: first, malignant disease; second, syphilis; third, hydatid.

The patient is extraordinarily young for cancer of the liver. He has had no gastric symptoms such as usually accompany the primary gastric cancer, from which the liver metastases follow. Moreover, this patient's nutrition is extraordinarily good for so serious a neoplasm.

Syphilis cannot be excluded and the absence of a Wassermann reaction does not rule it out. We cannot say, however, that we have any positive evidence of such disease unless the presence of an accompanying splenic tumor is so regarded.

Hydatid is suggested by the patient's race and by his good nutrition, despite the presence of a large tumor. Against it we have the lack of any eosinophilia and the general rarity of the disease in New England. We have almost ceased to look for the classical hydatid thrill about which the older text-books used to excite us so much.

Outcome.—Operation showed a liver studded with cysts, whence scolices were obtained.

In view of all the facts and of the patient's good recovery, there seems no good reason to believe that there is any disease in the kidney or in the region of the prostate. The findings recorded in these organs are regarded as errors.

CHAPTER II

VERTIGO

VERTIGO, or the disturbance of static control, cannot be defined in purely objective terms. We cannot deny that a person is dizzy, even if we cannot see him stagger or verify the existence of nystagmus. Nevertheless, such objective verifications are always to be sought for, especially in medicolegal cases, traumatic neuroses, etc. As a presenting symptom, vertigo is not at all common. Joseph Collins[1] states that among 425 neurologic cases of all types, seen by him in the New York Neurological Institute during 1910, only 22 complained of vertigo, in the sense of a definite disturbance of equilibrium. He excludes here sensations called dizziness, but consisting chiefly of blurred vision, minute black spots in the visual field, and disagreeable sense of mental confusion.

PHYSIOLOGIC VERTIGO

(*a*) Most normal individuals occasionally become dizzy if they look down from a great height or look up to a great height, or if they spin round rapidly, as in waltzing without reversing. A certain number of people become dizzy if they ride backward in a railroad train or if they watch moving objects, such as a waterfall, a snowstorm, water flowing under a bridge, or clouds overhead.

(*b*) Probably in a different group should be placed the occasional attacks of dizziness on suddenly rising from a stooping posture or suddenly lying down, on quickly turning the head, or quickly looking at the ceiling.

(*c*) What is called car-sickness and sea-sickness are probably exaggerations of these physiologic types of vertigo.

(*d*) In many persons the passage of a galvanic current through the head or a syringing of the external ear with hot water is sufficient to produce dizziness, without there being any organic disease present or any pathologic sensitiveness to ordinary stimuli.

[1] New York Medical Record, 1912, vol. lxxxi, p. 1019.

Causes of Vertigo

AURAL DISEASE

ARTERIOSCLEROSIS

OTHER ORGANIC BRAIN DISEASE NOT NOTED BELOW

THE MENOPAUSE

ACUTE INFECTIOUS DISEASE (ONSET)

NEUROTIC STATES (NEURASTHENIA, HYSTERIA, MIGRAINE)

OCULAR DISEASE

} CASES TOO MANY AND TOO VAGUELY ENUMERABLE FOR GRAPHIC REPRESENTATION.

PATHOLOGIC VERTIGO

Dizziness, as a result of disease, may be divided into four main groups:

Vertigo from organic brain disease.

Labyrinthine vertigo ("aural").

Vertigo in neurotic patients.

Vertigo from cerebral anemia or transitory cerebral intoxication.

In a general way we may say that the dizziness of young people is ordinarily transient and unimportant; that the dizziness of elderly people is apt to be recurrent and serious because it usually depends upon organic disease of the brain or internal ear. Each of these main groups will now be discussed more in detail.

Vertigo from Organic Brain Disease

In organic brain disease we must distinguish, as the commonest of all causes of vertigo, *arteriosclerosis*. When an elderly person begins to have attacks of vertigo, we may usually make a correct guess that it is due to arteriosclerosis. These attacks may be mild and occur off and on for years without ushering in anything more serious; but in many cases they are either the beginning or the precursor of apoplectic seizures. It seems to me impossible to distinguish the vertigos of cerebral syphilis, so called, from those of arteriosclerosis, just described.

In *cerebral tumor*, vertigo is a frequent symptom, especially if the growth involves the frontal lobes or the cerebellum. The best authorities find vertigo in almost every case of cerebellar disease, in the majority of frontal tumors, and in not more than one-third of the tumors occupying other parts of the brain. Cerebellar vertigo tends to be associated with staggering or swaying in one particular direction. According to Hitzig, paroxysmal attacks of vertigo in brain tumor tend to prove that the growth is in the regions of the motor areas.

In *multiple sclerosis* there is probably no more constant symptom than vertigo. Three-fourths of the best studied cases show it.

In *dementia paralytica*, vertigo is common as an early symptom, before the disease is fully developed. Later in the course of the disease it always appears a few minutes or hours before an acute seizure (coma, convulsion, hemiplegia).

Before cerebral hemorrhage or acute softening, vertigo is one of the commonest of prodromata. It is distinctly commoner than headache.

Aural Vertigo

A patient may have advanced disease of the ear and deafness, without vertigo, in case the labyrinth is not in any way affected. Nevertheless, in the vast majority of affections of the ear, with or without deafness, vertigo is a more or less common symptom. The complex of symptoms, known as Ménière's disease, is not properly a disease. It may occur without any organic lesion of the vestibule or of any other part of the body. In the latter cases, for example, in traumatic neurosis, one may use the term pseudo-Ménière's disease, but this seems to me foolish. The complex of symptoms usually associated with Ménière's name is deafness, tinnitus, vertigo, and nausea or vomiting, the whole group appearing with alarming suddenness and often utterly prostrating the patient. Less constant are the sense of pressure in the head, nystagmus, ataxia of the cerebellar type, and, rarely, diarrhea. In all cases of this type the help of an aurist should be sought, although a treatment directed to the ear is often unavailing.

To determine whether the labyrinth is actually involved and is the cause of vertigo the general practitioner is rarely sufficiently expert, and a specialist should be consulted. It may be said, however, that labyrinthine vertigo can rarely be diagnosed unless nystagmus can be observed. On the other hand, it must not be forgotten that nystagmus sometimes occurs spontaneously and habitually in otherwise healthy people. When nystagmus can be produced by spinning the patient upon a rotary stool or by hot ear injections, labyrinth disease is much more strongly suggested.

Neurotic Vertigo

Whatever else we may or may not mean by the neurotic state (neurasthenia, psychoneurosis, congenital nervousness), it certainly involves an undue sensitiveness to stimuli and impressions of all sorts. Most cases of neurotic vertigo occur when a person is exposed to some sudden change of position or to some other environment which in ordinary persons would not be sufficiently strange to upset their static control. Thus, in many neurotics, especially in traumatic neuroses, sudden turnings, bendings, any associations with the conditions which have produced the original injury, walking, driving, and other common acts, are sufficient to produce giddiness. Especially common in the neurotic is giddiness or headache on exposure to the sun. Many of the cases of vertigo, supposedly due to alcoholism, to tobacco, or to

indigestion, are probably of the neurotic type. In this form of vertigo there are often no objective manifestations, no staggering or nystagmus. If the patient does stagger at all, it is usually an unsystematic lurching, without any constant tendency to go to one side. Patients with neurotic vertigo almost never fall, and in this respect their troubles contrast sharply with those occurring in arteriosclerotics and in other forms of organic brain disease. In the latter, serious injury not infrequently results from a fall during an attack of vertigo.

In the neurotic type of vertigo the symptom is often associated with or initiated by fear and autosuggestion. Thus, the neurotic often suffers from vertigo when he gets into a large open space, and in such cases his dizziness may be associated with or substituted for an agoraphobia. Conversely, the neurotic is often dizzy in enclosed places, in church, at the theater, and here, again, his giddiness is associated with fear and the senseless dread that he cannot get out. Autosuggestion plays a large part in both the last-named types of vertigo, but there is another element—an ocular element—in many cases. In these the dizziness seems to be associated with inability to fix or focus the eyes upon any point near at hand. Sometimes this weakness is transferred wholly into the psychic field, and the patient is dizzy because he cannot concentrate his mind upon any single point.

Vertigo in Connection with Epilepsy.—With epilepsy, as with all acute cerebral seizures, any type of vertigo may occur, either as a prodromal symptom, ushering in the attack, or as a supposed equivalent for the convulsive attack. The great majority of epileptics are conscious of such troubles more or less frequently.

Vertigo from Disturbed Cerebral Circulation.—In the vasomotor disturbances, at the time of the menopause, vertigo is often associated with flushing, heat, and sweating about the head. Here it is natural to assume that the dizziness results from *cerebral hyperemia.* Very possibly a good deal of the giddiness associated with *cardiac disease* is also of this type, though it may belong to the group of cases next to be mentioned.

Cerebral anemia, either in the form associated with fainting or in that which forms a part of a general anemia, as in chlorosis or after hemorrhage, is a frequent and familiar source of vertigo. In this, as in all other types of dizziness, the symptom may be associated with nausea, pallor, and loss of consciousness.

IS THERE A GASTRIC FORM OF VERTIGO?

Thirty years ago I suppose that the majority of cases of vertigo would have been explained as resulting from stomach trouble (*vertigo a stomacho læso*). Nowadays we are very skeptical about these cases. The more carefully they are studied, the fewer of them appear to be of gastric origin. Thus, Charles G. Stockton[1] reports that out of 828 patients treated by him for stomach trouble, 55 complained of vertigo, "but in 30 of these the symptom was traced to aural defect, renal disease, or arteriosclerosis. In 15 it was dependent upon neurasthenia, intoxication, circulatory disease, or gout. Only in 10 did the dizziness appear to arise from dyspepsia," and even these were more or less doubtful. In Gower's text-book the author conjectures that not more than 5 per cent. of the cases of vertigo are of gastric origin.

It is, of course, well known that vertigo is very frequently associated with nausea, vomiting, and other gastric symptoms, but in the great majority of cases in which this association is found, the dizziness arises from the same cause that produces the nausea, as, for example, in sea-sickness, car-sickness, brain tumor, syncope, etc.

Vertigo of reflex origin—for example, the so-called laryngeal vertigo—is subject to a good deal of skepticism by the most competent authorities. Many of the cases of laryngeal vertigo are associated with a violent cough, and this, with cerebral congestion, would bring them into the same general group with the vertigos of the menopause.

The same skepticism exists with regard to the majority of so-called *toxic vertigos*, such as those from tobacco or alcohol. Circulatory influences can rarely be excluded, and if the dizziness is of more than transitory occurrence some organic basis may usually be found.

In conclusion, it may be said that the great majority of cases of severe chronic or paroxysmal vertigo are found, if carefully studied, to have involved some disease of the labyrinth.

Case 42

An Irish hostler of thirty-one entered the hospital October 26, 1900. The patient has always used tobacco to excess, but has felt perfectly well until yesterday morning, when he got up feeling very dizzy and unable to walk straight. Vomiting of bitter, green fluid soon followed. After that he managed to do his work as a hostler, but this morning the symptoms recurred and were so severe that he came to the hospital in the afternoon. He has noticed a dazzling of vision for two days, but has no headache and no other complaints.

[1] New York Journal of Medicine, August, 1912, p. 416.

At entrance his temperature and respiration were normal. His pulse was 50, and during his ten days' stay in the hospital it ranged between 50 and 60. He had a very marked polyuria throughout:—on the 28th, 125 ounces; on the 29th, 165 ounces; thereafter in the vicinity of 100 ounces a day. The specific gravity varied from 1008 to 1017. Albumin was always present in traces, and the sediment showed a rare hyalin and granular cast, with small, round cells and fat adherent; also an occasional fatty cast. The fundus oculi was normal. There was marked nystagmus. Below the right scapula breathing, voice sounds, and percussion resonance were diminished. The heart was not enlarged. The pulses were of high tension. Aortic second sound very sharp. The blood-pressure not measured. No edema.

By the first of November he was much better, had no dizziness or gastric symptoms, and felt as well as before the present trouble. The tension of the pulse was less high. The night amount of urine never exceeded the day amount until the last two days of his stay, when the figures were as follows: November 1, day, 34; night, 78. November 2d, day, 38; night, 60. He left the hospital on the 4th of November.

Discussion.—In the hospital record of this case the vertigo is attributed to the use of tobacco, but from my study of the record it seems to me clear that tobacco had little, if anything, to do with it. In fact, I doubt whether tobacco ever produces vertigo except in a novice. Although we lack several pieces of information which in a more modern record would be present, viz., a blood-pressure measurement and further functional tests of the kidney, I feel no doubt that the vertigo in this case was due to a chronic nephritis with hypertrophied and dilated heart. In such disease it is well known that cerebral seizures of various kinds and of various degrees of severity are common, and whether or not Pal's idea of a vascular spasm is the correct explanation of these seizures, the important fact is their constant association with chronic nephritis and hypertension, with or without arteriosclerosis of the cerebral arteries.

I have searched the hospital records diligently for a more plausible case of vertigo due to the use of tobacco, but this is the best that I have been able to find, and, to my thinking, the vertigo is in this case certainly due to the condition of the renal and vascular systems.

Case 43

A housewife of fifty-two entered the hospital March 27, 1902. Three years ago the patient had a bad fright and became very dizzy,

so that she had to lie down to prevent fainting. Since then she has had similar attacks of *vertigo* about once a month, relieved by lying down. Since last November, however, these attacks have been more frequent and now occur four or five times a day. Of late they have been associated with dyspnea and palpitation, but are still relieved by lying down for five or ten minutes.

For several months she has noticed pain in the lower abdomen and the small of the back, especially after exertion, accompanied by frequency of micturition. She passes urine twice in the night. Since November she has had more or less hoarseness, aggravated by excitement, and steadily increasing of late.

On further questioning, she remembered that three winters ago she had neuralgia in the upper part of her back, across the shoulders, in the nape of the neck, and in the right hand. These attacks have recurred each winter and are associated with tenderness of the painful areas, but not with any redness or swelling. The attacks usually last about two months. She had one child born thirty-three years ago; no miscarriage. All her life she has been more or less troubled by dyspnea and palpitation on exertion.

Her mother died at fifty-five of consumption. She has also lost three brothers and two sisters of consumption. Three other sisters and two other brothers are living and well.

Physical examination showed good nutrition, moderate cyanosis, normal pupils, glands, and reflexes. At the left apex behind there was a slight dulness, with high-pitched expiration, increased whisper, and decreased tactile fremitus. Otherwise the lungs were normal. The heart's apex was in the fifth interspace, $5\frac{1}{4}$ inches from the median line, the right border $2\frac{1}{2}$ inches from median line. There was well-marked pulsation at the junction of the clavicle and sternum on the right side, and considerable bulging of the clavicle and supraclavicular space. The veins of the upper sternal region were prominent. At the apex there was a slight systolic and a loud diastolic murmur, with absence of the second sound. At the base the first sound was replaced by a blowing systolic murmur and there was also a faint diastolic murmur. Over the seat of pulsation, below the right clavicle, was a loud, blowing systolic murmur and a slight systolic shock. The abdomen was negative. Both tibiæ were nodular and there was slight edema over them. The pulse was not obtained in the left wrist. Blood and urine normal. Tracheal tug present. No fever in a week's observation.

Discussion.—Although this patient has a strong tuberculous his-

tory, there are no actual symptoms in the case which we can attribute to a tuberculous lesion, and presumably the patient has not been infected in any important degree.

In working our way into the case it is important to note that the attacks of vertigo are associated with dyspnea and with a condition in which the patient nearly faints. Vertigo of cardiac origin is not at all infrequent, and such an origin is suggested by this patient's dyspnea, though the force of the suggestion is weakened when we read her statement that she has had dyspnea more or less all her life.

After reviewing the physical signs in the case, the bulging and pulsation at the right sternoclavicular joint, the diastolic murmur, with absence of the aortic second sound, the nodes upon the shinbones, the absence of the left pulse, and the presence of a tracheal tug, we can have little doubt that the patient has an aneurysm of the aortic arch, and that her hoarseness, her neuralgia of the shoulder, nape and hand, and probably her dyspnea, are due to the same cause. That cause, syphilis, has probably produced also changes in the cerebral arteries, whereby the amount of blood passing through them does not vary as it should, according to the demands of the moment. One can well conjecture that such vascular changes would produce vertigo.

Outcome.—The patient's rest in bed seemed to do her much good. By the 30th she was very anxious to get home. No medication was given save an occasional counterirritant or hypnotic, and on the 3d of April she left the hospital.

Case 44

A druggist of fifty-eight entered the hospital December 8, 1902. The patient was always perfectly well until last July, when, after a hearty dinner, he became dizzy and could not talk. This passed off in a few minutes and he has felt well until yesterday, when the same symptoms recurred and were followed by suffocation and soon after by unconsciousness.

For two years he has noticed that he had to rise twice in the night to pass urine, and last summer he had one short spell of vomiting and diarrhea. His eyesight has been excellent.

Physical examination showed good nutrition, partial coma, pallor, and a peculiar odor to the breath, not urinous, a high-tension pulse, a sharp aortic second sound, marked pulsation of the brachials, visible throughout the whole arm. There was no paralysis. At the

apex of the heart a soft systolic and a blowing diastolic murmur was heard. No enlargement, however, of the organ was made out. The pulses had a Corrigan quality. The bladder reached to the umbilicus and 42 ounces were withdrawn by catheter. The rectal temperature was 101° F. (Fig. 58). The leukocytes were 14,500; hemoglobin, 75 per cent. The urine was 40 ounces in twenty-four hours; specific gravity, 1009 to 1012; albumin, from ½ to 1 per cent.; a few hyaline and highly refractive casts.

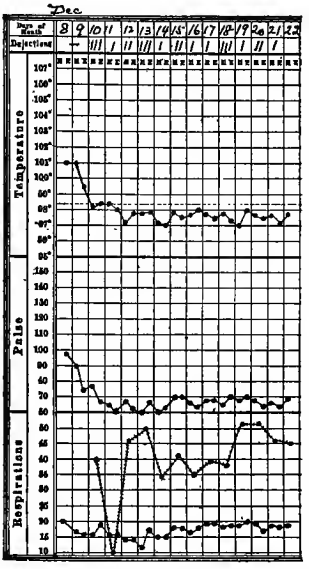

Fig. 58.—Chart of Case 44.

Discussion.—When vertigo is associated with aphasia in a man of fifty-eight, and especially when six months later these same symptoms are followed by an attack of coma, there is little doubt that we are dealing with cerebral arteriosclerosis. The history of nocturia makes it probable that further examination of the heart and kidney would reveal similar arteriosclerotic changes in these organs. Unfortunately, we have no blood-pressure measurements, as in 1902 we were not making them in all cases, but it seems to me clear that the coma which led to his becoming a hospital patient was of the type associated with a chronic nephritis and cerebral arteriosclerosis.

Since the Wassermann reaction had not been discovered at the time when this case was seen, and since no *x*-ray examination of the aortic arch was made, we cannot decide whether or not the diastolic murmur was due to a syphilitic aortitis.

The fever present during the first forty-eight hours of his illness is probably of the cerebral type, the type often seen in cerebral hemorrhage, cerebral tumor, concussion or fracture of the skull, even when all infection can be excluded. This point is sometimes of importance in differential diagnosis, as many physicians are prone to believe that the presence of such a fever proves infection.

Outcome.—Under hot-air baths and purgatives he rapidly improved; by the 19th he felt very well and was able to go home, but died there on the 23d of December.

Case 45

A wood-chopper of sixty-two entered the hospital February 3, 1904. The patient's mother and one sister died of consumption; his father, of some unknown cause; two other sisters, of typhoid. The patient himself has been in perfect health until ten months ago and his habits have been excellent. At that time he first noticed dizzy spells, slight headache, and dimness of vision. The attacks lasted ten to fifteen minutes and gradually increased in frequency, until during the last month the three symptoms above mentioned have been constant and walking has become very difficult. He has noticed numbness in his right arm and leg, also a very slight numbness in his left arm. His appetite and digestion are excellent, bowels regular.

Examination of the internal viscera is negative. The arteries are somewhat thickened and tortuous, with a lateral excursion in the brachials. The right knee-jerk is more marked than the left. Plantars normal. Sensation to touch and temperature is absent in the right thigh and leg. Pain sense and muscle sense present. Cremasteric reflex absent on the right. Fibrillary twitching in the extensor of the right thigh. Skin reflex on the right side of the abdomen much diminished. The right hand is weaker than the left. No disturbance of sensation in the arms. Blood and urine normal. Speech slow, but not aphasic. Double optic neuritis is found on examination of the fundus oculi.

Dr. G. L. Walton thought there was a new-growth in or near the Rolandic region on the left, and advised operation for decompression. During the patient's six weeks' stay in the medical wards there was no abnormal temperature or pulse recorded. The patient had a good deal of headache up to the 12th of February, after which it was less. On the 17th it again increased and his mental condition became duller. He also had some difficulty in swallowing, which lasted, however, only a few days.

On the 12th of March it was noted that his headache has not increased, but the dizziness was more troublesome and he began to become stuporous, so that he snored continuously, day and night. As the degree of optic neuritis steadily increased, he was transferred to the surgical wards. Examination there showed incomplete fixation of the eyes when they were turned toward the left, the effort being accompanied by twitching muscles of the eyeballs (nystagmus). When the effort was made to turn the eyes to the right, the right eyeball did not go beyond the median line. The pupils were normal. The

masseter muscles were contracted on each side. The right side of the face below the eye moved less well than the left. There was diminution of sensation over the whole right side of the face, both to touch and temperature. There was considerable deafness in the right ear. There was no Babinski. Both knee-jerks were lively. The muscles of the right leg were weaker and less complete than those of the left. Sensation of position for the toes of the right foot diminished. A half-dollar piece was not recognized by the right hand and was called a jack-knife, but it was at once recognized by the left hand. There was some inco-ordination of the hands, especially of the right.

Discussion.—The history shows vertigo associated with numbness in the right half of the body. Physical examination shows weakness; in addition, ataxia of the right side, associated with optic neuritis, and later with mental changes and dysphagia. All this points directly to some focal brain lesion, probably brain tumor.

Arteriosclerosis is to be excluded. It does not ordinarily, if ever, produce a double optic neuritis, and the gradual onset of mental cloudiness is not characteristic. The type of hemiplegia associated with arteriosclerosis is apt to appear more suddenly and to involve more extensive loss of power.

Dementia paralytica might begin in this way and might produce many of the symptoms present in this case. It would be unusual, however, to have no more definite mental symptoms, and double optic neuritis is not the usual lesion found in these cases. Spinal puncture and the examination of the spinal fluid for evidence of syphilis would be the most important point in making more certain our right to exclude dementia paralytica, but spinal puncture is sometimes an operation of serious danger in cases of brain tumor, and when that lesion is suspected should be performed with extreme caution and only for the best of reasons. The appearance of nystagmus and astereognosis goes to confirm a diagnosis of localized cerebral lesion and, therefore, of a tumor.

The point of special interest is the fact that vertigo was his first symptom.

Outcome.—On the 26th the patient was trephined over the Rolandic area on the left, the dura was opened, and the brain exposed. Nothing abnormal was seen. The operation made no difference at all in the patient's symptoms except that on the 3d of April he was aphasic. On the 16th of April the brain was further explored for tumor, but nothing found. There was no considerable change in the patient's condition until the 5th of May, when he began to have

convulsive movements on the left side. There was considerable hernia of the brain substance. On the 24th of May he died. Autopsy No. 1220 showed an endothelioma of the dura mater in the posterior fossa; purulent meningitis; multiple gas-cysts of the brain; bronchopneumonia of the left lung; lymphoma of the mediastinal region; cysts of the kidney. Obsolete tuberculosis of the upper lobe of the left lung and of the bronchial lymphatic glands. Slight arteriosclerosis of the aorta.

Case 46

A gymnastic instructor of twenty-eight entered the hospital September 21, 1904. For the past two weeks the patient has been feeling weak and has been troubled with *dizziness* and headaches. He has slept but little and has no appetite. He has never been sick before and has an excellent family history and habits.

Physical examination was negative. There was a continued fever and a positive Widal reaction. The white cells at entrance numbered 11,200; hemoglobin, 80 per cent. The urine was 30 ounces in twenty-four hours; specific gravity, 1020; albumin, very slight trace, and a few hyaline, fine granular and coarse granular casts. The patient ran the ordinary course of a typhoid with relapse, and left the hospital in good condition on the 5th of November. At the time that he left he had slight cystitis and typhoid bacilli were recovered from his urine. *His white count remained above 9000 during the whole of his fever.*

Discussion.—The case is a typical illustration of vertigo associated with an acute infectious disease. Presumably the dizziness has the same significance here that headache does. Precisely what the significance is we do not know. It may be toxic, but it may also be circulatory. The occurrence of nosebleed at the same period at which headache occurs in the beginning of infectious diseases inclines us to believe that vasomotor changes rather than purely toxic influences are at work. In typhoid fever this is all the more probable because the headache and vertigo are apt to decrease in the second and third week of the disease, when the general manifestations of what we call toxemia are at their height.

There can be no doubt that this illness was typhoid fever, but it should be specially noted, as a point of great rarity, that the white cells were slightly elevated during the whole of his fever. This probably does not occur more than once in a thousand cases, if so often. But for the finding of typhoid bacilli in the urine one might

be almost disposed to doubt the diagnosis of typhoid because of the elevated leukocyte count.

Case 47

A hack driver of forty-three, born in Russia, entered the hospital January 9, 1905. For the past eight months the patient has had a full feeling in his head. On attempting any exertion he becomes dizzy and feels as if he would fall. During the same period he has had buzzing and roaring in his left ear or sometimes a noise like a bell, and did not hear well. In other respects he feels perfectly well, but he has fallen twice in six months owing to vertigo. He always falls to the right.

Physical examination is negative save as relates to the ears, which show evidence of labyrinthine disease. Romberg's sign absent.

Discussion.—This case illustrates a typical Ménière's complex (not Ménière's disease), which in this case depends upon definite disease of the labyrinth. The diagnosis depends upon a lack of evidence for any other cause of vertigo and the presence of a labyrinthine disease, as determined by an expert.

Outcome.—The patient was transferred to the Eye and Ear Infirmary, where diagnosis of labyrinthine disease was confirmed.

Case 48

A sailor and marketman of thirty-two entered the hospital March 11, 1905. The patient has been in the habit of taking three whiskies a day, occasionally one before breakfast. He had gonorrhea ten years ago, soft chancres eight years ago, and erysipelas of the face five years ago. In the past six months he has been troubled by dizzy spells, occurring at least once a day and lasting a few minutes, especially when he rises suddenly from a chair or goes from a hot room into the open air. He is obliged to sit down when the attacks come, otherwise he would fall. During the attacks he is conscious, but his limbs, he says, are in clonic spasm. There is no involuntary micturition and in a couple of minutes he is perfectly well and laughing at himself.

For six months he has noticed dyspnea, palpitation, and edema of the legs after exertion, and for three months there has been discoloration of the lower part of the legs. All winter he has found it very difficult to get warm and he never sweats except in a Turkish bath. During the last six months his color has been changing, so that his friends have nicknamed him "the Jap." For two weeks he

has been unable to work on account of weakness, yet he seems to feel better when exercising. His appetite is good, his bowels regular, his sleep restless. He often passes urine involuntarily at night.

Physical examination shows marked pallor of the skin and mucous membranes. There is a systolic murmur audible all over the precordia, not associated with other abnormalities of the heart. There is soft edema of the lower legs and marked varicose veins on both of them. Otherwise physical examination is negative. The blood shows red cells, 2,428,000; white cells, 3400; hemoglobin, 50 per cent. Stained specimen shows well-marked achromia, but no other changes

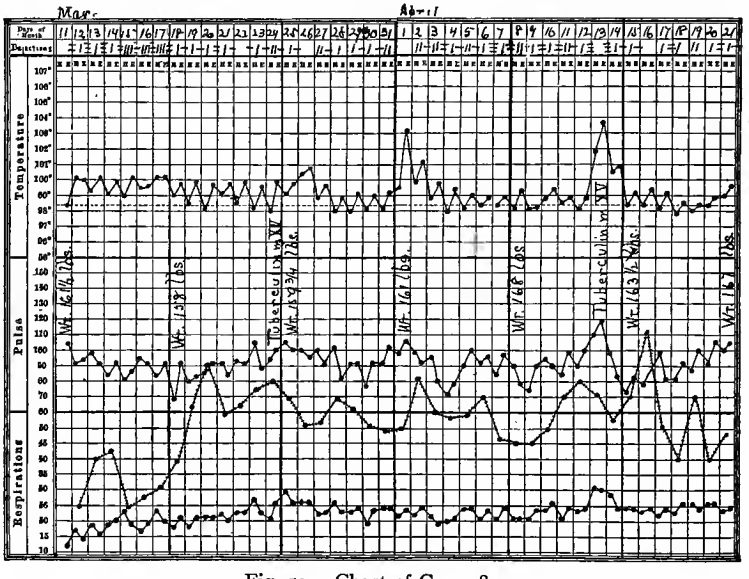

Fig. 59.—Chart of Case 48.

in the red cells. Differential count normal. The urine averages 60 ounces in twenty-four hours; specific gravity, 1009 to 1012; no albumin; a rare hyaline cast in the sediment. On the 15th of March it is noticed that his spleen is palpable and he has been having a good deal of nosebleed. Examination of the ears shows no explanation of the dizziness. The temperature is seen in the accompanying chart (Fig. 59).

The bowels were very loose during the first and last week of his stay, at other times they were normal. A few darkened spots were found on the mucous membrane of the mouth and about the scrotum. On the 26th of March he seemed to be a little browner, but felt better and stronger. There was no reaction to tuberculin. The blood-

count had risen to 2,872,000. The red cells showed marked achromia and deformities in shape, otherwise the blood was as before. The stools were negative. There was no incontinence of urine after entering the hospital, and that previously mentioned was probably due to drinking heavily. On the 2d of April the patient was again given tuberculin, and fourteen hours later showed a rapid rise in temperature to 104° F., followed by rapid lysis. On the 12th of April the patient seemed to be stronger and had gained 10 pounds in four weeks, but his blood-count showed, April 15th, red cells, 1,976,000; otherwise it was as before. He left the hospital on the 22d of April.

Summary of subsequent out-patient records: April 27, 1905, Well except for lame back. ℞. Straps.

May 4th. Feels "elegant"—active, lively, 3 to 4 mile walk today. Before entrance much dyspnea, now none. Vertigo only when he first gets up. Much improved in this respect. Appetite, bowels, and sleep O. K. Not at work yet. Color still poor. Weight, 184 pounds. Hemoglobin, 55 per cent. Reds, 3,456,000; whites, 6800. Achromia, small-sized red cells, slight deformities, and increased blood-plates. No blasts or stippling. Normal differential count.

Discussion.—I have introduced this case because it seems to me one of great interest, although the diagnosis is by no means clear. The essential features of the case are as follows: Marked secondary anemia associated with enlargement of the spleen, evidence of cardiac weakness, vertigo, a brownish color to the uncovered parts of the skin, and a negative tuberculin reaction, all these symptoms in an alcoholic patient who very possibly has had syphilis.

Addison's disease must, of course, be considered, and it is impossible to say that Addison's disease never gets well and to deny the possible correctness of that diagnosis in this case because the patient apparently recovered or, at any rate, greatly improved. It is greatly to be regretted that we have no measurements of blood-pressure. Were a strikingly low pressure recorded—75 mm. Hg. or lower for the systolic pressure—evidence of Addison's disease would be strengthened. The presence of pigmentation within the mouth is of special importance as further strengthening this diagnosis. On the other hand, the negative tuberculin reaction, and especially the fact that two subcutaneous injections of a large dose of tuberculin were borne so well by the patient, militates against the diagnosis of Addison's disease. Such injections are very dangerous, and in at least two instances known to me have been followed immediately by death.

They should never be given in any case of suspected Addison's disease.

Syphilis must certainly be considered and might account for all the symptoms in the case. It has been often noticed that vertigo is a frequent and early symptom in cases of syphilis affecting the brain, and there is a great deal in this case to suggest organic brain disease, especially the clonic spasms of the limbs, the involuntary micturition at night, and the causeless anemia which, in a man of his age and especially in a sailor, is more often due to syphilis than to any other disease. It is greatly to be regretted that no Wassermann reaction was done. As far as I know he received no antisyphilitic treatment, but the fact that he nevertheless improved does not invalidate the diagnosis of possible syphilis. A good many similar cases are on record.

Since the anemia was associated in this case with splenic enlargement, we are forced to consider the complex called splenic anemia as a possible explanation of his symptoms, but this would necessitate neglecting altogether the cerebral aspects of the case, and would make it improbable that so prompt an improvement should occur.

Outcome.—November 10, 1905. Feels first rate. Notices some loss of strength in legs. Appetite good. Bowels move daily. Comes to hospital for eczema on legs.

Case 49

An Irish laborer of sixty entered the hospital July 12, 1905. Three days ago the patient was exposed to very hot weather, and his head became so dizzy that he did not know what he was doing part of the time, yet he did not give up work, and next day felt well. At noon today, after working in the sun all the morning, he again began to be dizzy, and finally could not see and lost consciousness. He was brought to the hospital in coma, with stertorous breathing.

On physical examination the left pupil was larger than the right; both reacted normally. Coma was complete. The internal viscera showed nothing abnormal. The temperature was 104.4° F.; pulse, 112; respiration, 40. The plantar reflexes were normal, the others not obtained. The urine showed a very slight trace of albumin, but was otherwise negative, as was the blood.

Discussion.—Although we do not understand the pathogenesis of sunstroke, we have reason to believe that the temperature is excessively elevated, not only in the places at which we can measure it,

but within the semicircular canals and everywhere else. It has been well established experimentally that caloric stimulation of the internal ear, such as might be produced by hot syringing of the external ear or otherwise, is prone to produce vertigo.

Most cases of sunstroke, if we are so fortunate as to obtain a good history, are preceded by vertigo which may last for minutes or for hours, and should warn the patient that he is in danger. Such premonitory symptoms, like sunstroke itself, are much more frequent in alcoholic patients. One rarely sees a case of sunstroke not previously weakened by alcoholic or some other deleterious influence.

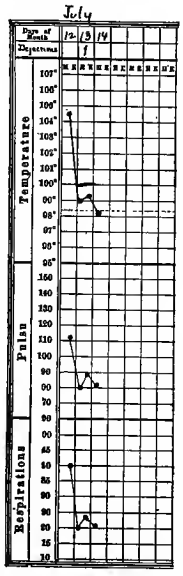

Fig. 60.—Chart of Case 49.

Outcome.—After a cold bath he became conscious and the temperature dropped, as shown in the accompanying chart (Fig. 60). He rapidly convalesced and left the hospital on the second day.

Case 50

An Irish laborer of forty entered the hospital June 5, 1907. His family history and past history are negative. The patient has been a hard drinker for many years. For the past two years he has taken nearly a quart of whisky a day. He had a touch of the "horrors" five years ago. For two years his eyesight has been failing, and nine months ago he had to stop work on this account. Since then "he has had dry heaves in the morning" and has lost strength.

For seven months he has had frequent dizzy spells, which are now his main complaint. For five months his hands and feet have been swollen, and occasionally his face has been puffy. For a month he has eaten irregularly and little, has drank heavily, and been very fidgety.

Physical examination shows good nutrition, extreme motor restlessness, marked tremor of the hands and lips. Pupils, glands, and reflexes are normal. Chest negative. The abdomen is distended and shows shifting dulness in the flanks, but no other abnormality. There is slight edema of the feet. Urine, 25 ounces

in twenty-four hours; specific gravity, 1016; very slight trace of albumin, and a very rare hyaline cast. Systolic blood-pressure 128 mm. Hg. Blood negative. Examination of the fundi shows optic atrophy in the temporal half of each disk.

Discussion.—On the hospital record the diagnosis of this case stands as "alcoholism," and it may well be that no other diagnosis is possible with the known facts, but we have every reason to believe that he has some severe circulatory disturbances in the portal system, presumably cirrhosis, and the bitemporal atrophy of the optic disks makes us very suspicious of some organic cerebral lesion, possibly arteriosclerosis or gumma. Internal pachymeningitis is also a possibility, but we have no way of coming to any closer certainty in the matter. As regards the supposed connection between alcoholism and vertigo, it is notable that although this patient has been a hard drinker for many years and has taken a quart of whisky a day for two years, he had no vertigo until the past seven months. These facts strongly suggest that some organic lesion, something other than the purely toxic effects of alcohol, has been at work since he began to be dizzy.

Outcome.—Within a few days he had lost his nervousness and tremor; he liked the hospital as a hotel, but did not seem to need it in other respects. He was allowed to go home on the 13th.

Case 51

An Italian shoemaker of forty-one enters the hospital January 29, 1908. About two years ago the patient began to be dizzy, at times drowsy, and at other times to have cramp-like muscular pains. He was in the Boston City Hospital for three months without great improvement. Nevertheless, he has been able to do less and less work since that time, and for the last nine months has done none at all. Nocturia, 1 to 2, has been present for years, but in the last seven months has increased to 4 or 5. He has no headache, no vomiting, dyspnea, or edema, but for six months his eyesight has been failing. His family history and past history are entirely negative.

The man is poorly nourished and has a funnel breast. Cardiac apex extends $\frac{3}{4}$ inch outside the nipple, in the fifth interspace. There is no increase of dulness to the right. At the base there is a faint systolic murmur. There are no other abnormalities. The artery walls seem to be thickened. Systolic blood-pressure is 205. Lungs and abdomen are negative. Blood is normal. The urine is 35 ounces in twenty-four hours; specific gravity, 1013; a trace of albumin; a few

hyaline and granular casts. Retinal examination shows hemorrhages on each side. During his four days' stay in the ward he felt perfectly able to work and had no symptoms except failing vision.

Discussion.—Although we do not understand precisely what is the relation between vertigo and high blood-pressure, we cannot doubt that there is some such relation. Not every case of hypertension suffers from vertigo, but a considerable percentage of such cases do suffer in this way, and that percentage is about the same whether the cause of the vertigo and hypertension resides wholly in the kidney or not.

In the present case everything points to the presence of a chronic glomerular nephritis. The age, the long-standing nocturia, the enlarged heart and high blood-pressure, the condition of the urine, and retinal hemorrhages—all point in the same direction.

Case 52

An Irish laborer of twenty-seven entered the hospital July 9, 1909. The patient has a good family history and past history, though he has been treated in the Out-patient Department for two months for psoriasis.

Five weeks ago he began to have constant vertigo, day and night, so severe that he was unable to walk without staggering. This vertigo was accompanied by headache, especially on the right side of the head and in the right eye. It came usually at 8 P. M., lasted a week, did not disturb sleep. After that it shifted to the left side of the head and the left eye for a week. For the past fortnight he has had no headache and his vertigo has been much less severe, so that he can walk without difficulty. He has never fallen and has no spasms or convulsions, though occasionally his left hand trembles a little. For the past month his eyesight has been poorer than usual, but lately is improving again. The cessation of his headaches was coincident with the beginning of hydrotherapeutic procedures two weeks ago. He has no deafness and no other symptoms except those above mentioned. His appetite and digestion are good and his bowels regular.

Save for the areas of psoriasis, physical examination is negative. Temperature, blood, and urine were normal throughout. The fundus oculi also normal. Under encouragement, hydrotherapy, and static electricity he did very well, but on the 21st of July the Wassermann reaction was found to be positive. Nevertheless, he was discharged the same day.

Discussion.—This case was diagnosed as one of "hysteria" at

the hospital, but in view of the positive Wassermann reaction this diagnosis seems to me improbable. Of course, it is perfectly possible for hysteria to exist in an Irish laborer of twenty-seven, but such a coincidence is certainly infrequent, and as we know that vertigo is a frequent accompaniment of various stages of syphilitic infection, it seems much more reasonable to explain this patient's dizziness as due to some cerebral change dependent upon the activities of the Spirochæta pallida. The chief reasons for the diagnosis of hysteria seem to be the improvement of the patient following encouragement, hydrotherapy, and static electricity, but this improvement may well have been a coincidence. I am inclined to think that such was the case.

Outcome.—August 20th he was walking better and improving generally. Soon after he returned to Ireland and was lost sight of.

Case 53

An Armenian laborer of seventy-one entered the hospital September 29, 1909. Six months ago the patient began to have pain in his neck and the back of his head, gradually extending to the forehead, though it was still in the back of the neck. The pain is continuous and accompanied by occasional dizzy spells, with ringing in the left ear. Turning his head causes pain in the right side of his neck. He has no other symptoms, and has never been sick before except for an attack of rheumatism, two years ago, which confined him to bed two months.

Visceral examination was negative except that deep pressure in the right flank during inspiration was slightly painful. The knee-jerks were increased. There was no stiffness of the neck, no disturbances of sensation. The right pupil was circular and reacted normally. The left eye was glass. The fundus oculi showed optic neuritis, the disk border completely obliterated, and moderate prominence of the disk surface. There was a very little exudate, but numerous hemorrhages extending from the upper inner quarter out into the adjacent retina. The headache persisted (though there was no vomiting) until the 6th of October, when, without preceding nausea, he suddenly emptied his stomach. Lumbar puncture showed clear fluid under no excessive pressure and with no increase of cellular content. Wassermann reaction was negative. Under two weeks of antisyphilitic treatment the patient did not improve at all.

Discussion.—Brain tumor is unusual at the age of seventy-one. We should make every effort in a case presenting cerebral symptoms

at this age to explain them as results of arteriosclerosis or syphilis; but in this patient the negative results of the Wassermann test, the lumbar puncture, and the antisyphilitic treatment make it improbable that he is suffering from syphilis.

In favor of brain tumor are headache, vertigo, cerebral vomiting, and the double optic neuritis.

Outcome.—October 15th the skull was first opened in the right temporoparietal region. When the outer table was penetrated and before the skull was opened the patient stopped breathing. His pulse was of good quality, and artificial respiration was done for about half an hour without improvement in the power of spontaneous respiration. The wound was then closed and artificial respiration continued steadily for six hours, during which period his color remained good, but his pulse gradually weakened until his heart stopped. Autopsy No. 2464 showed cyst of the cerebellum with old hemorrhage into it, internal hydrocephalus, arteriosclerosis of the coronary arteries, and hemorrhagic edema of the lungs.

Case 54

A bartender of thirty-four entered the hospital January 22, 1910. Family history was negative. Ten years ago he had what was called "syphilis" and was under treatment two or three years. Three years ago he had severe headache for two or three weeks. After glasses were fitted the headache ceased and has rarely troubled him since until last fall, when he began to have pain at the nape of the neck, always worse at night, and usually confined to the nape, but occasionally affecting the left side or the forehead.

December 10, 1909, the pain was so severe that he stopped work. For the week succeeding that time he was very dizzy, vomited frequently, and had cramps and numb feelings in his right arm, leg, and the right side of his face. About this time he was almost blind for three days, after which his sight improved. The headache continued, and five days ago he had another bad attack of vertigo and vomiting and lost power over the right side of his body. The next three days he was blind, but all of these symptoms have now cleared up, though he still has some headache and does not see well. His sleep has been poor for six weeks and he has had no appetite for a week.

On physical examination the patient was well nourished, the left pupil larger than the right, both reacting normally. There was no glandular enlargement and the tongue came out straight. Visceral examination was normal. There was a slight loss of power in the

right arm and leg, but no paralysis. The fundi were perfectly normal. Dr. James J. Putnam, who saw him on the 24th, thought the hemiplegia might be functional. He found some paresthesia of the right hand, arm, leg, and the right side of the face, and slight ataxia of both arms, especially the right.

Discussion.—The essentials of the history in this case are a syphilitic infection ten years earlier, a headache of three years' duration, apparently relieved at first by glasses, but recently returning; then one month ago, vertigo, vomiting, paresthesia, and, later, hemiplegia on the right side, with poor eyesight for three days.

In a patient of thirty-four it seems unreasonable to explain these symptoms as a result of arteriosclerosis unless we are perfectly certain that we cannot refer them to syphilis. With so much in this patient's history that suggests syphilis, it seems to me that treatment must be based on this belief.

We may admit that cerebral tumor or abscess might produce the same troubles, but the negative fundus is against both of these diagnoses. In point of fact, what we really recognize by the symptom group presented in this case is the presence of increased intracranial pressure and of some focal lesion such as can produce partial hemiplegia. Beyond this, our reasoning to more exact diagnosis must be based upon our statistical knowledge of a relative frequency of the diseases capable of causing such a group of symptoms in a bartender of thirty-four.

Outcome.—Within a few days after this he began to show marked improvement under antisyphilitic remedies. His headache was much less and he was up and about the ward. At no time was there any abnormality about his temperature, pulse, respiration, blood-pressure, blood, or urine. He gained 5 pounds during his ten days in the hospital and went home on the 2d of February.

Two years later he reported, looking and feeling perfectly well. He had had two bad attacks in the past summer, with nausea and blindness, lasting two hours, and one still worse attack in August, 1911, when he was unconscious for thirty-six hours. His vertigo is now practically gone, but it is noticeable that as he gives the foregoing account he stumbles now and then in his speech. Perhaps paresis is developing.

Case 55

A mill operative of twenty-six, born in Russia, entered the hospital March 14, 1910. The patient was sent in from the Out-patient Department (No. 154,217) for vertigo and staggering gait. Cerebral

tumor, syphilis, and ear disease had been considered as diagnoses. The patient's family history and past history were negative.

The patient has had dizzy spells for five months, and says she has had headache night and day for three months. She now cannot walk alone. There has been no vomiting, and her eyes and ears do not trouble her.

Physical examination showed good nutrition, slight pallor, pupils slightly irregular, but reacting normally. Visceral examination was negative, but the patient could not stand with the feet together and the eyes shut, and walked with a very unsteady gait. The plantars and knee-jerks were normal. The fundus oculi normal. Ears negative. Wassermann positive. Dr. J. J. Putnam considered it tumor of the cerebellum. By April 12th she was able to walk with only a little assistance. In the meantime mercurial inunctions had been given daily, and 20 gr. potassium iodid, three times a day. The stools showed many eggs of the Trichiuris trichiura. The blood showed slight achromia and some variations in size and shape, otherwise nothing abnormal. Systolic blood-pressure, 155. The fever during first week in the hospital was as seen in the accompanying chart (Fig. 61). After that it was normal. Blood and urine normal. Studied in the neurologic wards, it was found that the patient would stand if she were scolded, but if not scolded she would sway and tend to fall to the left. She remained there three weeks and left with the diagnosis of "debility." At the time of discharge nothing abnormal could be found.

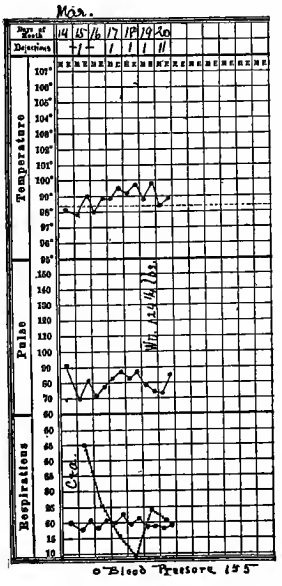

Fig. 61.—Chart of Case 55.

Discussion.—On the hospital records the diagnosis of this case stands as "debility." This diagnosis was made four years ago, and I cannot believe that anyone would consider it justified today. Apparently the idea that this patient had no organic disease was based upon the fact that she stood without swaying when they scolded her, and could not stand so unless they scolded her. But this only gives the proof that there may be a functional and psychic element in the case of a person suffering from severe organic disease.

To me it seems tolerably obvious that when a woman of twenty-six has a blood-pressure of 155, a slight anemia, a positive Wassermann reaction, and has suffered for five months with headache, vertigo, and ataxia, we should make a diagnosis of syphilitic disease affecting some part of the brain, presumably the meninges, possibly the arteries. Certainly she should be treated upon this basis, though brain tumor cannot be excluded. Apparently no careful tests of labyrinthine function were made.

I wish to express here my conviction that a great many bad mistakes are made in the management of cases of illness because we have in our minds a hard-and-fast alternative. The patient before us must, we say, have either an organic disease, a functional disease, or no disease at all. But it seems to me most important to recognize that the patient with indubitable anatomic changes in one or another organ may also have, on top of this, a variety of symptoms which are essentially functional or mental and can be removed by change in environment, in the patient's point of view, or by anything that instils hope. I have in mind a case of tabes dorsalis following a known syphilitic infection; the patient had Argyll-Robertson pupils, absent knee-jerks, Romberg's sign, lancinating pains, and some disturbances in the sphincters, but, in addition to these troubles, he was obsessed with the idea that he could never work or walk again, that he was a useless encumberer of the earth, and forever disgraced. When these ideas were expelled from his mind and a good job was found for him, he lost his pains altogether, became able to walk as well as any one else, gained 20 pounds in weight, and is today a picture of health and happiness, although he has his tabes and always will have it, and although his pupils and knee-jerks are as abnormal as ever.

The lesson taught by this case should always be remembered at the outset of our treatment, and especially of our prognosis, in cases of incurable organic disease. Recognizing that we cannot cure the latter, we must remember that there is no limit to the amount of functional and curable trouble which might be superimposed upon and mixed up with the underlying trouble. Recognizing frankly that we cannot cure the disease, we may yet hope to cure the patient of most of the troubles which torture him. It is here that quacks and irregular practitioners of various types score their successes in patients "given up by regular physicians."

Outcome.—December 28, 1912, a letter received from a friend states that the patient returned to Russia, and has been better during the summer and worse in the winter, since leaving this country.

Case 56

A brick-mason of fifty-six entered the hospital February 28, 1910. The patient was sent in from the Out-patient Department with a diagnosis of "general paresis" or "cerebral syphilis." One paternal uncle died insane; otherwise the patient's family history is excellent and he has three healthy children. Three weeks ago he had an abscess in the region of the anus; otherwise he has considered himself entirely well. Last September his mother, with whom he has lived, died, leaving him only a quarter of her property. This resulted in litigation which has continued ever since. Since last October he has noticed a girdle sensation about his waist and he has been short of breath, but considered himself fairly well until three weeks ago, when he began to stagger in his gait on account of dizziness, and this symptom has rapidly become aggravated since. At present he gropes about upon his feet as if he were blind. Twelve days ago he began to vomit profusely, and ten days ago he began to talk in a rambling manner, turning rapidly and irrationally from one subject to another. In the last two days his friends say there is no sense in what he says, but he has had no hallucinations or illusions. His head feels full, but does not ache. He seems listless and sleepy, but has not been in bed, though he gave up work three weeks ago.

Physical examination showed poor nutrition, good color, and slight puffiness under the eyes. The pupils were oval in outline, irregular, the left greater than the right. They reacted fairly well to light, but better to distance. The tongue showed no tremor or deviation. The heart's apex extended $1\frac{1}{2}$ cm. to the left of the nipple. The right border 4 cm. from midsternum. No murmurs or accentuations. Slight dulness and diminished breath sounds were detected at the base of the right lung behind. Otherwise the lungs were normal; likewise the abdomen. At the top of the right testis a small nodular mass was felt, and on the front of the scrotum there were a few soft yellow areas, surrounded by an infiltrated reddened zone. Knee-jerks were sluggish and there was a suggestion of Babinski's reaction on each side. No clonus. Double Kernig sign. Gait very unsteady. Neck somewhat stiff.

White cells, 12,500; hemoglobin, 90 per cent. Urine 1018 in specific gravity, with the slightest possible trace of albumin and with an occasional hyaline or fine granular cast. Systolic blood-pressure, 145. Temperature as seen in the accompanying chart (Fig. 62). The fundus oculi was normal.

The patient's handwriting was very poor and he often made meaningless signs. March 1st lumbar puncture was done, and about 10 c.c. of clear colorless fluid was obtained under slightly increased pressure. The fluid reduced Fehling's solution, did not clot, was negative on culture, and showed in the sediment only a rare lymphocyte. *The Wassermann reaction was positive.* On March 3d ptosis of the left eyelid appeared. On the 4th the left pupil became larger than the right.

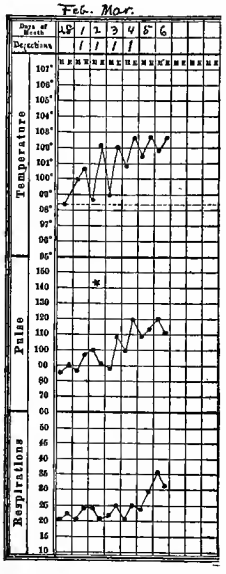

Fig. 62.—Chart of Case 56.

Discussion.—The gist of this case seems to be that the patient has suffered from vertigo, ataxia, dyspnea, and a girdle sensation for five months; that for twelve days he has had vomiting and an abnormal mental state characterized by listlessness, stupidity, and rambling talk.

In the physical examination part of the findings suggest a tuberculous process and part a syphilitic. The signs at the base of the right lung, the nodule in the testis, the stiff neck, the fever and Kernig's sign, are what we should expect with a tuberculous process involving the brain and other organs. On the other hand, the condition of the pupils, the sluggish knee-jerks, the positive Wassermann reaction, the speech, and handwriting incline us toward a diagnosis of syphilis.

The ocular ptosis might be explained either by syphilitic or tuberculous meningitis at the base of the brain. The condition of the spinal fluid does not favor either hypothesis.

On the whole, the diagnosis which I favored during the patient's life was syphilis.

Outcome.—He was given vigorous antisyphilitic treatment, but got steadily worse and died on the 7th; in the last twenty-four hours of life there were signs of solidification at the right base. Autopsy No. 2553 showed general miliary tuberculosis, tuberculous meningitis, chronic adhesive pericarditis.

Case 57

A laborer of forty-six entered the hospital May 27, 1910. Vertigo was the patient's chief complaint, and this was first noticed five weeks ago, when it attacked him while at work and was accompanied

by a shaking chill. Since then he has had many such attacks, though he has never fallen or lost consciousness. During the first week of this trouble he vomited much and he has been unable to work since the onset of his symptoms. He has had no edema, no loss of weight.

Physical examination showed a well-nourished, ruddy looking Irishman. Normal pupils and reflexes. Heart's apex extended 1 inch outside the nipple, the right border 1¼ inch from midsternum. The sounds at the apex were irregular in force and frequency; second sound always faint, sometimes inaudible. The heart sounds came in pairs, the first sound of the second pair being less booming and more valvular than the other. With the second of the pair there was a venous pulse in the neck. Systolic blood-pressure, 130 mm. Hg. The apex pulse was very slow at entrance (Fig. 63). Many beats were not transmitted to the wrist. Blood and urine normal. Lungs and abdomen normal. The patient's physician, seen on the 31st, said that he saw the patient April 18th and found his pulse then regular. Dizziness continued even when the patient was lying quietly in bed.

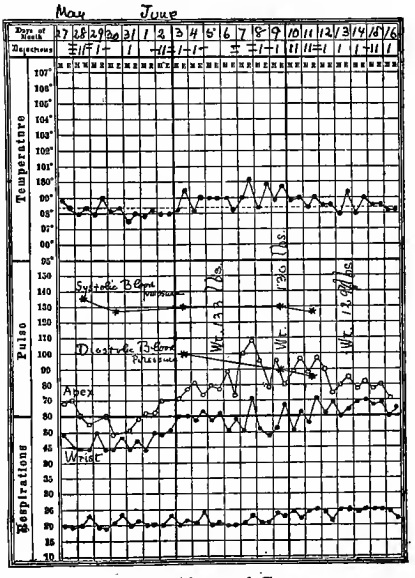

Fig. 63.—Chart of Case 57.

Discussion.—Five weeks' vertigo in a patient with an enlarged, irregular, weak heart and no definite signs of arteriosclerosis, of kidney disease, or of aural trouble, may naturally, I think, be attributed to poor cerebral circulation, local anemia. The only difficulty with this explanation is that the patient's vertigo continued even when he was lying flat in bed. Possibly the very slow pulse may have had something to do with it.

Precisely what the relation is between heart disease and vertigo no one seems to know. A considerable proportion of all these cases of failing heart, probably one-tenth, are more or less troubled with dizziness, but it is not always those with the poorest circulation who have the most vertigo, nor can we associate the giddiness with any single type of heart trouble. It has not seemed to me any commoner

in the elderly than in the young subjects of heart disease. If this impression is true, it militates against the supposition that cerebral arteriosclerosis is at the bottom of the whole thing.

Outcome.—As the pulse-rate rose this dizziness did not seem to disappear, but by the middle of June he felt a good deal better, and on the 16th he was allowed to go home. Throughout his stay in the hospital he had a good deal of headache. Tracings were made from the neck veins, but were not satisfactory. I cannot make a diagnosis in this case, but should suspect that the vertigo is due in some way to poor cerebral circulation.

Case 58

A man of seventy-three enters the hospital June 13, 1910. The patient has lost one brother by tuberculosis; except for this his family history is negative. Thirty years ago he had an attack of inflammatory rheumatism. Otherwise he has been well until the present year. His habits are excellent. A year ago he had to give up work on account of dizziness, which was first noticed five years ago when he started quickly to walk or to rise from a chair. These attacks have increased in severity and frequency since that time and he has fallen unconscious many times. Within the past year he thinks he must have had two hundred attacks, varying from three minutes to three-quarters of an hour in length. He usually has about half a minute's warning, then everything turns black, he sees stars, his head whirls, and he falls unconscious. After the attack he often has a severe general headache, lasting about three-quarters of an hour. He can easily bring on another attack by exertion, and for a year past any such exertion produced considerable dyspnea. Previous to a year ago he could run or make any other severe exertion easily. For ten years he has had nocturia, 2 to 3. He has always been very emotional, and as he told the above story his eyes filled with tears several times.

Physical examination shows a poorly nourished old man, who yet seems young for his age. His pupils are slightly irregular, the right larger than the left, and both react sluggishly. The heart's apex is in the nipple line, fifth space; sounds regular and of good quality. At the apex a loud systolic musical murmur transmitted all over the chest. The pulmonic second sound slightly accentuated. The artery walls are thickened, cord-like, and a few roughnesses are palpable on the right radial. The brachials are tortuous and pulsate laterally. Systolic blood-pressure is 137 mm. Hg.; diastolic, 72 mm. Hg. The second sound, both at the apex and in the second right

interspace, is feeble, but there is no diastolic murmur. The pulse is of the Plateau type. The Wassermann reaction is negative. A radiograph taken at 7 feet shows an aortic shadow, 9 cm. wide, opposite the manubrium.

Discussion.—A good many things in this case suggest a simple senility without definite organic lesion, but an aortic shadow 9 cm. wide cannot be thus explained. The aorta must be either tortuous or dilated, and the condition of the heart and arteries also suggest arteriosclerosis. On the whole, I do not see anything in the case which cannot be explained by arteriosclerosis, though it is a little surprising that his blood-pressure is so low.

The condition of the pupils is such as we often find in arteriosclerotic old men. Whether the arteriosclerosis has anything to do with it or not I do not know. The case might be taken as typical of a very large number in which vertigo is the presenting symptom, and arteriosclerosis is the best diagnosis that we can make.

Outcome.—During a week's stay in the hospital the patient was entirely comfortable and showed nothing abnormal in the ears, blood, and urine. He had headache almost daily, and on the 20th was allowed to go home.

Case 59

A steamfitter of thirty-four entered the hospital June 24, 1910. His family history is negative and he has never been sick until within a year. In February, 1910, he had "the grip" and was in bed a week. Since that time he thinks he has not been as strong and has had a slight cough, off and on, but has had no definite symptoms until twelve days ago.

Twelve days ago, while threading a pipe, he was suddenly taken with weakness, dizziness, faintness, together with shortness of breath. He had to give up work and has had more or less similar trouble ever since, associated with a rather sharp pain in the region of the navel, coming once or twice a day, usually about four hours after meals and lasting four or five minutes. This pain usually causes vomiting and is relieved by it. He has seen no blood in the vomitus or in the stools. He has lost about 25 pounds in four months, but worked until about a week ago.

On physical examination the patient's face was tanned and he looked healthy. There was no lead line; pupils and reflexes normal; internal viscera normal. Blood and urine not remarkable. Systolic blood-pressure, 90 mm. Hg. Temperature, pulse, and respiration

normal during five weeks' observation. Guaiac reaction negative in ten examinations, positive in one. The patient vomited almost every day until July 3d, no cause for the vomiting being apparent. Blood-pressure continued between 80 and 90, more often at the lower figure during the first three weeks of his stay. Later it rose somewhat, so that by the end of July it ranged about 100. The skin tuberculin test was positive. After the 3d of July he ceased vomiting and gradually gained strength. On the 18th the stomach-tube was passed, but no fasting contents obtained. After a test-meal the gastric contents showed no hydrochloric acid and a moderately strong reaction to guaiac. The capacity of the stomach could not be ascertained. The Wassermann reaction was negative.

During his first week in the hospital the patient lost 5 pounds, but after that time held his weight steadily, and on the 28th of July left the hospital, much relieved.

He re-entered on the 11th of August, 1910, after being at the Waverley Convalescent Home in the interim. At this time he remembered that in the previous April and May he had been so thirsty that he drank 5 gallons of water a day when working. Nevertheless he says that up to June 10th he was reputed the strongest man in his shop. This time it was noticed that the skin of his axillæ and groins was pigmented and the mucous membranes of his lips as well. On the hard palate a few fine pigmented spots were also noticed. Otherwise the physical examination was essentially as before. He could eat nothing but crackers and milk, and vomited that occasionally. On the 12th he had a severe attack of abdominal cramps, doubling him up, and relieved only by morphin. The pain was in the center of the abdomen and did not radiate. He remembers that he had an attack like this five years ago, but none so severe since. At that time he was exposed to lead and one of his fellow-workmen had lead-poisoning.

Discussion.—From a history like this, duodenal ulcer is perhaps the first thought that enters our minds. The sudden attack of faintness while at work might be due to a hemorrhage, the blood passing into the bowel, but the continuous vomiting and low blood-pressure in a patient completely at rest and not suffering any further hemorrhage (if, indeed, any has occurred) is not characteristic of peptic ulcer. The negative physical examination does not incline us either for or against a peptic ulcer, since in the majority of ulcer cases physical examination shows nothing of any importance.

At the time of his second entrance the evidence of pigmenta-

tion, especially in the mouth, becomes important. Taking this in connection with the low blood-pressure, the cardiac and gastric symptoms unexplained by any obvious cardiac or gastric lesion, Addison's disease seems probable.

Lead-poisoning, however, must be seriously considered. The cramps of which this patient complains are fairly typical of lead-colic, and his occupation is one which might well expose him to the absorption of lead. But lead-poisoning, when it affects the blood-pressure at all, is apt to raise it. Moreover, when a patient is put at rest and all possibility of lead absorption is stopped, he almost always shows prompt improvement. There was no such gain in this case. Yet the absence of lead line and of stippling in the blood does not exclude lead-poisoning. This is a matter of some importance, as many early cases pass unrecognized in our clinics because the physical examination is negative in these two respects.

If Addison's disease is our diagnosis, the vertigo is naturally to be explained as a result of cerebral anemia from low blood-pressure.

Outcome.—At 4 o'clock on the morning of the 13th his respirations became very slow and shallow and soon after he died. Autopsy No. 2657 showed tuberculosis of the adrenal glands. No evidence of tuberculosis elsewhere in the body. Slight chronic pleuritis and pericarditis.

It is notable in this case that so marked a period of improvement took place in a patient who must have been suffering from Addison's disease from the beginning of his symptoms. Addison's disease is often stated to be progressive in its course. This case proves the contrary.

Case 60

An Italian laborer of fifty-nine entered the hospital June 8, 1911. He has previously been well and his family history is good. He began in June, 1910, to suffer from dizzy spells. In the first one he fell and was unconscious half an hour. He has never fainted since, but ever since then has had a tight feeling in the front and left side of the head, with stiffness about the muscles of the neck and some numbness in the neck and back. At times he is also very dizzy or, again, he has failures of memory, or is unable to tell what he is doing on account of a cloudy, peculiar sensation in his head. For the last six months his appetite has not been good and his eyesight has failed somewhat. During the last year there has been some loss of power,

together with pain and numbness in the right arm. Nevertheless, he has worked almost steadily until entrance.

Physical examination shows fair nutrition and marked tanning of the skin. The pupils are equal, circular, and react well to light, but slightly to distance. The left epitrochlear gland is palpable, otherwise there is no glandular enlargement. The heart's impulse extends 1 cm. outside the nipple line, in the fifth space. The sounds are regular, faint, and at the mitral area the first sound is accompanied by a blowing murmur, transmitted over the whole precordia. The aortic second is sharp and greater than the pulmonic second. The tension of the pulse seems to be somewhat increased. The walls not demonstrably thickened. Systolic blood-pressure, 135 mm. Hg. Blood and urine normal. Wassermann reaction negative. Coarse moist râles are heard with inspiration and expiration over both lungs, especially at the right base. The right shoulder seems to be a little stiff. The grip in the right hand is somewhat less strong than in the left. The elbow-jerks and wrist-jerks are obtained on each side and are equal. The knee-jerks and plantars are normal.

Discussion.—The essential points in the case seem to be attacks of vertigo and a cloudy mental state occurring in an old man with increased arm reflexes, peculiar pupils, and diminished power in the right arm. This is the sort of case to which we are accustomed to attach the diagnosis of arteriosclerosis, although we do so wholly on the history. There is nothing in the physical examination to support such a belief. Our course of reasoning is something as follows:

Arteriosclerosis is very frequent in old men. An Italian at fifty-nine is an old man. The symptoms here present might be all caused by arteriosclerosis. Therefore, in the absence of any positive evidence of any other disease, it is best to guide our action in prognosis and treatment upon the hypothesis of arteriosclerosis.

What else could it be? Conceivably it might be dementia paralytica, but we have no positive evidence of that disease, and the pupils, though abnormal, are not those ordinarily associated with cerebral spinal syphilis. The Wassermann reaction is negative, there are no mental changes, and no defect in sphincteric action.

Could it be syphilitic meningitis? Again we have no definite evidence, and such a disease is much less common than arteriosclerosis.

Outcome.—He stayed in the hospital only a few days, and there seemed to be little that we could do for him. He went home on the 13th of June and died at the end of September.

Case 61

A teamster of twenty-four entered the hospital August 12, 1911. Three weeks ago his head began to feel queer, contained a buzzing noise, and felt unsteady. Soon after appeared dizzy spells, so that he could hardly keep his balance while walking, because the objects around him wavered and swam about. He staggers and falls, always to the left. Two weeks ago he had to give up work and go to bed. For ten days he has had frequent severe headaches, beginning in the left frontal region and lasting an hour or so. For five days he has vomited about once a day, without relation to food. The vomiting is preceded and followed for about half an hour by nausea. He has noticed no weakness, no change in sensation.

Physical examination shows good nutrition, pupils normal. Nystagmus. No other ocular defect superficially. Optic atrophy in the right eye. Thorax and abdomen negative. The left plantar reflex absent, the left cremasteric sluggish. Superficial abdominal reflexes not obtained. Other reflexes normal. Blood and urine normal. Blood-pressure, 130 mm. Hg., systolic; 90 mm. Hg., diastolic. No temperature in two weeks' observation. Wassermann reaction negative. Dr. E. W. Taylor suggested aural vertigo; Dr. John Homans, cerebellar tumor. On the 13th the left knee-jerk is found to be more active than the right. On the 16th there is ankle-clonus on the left and a plantar reflex suggesting Babinski. Ankle-jerk increased. The deep reflexes of the left arm increased. Superficial abdominal reflex present on the right; absent on the left. A thorough examination of the ears shows no disease.

Discussion.—A severe headache and vertigo in a patient of twenty-four, unexplained by any simple or obvious cause, makes us think of cerebral tumor. In this case the vertigo is of the aural or cerebellar type, that is, it is associated with staggering in a certain definite direction and always the same direction. Concomitant and reinforcing symptoms are the vomiting, nystagmus, increase of deep reflexes, diminution of the superficial reflexes, and optic atrophy. If the trouble were wholly labyrinthine, many of these symptoms would not be explicable. On the other hand, there are no symptoms in the case that could not be explained by cerebral tumor, and this seems, on the whole, the most reasonable diagnosis. Since localizing symptoms, most of them concern the left side; we may suppose that the trouble is on the right side of the cerebellum.

Outcome.—On the 12th of September the occipital region was de-

compressed with considerable difficulty, as the skull was very thick. While the operation was going on the blood-pressure gradually fell to 85 and the pulse became impalpable. The patient's position was then changed, and the respiration, which had stopped, improved. The exposed dura was tense and bulging, but was not opened. After the operation he did very poorly. While in the ward respiration suddenly became labored and irregular. Cyanosis supervened and the patient died of respiratory failure. Autopsy showed a cholesteatoma in the median line between the two lobes of the cerebellum, but not actually in the cerebellar tissue. The tumor was encapsulated and about the size of a fist.

Case 62

A locomotive inspector of forty-seven entered the hospital November 9, 1911. The patient's mother died at seventy-six of consumption; otherwise the family history is excellent. He takes a glass of whisky once a day and smokes a pipe incessantly. He denies venereal disease.

Ten days ago he felt as well as ever, but as he started to go home from work he suddenly felt weak, light headed, and short of breath. Then came nausea and vomiting, but he reached home, there ate heartily, and went to sleep. He woke very tired, and while walking to work the next day he felt weak and vomited again. While at work that day he had several giddy spells and had to grasp a support to prevent himself from falling. Every day since that time he has had similar experiences and a constant sense of fatigue. He vomits only when walking to or from his work, and he has to walk very slowly. He needs half an hour to cover a distance which he formerly did in ten minutes.

Last night, for the first time, he fell during one of his giddy spells and, being detected in this by his foreman, was sent to the hospital. He did not lose consciousness and had nothing like an aura. He has had no trouble in controlling his sphincters and no fever, but remembers four days ago a heavy sweat. During the ten days of his illness he thinks he has lost 14 pounds.

Physical examination shows a thin, pale man, lying flat without dyspnea, but with slight cyanosis of the mucous membranes. The pupils are circular, equal, and react normally. There is no glandular enlargement and no lead line. Internal viscera negative. Knee-jerks not obtained even with reinforcement. Ankle-jerks slight, but present. The range of the temperature is shown in the accompanying chart (Fig. 64). The urine averaged 45 ounces, with a specific

gravity of 1020, a very slight trace of albumin, and a few hyaline casts. The leukocyte counts are as follows: November 9th, 6000; November 13th, 7000; November 21st, 8000; December 2d, 5500; December 8th, 8500; December 11th, 11,000; December 14th, 8000. The Wassermann reaction is negative; blood culture is also negative. Widal reaction is positive at entrance, but the case did not seem at all typical of typhoid fever, as there is no prostration and no rose spots or splenic enlargement, and the fever is often higher in the morning than at night; in fact, this is the rule during the first week of his stay in the hospital. The Widal reaction is recorded as follows: On the 10th, suggestive; on the 14th, slightly positive; on the 17th,

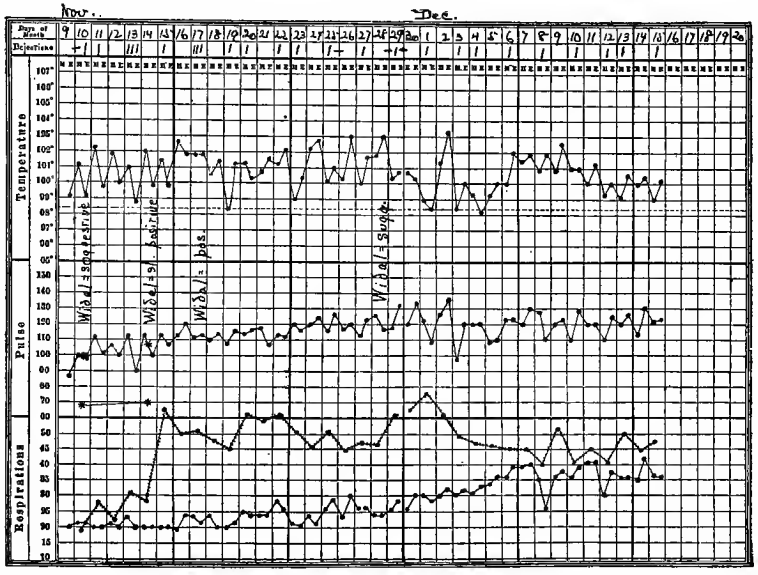

Fig. 64.—Chart of Case 62.

positive; on the 29th, suggestive. On the 29th a few sharply resounding râles were heard at the base of each lung, and from that time on the tendency to hypostasis steadily increased and the respirations rose, but no evidence of solidification was made out. December 14th he seemed to be improving and the outlook for recovery seemed hopeful. At times during this week he had patches of crackling râles in the front of the chest without any signs of solidification and without any persistence in a single site.

Discussion.—The history gives us no light at all on the diagnosis. It is not until we get to the physical examination that it becomes obvious that we are dealing with some sort of an infectious disease,

probably with typhoid fever, since we have a continuous pyrexia, low white count, and positive Widal reaction. Against typhoid we have mainly the fact that the fever is higher in the morning than at night. I do not remember to have ever seen this happen in typhoid fever. On the other hand, I have often seen the temperature higher in the morning than at night in cases of phthisis, and Dr. James A. Honeij has recently reported the same thing in leprosy. The positive signs of typhoid, such as enlarged spleen, rose spots, and typhoid bacilli in the blood-stream, are not present here, but they are, as we know, frequently absent in demonstrable typhoid fever.

Can this patient have a sepsis of any type? There is nothing to suggest it, and no evidence of a focus of infection or of any source from which he could have acquired it. Nevertheless, we must admit that sepsis may occur without our being able to discover any point of entry or any present focus of infection.

Tuberculosis will account for all the symptoms except for the positive Widal reaction. The initial and persistent cyanosis and the rising respirations suggest the miliary form.

As I remember the case, the majority of us considered it one of typhoid, and explained the vertigo as that ordinarily associated with the beginning of an infectious fever.

Outcome.—He died on the 16th. Autopsy showed miliary tuberculosis of the lungs, liver, spleen, and kidneys, solitary tubercle of the small intestine, obsolete tuberculosis of the bronchial lymphatic glands and right lung, chronic pleuritis of the right.

Case 63

A box maker of forty-three entered the hospital November 14, 1911. The patient's father died at eighty-four of gastric cancer. Otherwise the family history is good. The patient denies alcohol and venereal disease, and, though always dizzy, has been well and strong all his life. Sixteen months ago dizzy spells began to bother him increasingly and are now his chief complaint. They begin with a hissing sound in his right ear. A few minutes after this things begin to spin round in the horizontal plane, from left to right. This lasts about two minutes, and unless he sits down or takes hold of some support he invariably twists round from left to right and tumbles upon his right side. The noise in the ear stops immediately before the vertigo does. After an attack he perspires, vomits, and is weak. Within fifteen minutes he is all right again. He never loses consciousness.

The attacks have come at various hours in the daytime, never at night. The early attacks were separated by a week or so, but for the last year he has had them every few days and sometimes two or three in a day.

Eight months ago, after a severe attack, he was semiconscious for some hours, and since then he has not felt able to work and has gradually come to notice a deafness in the right ear.

Three months ago he noticed cloudiness and specks before his eyes when he raised his head after stooping. Glasses gave him no relief, though they improved his vision. He notices, however, that if he takes off his glasses while standing or sitting he sometimes has an attack of vertigo. In fact, this is the only thing that he knows of as capable of bringing on an attack. He has had a few attacks of sharp frontal headache, and for the last three months a feeling of fulness or pressure, almost constant, in the right half of the head.

Every week or so and sometimes for several days in succession he has a discomfort, compared to a sense of a hot stone below his right ribs in front. This comes most often at night and has no relation to meals, but he thinks he can feel a lump in the seat of discomfort at the time of these attacks, which, however, bothers him very little. His bowels are very constipated and require medicine daily. His best weight, eighteen months ago, 122 pounds; now, 112 pounds. He has no further complaints.

Physical examination shows poor nutrition, normal pupils and reflexes, no nystagmus, no abnormalities in the internal viscera, normal blood, urine, and blood-pressure; no fever. The diagnosis at entrance was enteroptosis, with a question of cancer near the cecum. On the 18th he was sent to the Massachusetts Charitable Eye and Ear Infirmary, where examination showed that the hearing in both ears was excellent. Tests for labyrinth disease showed a sluggish reaction in all three directions, but nothing positive enough to point definitely to either ear or to suggest an operation. The Wassermann reaction was negative. The fundus oculi normal. A neurologic consultant believed the case to be Ménière's disease, despite the report of the aural consultant. At the advice of the former, 25 c.c. of spinal fluid was removed by lumbar puncture. The fluid was limpid and came out under moderate pressure. The patient felt immediately relieved from a sense of tightness in the right side of his head and from the sharp pumping in his ear with each heart-beat, but next day he vomited and had a severe attack on getting up. These attacks continued daily, and after the spinal puncture he seemed distinctly

worse, in that a new set of sensations were now complained of, radiating from the point of lumbar puncture. High-frequency electricity and hydrotherapy were given during the last week of his stay in the hospital, whence he was discharged December 31st.

Discussion.—This patient says that he has always been dizzy. A statement like this generally means a neurotic patient, and that, naturally, is our first impression of this case, but when we find that he has the typical Ménière's complex, we may properly doubt our first guess. It must be admitted that Ménière's complex has been shown to exist in patients seemingly free from any aural disease and apparently belonging in the neurotic group. The results of aural examination and of lumbar puncture go to support the idea that we are dealing in this case with what has been called a pseudo-Ménière's complex. This is further suggested by the fact that after lumbar puncture the patient experienced a new set of symptoms, radiating from the point of puncture and apparently due to the strongly unpleasant effect made upon his mind by that operation.

The gastric symptoms may well be interpreted as those of a nervous hypochlorhydria.

Outcome.—June 17, 1914, the patient writes that he is about the same, that he has had several of the dizzy spells, the last four weeks ago. He complains, moreover, of a profuse flow of perspiration in the right side of his head. His appetite is good, weight unchanged, and general health apparently very fair.

Case 64

A housewife of twenty-nine entered the hospital May 13, 1912. For six months the patient has been troubled much by spells of dizziness and by severe temporal headaches. Her eyesight has always been unsatisfactory. For the past week she has been in bed most of the time on account of weakness and sore throat. She has fainted once or twice, and vomited once a week ago. She has four children, living and well, but since the last child has had four miscarriages. In August, 1909, small sores came out upon her arms and legs, and in November a general eruption on the face and neck.

Her appetite, bowels, and sleep are normal. Her hands and feet feel numb a good deal of the time. She has no cough, dyspnea, or edema. For the last two months her menstruation has been absent.

On physical examination the patient is well nourished, drowsy, and slow mentally. She complains and cries out, but cannot locate pain anywhere. The skin shows ichthyosis. The pupils are irreg-

ular, the right larger than the left, both reacting sluggishly to light. The uvula is absent and the surrounding area has a ragged edge. The internal viscera show nothing abnormal and the reflexes are negative. The lower legs are covered with depressed circular scars, 1 to 1½ cm. in diameter, some white, some red, some slightly crusted.

In the wards the patient was constantly distressed by vertigo and headache when not sleeping or drowsing. When spoken to she answered in a weak, high-pitched, whining voice. Her mental processes were slow. The Wassermann reaction was weakly positive.

Discussion.—The history is not in any way definitive. The four miscarriages may well have been self-induced. We cannot justly take them as evidences of syphilis.

But when we come to the physical examination and find Argyll-Robertson pupils, a throat strongly suggestive of syphilitic ulceration, and a weakly positive Wassermann reaction, I do not see how we can fail to believe that syphilis is the most probable diagnosis. The nature of the scars upon the lower legs is not clear from the description here given, but they are perfectly consistent with a diagnosis of syphilis. If this be correct, the vertigo is to be explained as that accompanying the earlier state of an infectious process. Such vertigo is especially common at the beginning of this particular disease, perhaps because it so early involves the cerebral spinal system.

Outcome.—On the 22d and the 28th ½ gram of salvarsan was given intravenously. By the 30th she showed marked improvement, was bright, smiling, free from headache, and eating well. The voice had lost the distressing whine and she was able to sit up all day. On the 3d and 10th of June salvarsan was given as before. On the 11th the soft palate was entirely healed, the Wassermann reaction negative.

Case 65

A machinist of forty-six entered the hospital August 7, 1912. The patient's father died of tuberculosis at sixty-three, otherwise his family history is excellent. The patient had bloody dysentery at eighteen, and for many years has had indigestion, with gas and sour stomach, unless he is careful of his diet. He denies venereal disease. Twenty-seven years ago his hearing began gradually to be impaired and this trouble has progressed until now he is stone deaf. He also has a sense of pressure in his head and noises in his ears, especially during the last few weeks.

For two years he has had occasional attacks of dizziness and vomiting, attributed to and treated for stomach trouble, and never

occurring at his work, but always upon Sundays and holidays. During the last few weeks he has felt light headed a good deal of the time, but without vomiting. He always feels better when lying down, and apparently can sometimes stave off an attack by lying down and going to sleep.

Today, while on a trip to Revere, he was taken, on the electric car, with severe vertigo, so that he staggered like a drunken man. He leaned against a fence and vomited; later he was brought to the hospital.

Physical examination was entirely negative except for the deafness. Urine and blood-pressure were within normal limits. An aural consultant found otosclerosis and considered disease of the labyrinth possible. The Wassermann reaction was negative.

Discussion.—The patient's deafness makes it natural to attribute his vertigo to aural trouble. Why he should have had vertigo at first only on Sundays and holidays I have no idea. People are more apt to overeat and overdrink at these times, and this fact may have led his local physician to treat him for stomach trouble. One may blame the general practitioner in a case like this for giving treatment directed to the stomach when there is good reason to suppose the ears to be at fault, but, after all, we cannot say that any harm results therefrom, since the aural specialist can almost never do anything to benefit the patient, who finds the latter's discouraging prognosis by no means palatable. The patient always prefers to refer the vertigo to his stomach. It is very natural, therefore, to accept his view of things and treat him accordingly. Nevertheless, if we want the truth, we have no right to allow the patient to be without the services of an expert aurist.

Outcome.—For more thorough examination he was transferred to the Eye and Ear Infirmary, where positive evidence of labyrinthitis was found.

CHAPTER III

DIARRHEA

CAUSES AND TYPES OF DIARRHEA IN ADULT LIFE

I UNDERTOOK recently a fresh study of this ancient problem, with the collaboration of Dr. Haven Emerson, of New York, beginning with the necropsy records of Bellevue Hospital in New York and the Massachusetts General Hospital in Boston. In the latter institution I examined 3000 of the necropsy records, searching for lesions ordinarily supposed to produce diarrhea. I then traced the cases showing these lesions back to the clinical records, trying to ascertain first whether the lesions actually produced diarrhea, and if so, in what proportion of cases; second, whether any special type of symptoms or of discharges was associated with any special lesion of the intestine, the endeavor being to mark out clinical types so far as this was possible. Finally, I reviewed the results of treatment both in necropsied cases and in a considerable series of cases which did not come to necropsy, and endeavored to estimate the value of the different methods used.

For various reasons I have excluded from this study certain diseases often associated with diarrhea. I have taken no account of the cases of typhoid fever, partly because the relation of this disease to diarrhea has already been thoroughly studied in large groups of cases, and, second, because I was anxious to get some idea of the relative frequency of the different diseases showing this symptom, and I am well aware that the number of persons sick with typhoid in these two hospitals was not a fair sample of the number of cases of this disease existing in the community outside, since cases of typhoid are quite abnormally collected from large areas in hospitals such as that in which I have pursued my studies. The parasitic diarrheas have also been excluded because of the small number of these cases available in Boston or New York. I have made no effort to study the cases of mercurial or arsenical poisoning or cases of dysentery due to organisms of the Shiga type, or other organisms closely allied to it. I have also excluded all cases occurring in persons under sixteen years of age. Leaving out the types just mentioned, we have left 640 cases of the varieties ranged in Table 1.

TABLE 1.—RELATIVE FREQUENCY OF DISEASES CAUSING DIARRHEA IN ADULTS—MASSACHUSETTS GENERAL HOSPITAL, 1905–1912

Acute enteritis and unknown (acute) causes—clinical cases		244
Acute enteritis—necropsied cases:		
"Primary"	9	
Secondary [with and without intestinal lesions] to:		
Nephritic lesions	10	
Cardiac lesions	2	
Cardiorena lesions	2	
Arteriosclerotic lesions	3	
Acute infectious lesions	5	
Various acute and chronic conditions	10	
Intussusception	1	
		42
Acute enteritis—total		286
Chronic enteritis and unknown (chronic) causes—clinical cases		139
Chronic enteritis, necropsied cases:		
"Primary," *i. e.*, of unknown cause	8	
Secondary to:		
Cardiac	7	
Renal	1	
Cardiorenal	1	
Various chronic conditions	2	
		19
Chronic enteritis—total		158
Cancer of bowel		52
Pernicious anemia		34
Mucous colitis		32
Exophthalmic goiter		25
Nervous diarrhea		17
Tuberculosis of bowel		15
Amebic dysentery		14
Fat intolerance		7
Total		640

DIFFICULTY OF DISTINGUISHING ACUTE FROM CHRONIC ENTERITIS AND COLITIS

It is clearly desirable to distinguish the acute from the chronic cases, but this I have found unexpectedly difficult. The intestine is like the kidney, in that a long-standing disease may show clinical symptoms only now and then, presenting itself suddenly under the guise of an acute disease. Just as the acute exacerbations of chronic nephritis appear under the guise of an acute nephritis, so the acute exacerbations of a chronic colitis (due to amobæ or other causes) often appear with all the evidences of acute disease, run a short course and subside, though we have good reason to suppose that the intestine, like the kidney, remains diseased throughout long symptom-

Relative Frequency of the Common Causes of Diarrhea in Adults

Massachusetts General Hospital, 1905–1912

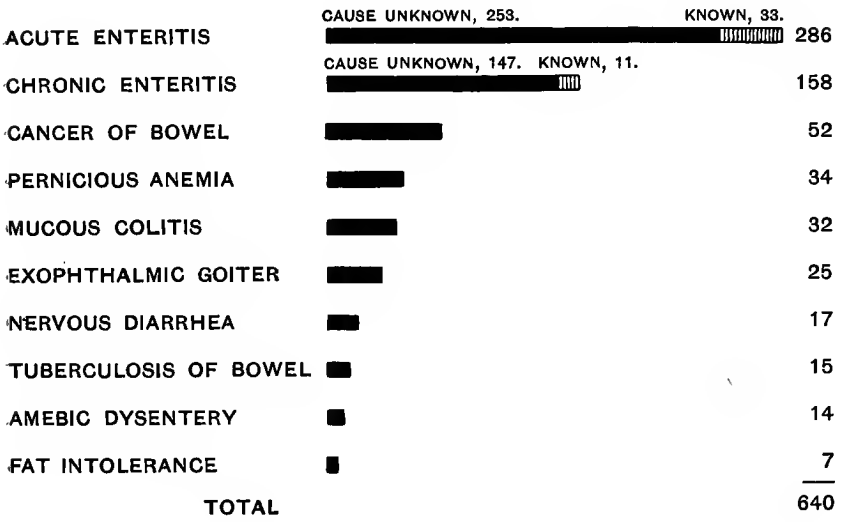

less periods. Only by following individual cases in large numbers and over a long period of time would it be possible to ascertain whether a diarrhea which appears to be evidence of an acute disease is really such, or merely one of the exacerbations of a chronic process. Since I have been unable to follow any large number of cases in this way over a long period, I have not found it possible in this study sharply to separate the acute from the chronic cases.

Further, the attempt to classify all the long-standing diarrheas as due to *organic* intestinal disease and all the acute diarrheas as *functional*, breaks down, both for the reason just indicated and because in some cases a purely functional disturbance hardened into a habit may produce a long-standing diarrhea, though organic disease is demonstrably absent.

CAUSES OF DIARRHEA

"Indiscretions in diet" have long been blamed for a large proportion of the brief diarrheas occurring in adults as well as in children. There is no reason to doubt that these indiscretions are in a certain number of cases responsible, but a careful analysis of the records shows that many patients suffering from precisely the same symptoms as those supposedly due to indiscretions of diet have, in fact, committed no such indiscretions and eaten nothing unusual. These patients are often badgered about dietetic history until some damaging admission about diet is with difficulty extracted from them, the physician feeling it incumbent on him to find something wrong in the diet at all hazards. By leading questions, almost any patient can be induced to assert that he has eaten something unusual or deleterious within a more or less extended period previous to the beginning of his symptoms. But if we are fair and do not try to prejudge the case, we must admit that the number of cases in which faulty diet is obviously the cause of an acute diarrhea is much smaller than is ordinarily supposed.

Among a group of 89 patients suffering from acute benign diarrhea, presenting in the stools no evidence of bowel ulceration and recovering within from ten to fourteen days, 41 patients ascribed the trouble to some supposed indiscretion in diet or to some food believed to have been poisonous, while 48 patients, exhibiting precisely the same symptoms, signs, and course, remembered no dietetic cause for their trouble and, indeed, no obvious cause of any kind.

In but few cases out of this whole series was there any convincing evidence that the patient and other persons had partaken of a certain food and that all were similarly attacked by diarrhea, while other

persons under the same conditions, except for abstention from that particular food, remained well. A study of the clinical records has convinced me that even in the group of cases labeled by the patient or by his physician as due to indiscretion in diet, this diagnosis is often retrospective and made simply for the reason that other cause could not be found.

Ptomain-poisoning is one of the commonest and one of the most popular and fashionable diagnoses of the day among a certain class of practitioners. Yet this diagnosis will seldom stand criticism. Many of the cases to which this name is given turn out to be appendicitis, gall-stones, intestinal obstruction, pancreatitis, a gastric crisis in tabes, lead-poisoning, and other diseases having nothing to do with ptomains. In another group of cases the evidence points simply to an acute diarrhea of unknown origin which is labeled "ptomain-poisoning" presumably because of the impressive sound of the term. The number of cases in which a chemical poison properly to be called a ptomain or leukomain has been isolated from the food taken by the patient is almost negligible. In my series there are no cases at all of this kind. I have not found a single case which deserves the term "ptomain-poisoning," although there were cases in which the diarrhea seemed attributable, with reasonable certainty, to something wrong in the food. In these cases the much vaguer and less high-sounding term of "food poisoning" seems to me more proper.

I have merged in a single group a large number of cases variously designated on the clinical records because there seemed to be no good reason for the employment of the different terms such as dysentery, gastro-enteritis, enterocolitis, colitis, etc. To the same group of cases, now one, now another of these terms is applied without any clear reason, according to the taste and fancy of the individual physician.

In a small group of cases, only 7, in the Massachusetts General Hospital series during a period covering the years from 1895 to date, there has seemed to be a genuine *intolerance* of the intestine *for* one or another foodstuff, chiefly *fat.* Intolerance for a protein or a carbohydrate was very rarely identified, but in the small group of cases previously referred to, an excess of fat was present in the stools on ordinary diet, and when a diet free from fat was given, the diarrhea ceased. In none of these cases was there any definite evidence of pancreatic disease or of any other organic cause for the anomaly; indeed, no cases of diarrhea definitely to be referred to pancreatic disease were studied in this series.

Passive congestion of the intestine is not a cause of diarrhea. This

lesion was present in a large number of the cases of my series in which necropsy was performed, but was seldom associated with diarrhea. Thus in 88 cases of badly compensated cardiac lesions producing death with dropsy and general stasis, only 8 patients had diarrhea at any time. In 7 other cases of general cardiac stasis the intestine showed postmortem the lesions of enteritis, 3 of the ulcerative and 4 of the diphtheric type, but in only one of these 7 cases was there any diarrhea. Among 13 patients with chronic nephritis, dying by cardiac failure with general passive congestion of all the organs, not one had diarrhea. Constipation is the rule in cardiac or cardiorenal disease with stasis.

Tuberculosis of the intestine is a favorite diagnosis among general practitioners confronted by intractable and chronic cases of diarrhea. In my experience such a diagnosis is almost never warranted, for it is likely to be made in patients showing no pulmonary lesions of tuberculosis and despite the well-known fact that tuberculous enteritis almost never occurs except as a complication of phthisis. A striking result of our studies is this: Even when there is a demonstrable tuberculosis of the intestine (complicating pulmonary disease) diarrhea occurs in only 1 case out of 3. Thus in only 10 out of 31 cases of tuberculous enterocolitis which came to necropsy at the Massachusetts General Hospital (32 per cent.) and in only 29 out of 100 similar cases studied postmortem at the Bellevue Hospital (29 per cent.) was diarrhea present. The two series of cases here support each other in a very striking way (Table 2).

TABLE 2.—RELATIVE FREQUENCY OF CERTAIN FATAL DISEASES ASSOCIATED WITH DIARRHEA (6000 NECROPSIES)

Disease.	Bellevue Hospital, 3000 necropsies.		Massachusetts General Hospital, 3000 necropsies.		Per cent. having diarrhea.	
	Total cases.	Number of cases of diarrhea.	Total cases.	Number of cases of diarrhea.	Bellevue Hospital.	Massachusetts Gen. Hospital.
Acute and chronic enteritis (unknown cause)	111[1]	45	71	32	40	45
Cancer of colon	18	4	64	20	22	32
Tuberculosis of intestine	100	29	31	10	29	32
Tuberculosis of the lungs; intestine not diseased	71	11	35	4	15	11

[1] Seventy classified as acute postmortem; 25 of these had diarrhea. Forty-one classified as chronic postmortem; 20 of these had diarrhea.

Even when diarrhea occurs in patients suffering from distinct tuberculosis of the lungs, one is by no means certain that the flux is due to intestinal tuberculosis, for diarrhea is nearly half as common in cases of pulmonary tuberculosis *without* intestinal lesions as in cases *with* these lesions. Thus in 106 cases of pulmonary tuberculosis studied postmortem at the two hospitals referred to, 15, or 14 per cent., had diarrhea, although the intestines showed no lesions whatever. All this emphasizes the fact further to be insisted on that even when intestinal ulcerations are present in a case of diarrhea we are by no means certain that the ulcerations cause the diarrhea.

Cancer of the intestine was studied in 159 patients, postmortem or after operation, at the Massachusetts General Hospital, and in 18 patients postmortem at the Bellevue Hospital. The percentage of diarrhea in these cases, taken as a whole, is almost identical with that found in tuberculous enteritis. Thus 52, or 32 per cent., of the Massachusetts General Hospital cases showed a diarrhea either steadily or intermittently, while 22 per cent. of the Bellevue cases showed the same symptom. Contrary to the accepted idea on this subject, I did not find that diarrhea was any commoner in cases involving the lower part of the intestine than in those involving the upper part. Thus in 43 cases of cancer of the rectum, diarrhea was present in 37 per cent., while in 67 cases involving the hepatic flexure, the ascending colon, or the cecum, diarrhea was present in 41 per cent. In 32 cases involving the intermediate portion of the colon, including the transverse colon, the splenic flexure, and the descending colon (above the sigmoid), diarrhea was present in only 18 per cent.

In *chronic renal disease*, diarrheas of a supposedly compensatory type are often said to occur. My studies did not tend to confirm this supposition, for in 72 cases of chronic nephritis diarrhea was present only 11 times either in the history previous to hospital treatment or during that treatment.

Intussusception has for many years been associated in text-books with a bloody diarrhea and been supposed to differ thereby from other types of intestinal obstruction. This idea was borne out only to a limited extent in the cases studied in the present series, for only 3 out of 10 showed any diarrhea at all.

I have had no opportunity to advance my knowledge on the subject of so-called *morning diarrheas*, the association of which with achylia gastrica has recently been referred to. Such cases are ordinarily too mild to need hospital treatment and, therefore, did not come within my study. My experience, however, with similar cases in

private practice confirms that of others, in that I have frequently found that hydrochloric acid is absent from the gastric contents of such patients. The special treatment of this class of cases will be referred to later.

Closely associated with these, according to my belief, is the type known as nervous diarrhea or simple hyperperistalsis. Presumably, there is some connection here between the hyperperistalsis and low blood-pressure in the peripheral blood-vessels with vasodilatation in the splanchnic area. The feeble rapid heart and the tendency to faintness in such cases goes to strengthen this supposition.

An important group of cases, not very numerous, fortunately for us, but very obstinate and mysterious, are those associated with *intestinal ulceration of unknown cause*. Many of these cases are demonstrably non-amebic and not due to infection by any known type of micro-organism. Some of them bear the marks of infectious disease—fever, leukocytosis, and albuminuria. In others there is no such evidence. The diagnosis is made from the condition of the stools (see hereafter) or by proctoscopy. Sixty cases of ulcerative colitis of this kind were studied at the Massachusetts General Hospital, beginning with the necropsy record and following the case back into the clinical history. One hundred and eleven similar cases were studied at Bellevue Hospital. In 55 per cent. of the Massachusetts General Hospital cases and 60 per cent. of the Bellevue cases diarrhea was absent, and the diagnosis of intestinal ulceration or ulcerative colitis was often quite unsuspected before necropsy. Even when the colon is deeply and universally ulcerated, "hanging in rags," as one of my colleagues expressed it, the bowels may be constipated throughout the disease. Although there is nothing new about this statement, I desire to emphasize it afresh, since there is so strong a tendency to use the words diarrhea and enteritis as synonymous.

In cases of enteritis without diarrhea the diagnosis is, so far as I can see, impossible, unless something suggests proctoscopy. There may be no local tenderness in the abdomen and nothing whatever to indicate the disease. This silence is only what one might have expected from the analogy of typhoidal and tuberculous ulcerations, which produce in the great majority of cases constipation rather than diarrhea. Thus in only 17 per cent. of the 1495 cases of typhoid analyzed in Osler's "Modern Medicine" was diarrhea present, though in every case presumably the intestines were extensively ulcerated. The conditions existing in tuberculous enteritis have already been referred to.

Finally, I would lay especial emphasis on the fact obvious from the study of the cases in this series, that in many, perhaps most, cases of diarrhea the cause is utterly unknown. No evidence of infection, ulceration, food poisoning, cancer, or other disease can be found. In some of these cases we have evidence that the patient has been subjected to unusual overstrain, such as may well have lowered his powers of resistance or upset the vasomotor tone of his splanchnic vessels. Thus, loss of sleep and overwork often appear to be causative factors; but the intermediate steps between these strains and the diarrhea are not clearly known.

TYPES AND DIAGNOSIS

Can we recognize what part of the intestine is affected? Many text-books describe symptom-groups supposed to characterize diarrheas originating in the small intestine and in the large intestine, respectively. I have not been able, however, to identify any diarrheas originating in the small intestine. If there is a characteristic symptomatology for such cases I have not been able to find it. As regards the portion of the colon affected by disease one can say only this: that the presence of marked tenesmus points almost certainly to inflammation of the rectum. Beyond this we cannot go with any certainty.

The *study of the stools* is of much importance, especially in prognosis. Cases in which blood and pus are frequently present in the stools are almost certainly associated with ulcers of the large intestine and run a much more chronic course than those in which blood and pus are absent from the stools. The presence or absence of mucus in the stools seems to be of little importance, especially when there is no other abnormality. Mucus is not proper ground for the inference that enteritis or ulceration is present. In many persons mucus is passed from time to time without any disturbance of the general health and without any known reason whatever.

An *excess of fat, starch, or protein in the stools* is much less often of value in diagnosis or prognosis than the evidences of ulceration just referred to. In the routine examination of stools for causes of diarrhea such an excess of food products is distinctly infrequent and rarely characterizes a case for more than a short time.

Proctoscopy is of great importance in prognosis. The presence or absence of ulceration in the rectum and sigmoid can readily be decided by this method and, other things being equal, a much longer course can safely be predicted in cases showing ulceration of this

kind than in those free from it. Thickening and infiltration of the bowel wall may also be recognized in this way, and may furnish evidence of a long-standing, relatively intractable process. In 9 cases of the Massachusetts General Hospital series the *Amœba histolytica* was recognized in the stools and led to the identification of amebic dysentery. Such cases, however, are rare in Massachusetts even as importations. In parts of the country in which the *Amœba histolytica* is common stool examination may be of the greatest importance as a means of identifying diarrheas of this type, since it may lead to their treatment by the recently discovered specific, emetin.

Diphtheric colitis, or *enterocolitis*, produces no characteristic symptoms and no recognizable abnormalities in the stools. This was proved by the clinical record of diphtheric cases in which necropsy was performed at the Massachusetts General Hospital.

"*Mucous colitis*," or *colica mucosa*, is, in my opinion, not a colitis at all, but a form of neurosis associated with constipation and sometimes with starvation. Of 22 cases of this disease studied at the Massachusetts General Hospital, in only 10 was diarrhea present at any time and, even in those, constipation was much more frequent. As a cause and a result of their neurosis many of these patients have acquired the disastrous habit of examining their stools themselves, and it is almost pathognomonic of the disease if the patient produces a bottle in which curious materials have been accumulated as the result of a minute study of his dejecta. Habit and the mental attitude are the essential factors in these cases.

Prognosis.—The general measure of effectiveness in the treatment of chronic diarrheas of all types may be seen from the following figures drawn from the records of the Massachusetts General Hospital: Out of 90 cases of diarrhea lasting over four weeks previous to hospital treatment, there were apparently cured 54, or 60 per cent., and unrelieved (including deaths) 36, or 40 per cent. We have called the favorable cases "apparently cured" because we have not often been able to follow their progress after discharge from the wards.

Further analysis of the results of treatment in 25 cases of chronic non-fatal diarrhea, averaging about four years in duration, shows that chronicity is not necessarily of bad prognostic import. It was found quite easy to check the process and even to cure it in 12 out of these 25 cases in which organic ulceration and infiltration of the bowel were not indicated by the presence of blood and pus in the stools or by proctoscopy. Chronicity, then, does not necessarily mean intractability.

Our fatal cases have rarely been chronic. They averaged less than four months in duration. In contrast with this were 2 cases diagnosed as nervous diarrhea and yielding readily to suggestive therapeutics, though they had lasted two years and five years, respectively.

Of 13 patients with chronic ulcerative colitis, 5 were apparently cured, 2 were improved, and 6 not improved at all.

Acute Diarrheas.—So far as duration measures severity, the non-ulcerated acute cases, lasting five weeks or less, were as severe as the ulcerated cases. The average duration of 17 ulcerated cases (with blood and pus in the stools) was fourteen days before treatment began and thirty-eight days after treatment. In 21 non-ulcerated cases the average duration was thirteen days before treatment and twelve days after treatment.

The response to our therapeutic endeavors shows that the ulcerated cases were far more intractable. In 17 out of 21 acute non-ulcerated cases the movements ceased promptly after treatment by rest, diet, and catharsis only. Three patients needed also saline irrigations, and one, bismuth. Opium and silver nitrate were never needed in this group of cases.

Of the 17 ulcerated cases, on the other hand, only 2 yielded to rest, diet, and catharsis alone. Three of the 17 patients needed opium also; 5 needed bismuth; 7, silver nitrate, and 8, normal saline irrigations. Three of the 7 patients receiving silver nitrate had saline irrigations as well.

Case 66

A child, four years old, entered the hospital September 9, 1908, with a diagnosis of "subacute appendicitis," made in the Out-patient Department by Dr. Simmons. For nine weeks he had been having diarrhea, six to seven movements a day. Every three or four days he has had an attack of epigastric pain and vomiting. With the earlier attacks the child was feverish. Weight and strength have been failing, though the appetite has been good.

Physical examination showed poor nutrition, good color, normal chest. The right side of the abdomen showed slight dulness and slight rigidity. In the right iliac fossa a soft, indefinite mass, about the size of a lemon, could be made out. It was only slightly tender. The range of the temperature, pulse, and respiration are seen in the accompanying chart (Fig. 65).

Discussion.—Here is a subacute diarrhea of moderate intensity, in a poorly nourished child, showing a mass in the right iliac region

and some fever. The slow course of the disease, the lack of any severe pain, or acute onset are against appendicitis.

Rickets is often accompanied by such a diarrhea, but there are no evidences of rachitic changes in the bones or muscles, and no way of explaining, by this diagnosis, the right iliac mass.

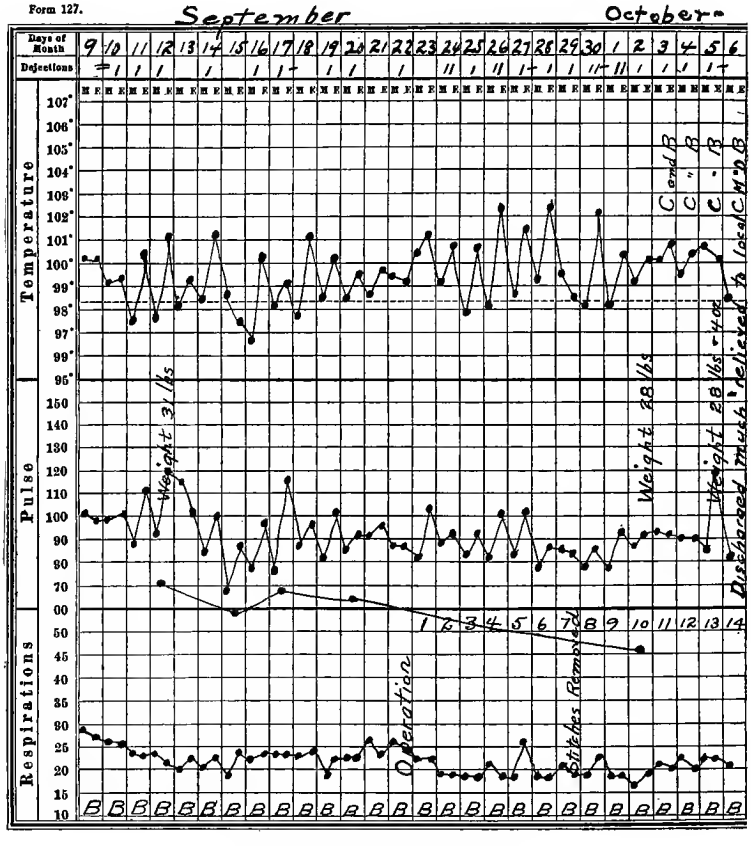

Fig. 65.—Chart of Case 66.

Malignant disease, in a child of this age, rarely involves the right iliac region unless a large tumor of the kidney extends unusually far down. There is no evidence of such a tumor here.

If the liver and spleen are normal, as is here stated, we have no reason to consider syphilis.

Tuberculosis of the mesenteric glands is common at this age, is apt to produce a mass in the region of the cecum, and is often associated with diarrhea and fever. One should look carefully for evi-

dences of tuberculosis elsewhere and for free fluid in the peritoneum, but such evidences are often absent. A tuberculin test should be done.

Outcome.—After waiting a week for some improvement in the child's condition, the abdomen was opened on September 16th. A small amount of clear serous fluid escaped. The appendix, cecum, and the whole of the large intestine were dotted with small nodules, thought by the surgeon to be miliary tuberculosis. The appendix was removed, but on microscopic examination found to be entirely normal. Its external surface, however, showed infiltration with round cells, in areas containing cheesy centers and giant-cells. The condition was pronounced tuberculosis by the pathologist. After operation the child continued to lose weight and strength, and on October 6th was discharged in poor condition.

Case 67

A girl of eighteen, working in a hat factory, entered the hospital March 25, 1907. For two years the patient has had pain in the lower left side of the abdomen, radiating to the median line, but never beyond it, occasionally upward to the left shoulder. This pain has been worse for the last six months, troubles her more in the morning, more when she is constipated and when she is on her feet. It has no relation to food or to micturition and does not keep her awake. She has no cough and no vomiting. She has had no previous illness. Her family history is good, except that her father has been ill for as long as she can remember; why she does not know.

Physical examination shows good nutrition and is negative, save that the abdomen is somewhat tender and rigid between the umbilicus and the pubes. Temperature, blood, and urine normal. Stomach-tube examination shows nothing remarkable. Guaiac test in the stools negative. After a few days of liquid and soft-solid diet, with Carlsbad salts and a bitter tonic, she feels much improved. Examination of the abdomen under ether, with rectal examination, reveals nothing and she is discharged "well" on the 1st of April, 1907.

She continued well and worked until the summer of 1908, when she had to give up on account of lack of strength. Although she has been at work she has had epigastric pain ever since leaving the hospital, her pain aggravated by food, but not asssociated with any lack of appetite. For eight weeks she has been able to take nothing but milk. For a week she has had diarrhea and swelling of the ankles. There has

been no vomiting at any time, but she has lost steadily in strength and weight.

She enters the hospital for the second time November 7, 1908, emaciated, but without any demonstrable physical signs except moderate edema of the feet and ankles. The blood and urine are negative and there is no fever during the three weeks' stay in the hospital, but her pulse is often above 110 (Fig. 66). Her weight at the time of entrance is only 75 pounds. Guaiac test is positive in the stools, which contain blood and mucus. The first week she gains 5 pounds, but ascites is demonstrable on the 18th, and there is a slight edema of the skin over the abdomen and back. The guaiac test continues strongly positive and the diarrhea cannot be checked. No tubercle bacilli are found in the stools.

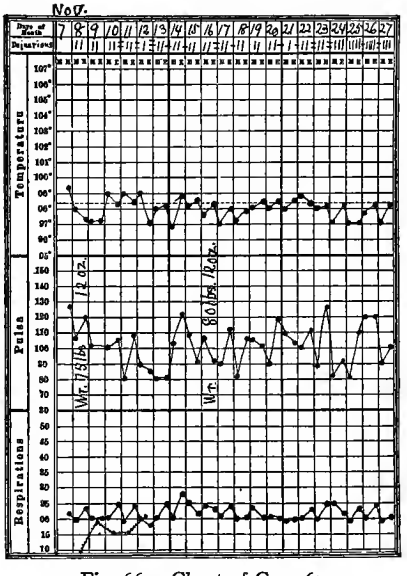

Fig. 66.—Chart of Case 67.

Discussion. — We utterly failed to understand the case during the patient's first stay in the hospital. She remained only a week because we could find nothing wrong on physical examination. The long-standing pain in the left iliac region might have suggested in an older person a diagnosis of cancer of the sigmoid or diverticulitis, but the patient's age makes these practically impossible.

Pelvic disease, such as pus-tube, was considered, but apparently ruled out as a result of the thorough examination under ether. Our diagnosis, when she left the hospital April 1st, was *gastric neurosis.*

When she returned, six months later, the steady loss of weight and strength, the diarrhea, swollen ankles, emaciation, and fever made it clear that we were dealing with a chronic infectious disease. The most definite localizing sign was the character of the stools, which showed conclusive evidence of intestinal ulceration, namely, blood and pus.

Ordinarily, I think, not enough attention is paid to the importance of pus in the stools. Many hospital records never mention it, yet it is

present in a great majority of cases of intestinal ulceration and is more distinctive of that condition than blood. Given the evidences of ulceration in the bowel, one has still to inquire the *cause* of this ulceration. In temperate climates one may rule out amebic dysentery unless the patient has previously resided in a tropical or subtropical climate. Aside from this variety of ulcerative enteritis, we know nothing of the causes of such a condition, except that a small proportion of them are due to tuberculosis. The great majority reveal no cause, either during life or after death. It sometimes appears that diseases which lower the patient's power of resistance make him liable to infection in the intestine, as well as elsewhere. Perhaps the bacteria ordinarily present in or upon the intestinal wall may attack the tissues when long-standing diseases, such as cirrhosis, nephritis, diabetes, or arteriosclerosis, have weakened the system. However this may be, it is certainly true that, in the great majority of cases, ulcerative enteritis, arising in temperate climates, shows no known etiologic agent.

This is of some importance because the diagnosis of tuberculous enteritis is so often made wrongly in cases of long-standing diarrhea. In my opinion this diagnosis should never be made unless there is abundant evidence of tuberculosis in the lungs or peritoneum, to one of which intestinal tuberculosis is usually secondary. The demonstration of ascites on the 18th made it natural to assume that the accompanying enteritis was of tuberculous origin.

Outcome.—On the 26th I made the diagnosis of tuberculous peritonitis with tuberculous enteritis. On the 29th the patient died. Autopsy showed tuberculous ulceration of the small intestine and one tuberculous ulcer in the large intestine; also tuberculosis of the mesenteric and peritoneal lymph-glands; amyloid degeneration of the spleen and kidneys; no tuberculosis of the peritoneum; no ascites.

Although my diagnosis was half-right in this case, even this degree of success was largely accidental, for my diagnosis rested chiefly on the supposed presence of free fluid in the peritoneal cavity. This is a mistake not infrequently made in patients who have diarrhea, as the intestines with their fluid contents can probably shift from side to side in such a way as to simulate the movement of free fluid.

Case 68

A baker of twenty-eight entered the hospital July 9, 1909, for diarrhea. Ten years ago he had syphilis; one year ago, gonorrhea. Otherwise he has been well. Ten weeks ago, after eating half a dozen overripe bananas, he began to have abdominal pain and diarrhea.

Five or six watery movements a day have continued ever since. There is no blood and no pain with movements, but the taking of food excites pain. The appetite is poor, but he has never vomited. He has been losing weight and strength and thinks he has had fever at times. Three months ago he says he weighed 150 pounds, with his clothes. At entrance he weighed 114 pounds, without clothes. He worked until three days ago.

On physical examination the patient was well nourished, and during a month's stay showed almost constantly subnormal temperature and pulse, the latter ranging between 50 and 60, while the temperature averaged 97° F. The physical examination was wholly negative. The blood and urine were normal. The stools contained much undigested food—meat, potato, and corn were identified with the naked eye. Microscopic examination shows an excess of fat, soap, and fatty acid; no mucus, pus, or parasites. Guaiac test strongly positive. On a Schmidt diet the amount of muscle was somewhat less. There was still much free starch and fat, especially neutral fat, calcium soaps, and colorless soaps. Guaiac test was still markedly positive. Dr. H. F. Hewes saw the patient July 8th, and thought there was either some involvement of the pancreas or some lesions high up in the intestinal tract. He prescribed a diet consisting of meat once a day, milk once a day, four slices of toast, custard, jelly, macaroni, potato purée, and white of egg. On this diet the patient's diarrhea ceased, and he began to gain in weight and strength as soon as glucose, 100 grams a day, was added to the diet, though there still continued to be an excess of fat in the feces. After the 24th he began to gain in weight, and in the week following that date gained 8 pounds, so that he left the hospital, July 31st, weighing 121 pounds. At that time Dr. Hewes considered the case one of functional diarrhea, due to some disturbance high up in the intestine, possibly an interstitial pancreatitis.

August 6th the patient re-entered the hospital, stating that he had been unable to work since leaving the hospital, as his diarrhea at once recurred, three or more movements a day. Three days ago he began to have abdominal pain and the stools increased to nine a day. He stated that he had adhered strictly to the fat-free diet given him when he left. His weight August 6th was 118 pounds. He was put at once upon the same fat-free diet and gradually improved. Nevertheless, August 15th there was still a great excess of fatty acids, crystals, and soaps. He was then given a diet containing nothing but lean meat, albumin-water, and toast. This checked his diarrhea,

although microscopic examination of the formed movements showed, August 27th, that some excess of fat was still present. In five weeks' stay he increased in weight to 124½ pounds and during the last three weeks had no diarrhea.

He left the hospital September 9th, but returned December 24th, having been two months at Tewksbury Almshouse in the interim. His abdomen had been sore, especially near the navel and to the left of it, for two weeks. The diarrhea had gradually returned and he said he had lost 30 pounds in three months, though adhering closely to a fat-free diet. The examination of the abdomen now showed a nodu-

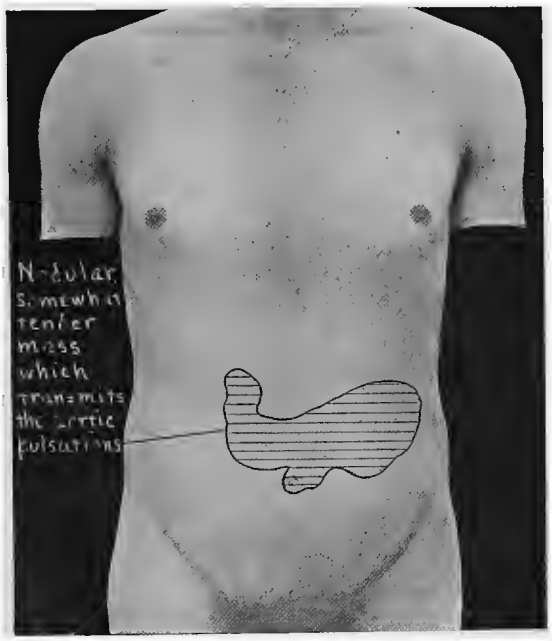

Fig. 67.—Mass felt in Case 68.

lar, tender mass, as indicated in Fig. 67. During this, his third stay in the hospital, he had no diarrhea, but his weight was only 105 pounds at entrance, increasing a couple of pounds in the next ten days. January 2, 1910, the tumor was very much less distinct, if, indeed, it was palpable at all. He was given pancreon, 10 gr. three times a day after meals, but without effect.

January 9th it was decided to open the abdomen, with a view to relieving, if possible, some lesion of the pancreas, but on examination the stomach and pancreas were found to be normal. At the splenic flexure of the colon there was a solid tumor the size of a hen's egg,

from which a projection extended downward, beneath the peritoneum. At the root of the mesentery, corresponding to the jejunum, a soft mass of glands was found. One of these was removed, but showed, on examination by Dr. W. F. Whitney, a normal lymph-gland structure except for some evidence of hypertrophy. As it was thought impossible to remove the splenic mass, the abdomen was therefore closed. The fatty stools continued after operation. He seemed to have considerable pain and some tenderness to the right of and above the navel.

On the 29th of January both hands were forcibly flexed at the wrist, with all the fingers likewise flexed. Although the latter could be readily straightened out, they immediately returned to their former position when let alone. At this time he could speak only in a whisper. The house officer considered the attack one of hysteria. On the 17th of February there was an attack similar to that above described, but this time the patient seemed very much confused and semicomatose. The knee-jerks were normal. Later in the morning the patient complained of numbness in his hands. From time to time thereafter he vomited large amounts of food material. He remained in the hospital until February 23d, but did not gain appreciably and was discharged unrelieved.

Discussion.—The recurrence of diarrhea in this case, and its cessation when the fats of the food were limited, seem to prove an intolerance of the patient's system to fat. We have no special reason to incriminate the pancreas, since after the very first the proteins and carbohydrates seemed to be well taken care of. We were altogether in the dark as to the cause of the fat intolerance until the mass shown in the diagram made its appearance, and even after that was discovered there was no good explanation of the diarrhea, since the intestine was apparently not interfered with.

From the situation of the mass and the age of the patient a malignant lymphoma or a tuberculosis of the retroperitoneal glands seem most probable. The softness of the gland at the root of the mesentery favors tuberculosis, but the histologic examination negatives this, at any rate, so far as the gland examination is concerned.

The attack of the 29th of January may have been hysteria, but was more probably tetany.

Outcome.—He went to Tewksbury State Hospital and died July 21, 1910. The cause of death was believed to be carcinoma of the splenic flexure. Lymphoma seems to me more probable. There is no record of any postmortem examination.

Case 69

The patient, a housewife of twenty-nine, was first seen July 3, 1907, when she entered the hospital for dysmenorrhea, nervousness, and a mass which she feels moving in the abdomen. Both tubes and ovaries were removed supposedly for subacute salpingitis. She did well after that, but came to the hospital again October 8, 1908, on account of diarrhea which began in July, 1908. The movements at first were as frequent as fifteen in an hour and contained fresh blood. They were associated with pain during and just before the evacuation. In July she also had epigastric distress after eating, and soon after began to vomit green and slimy material in small amounts. For the past eighteen days she has been improving and was now troubled with raising large amounts of gas. Her bowels were constipated and she had very little gastric distress. She had been much in the open air, and her color, which was naturally dark, had become much darker. During this sickness she has lost about 25 pounds. She now weighs 119 pounds.

Physical examination showed a dark skin, especially on the arms and face. The folds of the axillæ were also markedly pigmented and above the crests of the ilia the skin was dark brown in color. She was well nourished and showed no pigmentation in the mouth. Physical examination was generally negative except for dulness in the flanks of the abdomen, shifting with change of position. There was no fever in two weeks' observation. Systolic blood-pressure, 125 to 130. The blood and urine were normal. The stomach capacity was 44 ounces. There was no residue before breakfast. Gastric acidity was not tested. On the 16th of October the ascites seemed to be increasing, though she seemed in other respects better. At times it seemed as if the fluid were encysted, as it did not shift freely with change of position. At other times a demonstrable shifting seemed clear. After 5 mg. of old tuberculin, subcutaneously, there was no reaction.

On the 22d of October, 1908, she left the hospital. August 16, 1909, she returned, having been in fair health and having attended to her housework meantime, though she had been subject to crying spells, with nervousness and shivering. In June, 1909, she began to have abdominal pain and diarrhea, with blood and mucus in the stools. These symptoms had continued ever since, save for remissions of a few days, from time to time. She had had no formed stools since June. Their number was six to ten daily and they were accom-

panied by griping, paroxysmal pain, lasting ten minutes and repeated every hour or so. She had had practically no gastric troubles. When seen August 16, 1909, she was well nourished and showed no physical sign of disease.

Discussion.—Here is a patient who has suffered during two successive summers from severe diarrhea. There are some suggestions of a neurotic temperament. Addison's disease is suggested by the dark-brown pigmentation of the skin, as well as by the loss of weight and vomiting. There was no record of low blood-pressure and no cardiac symptoms; the remissions which have characterized the disease are very unlike the progressive course of Addison's disease, also her good condition in August, 1909.

The apparent presence of fluid in the abdomen and the pigmentation, as well as the diarrhea, are common in tuberculous peritonitis, but against this are the negative tuberculin reaction, the absence of temperature, and the lack of any spasm or pain, even slight, in the abdominal muscles.

The diagnosis made and thus far unrefuted was of a diarrhea dependent upon the patient's nervous and mental condition. There were many indications that if a Social Service worker had gained her confidence and looked into her home conditions, her worries and associations, some more definite cause might have been found in her temperament or environment.

Outcome.—There was no fever in four weeks' observation, during which time she gained 8 pounds in weight, which was at the end 119 pounds. On a Schmidt diet she had no diarrhea, normal stools, and within a short time was given house diet, which was also well borne. Though very nervous, she improved markedly, and went home on the 8th of September. She was seen again December, 1910, when she had an incomplete miscarriage (?), but no more trouble with her bowels. January, 1912, she had continued well. Obviously, there must have been some mistake in the report that both tubes and ovaries were removed in 1907.

Case 70

A janitor of thirty-four, born in Russia, entered the hospital November 22, 1909. His family history and past history were not remarkable, and he had been perfectly well until last May, when, after working hard and getting very hot, he drank some ice-water. This was followed by a pain in the epigastrium and right hypochondrium, and within a few hours by a bad diarrhea with some blood in

the stools. At first he had four or five movements an hour, and since then he has been unable to work on account of diarrhea. Excessive frequency of micturition accompanied his other troubles. At first there was blood in his urine, but this was not seen again until this morning, when he passed small amounts of blood frequently. Of late he must pass his urine at least twenty times in the night. There has been pain low down in the abdomen for four months and a half.

His appetite has remained good and he has had no vomiting, but meat causes distress.

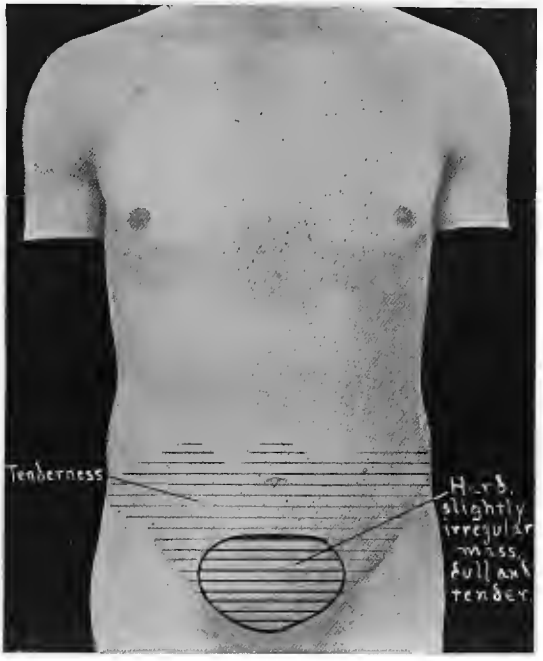

Fig. 70.—Position of "mass" and tenderness in Case 70.

Physical examination was negative except as relates to the abdomen, where "a hard slightly irregular mass, dull on percussion and tender," was found in the position shown in Fig. 70. There was no evidence of fluid in the belly. Rectal examination showed a large hard mass in the region of the prostate, not tender, but apparently connected with the suprapubic mass. After catheterization the latter disappeared and was evidently due to a distended bladder. The urine, at the time of entrance, contained almost nothing but blood and was 1030 in specific gravity. Leukocytes, 9700. Hemoglobin, 90 per cent. Weight, 133 pounds. Temperature as in the accom-

panying chart (Fig. 71). The patient refused operation. The bladder was washed free of blood-clots, and thereafter he was able to pass a fair amount of bloody urine. December 1st gonococci were found in his urethral discharge. He continued to complain of pain on micturition and would drink but little water. The urine contained so much blood that nothing else could be distinguished in it. Its amount averaged 40 ounces in twenty-four hours. He seemed to be in pretty fair condition until the afternoon of the 24th of December, when he complained of pain and slept so poorly that he was given $\frac{1}{6}$ gr. of morphin, subcutaneously.

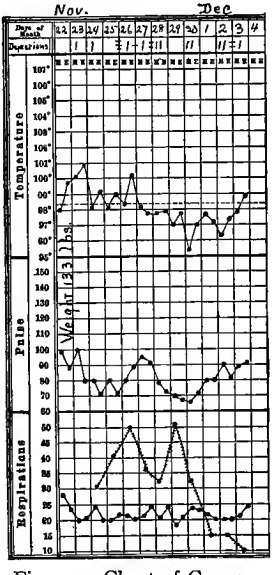

Fig. 71.—Chart of Case 70.

Discussion.—The association of diarrhea with hematuria is common in cancer of the bowel extending to the bladder; also in neoplasms of the bladder and prostate, involving the bowel. In the tropics, bilharziasis is also a common cause of proctitis and hemorrhagic cystitis, but, so far as is known, this patient has never lived in a country where such infections are common. Since rectal examination shows no evidence of rectal cancer, it seems more reasonable to believe that the trouble originated in the bladder or prostate.

Gonorrhea can affect both bladder and rectum, but never produces so profuse a discharge of blood. The presence of gonococci in the urethral discharge had nothing to do with his main disease.

The excessive and continued hematuria are not consistent with any known disease of the kidney. Hematuria from this source is not often associated with such dysuria and frequency.

Malignant disease of the bladder is not common at thirty-four, but, taking all things into consideration, no better diagnosis can be made. The drinking of ice-water was probably of no importance in the case.

Outcome.—Two and a half hours after the morphin injection of December 24th he was found to be pulseless, and on the arrival of the house officer was dead. Autopsy (No. 2492) showed: Squamous-cell carcinoma of bladder with bone formation in the stroma; occlusion of ureters in bladder wall; suppurative nephritis of right kidney; atrophy of right kidney with dilatation of its pelvis; compensatory

hypertrophy of left kidney; dilatation of ureters; obsolete tuberculosis of the mesenteric lymph-glands; chronic pleuritis. The intestine was not remarkable.

Case 71

A salesman of twenty-four entered the hospital January 27, 1910, with a diagnosis of "tubercular enteritis" (Out-patient Department, 142,612). Family history negative. The patient had typhoid fever eight years ago and no other illness of importance. He smokes one or two boxes of cigarettes a day.

January 3d he had severe pain in the right lower quadrant and a temperature of 102° F. Also some pain in the left upper quadrant. He went to bed for five days, and since he got up, nineteen days ago, he has had an obstinate diarrhea, sometimes twenty-four movements a day, with much colorless mucus. He has now no pain in the right lower quadrant, but a week ago he was so sore along that side of his abdomen that he could hardly move his right leg, and he has therefore remained in bed since that time. There has been no nausea or vomiting since the 3d of January, but he believes that he has had a little fever for at least forty-eight hours. His appetite for the past ten days has been poor, and his sleep poor for three weeks. Since the beginning of his illness he has lost 13 pounds.

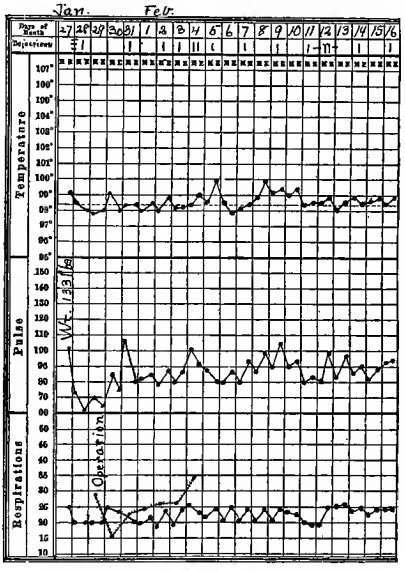

Fig. 72.—Chart of Case 71.

Temperature at entrance, 99.2; pulse, 102; respiration, 25. White cells, 27,000, the stained smear showing polynuclear leukocytosis. Urine negative. Chest negative. Abdomen tympanitic, the upper portion gradually becoming dull as one approached the pubes. In the right lower quadrant an indistinct mass, the size of an egg, was felt, and there was some spasm and tenderness in this region. "Rectal examination reveals a hard prostate, either enlarged or pushed down. The large mass felt seems like a full bladder." The course of the

temperature during the patient's three weeks in the medical wards was as seen in the accompanying chart (Fig. 72).

Discussion.—The age of the patient, together with the diarrhea, the soreness, and the mass in the cecal region, are quite consistent with an abdominal tuberculosis. The duration of the symptoms also favors this. Against it, however, are the high leukocyte count and the absence of any considerable fever during most of his three weeks in the ward.

The only type of neoplasm often seen in persons so young is malignant lymphoma, and this is seldom associated with so marked a leukocytosis or so obstinate a diarrhea. In the majority of cases, moreover, malignant lymphoma is multiple.

Appendicitis would account for the mass and the leukocytosis, but against appendicitis are the prolonged diarrhea and the absence of any marked elevation in temperature or pulse. The clinical diagnosis favored abdominal tuberculosis.

Outcome.—On the 29th of January the abdomen was opened, the small intestine found matted together about the cecum. A small cavity of pus, containing about 2 drams, was found at one side of the cecum. The appendix was found adherent to the cecum and perforated at the tip. No evidence of perforation was found in the gut. The patient did well after operation and was discharged February 16th. Examined February 18, 1911, he seemed to be entirely well. Why the patient never had any elevation of temperature and pulse, and why he had so much diarrhea, I do not know.

Case 72

A schoolboy of eighteen, born in Turkey, enters the hospital April 19, 1910. He has been in this country only eight months, but has been sick for considerably more than a year with obstinate diarrhea in recurrent attacks and with almost constant abdominal pain. Owing to his scanty acquaintance with English, no further history is obtained.

The patient is emaciated and has a dry, harsh skin. His eyelashes are noticeably long. Fingers slightly clubbed at the ends. His chest negative. Abdomen slightly distended, tympanitic in the epigastrium, dull in the flanks, the dulness shifting with change of position. The whole right side is slightly spastic, especially in the right lower quadrant. Visceral examination otherwise negative. Urine negative. White cells, 6000 to 8000. The stained smear shows moderate achromia and slight deformities of the red cells. Marked increase of

blood-plates. The bowels moved three to ten times a day during his month's stay in the hospital. Feces contain much mucus and an occasional leukocyte. No excess of fat, muscle, or carbohydrate. Guaiac test always negative and no tubercle bacilli or other organisms of importance. The temperature as in the accompanying chart (Fig. 73). Weight, 72½ pounds, gradually decreasing to 68 pounds during the course of his stay. The camphor, opium, and tannin pill, large doses of bismuth, lactic acid milk, the fluidextract of coto bark, tincture of catechu, the Schmidt diet, and various other modifica-

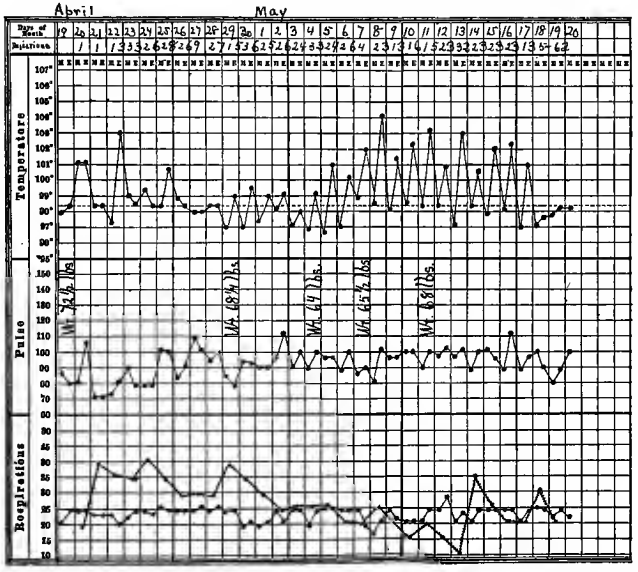

Fig. 73.—Chart of Case 72.

tions of diet were given without result. When the boy left the hospital, May 20th, he was worse than at entrance.

Discussion.—In many ways this case resembles the last (Case No. 71), although there was only spasm, no mass in the right iliac region. A year's diarrhea in a Turk, with fever reaching repeatedly above 102° F., and free fluid (apparently) in the peritoneum, suggests abdominal tuberculosis, especially as the diarrhea proved intractable.

It is conceivable that in this case, as in the last, appendicitis may have been present, but the low white count and the long course of the case are against this. Unfortunately, we have no definite knowledge of the outcome.

Case 73

A girl baby, seventeen months old, entered the hospital June 13, 1910. Its parents and the rest of the family are healthy. The baby was breast fed for eleven months and has always been well until yesterday, when it ate a large amount of fresh bread, potatoes, and macaroni. At 2 A. M. today the baby waked, feverish and vomiting. After castor oil it slept, but awakened at 5 A. M. and had general convulsions with cyanosis and dyspnea. More castor oil was given, but at 8 o'clock there was another convulsion, lasting three minutes. The bowels moved five times normally yesterday, once this morning after 2 o'clock and again after an enema.

The baby is fat and healthy looking. Tonsils much enlarged and reddened. Anterior surface of the pillars is covered with small red papules. Physical examination otherwise negative. The streptococcus is the predominating organism in the throat. The blood shows 15,500 leukocytes, with a slight polynuclear leukocytosis. Urine normal. Numerous loose stools continued during the first ten days of the child's stay in the hospital, the stools containing blood and pus. There are numerous râles scattered in various parts of the chest. The ears are examined, June 18th, by Dr. Mosher, who finds both ear-drums reddened, and on puncture recovers a little pus from each. By the 25th the bowel movements are fewer in number, the lungs clearer, and the ears discharging less. By the 29th the stools are normal in frequency and quality. This evening the pulse is very slow and a little irregular. Temperature abnormally low, but nothing of importance results from this state of things.

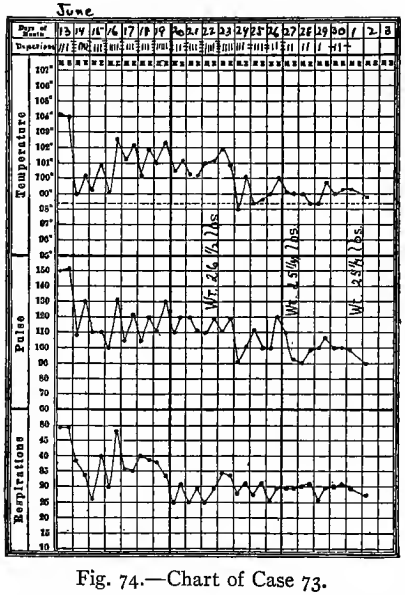

Fig. 74.—Chart of Case 73.

Discussion.—So high a fever in a young child should make us search for all the commoner sites of infection, and exclude otitis by examination of the ears; bronchopneumonia, by examination of the chest; and pyelitis, by examination of the urine.

Evidently the child had a streptococcus throat, and the small red papules in the pharynx made us look carefully for an exanthem. None such, however, appeared, and when all the infections mentioned in the previous paragraph had been ruled out, there remained no serious doubt that the infection was of intestinal origin. That it was not a mere food diarrhea was shown by the presence of blood and pus in the stools, as well as by the duration and obstinacy of the symptoms.

Intussusception would produce diarrhea more or less similar to this, but would be unlikely to last so long without producing any tumor, abdominal distention, or other severe symptoms.

Since no cultures were made from the stools, there is nothing more to be said regarding the organism at work there.

Outcome.—By the 2d of July the baby seemed quite normal, except for a slight discharge from the right ear. The treatment consisted of milk feedings, 3 ounces every three hours, alcohol sponges at 80° F. for fever, and rectal irrigations every six hours with a quart of warm salt solution. The ears were syringed every two to four hours with warm boric acid solution. Water was offered the child very frequently. The course of the disease is well indicated in the accompanying temperature chart (Fig. 74).

Case 74

A widow of sixty-four entered the hospital June 21, 1910. Family history and past history uneventful. In August, 1909, she began to have diarrhea, with five or six loose movements a day, each preceded by cramps in the left lower abdomen, radiating from the region of the hip down the leg, and relieved by the passage of feces. She has had no normal movements since August, 1909. In February, 1910, she began to notice blood-streaked, jelly-like masses in the movements, and since that time she has been confined to bed for a day or two, off and on, in order to relieve the pain. For four weeks her bowels have been costive at times. Since February, 1910, the abdomen has been greatly swollen, the swelling more or less relieved in the last two months by four spoonfuls of castor oil each morning. The appetite has been fair until about a month ago, at which time she had to give up work. Her usual weight, 180 pounds; now, 151 pounds.

On physical examination the patient is still fat, but sallow and pale. The head and chest are negative. The abdomen shows in the left iliac fossa an indefinite, very tender mass, about the size of an orange, but is otherwise negative.

Discussion.—Malignant disease of the sigmoid is certainly the diagnosis which comes first to our minds, but we are less confident of this impression's correctness when we note that the patient continued her work until a month ago and that she is still fat, despite the loss of nearly 30 pounds. Nevertheless, it is well known that intestinal neoplasms have a remarkable latency and mildness in many cases.

Diverticulitis is a possibility which must always be taken into consideration when cancer of the sigmoid is our first choice, since the cases published within the past five years make it clear that these two diseases may be almost or quite indistinguishable without histologic examination of the tumor mass.

In this case the absence of fever and leukocytosis and the notable discharge of blood incline us to favor cancer.

Tuberculosis rarely appears in the abdomen at this age, and rarely shows itself in the region of the sigmoid. The cecum and the epigastric region are its commonest sites of manifestation.

Outcome.—June 27th the abdomen was opened and a cancerous mass found in the sigmoid, involving the entire gut for 4 or 5 inches, the mass itself being about the thickness of a man's wrist, hard and nodular. Glandular infiltration was extensive in the neighborhood. A right inguinal colostomy was done. The patient made a good recovery from the operation and was discharged in good condition on July 19th.

Case 75

A shirtwaist maker of twenty-two, unmarried, entered the hospital August 16, 1910, with a diagnosis of typhoid fever. Thirteen days previously she began to have diarrhea, four or five movements daily, continuing until three days ago, since when she has been constipated. Nine days ago she left work and went to bed on account of weakness. She has felt feverish and chilly, and during the last two or three days has had severe headache.

Physical examination showed good nutrition, normal chest and abdomen. Normal extremities. White cells, 7000, with 55 per cent. of polynuclear cells. Urine negative. The Widal reaction was done every second day for two weeks, and every four days thereafter, until the 20th of September. At no time was there any evidence of a positive reaction. She had no diarrhea during her stay in the hospital. Temperature was as in the accompanying chart (Fig. 75). She looked typically typhoidal. At one time in the early days of Sep-

tember she had considerable pain on micturition, but this pain ceased when the urotropin was omitted, a drug which had previously been given in doses of 5 gr. every four hours. The agglutinative reaction with the alpha- and beta-paratyphoid were negative, but with the Bacillus coli a positive reaction was obtained in a dilution of 1 to 40.

Discussion.—A short fever, preceded by ten days' diarrhea and ending in recovery, presents itself in this case. Arguing from the agglutinative reaction with the colon bacillus, one is inclined to class this as a colon bacillus infection, but it is to be remembered that the number of demonstrated cases of generalized infection from colon

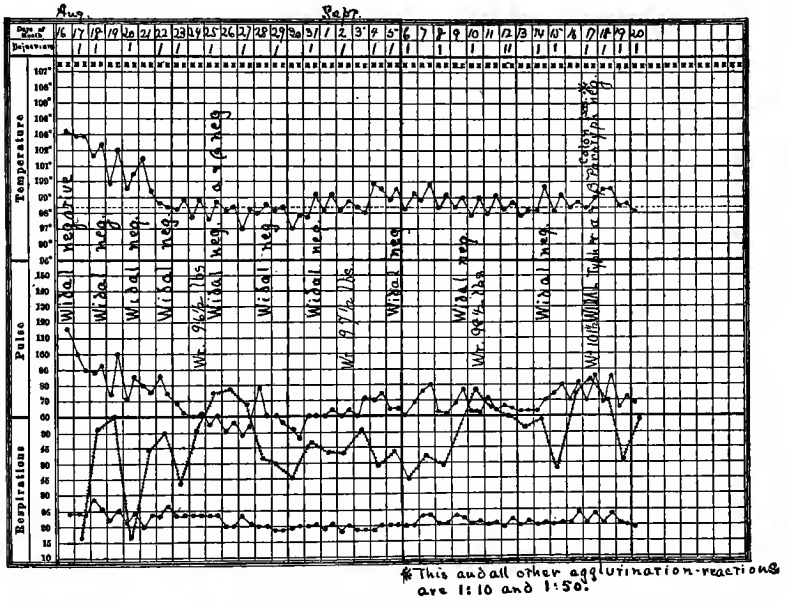
Aug.
Sept.
Temperature
Pulse
Respirations
Widal neg.
Wt. 96½ lbs.
Wt. 97½ lbs.
Wt. 99½ lbs.
Widal neg.
Widal neg.
Widal neg

case and the tolerably rapid lysis. Against typhus is the normal white count (it should be 11,000 to 13,000) and the absence of any cutaneous eruption. Nevertheless, I do not think that this diagnosis can be excluded.

I see no reason to consider seriously the phrases "grip" or "febricula," terms often applied to short fevers of unknown origin, but undesirable because they give the appearance of knowledge without the reality.

Outcome.—Blood culture was negative. September 20th she had gained 7 pounds, was walking without fatigue, and was allowed to go home.

Case 76

A sewing girl of twenty entered the hospital September 15, 1910. The patient's mother died at forty-two of gastric cancer. All her family are nervous. In April, 1908, she was operated upon in St. Joseph's Hospital, Providence, for a cervical swelling of four months' duration. Otherwise she was well until her present illness, but she has been in the habit, during the last three or four months, of drinking 19 to 20 cups of fairly strong tea a day. Before this time she took only about 3 cups of tea a day.

In March, 1909, without known cause and without previous stomach symptoms, she was suddenly seized with severe epigastric pain, relieved only by morphin, In the course of three days this pain wore off and she went back to work, but never since that time has she been free from epigastric pain and hardly a day has passed without vomiting. During July, August, September, October, and November, 1909, she was in St. Joseph's Hospital at Providence. In November she was operated upon by Dr. Harris, and in January, 1910, she went to work again, but in March began to have pain in the right iliac fossa, which led to a second operation at the same hospital by Dr. McKenna, April 1st. For the past two months she has had an attack of pain in the left iliac fossa every few days, lasting fifteen to twenty minutes, and sometimes extending down the front of the thigh.

Meantime the stomach symptoms have continued without much variation. Knife-like epigastric pain comes immediately after eating, and, if not relieved by vomiting, lasts fifteen or twenty minutes. After that it becomes moderate and constant. Her pain is not relieved by soda, by food or drink, and does not radiate, but is much relieved by vomiting, which occurs after almost every meal, is never

large in amount, and never contains blood or food eaten the day before.

Throughout the illness her appetite and sleep have been good. Bowels usually regular. She has not worked for six months. Two years ago her weight was 143 pounds; December 16th her weight, without clothes, was found to be 100½ pounds.

Despite this apparent loss of weight, she was well nourished and had a good color. Her hands and feet were always cold and clammy. On the right side of the neck, below and behind the ear, was an operation scar, 1 inch long. There were no enlarged lymph-glands present anywhere. Chest negative. The abdomen was tympanitic in the lower part, dull above, with slight involuntary resistance in the right upper quadrant and epigastrium. A 9 cm. vertical scar was seen above the umbilicus, to the left of the median line. Another, 8 cm. long, in the right lower quadrant.

The blood was negative; likewise the urine when obtained by catheter, though the routine specimen obtained without special precautions showed a pus sediment of about 5 per cent. of the total amount of urine when centrifugalized five minutes at the rate of one thousand revolutions per minute. Her vomitus contained free HCl and reacted strongly to guaiac. It contained no food residue or anything else of interest.

At first the patient could retain no food and was given only salt solution by rectum, 200 c.c. every six hours. By the third day she was able to take crackers and toast with butter, but the rectal salt solution was kept up until the 27th. She kept down her crackers and toast, but vomited liquids and cornmeal mush. Meantime a letter was sent to St. Joseph's Hospital, and an answer received, stating that a gastroenterostomy had been done, but making no mention of the pathologic condition found. By October 3d the patient had advanced to the third stage of gastric ulcer diet (see Vol. I. of this work, Appendix) and was perfectly comfortable. Thereafter she gained steadily, and had less epigastric soreness.

She went home October 23d, having gained 13 pounds in weight, but returned November 19th, stating that since her discharge she had been very miserable, vomiting almost everything eaten. Bowels very constipated, her condition altogether preventing work. She had got back to 102 pounds in weight. This time, despite treatment similar to that previously given, she continued to vomit occasionally, although she gained 6 pounds during her first week's stay in the hospital.

Discussion.—On a first reading of this case it is obvious that she has too many pains in too many places to fit any known localizable disease, and of the generalized diseases, such as infection or carcinomatosis, we have no evidence, especially as the appetite and sleep are good and there is no falling off in nutrition or color. Despite the absence of hydrochloric acid from the gastric contents, there is no good clinical evidence of cancer or of any other organic disease of the stomach.

Tabes dorsalis might account for her pain, and, although this is an unusual disease in a girl of twenty, I do not see that it can be absolutely excluded in this case, since no spinal puncture was made. I am thoroughly convinced that there are cases of tabes presenting no symptoms excepting abdominal pain and a characteristic spinal fluid, that is, cases in which the pupils and reflexes are normal. In the latter part of her history pain is much less prominent, and the possibility of tabes becomes correspondingly less.

At one time we were strongly inclined to consider that some form of tuberculosis was at the bottom of her troubles. This was suggested by the scars in the neck, the loss of weight, and the supposed presence of pyuria. When the pyuria was disproved, there seemed no sufficient ground for considering this hypothesis any longer.

There seemed to be nothing left but to suppose that the case was one of functional or neurotic stomach trouble, greatly aggravated by hospitalization and by unnecessary surgery.

Outcome.—On the 8th of December she was operated upon by Dr. Codman. The old gastro-enterostomy was closed, so as to restore so far as possible a natural condition of the stomach. No evidence of gastric or duodenal disease was found. The old gastro-enterostomy was in excellent condition and working as well as could be expected. Slight adhesions between the pylorus and the gall-bladder and between the old scar in the abdominal wall and the anterior wall of the stomach were separated. After operation the patient did fairly well, but was troubled very much by toothache. She was entirely relieved of her vomiting and was able to eat almost every sort of food. She left the hospital January 16th.

Case 77

An Italian caterer of fifty-six entered the hospital September 18, 1910. Six of his cousins and one sister died of tuberculosis. His wife has had tuberculosis for seven years. He has three healthy children and his family history is otherwise good. At thirteen he had

pleurisy, but was not tapped. Up to four and one-half years ago he worked as a courier, conducting parties on the West African Coast, in the West Indies, and in various parts of Europe. On these travels and occasionally since he has had attacks of diarrhea, lasting two or three days, and in winter has had frequent slight attacks of bronchitis. Three and one-half years ago he had a severe cough, lasting two months. Dr. J. Payson Clark has amputated his uvula and removed several polypi and turbinates. He denies venereal disease. He takes 2 or 3 glasses of wine and about 3 ounces of whisky a day.

Six weeks ago he had an accident, diagnosed by a skilful physician as "rupture of the plantaris." During the succeeding weeks of enforced idleness he lost his appetite completely and ate nothing but bread and milk. On the seventh day, at 2.30 P. M., his abdomen became distended and painful. Nausea, vomiting, and diarrhea followed, movements occurring forty to fifty times a day for twelve days, according to his statement. After that he got better and went to work, though his bowels continued to move eight or ten times a day. He blamed an overripe peach, eaten yesterday, for a return of vomiting, cramps, and diarrhea. Yesterday, he said, his bowels moved fifty times. Six weeks ago his weight was 170 pounds; at entrance his weight, without clothes, was 150 pounds.

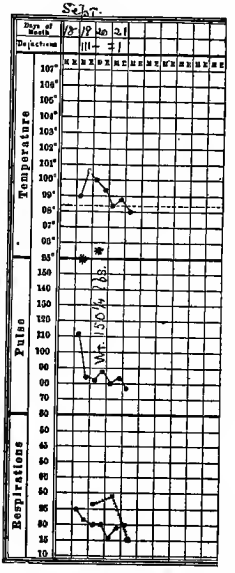

Fig. 76.—Chart of Case 77.

He was well nourished. The heart's apex extended $2\frac{1}{2}$ cm. outside the nipple line. The aortic second sound had a metallic and ringing quality. The systolic blood-pressure was from 160 to 170 mm. Hg. The heart showed no murmurs and no other abnormality. Physical examination, including the blood and urine, was otherwise negative. The range of his temperature is shown in the accompanying chart (Fig. 76).

Discussion.—There is strong tuberculous taint in this case, as shown by the family history and the early pleurisy. His two months' cough and his frequent attacks of "bronchitis" strengthen this suspicion, but there is nothing in the physical examination at the present time that points to any tuberculous lesion.

He has been in countries where bilharzia is common, but the

absence of blood and eggs in his stools leaves no further ground for this suspicion.

Alcoholics are especially subject to diarrhea. This patient has taken a good deal of alcohol, and if no other explanation can be found, it may seem most reasonable to blame this habit for his symptoms.

Can his high blood-pressure explain the condition of his bowels? Various writers have attempted to show that in interstitial nephritis, such as might explain his hypertension, a compensatory diarrhea occurs as an expression of nature's effort to rid the body of poisonous substances normally excreted by the kidney. I have never been able to satisfy myself, however, that such a compensatory diarrhea exists. Moreover, the urine shows no evidence of nephritis. The enlarged heart and high blood-pressure are more reasonably explained as part of a general arteriosclerosis.

Why should we not adopt the patient's own suggestion—viz., a food diarrhea? The last attack is more easily explained in this way than the earlier one, which occurred when he was taking only bread and milk. Nevertheless this was the best explanation which we could offer and it seemed to be confirmed by the outcome.

Outcome.—The patient was given only water by mouth, and after twelve hours of such starvation was started on liquids and soft solids. Food was excellently well borne. He had no diarrhea after the first two days. The stools during the first two days contained no guaiac reaction and no other evidence of consequence. September 22d he went home well.

Case 78

An Italian laborer of twenty entered the hospital September 21, 1910. His family history and past history were negative. His habits include the use of three or four beers and one or two whiskies daily. About a month ago he began to have moderate diarrhea, accompanied by abdominal distention, and he quit work for two weeks on account of weakness. For the past eight days the bowels have moved six to eight times daily. He has had an occasional attack of pain over the lower left ribs in the axilla, lasting a few days at a time. For the past day or two he has had a slight dry cough. Five weeks ago he weighed 140 pounds, with his clothes. At entrance he weighed 122 pounds, without clothes.

Physical examination showed a boy with long eyelashes and bright scleræ. The heart was negative. The lungs showed the appearance depicted in Figs. 77 and 78. The abdomen was distended, and flat on

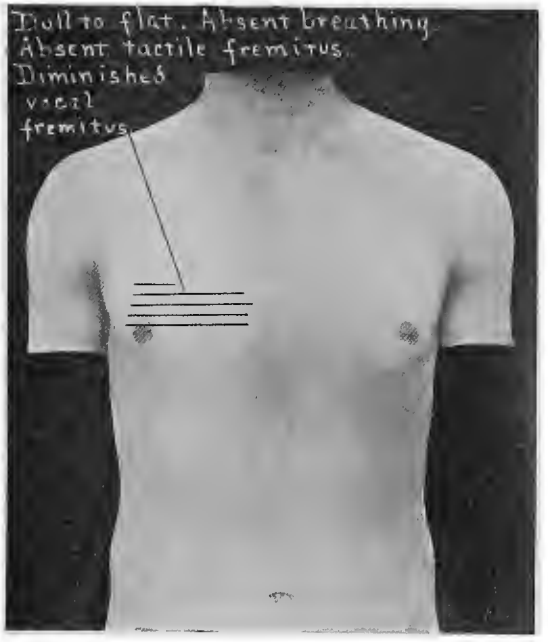

Fig. 77.—Chest signs in Case 78.

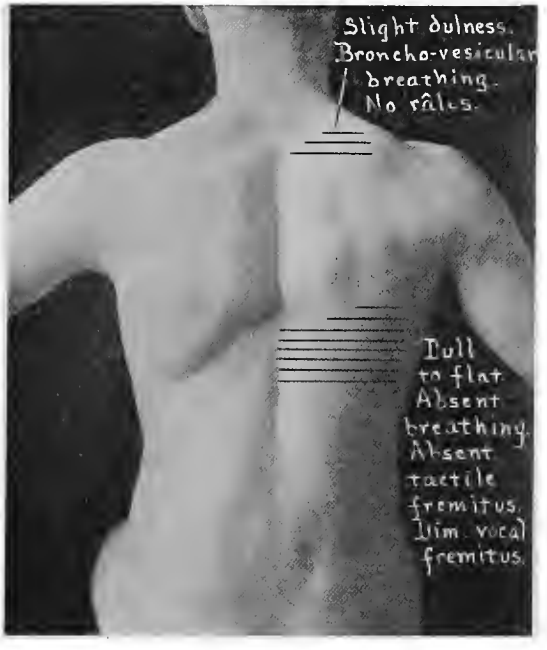

Fig. 78.—Chest signs in Case 78.

percussion in the flanks and over the pubes. A fluid wave was present. The right epididymis was slightly thickened. Stools negative. September 22d the abdomen was tapped and 3350 c.c. of yellow, slightly turbid fluid removed. Its specific gravity was 1019. Albumin, $3\frac{1}{4}$ per cent. The sediment consisted wholly of lymphocytes, 90 per cent. of which were of small size. No tubercle bacilli or other organisms were found. Cultures were negative. Twenty minims of the fluid were injected into a guinea-pig September 23d. Autopsy of this pig showed nothing abnormal. The range of the temperature is shown in the accompanying chart (Fig. 79). On the 25th of September he complained of pain in the left axilla and a loud friction sound was heard there.

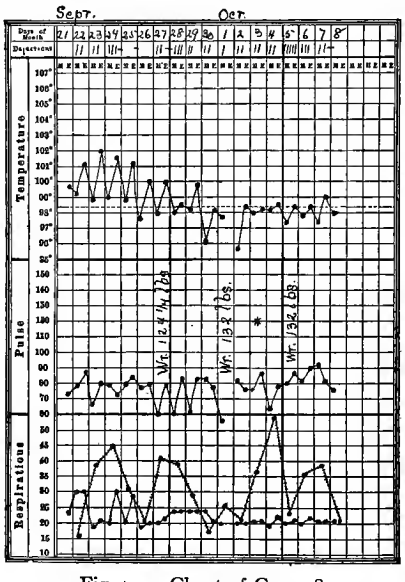

Fig. 79.—Chart of Case 78.

Discussion.—The association of diarrhea with ascites, chest pain, cough, fever, and epididymitis is strongly suggestive of tuberculosis, even though the guinea-pig test of the ascitic fluid showed nothing. That the temperature rapidly subsided after rest in bed does not in any way militate against this diagnosis. The character of the ascitic fluid is wholly consistent with tuberculous peritonitis, and the evidences of fluid and friction in the right chest confirms it.

Need we suppose that tuberculous enteritis was also present? There seems no such necessity, especially as the stools were negative and by no means excessively frequent.

Outcome.—By October 5th the fluid in the right chest was disappearing and the friction-sounds gone. He had gained 10 pounds and much strength, but, as he was still unfit for work, he was transferred, October 8th, to the State Hospital at Tewksbury. Two years later the Superintendent of the Institution writes that the patient remained there from October 8, 1910, to April 29, 1911, and left improved. On October 11, 1910, and on March 14, 1911, the right chest was tapped. Each time 45 ounces of amber-colored fluid was withdrawn.

October 24, 1910, an exploratory laparotomy was done and the diagnosis of tuberculous peritonitis was confirmed. At this time the patient was very sick, and the marked improvement which occurred later was quite unexpected.

Case 79

An unmarried woman of forty-four was seen in consultation in September, 1910. *For twenty years she has been suffering with diarrhea*, alternating with short periods of constipation. Fifteen years ago she spent five consecutive years in bed, and since then has frequently been bedridden for months at a time. It is years since she has ventured outside the house, and she never takes more steps than is absolutely necessary within the house, as exercise invariably brings on increased diarrhea. She now lives quite alone, in a rural district, getting her own meals, which consist exclusively of the juice chewed out of $1\frac{1}{2}$ pounds of broiled steak, per day, the whey from 2 quarts of milk, and $\frac{1}{4}$ pint of heavy cream. This is absolutely the whole of her diet and has been the same for some years. She states that any attempt to eat more is followed by an increased diarrhea and an enormous production of "membrane" within the bowel, which blocks it and sets her physicians to working for weeks before the bowel can be made to move. Her appetite is good. She longs to eat more, but does not dare to.

The patient states that she has been able throughout this long illness to keep her mind well occupied by reading and sewing. Considerable study of her convinces me that this is perfectly correct, and that she is not at all self-centered or morbid in any way. Except for this diarrhea and a gradually increasing deafness during the past six years, she complains of nothing and has an excellent family history.

Physical examination shows emaciation, but is otherwise negative. Blood and urine show nothing abnormal. Systolic blood-pressure 140 mm. Hg.

The patient stayed nearly nine months in the hospital, which she entered weighing 70 pounds; on leaving she weighed $86\frac{3}{4}$ pounds. During the first three months of her stay the bowels were constipated and at no time in the nine months was there any diarrhea. Her pulse, temperature, and respiration were always normal except during an inflammatory complication, to be referred to presently. There was always a guaiac reaction in the feces, but nothing else of importance was discovered, despite frequent and careful examinations.

Treatment was begun with the patient's usual diet. For abdominal pain she was given hot fomentations and a daily high enema of warm oil. October 3d cornmeal mush and ice-cream were added to the diet. She complained of much pain thereafter, but managed to retain them and slept fairly well each night. October 6th a raw egg daily was added. October 12th hot rice with cream and bread-crumbs with beef-juice were added, and after the 15th of the month she took apple-sauce or the juice of an orange daily. In the open ward she did not do well, but when put into a private room began to gain. *Her pain was still severe*, sometimes constant, sometimes in paroxysms, *accompanied by abdominal distention*. November 10th toast and milk were added to the diet, and she was given, despite her protestations, a dropped egg on toast. When she found that she could eat this without increase of distress and much relish, her spirits were exuberant. The upright position and attempts to walk increased her pain, and were followed by periods of general abdominal tenderness and rigidity. Nevertheless, she was urged to persevere, and succeeded in overcoming her discomfort.

December 26th she began to have great pain about the rectum and perineum, accompanied by a slight rise of temperature and a leukocytosis of 18,000, which rose January 4th to 30,000, when a vulvar abscess was opened by Dr. Cobb and 50 to 100 c.c. of foul pus, containing colon bacilli, evacuated. It took her until about the 19th of January to get over this. The oil enemata were increased about this time to 16 ounces every night. This enema was followed by a feeling of great comfort and enabled her to sleep. After February 1st she gradually increased her walking distance until she was able to walk an eighth of a mile within the hospital and to take Zander exercises without discomfort. By May she appeared really perfectly well, though subject to occasional attacks of abdominal pain. She was eating everything, including many foods which she had not taken for twenty years.

Discussion.—This case is remarkable in several respects. First, in that a woman who had lived the life of an invalid for twenty years and had not been able to cross the threshold of her house for at least a decade was restored to perfect health, practically without any treatment except diet. Her recovery would have been impossible, I think, but for her unusual force of character, for several times in the course of her treatment her sufferings were very great, and any but a very determined person would have given up the effort to eat unaccustomed food and returned to starvation diet.

At times the abdominal distention and pain were so severe that but for the normal temperature and pulse she would have undoubtedly been operated upon.

In view of the outcome of the case, I believe that her sufferings were wholly due to constipation, with resulting irritation and ulceration of the bowel. At times the case took on the features of *colica mucosa*, but most of the time the symptoms were simply those of constipation. Practically no medicine was given by mouth, but she got great relief from her pain by the enemata of olive oil.

No bismuth *x*-rays were taken in this case, but it closely resembled, on the clinical side, many that get operated upon for adhesions. I should like at this point to express my belief that when patients improve after operations done for the relief of adhesions, the relief is not due to the operation, except in rare cases. It is just now the fashion to lay great stress upon adhesions, veils, or membranes about the cecum, about the gall-bladder, and the pyloric end of the stomach, but I am convinced as a result of my study of cases, postmortem and antemortem, that such membranes and adhesions rarely cause any symptoms, and that the symptoms attributed to them are just as frequent in patients having no adhesions. The present fad for operating on such cases rests upon evidence as unsatisfactory as that which led us a few years ago to operate upon so-called floating kidneys, and to make diagnoses of "auto-intoxication," "lithemia," and "ptomain-poisoning."

It must be admitted that many patients improve after operations for the relief of adhesions, but I believe that this improvement is to be explained by the dietetic, hygienic, and psychic régime to which the patient is submitted after the operation. Some patients cannot be induced to diet or to submit themselves to any régime unless some sort of an operation is performed. This sort of irrationality is parallel to the foolishness of those who would not stop overeating and overdrinking unless they are sent to some spa or springs to drink a large quantity of disagreeable water. But it seems to me altogether unnecessary and wrong for the medical profession to encourage people in such wasteful and ridiculous performances. In the long run the public will not thank us for helping them to deceive themselves and to waste their money.

Outcome.—She left the hospital May 5th, 1911, but was heard from subsequently as enjoying splendid health and getting back into the world of affairs which had been unknown to her for many years. Ischiorectal abscess later developed and was operated on at the

Baptist Hospital by Dr. Hugh Cabot, after which she made a good recovery and has remained well since (1914).

Case 80

A married woman of twenty-four entered the hospital September 29, 1910, with a diagnosis of "tubercular enteritis." Her family history was negative and she herself has always been well except for an occasional "summer diarrhea," never lasting more than a week. She has two children, the youngest fourteen months old. This child she nursed until two or three days ago.

For nine weeks there has been steady diarrhea, first, three movements a day, but lately increasing until she says that movements come every ten minutes and feel like hot water. For a week there has been considerable blood in them and always much mucus. For a fortnight she vomited after nearly every meal, and once last week raised a teaspoonful of blood. She has had slight dry cough for nine weeks, but never raised blood. Up to a week ago she kept at work, but since that time severe and frequent abdominal cramps doubled her up and compelled her to stay in bed. Previously her diarrhea had been nearly painless.

Her appetite and sleep were very poor. Her best weight, two years ago, was 138 pounds; six weeks ago, 97 pounds; now, without clothes, 81 pounds.

The patient was emaciated and pale, with flushed cheeks. A few squeaks were heard at the right apex, where the physiologic dulness seemed to be increased. Otherwise the chest was negative. The abdomen was concave and acutely tender throughout. Coils of intestine could be seen and felt in it. The stools, examined every day or two for three weeks, showed no reaction to guaiac and no other features of importance. Tubercle bacilli were never found. Blood and urine were normal. Blood-pressure, 105 mm. Hg., systolic; 80 mm. Hg., diastolic. Temperature, pulse, and blood normal.

The patient was put on a Schmidt diet with subnitrate of bismuth, 1 dram four times a day, and a suppository of gall and opium, when needed for pain. The movements were five or six daily during the first three days. After that there was no diarrhea in three weeks' observation. The officinal pill of camphor, opium, and tannin was given four times a day for four days, beginning October 1st. After that no medicine was needed except high oil enema daily.

Discussion.—In all probability this patient had a mild tuberculosis at the right apex, and, admitting that, many a physician would

conclude at once that the diarrhea must be due to tuberculous enteritis. That this is often a mistake I have shown elsewhere.[1] Not every case of diarrhea associated with pulmonary tuberculosis is due to tuberculous enteritis. A quite curable non-tuberculous enteritis is common in such cases, and this fact is of much importance in prognosis. The patient's response to treatment in this case made it very improbable that there was any tuberculosis in the bowel.

The tenderness of the abdomen and the visible peristalsis gave rise in this case, as they frequently do, to unnecessary anxiety. Peritonitis and obstruction were suspected, but in view of the normal temperature and pulse, the normal blood, and the frequent stools there was never any good reason for anxiety. Such tenderness and peristalsis are common when enteritis occurs in an emaciated person.

The rapid disappearance of a diarrhea which lasted nine weeks is due largely, I think, in this case to rest in bed. It will be noted that the patient had kept at work until a week before her entrance to the hospital. I know no disease comparable to enteritis in the rapidity of benefit produced by rest in bed and change in environment, even when no dietetic or medicinal remedies are used. Since blood and pus were absent from the stools, we have no good reason to suppose that any ulcerations were present in the bowel. The exact cause of the diarrhea is obscure, as it is in a very large number of mild cases.

We cannot reasonably assume that colitis or any other anatomic change is present. The trouble may well be due to anomalies of secretion, of motility, or to some circulatory disturbance. The latter is somewhat suggested by the low blood-pressure.

Outcome.—By October 3d she looked and felt like a different person. The appetite rapidly increased, and by October 9th she had gained 9 pounds. From that time until her discharge, October 22d, she gained steadily in weight and strength, and when discharged weighed 94 pounds, an increase of 13 pounds.

Case 81

A weaver of thirty, born in Finland, entered the hospital October 14, 1910. Ten years ago he was in bed a week with diarrhea and expelled a tapeworm 20 feet long. Otherwise he has been well and denies venereal disease. He confesses that every now and then he is in the habit of drinking a pint or so of straight alcohol, when his wife happens to have it in the house for non-medicinal purposes.

[1] "Causes, Types, and Treatment of Diarrhea in Adult Life," Journal of the American Medical Association, September 27, 1913.

For one year he has been disabled by a persistent diarrhea, ten or twelve movements occurring daily. During this time he has eaten enormously, often feeling so full after supper that he could scarcely walk, yet still hungry. For four months last winter he would vomit after each meal, but immediately after vomiting would devour more food in a vain effort to appease his inordinate appetite. His wife now works and so keeps him supplied with food.

The patient is found, on physical examination, to be moderately obese. Otherwise external examination is entirely negative. Likewise the blood and urine. The systolic blood-pressure is from 160 to 165 mm. Hg.; diastolic, 110 mm. Hg.

On a Schmidt test-diet there is no diarrhea, and after two days he is given house diet, which also produces no diarrhea. His wife avers that his "insides must have been burnt," for until she stopped using alcohol for household purposes he was constantly consuming it, undiluted, until he became so drunk that he could not move. Since she has stopped buying alcohol he has been better. October 21st he left the hospital, apparently in perfect health.

Discussion.—The association of diarrhea with alcoholism is a very familiar one, and in view of the negative findings, on physical examination, I see no reason to doubt that alcohol was the cause of all this patient's troubles. It is very striking that a man who has had diarrhea for an entire year should get over it within a week, in fact, within forty-eight hours, as a result of nothing in the world but abstention from alcohol and rest in bed. Such cases, however, are very familiar and have already been referred to. No doubt his habits of gourmandizing also played a part in upsetting him.

I would call attention to the fact that no medicine and no antidiarrhea diet was given in this case.

Case 82

An English laborer of forty-three entered the hospital October 21, 1910, for a continuous diarrhea of six months' duration, averaging three or four watery, sometimes bloody, movements a day. In this period he had lost 50 pounds, his usual weight being 160 pounds, and had become very weak. Attempts to work had been quite futile. There has been considerable burning pain in the left iliac fossa and the epigastrium and some colic before stools. He continued to eat ordinary food, with good appetite, and no vomiting, but frequently felt chilly, especially in the evening. For the past four or five months he had had a slight, dry cough. His previous history was good and

he had never been farther south than Baltimore. The past eleven months he had been living in New Hampshire, but has been told that several people in his neighborhood also had dysentery.

His stools were examined thirty-three times during his five weeks' stay in the hospital. The guaiac test was positive eight times, and negative in the remainder, otherwise there was nothing remarkable on gross or microscopic examination. Culture from the stools showed the colon bacillus as the only micro-organism present.

The patient was fairly nourished. Along and behind the right sternomastoid muscle was a chain of very hard, movable, non-tender

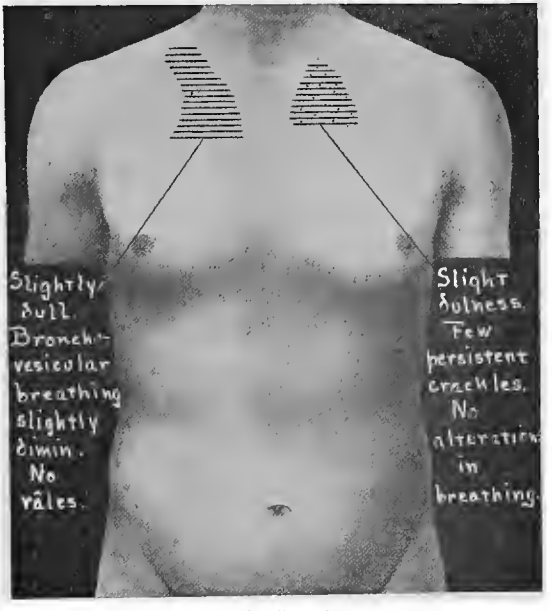
Slightly dull. Bronchi-vesicular breathing slightly dimin. No râles.
Slight dulness. Few persistent crackles. No alteration in breathing.

Fig. 80.—Signs in Case 82 at entrance.

glands, the size of a pea to that of a bean, partly conglomerate, not attached to the skin. The axillary and inguinal glands were somewhat enlarged. The epitrochlears were enlarged on both sides. Lungs showed the lesions pictured in Figs. 80, 81; *x*-ray examination showed extensive involvement of the left lung, as low as the fifth rib, apparently an old infiltration and largely healed. The right lung also showed involvement down as far as the third rib. The temperature was as in the accompanying chart (Fig. 82). Abdomen was dull everywhere except in the left upper quadrant. There was general tenderness on deep pressure. Otherwise physical examination was not remarkable. The diarrhea ceased after the first two

weeks of hospital care. During the last four weeks of his stay in the hospital he had absolutely no sputum and almost no cough.

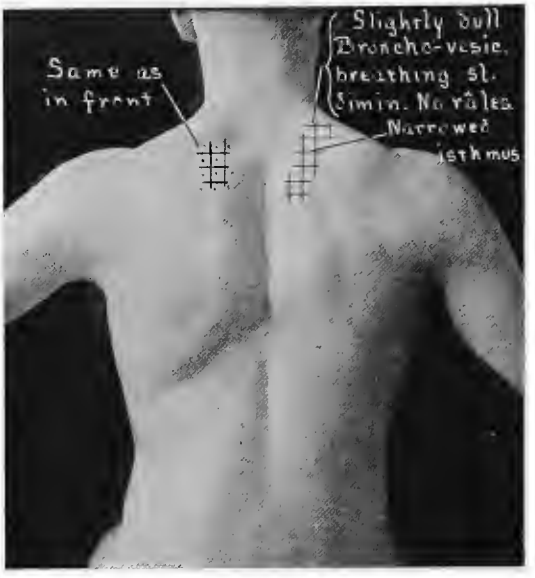

Fig. 81.—Signs in Case 82 at entrance.

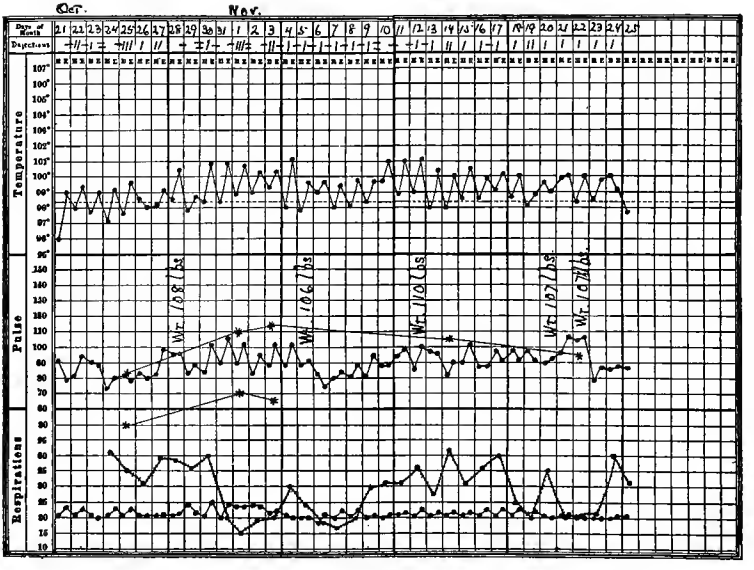

Fig. 82.—Chart of Case 82.

The diarrhea had entirely ceased after he was put to bed, November 13th. His weight on leaving the hospital was 107 pounds, within

a pound of that with which he entered. Apparently, rest in bed was the treatment which helped him most. Fat-free diet and colonic irri-

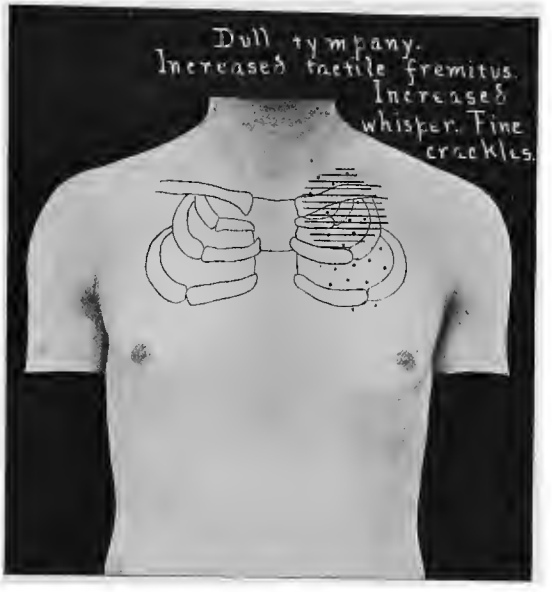

Fig. 83.—Signs in Case 82 on November 24th.

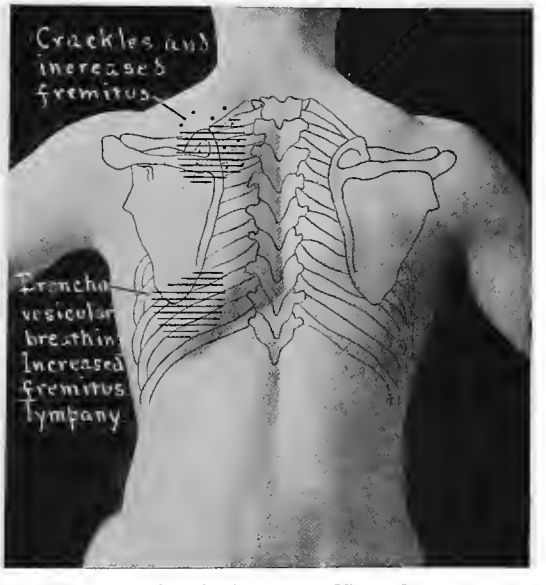

Fig. 84.—Signs in Case 82 on November 24th.

gations with 1-dram doses of bismuth, three times a day, gave him no special relief; Figs. 83 and 84 show the lesions found November 24th.

Discussion.—This case presents the picture of a diarrhea continuous for six months in a patient showing extensive pulmonary lesions, in all probability tuberculous. Although there is no pus in the stools, the frequent presence of the guaiac reaction makes it not improbable that intestinal ulcerations are present. This is not negatived by the fact that no diarrhea occurred after he was put to bed. This is often the case in ulcerative colitis.

The chief point of doubt is whether or not the diarrhea is of tuberculous origin. The fact that it complicates pulmonary tuberculosis in no way proves that the colitis is tuberculous. (For further discussion of this point see Case No. 80.) Even the finding of tubercle bacilli in the stools would not prove that the intestinal lesions were tuberculous, since the bacilli may come from swallowed sputa. The main point to be insisted upon in this case is that if the patient can master his pulmonary tuberculosis, there is not necessarily any incurable complication in the intestine to cloud the outlook.

The examination of the stools makes it unlikely that any specific type of infection (Amœba histolytica or Shiga's bacillus) is present.

Outcome.—The patient went home November 25, 1910, and died February 12, 1911. The diarrhea continued unchecked. There were no pulmonary symptoms.

Case 83

A kitchen man of thirty-five, born in Russia, entered the hospital September 13, 1910. The patient is a steady drinker and occasionally gets drunk. He also smokes to excess. He has had no previous sickness except typhoid, which he had in Russia many years ago. Three or four weeks ago he began to be bothered by diarrhea, eight or ten watery movements a day, without blood or tenesmus. At the same time he had severe, almost constant, headache, occasional attacks of vomiting, and on exertion experienced a pain referred to the hepatic area. He has also noticed shortness of breath, with palpitation and precordial pain on exertion.

Physical examination showed good nutrition. Pupils slightly irregular, otherwise normal. Glands and reflexes negative. The left border of cardiac dulness extended 13 cm. from the median line and was outside of the nipple. Right border 5 cm. from midsternal line. There was some increase in the width of the dull area behind the manubrium and a palpable impulse in the suprasternal notch. There was a harsh systolic murmur at the apex, transmitted inward and outward. In the axilla a diastolic murmur was heard. In the second

right interspace there was a blowing systolic murmur, different in pitch and quality from that at the apex. The aortic second was high pitched, sharp, and ringing. The pulses showed no Corrigan quality. The arteries were thickened, tortuous, and in places beaded. Blood-pressure 160 mm. Hg., systolic, at entrance; 105 mm. Hg., diastolic. The lungs showed dulness and a few fine crackles at each base behind. The liver extended from the sixth interspace, mammary line, to a point four fingers below the ribs, where an edge was indistinctly felt. Manipulation of this region caused pain and dilatation of the neck veins. The spleen was felt two fingers' breadth below the ribs and

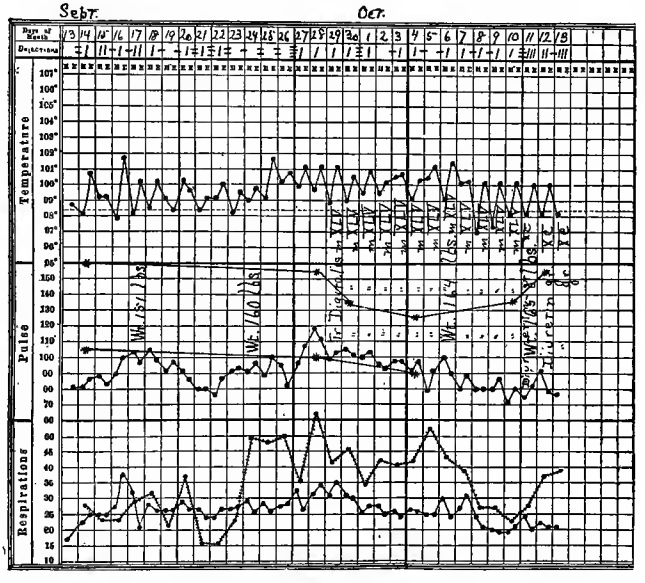

Fig. 85.—Chart of Case 83.

its percussion area was enlarged. The blood was negative. Temperature as shown in the accompanying chart (Fig. 85.)

The urine averaged 25 ounces in twenty-four hours during the first week of his stay in the hospital; after that, from 40 to 50 ounces; this increase corresponding with a fall in blood-pressure to 135, and on the 4th of October to 125. Diastolic pressure varied very little during these changes. The specific gravity of the urine varied from 1008 to 1012, with a slight trace of albumin, many hyaline, granular, and cellular casts, and a little blood, free and adherent. Later in the course of the disease casts were almost impossible to find. On the 18th of September the red cells numbered 4,300,000; hemoglobin, 60

per cent. The reds showed moderate achromia. The patient had at this time no symptoms whatever, seemed bright and happy. He was given potassium iodid and hydrargyrum until salivation was produced, but without any effect upon the temperature or other physical signs. Blood-cultures were negative.

The heart signs did not change at all, but toward the middle of September there was a little edema over the sacrum and in the legs. By the last of the month he was obviously losing ground. On the 28th he had a profuse nosebleed, requiring to be packed. The next day the blood showed: red cells, 3,000,000; white, 4500; hemoglobin, 54 per cent. The second blood-culture showed again negative results. The salivation produced by mercury continued into the early part of October. At this time the diastolic murmur could clearly be heard along the left border of the sternum. Pulmonic second sound was reduplicated. There was no thrill anywhere. The fundus of the eye was normal.

Discussion.—Headache and dyspnea are not symptoms of any form of enteritis, and suggest at once that this patient's diarrhea is symptomatic of some non-intestinal disease. The blood-pressure and the condition of the urine strongly suggest chronic nephritis, probably of the glomerular type. The nosebleeds further support this diagnosis.

Beyond this the early arterial changes, the splenic enlargement, and the evidences of aortic regurgitation, without previous history of rheumatism, chorea, or sore throat, lead us to consider syphilis as a possible cause for his symptoms. (Note the positive Wassermann reaction obtained at the Boston City Hospital and recorded below under Outcome.)

A glance at the chart reveals a fever not well accounted for either by glomerular nephritis or by late syphilis, such as he must have if there was any syphilis about him. Neither of these diseases causes such a fever as this patient had. This fact should have made us suspect that the cardiac murmurs might be due to an acute endocarditis, even though leukocytes were normal.

Outcome.—On the 13th of October he was transferred to Tewksbury Hospital, where he stayed two months without improvement, and then went to the Boston City Hospital, where his condition was essentially the same as that previously recorded, blood-pressure, May 22, 1911, being 130 mm. Hg. The Wassermann reaction at this time was strongly positive. On the 14th of September hemorrhages were found in the fundus of the right eye. On the 17th of June, 1911, after

a gradual failure and slight, irregular temperature, edema, hydrothorax, ascites, and anasarca, the patient died.

Autopsy showed subacute infectious endocarditis of the mitral and aortic valves; heart's weight, 775 grams; chronic glomerulonephritis.

It is interesting to speculate here whether the nephritis was the cause of the endocarditis or *vice versâ*. Libman's studies of subacute bacterial endocarditis (endocarditis lenta) led him to believe that chronic glomerula nephritis is often a result of emboli thrown off from an inflamed heart-valve. In view, however, of the enormous size of the heart in this case, it seems more probable that the nephritis has existed for a long time, and that the endocarditis should be regarded as a manifestation of lowered resistance to infection, dependent upon the nephritis.

Case 84

A metal polisher of twenty-eight, born in Russia, entered the hospital May 7, 1910. For six years, beginning eleven years ago, he has been a sailor, and has visited Australia, India, Egypt, Turkey, and Chili. The last five years he has done metal polishing, chiefly of brass, and uses an emery wheel, but has considered himself well until the present illness.

Diarrhea and cramps began two years ago and have been present continuously ever since, except for short intervals, never exceeding a week in duration. The cramps are never severe or localized and never radiate upward or downward. They precede stools, and are brought on by exertion, by soups, fruits, or large meals. His stools are brown and never contain blood. Bowels move every two hours at night and somewhat less frequently during the day. He is always hungry and has no nausea or vomiting, but is afraid to eat because of the effect upon his bowels. He has lost 7 pounds in two years.

The patient is well nourished, but markedly pale. He appears to have two radial arteries in his right wrist. Chest, abdomen, and extremities show nothing abnormal. Urine is normal. Blood contains 13,500 leukocytes per cubic millimeter, 6 per cent. of them being eosinophils. Red cells show slight achromia and some varieties in size. Feces show flagellates in great numbers, their rapid motion preventing accurate identification. An occasional egg of the trichocephalus is seen. The guaiac reaction is always positive, but there is no pus or obvious blood, no mucus or excess of food elements. On the 8th of May two or three amebæ are seen in active motion. The endoplasm is gradually and easily distinguished from the highly

refractive ectoplasm, even when the amebæ are at rest. The diameter seems to be from 35 to 50 microns. The nucleus is not made out and there is no contractile vacuole. One inclusion, apparently a red corpuscle, is seen. Charcot-Leyden crystals are numerous, some of them 50 microns in length.

Discussion.—This patient raises the question how we are to differentiate the harmless Amœba coli from the pathogenic ameba, ordinarily known as the Amœba histolytica or the ameba of dysentery. The histologic and tinctorial differentiæ will be referred to presently. Meantime, it is obvious that this patient has visited a number of countries, in any of which he might have picked up amebic dysentery. This disease is still further suggested by the long duration of the diarrhea and by the apparent efficiency of the ipecac treatment. (See below.)

The more important distinctions between the harmless ameba and the dysenteric ameba are as follows:

1. The dysenteric ameba, or Amœba histolytica, is more active in its movements, and these movements often persist for hours in the cold, while the harmless ameba (Amœba coli) is always more sluggish and soon loses its movements at room temperature.

2. The dysenteric ameba much more often contains red corpuscles and other cells within its protoplasm. The harmless ameba rarely takes these up.

3. In stained specimens the Amœba histolytica shows an indistinct nucleus containing but little chromatin, while the Amœba coli has a much clearer nucleus, containing abundant chromatin.

In the encysted state the Amœba histolytica has a smaller, less refractive, and thinner cyst, and usually contains the elongated refractive so-called "chromidial" bodies, which are not found in the Amœba coli. In this encysted state the nuclei of the Amœba histolytica are never more than 4, while those of the Amœba coli are 8 or more.[1]

Outcome.—The patient was given a diet of liquids and soft solids and the bowel was irrigated with 1 quart of quinin solution, 1:2500. Following this the diarrhea ceased and no amebæ could be found during the last ten days of his stay in the hospital. The bowel movements were formed and occurred but once daily. He left the hospital, much improved, May 20th, but returned November 29th, stating that for two months after his last treatment at the hospital he was quite well, then his diarrhea gradually returned and has continued

[1] Walker and Sellards, Philippine Journal of Science, Section B, vol. viii, No. 4, August, 1913.

since, though he has gained 4 or 5 pounds since he was last in the hospital and has worked until five days ago. At this time no amebæ could be found in the stools. Nevertheless, he was given the ipecac treatment, namely, 10 gr. of ipecac in salol-coated pills twice a day for three days; then, later, the same dosage for nine days. Quinin irrigations, 1:2000, were also given daily. The stools occurred only once or twice a day during his stay in the hospital. His weight at this time was 10 pounds greater than at his last entrance and the eosinophils made up 1 per cent. of the leukocytes present. December 19th he was discharged considerably relieved.

Case 85

A meat packer of twenty-two, born in Greece, entered the hospital January 23, 1911. The patient had always been perfectly well except that once, six months ago, he had been laid off for three days with a condition similar to the present. For the past three months he had felt unduly tired. His bowels move from three to five times a day. Duration of this diarrhea not clearly made out. (See Outpatient Department record No. 154,759.) Patient had lost no weight and had had no trouble with his urine. His appetite was excellent and he had worked until four days before entry.

Physical examination was entirely negative except as related to the stools, which contained in each slide examined a few eggs like those shown in the accompanying figures. Twice a free-swimming ciliated embryo was seen. There was a good deal of pus and mucus and a little blood in the well-formed stools.

After the first day in bed there was no diarrhea for a week. After that he began to have three or four stools a day. Rectal examination showed numerous polypoid projections, $\frac{1}{2}$ to 1 cm. long and about the same in thickness, but no ulcers. One of these polyps was removed and showed, on microscopic examination of paraffin sections, a tissue richly infiltrated with plasma-cells and some leukocytes, in the midst of which were eggs and embryos of the Schistosoma hæmatobium, surrounded by giant-cells. Atypical epithelial tubules, like those of the rectal mucous membranes, were also seen.

The patient was given "606," 0.6 gram into a muscle, but no particular effect was observed.

Discussion.—The findings on rectal examination and stool examination make any discussion of differential diagnosis unnecessary. The eggs shown in Figs. 86 and 87 are entirely characteristic of bilharzia disease. This parasite, as is well known, affects usually the

bladder, the rectum, or both, producing a most intractable form of chronic inflammation.

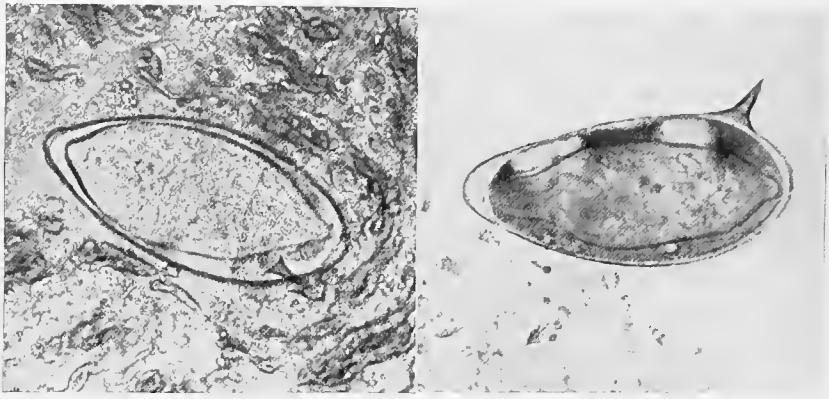

Fig. 86.—Unruptured bilharzia eggs. Note the lateral spine in each. (Photographs by L. S. Brown, of the Pathological Laboratory of the Massachusetts General Hospital. The case was under the care of Dr. Arthur K. Stone, by whose kind permission it is referred to here.)

This patient was taken into the hospital in order to see whether the effectiveness of salvarsan upon some organisms of the protozoan group extends to bilharzia disease. The outcome showed that there was apparently no such action.

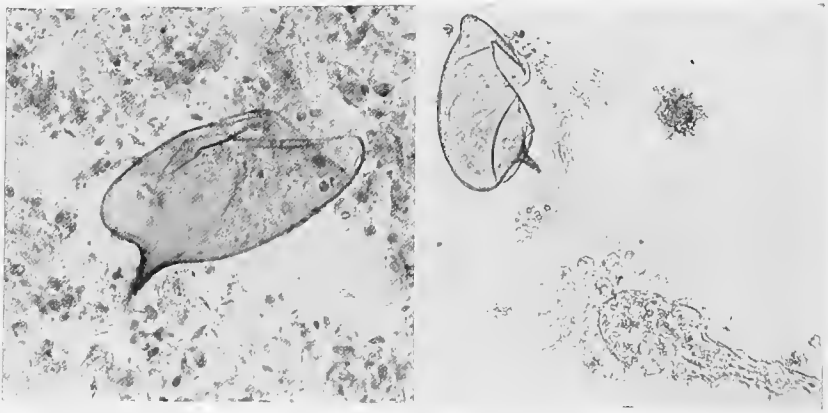

Fig. 87.—Ruptured bilharzia eggs. Near one the free embryo is visible. (Photographs by L. S. Brown, of the Pathological Laboratory of the Massachusetts General Hospital.)

Outcome.—The patient came in again on June 1, 1911, stating that since leaving the hospital, February 17th, he has had three or four movements a day, usually with some blood, but has worked con-

tinuously. The condition was exactly as before, and, after staying in the wards a couple of weeks and gaining 4 pounds, he was allowed to go home again. His blood on this occasion showed 9 per cent. of eosinophils in a total leukocyte count of 12,000.

September 14, 1912, the patient came to the dispensary for pains in the "calves" of both his legs, also a bad headache, especially on the left side, and slight pains in his abdomen. Examination of the stools showed spatters of soft, brick-red juice. Bilharzia eggs present. No food seen. Many soap and fatty acid crystals. Guaiac test positive. Pus-cells and blood present.

Case 86

A telephone operator of thirty-two entered the hospital March 21, 1911. His family history was entirely negative, and he had been quite well and strong until seven years ago, though he was in bed for some time at the age of nineteen, owing to stiff and painful knees. His work had never exposed him to lead-poisoning, as far as he knew, but for eighteen years he had lived in a house where drinking-water came through lead pipe. He denied venereal disease; was in the habit of taking four whiskies a day.

Seven years ago he had an attack of cramp-like abdominal pain, accompanying diarrhea and vomiting, and lasting a week. During the following year he had two or three similar attacks, and ever year since then he had been disabled several times by similar paroxysms. In each attack there was diarrhea, followed by griping pain. He had noticed no influence of food in the production of these attacks. For the past six months he had been out of work and had so much pain that he had been too discouraged to look for another job.

During the past two years he has several times fallen in the street on account of sudden dizziness, although he has never become unconscious, and has been able to get up again without assistance. For years he has had pains of a few seconds' duration, off and on, in the muscles of the thigh and calf. On further questioning he admits that these sensations are not genuine pain, but rather a tingling and numbness. He has no symptoms of bladder trouble and his eyesight is excellent.

For the above symptoms he was operated on four months ago by Dr. John C. Munro, at the Carney Hospital. A few adhesions were found and separated, but the symptoms continued as before. A year ago he was admitted to the Boston City Hospital for the tenth time, and was operated on by Dr. E. H. Nichols, who did laminectomy, ex-

posing the cord from the second to the sixth dorsal vertebræ, and cutting the dorsal nerve-roots at the level of the third, fourth, fifth, and sixth vertebræ, on both sides of the cord. The dura was edematous and considerably thickened. He stated that he experienced no relief after this operation. For the past month he had had some cough and sputum. His best weight four years ago, 125 pounds; at this time, 98 pounds. For the past seven years he had taken morphin, by the mouth, in gradually increasing amounts, until during the last six months he had needed 18 to 20 gr. a day.

The patient was poorly nourished and pale. His pupils were circular, equal, reacted normally to distance and sluggishly to light,

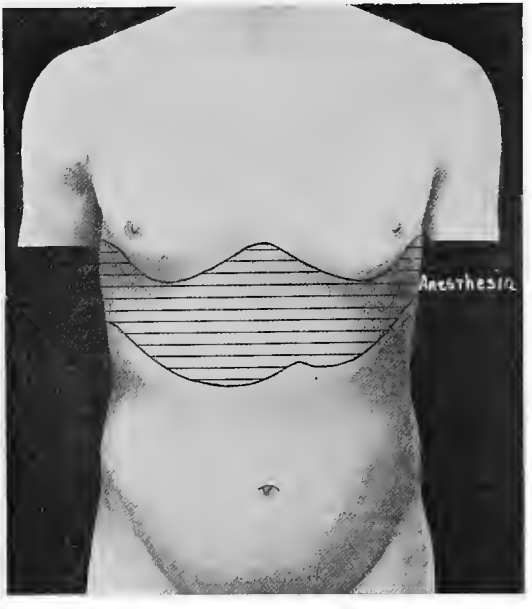

Fig. 88.—Numb area in Case 86.

especially the right pupil. There was no glandular enlargement. His teeth were very poor. He had a marked and typical lead-line on the gums. Except for a slight soft systolic murmur at the apex, the chest was negative, likewise the abdomen. The right knee-jerk active; the left present, but only on reinforcement. The right ankle-jerk likewise active; left not obtained. An area of anesthesia was mapped as shown in Figs. 88, 89. The urine showed nothing of interest. Blood-pressure, 130 mm. Hg. The red cells showed slight achromia, and in every few fields of the oil-immersion lens a stippled cell. The leukocytes, 13,000. On lumbar puncture a limpid fluid was

obtained in which the white cells numbered 74 per cubic millimeter, 99 per cent. of them being lymphocytes. The fundus oculi normal. Wassermann reaction negative in the blood. For a few days he excreted 5 to 10 grams of sugar in the urine, and this was still present when he left the hospital.

Discussion.—The history of exposure to lead-poisoning through drinking-water makes it possible that the abdominal pain is lead-colic. It is very unusual, however, for this colic to be associated with diarrhea. Constipation is the rule. Nothing in the physical examination excludes lead, and there is every reason to suppose that part, at least, of the patient's sufferings are due to this metal, since

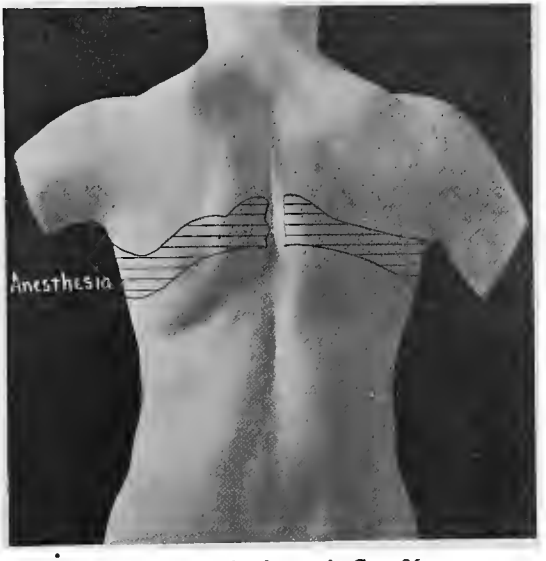

Fig. 89.—Numb area in Case 86.

the gums show its presence and the blood examination strongly suggests the same thing.

Nevertheless, the history of very brief pains in the legs and the long intervals between the attacks of abdominal pain should suggest some other disease, even in advance of the physical examination.

The absence of the left knee-jerk and ankle-jerk and the poor reaction of the pupils to light prepare us for the findings in the spinal fluid, which leave no reasonable doubt that the patient's abdominal attacks represent gastric crises in tabes dorsalis. But for the examination of the spinal fluid, this diagnosis might not have been clear. As it is, the case adds one to the long list of surgical blunders due to failure

to examine the nervous system. During the past five years I have known 5 patients who, though suffering from the gastric crises of tabes, were operated upon by competent surgeons in the hope of finding gall-stones, peptic ulcer, or acute appendicitis. Even after the operation surgeons sometimes fail to notice their mistake. A shriveled appendix is removed and the case is called chronic appendicitis.

This case also illustrates the proneness of surgeons to suppose that adhesions are a sufficient explanation of well-marked clinical symptoms. A very large number of unnecessary or mistaken operations fail to be recognized as such, and are called successful because a few adhesions are found and divided. In my experience, adhesions in any part of the abdominal cavity are very seldom, *per se*, of any importance.

Had not the evidences of tabes been found in this case, one might have been forced to investigate the possibility that the pain was due to morphin. Morphin is a very frequent cause of pain, a fact which does not seem to me sufficiently realized. Just how the drug produces pain I cannot say, but practically every patient suffering from the morphin-habit takes the drug at times for the relief of some pain, which will stop only when the drug is eliminated from the system and the habit is broken up. I have seen lightning pains in a tabetic which ceased as soon as the morphin-habit, contracted for the relief of these same pains, was broken. In this case one must suppose that the pain due to tabes itself had long ago ceased, its place being taken by suffering connected in some way with the drug habit.

Outcome.—As the morphin-habit seemed to be the most important feature of the patient's case at the time, he was transferred on April 6th to Tewksbury.

Case 87

A housewife of forty entered the hospital April 11, 1911. The patient has been nervous all her life and has had stomach trouble, consisting of vague epigastric distress after meals, never severe. Has also had a good many sick headaches. Throughout her life she has had a dread of crowds, and never goes to the theater without a feeling of great discomfort. In church she sits as far back as possible. During the past year she has sometimes fainted when in crowds.

She had an Alexander operation nine years ago, and seven years ago was operated upon for the freeing of peri-uterine adhesions.

For the past year she has had diarrhea, gradually increasing, until now she has six to twelve stools a day, which are occasionally very

dark, though she is taking no medicine. Her fainting attacks, formerly rare, have now become much more frequent. She consulted her physician in November, 1910, for the above symptoms, and also on account of weakness and dyspnea. At that time she says that her blood showed "marked secondary anemia," with a hemoglobin of 60 per cent. Under treatment she greatly improved, and hemoglobin rose to 85 per cent., but in the past few weeks her symptoms have

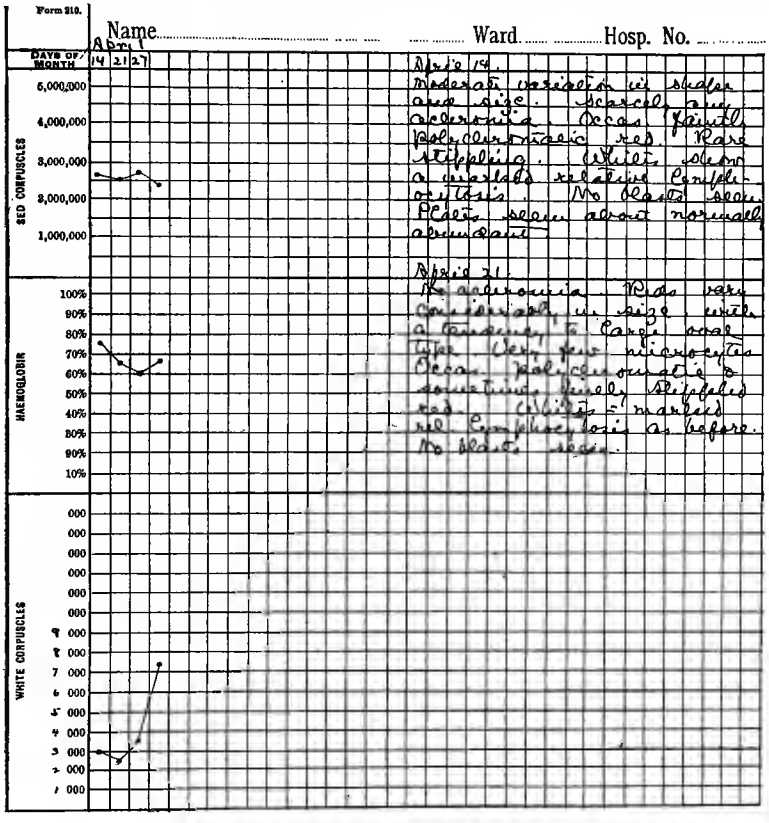

Fig. 90.—Blood chart of Case 87.

recurred and she has vomited very frequently. According to her statement she retains hardly any food. Three years ago her weight was 138 pounds; in November, 1910, 132 pounds; now, 125 pounds.

On physical examination she is well nourished, nervous, and apprehensive. Her hands in constant motion, with some coarse tremor. Skin, scleræ, and mucous membranes of good color. Visceral examination negative. Reflexes and pupils negative. Very slight soft edema of the ankles. Urine normal. Blood shows reds, 2,600,000; whites,

3000; hemoglobin, 70 per cent. During her month's stay in the hospital the course of the red cells, white cells, and hemoglobin was as shown in the accompanying chart (Fig. 90). In the stained smear the red cells show moderate variations in size and shape, no achromia. Occasional slightly abnormal staining or stippling. No nucleated forms. Among the leukocytes 82 per cent. are lymphocytes, the rest polynuclears. This percentage does not vary during her stay in the hospital. Blood-plates seem to be about normal in number.

The stools were negative to guaiac and showed nothing else of interest. The patient's tongue was unusually smooth and she had frequent attacks of herpetic stomatitis. The range of temperature is seen in Fig. 91.

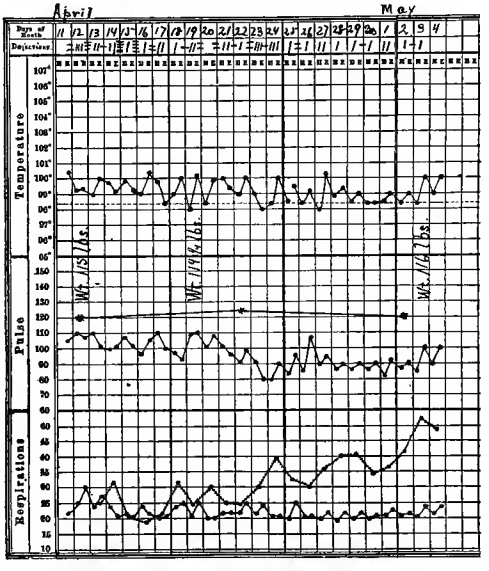

Fig. 91.—Chart of Case 87.

Discussion.—The neurotic taint in this case is so obvious that one suspects a nervous diarrhea, but the presence of blood in the stools rules this out.

The tremor and the slight fever suggests that a thyrotoxicosis (Graves' disease) may be the cause of the symptoms, but the absence of any tachycardia, any exophthalmos or thyroid enlargement, and the presence of marked anemia make this very improbable.

Cancer of the bowel would produce a similar diarrhea and anemia, but if this diagnosis were correct, one would expect periods of pain, constipation, visible peristalsis, abdominal distention, and intestinal

noise. The good nutrition of the patient is further evidence against the diagnosis of cancer.

Colitis, with or without ulceration, is very improbable in view of the negative condition of the stools.

Pernicious anemia is suggested by the condition of the mouth, the details of the blood-picture, and the tendency to periodicity which the history portrays.

Outcome.—She was given two doses of "606," the first, 0.3 gram; the second, a week later, 0.2 gram. The diarrhea ceased after the second week, but slight fever continued and the blood showed no considerable improvement. Nevertheless, on the 4th of May, she felt so comfortable that she decided to go home.

In this, as in many other cases of pernicious anemia, symptomatic improvement occurs, though the blood remains unchanged. The effect of salvarsan is sometimes much more favorable than in this case. Under its use, as also under treatment by atoxyl, some patients improve very markedly not only in their symptoms, but in their blood-picture. Arsenic, given in the form of Fowler's solution, may be less effective than when it is taken as salvarsan or atoxyl. It must be recognized, however, that no known form of treatment, whether by arsenic or by the recently much-heralded thorium, or by splenectomy, does anything more than retard for a few months the fatal termination of the disease.

This patient died on the 6th of June, 1911.

Case 88

A banker of thirty-six entered the hospital July 14, 1911. The patient's father died of "anemia" at sixty-six; otherwise family history is excellent and past history negative, except that he has had ever since twelve years of age a good many attacks of abdominal pain and diarrhea. Two years ago he weighed 145 pounds and felt reasonably well, when he was attacked by a severe diarrhea and was in bed three weeks. Since then he has never been really vigorous. Most of last summer he was in bed in a hospital and gained somewhat, but every few weeks he has attacks of pain and diarrhea, the pain being at times very severe, but never localized. He rarely vomits, but several times has had slight jaundice. Tenesmus has been a troublesome symptom. Since January of this year it has been noticed that he is paler than usual. His best weight, 145 pounds, was maintained up to two years ago, since when he has gradually fallen to 120 pounds. He worked until the 28th of June.

On physical examination he is rather sallow, mucous membranes pale. A soft systolic murmur replaces the first heart sound all over the precordia. The aortic second sound is faint. Abdomen shows a marked visible pulsation in the epigastrium, and some tenderness with slight rigidity, most notable in the region of the gall-bladder. Visceral examination and the reflexes otherwise normal. Proctoscopic examination shows nothing abnormal in the lower 8 inches of the bowel. The stools are negative to guaiac and show no other abnormalities. A specimen of urine, taken under aseptic precautions, shows moderate growth of streptococci. Temperature ranges as seen in the accompanying chart (Fig. 92).

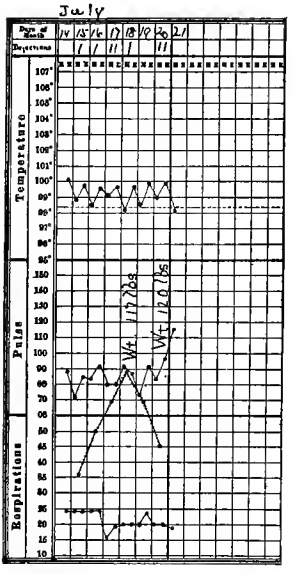

Fig. 92.—Chart of Case 88.

The blood shows red cells, 1,500,000; white cells, 3000; hemoglobin, 40 per cent. In the stained smear the red cells show marked variations in size and shape, with many huge oval forms. One megaloblast and one normoblast are seen while counting 200 leukocytes, among which 65 per cent. are lymphocytes; the rest, polynuclears. A few stippled forms and many abnormal staining reactions were found. The urine is negative.

Discussion.—The history of this case gives no distinct clue to its nature. The abdominal pulsation might bring aneurysm into consideration. The absence of pain in the back, of any definite tumor, and the central position of the pulsation (that of aneurysm is usually to one side of the median line) make this very improbable. Moreover, with such an anemia as is here present, unusual pulsations of one or another artery are very common. Indeed, they have often been mistaken for aneurysms, as in the case reported by Dr. A. R. Edwards, in the "Transactions of the Association of American Physicians," for the year 1902.

The presence of streptococci in the urine points to a mild degree of urinary sepsis. In the absence of pus, this finding is probably not of great importance. It certainly cannot be responsible for so marked an anemia.

The epigastric tenderness and rigidity, taken in connection with the evidence of a severe anemia, bring cancer of the stomach into

consideration, but the history of two years' illness, the rarity of vomiting, and the gradual and only moderate loss of weight are against this idea.

The details of the blood-picture, with the negative results of physical examination and of *x*-ray examination, point straight to pernicious anemia.

Outcome.—On the 17th the edge of the spleen was felt. After the 18th the gastric symptoms were very slight. The appetite generally good. Bismuth *x*-ray examinations showed that a considerable amount of bismuth remained in the stomach an hour after ingestion, but no intestinal lesion and no obstruction of the pylorus was made out. Stasis of this degree has been noted in several of our cases of pernicious anemia, proved by autopsy to be such.

The patient went home, without any change in his condition, July 21st. He improved somewhat after this, and about the 1st of January, 1912, was much better, but in April he began to run down again, and on the 15th of May he died.

Case 89

A housewife of forty-seven entered the hospital October 6, 1911. The patient's mother died at sixty-one of a "growth in the liver." One brother died of consumption at twenty-three. The patient has had no serious illness, but has always been very nervous and lacked vitality. Since the menopause, two years ago, she has had "nervous prostration and neurasthenia" many times. A year ago she had "acute indigestion," and since then has suffered constantly from sour stomach. For the past few months she has vomited sour material a good many times. She says her pain is due to hydrochloric acid trickling about the abdominal interstices and coming up into her throat in burning waves. She has never vomited blood.

One week ago she began to have severe diarrhea, and her abdomen, previously "small and shriveled," began to be distended. With this change came cramp-like pain and constant soreness in the lower abdomen.

Since her stomach trouble began a year ago her legs have been swollen and have felt very heavy at times. This has been especially marked in the last two weeks. A year ago she weighed 135 pounds, with clothes, but she has lost much weight since, and for the past year has done but little housework and has been recumbent most of the time, though lying down often increases her abdominal pain.

On physical examination the patient was found to be emaciated

and so weak that she spoke with difficulty. Pupils and reflexes negative. Tongue dry and cracked. Left border of cardiac dulness was 3 cm. outside the nipple line. The apex impulse could be seen and felt indistinctly almost as far as the anterior axillary line. The sounds were of good quality, the action regular, the first apex sound loud, accompanied by a slight systolic murmur. The aortic second and pulmonic second sounds were of equal intensity. The pulses were equal and normal in volume and tension. Artery walls not felt. Lungs negative.

Abdomen moderately distended; it showed dulness in the flanks, shifting with change of position; also a fluid wave. The vaginal walls seemed to be pushed together by masses of considerable hardness, apparently outside the vault. The cervix uteri was normal, the fundus not made out. The rectum, like the vagina, seemed to be enlarged by external pressure, but both examinations were unsatisfactory because of pain.

There was marked soft edema below the knees. The patient vomited almost everything and could not hold fluid by rectum. The stools were small and consisted largely of liquid and mucus. Operation was considered, but discouraged.

Discussion.—Although this patient has been supposed to have nervous prostration, the fact that her troubles began after forty makes this improbable.

Stomach symptoms beginning at her age and followed by swelling of the legs, even in recumbency, make a very ominous combination of symptoms. It suggests gastric cancer followed by peritoneal metastases. The dropsy is not at all easy to explain on the ground of any cardiac disease, for although the heart shows evidences of enlargement and of weakness, the dropsical fluid seems to be confined to the abdomen and legs, the lungs remaining clear. The finding of pelvic masses went to confirm the diagnosis suggested above.

Outcome.—The patient died October 15th. Autopsy showed a gastric cancer of the "fibromatous" infiltrating type, extending not only throughout the stomach, but over a considerable part of the large intestine in the form of a tough, whitish membrane, resembling that of chronic peritonitis, also spreading along the peritoneal surface from the stomach by contiguity. The stomach was not enlarged, showed no tumor, no ulceration, and no pyloric obstruction. The pelvis was wholly clear and showed no glandular metastases. One ureter was blocked by a cancerous membrane and a hydronephrosis had resulted on that side. The other kidney showed suppurative

nephritis. The cancerous growth along the large intestine had resulted in numerous carcinomatous strictures. There were also some cancerous nodules in the right kidney and in certain peritoneal lymphnodes.

The heart showed a well-marked mitral stenosis, though the organ weighed only 212 grams. Moderate ascites was present.

Case 90

A French Canadian barber of forty-four entered the hospital September 26, 1911. For years, he says, his bowels have moved three or four times a day, usually in the morning, but several times more later in the day if he drinks cold water. He has noticed nothing remarkable about the movements and has had no tenesmus. He thinks he has lost about 15 pounds in the past year. Liquid diet, especially milk, makes his diarrhea worse. On a diet of meat alone he has only one or two movements a day.

Eighteen days ago he got a cold in his head, felt chilly, and had vague pains in his legs and back. These symptoms have continued since. A nasal discharge is very profuse in the morning, sometimes slightly blood tinged. A frontal headache, more marked on the left side, has been present from the beginning of his cold. It begins in the morning, before he gets up, and wears away toward night. His nose, cheek-bones, and bones behind his ears are sore. He has had some cough for eighteen days and raises a little thick, yellow sputum. Appetite is very poor, and he has spells of retching every morning since the cold came on.

Physical examination shows poor nutrition, moderate pallor. Pupils slightly irregular, equal, reacting sluggishly. The glands on the left side of the neck are slightly enlarged and tender. Both epitrochlears are palpable; they are about the size of small beans. The throat shows a dry, chronic pharyngitis. The first heart sound is short and feeble, otherwise the heart shows nothing abnormal. The radials are moderately thickened and tortuous. Blood-pressure, systolic, 150 mm. Hg.; diastolic, 110 mm. Hg. Physiologic peculiarities of the right pulmonary apex seem somewhat exaggerated. A few tortuous dilated veins are seen over the abdomen, which is otherwise negative. The reflexes are normal. There is moderate tenderness over the left eyebrow, none over the right. Mastoid and cheek-bones not tender. White corpuscles, 13,800, with a normal differential count. Urine averages 45 ounces in twenty-four hours, a few hyaline or granular casts. The range of the temperature is seen in the ac-

companying chart (Fig. 93). Examination by Dr. Algernon Coolidge showed acute frontal sinusitis, in the stage of recovery, and chronic atrophic rhinitis. Rectal examination showed that the sphincter admitted the tip of the finger only.

Discussion.—The long duration of the intestinal symptoms in this case makes it natural to speculate whether the patient is not one of those persons who habitually have several movements of the bowel each day while in full health. The loss of 15 pounds in weight within a year, however, makes this supposition improbable.

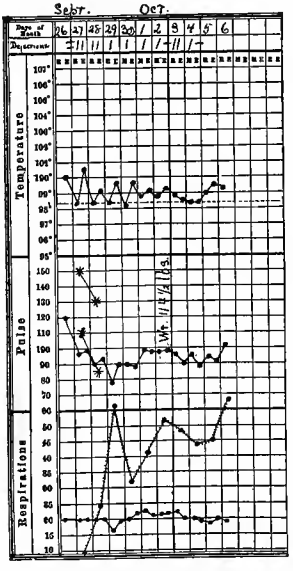

Fig. 93.—Chart of Case 90.

From the history alone no diagnosis is possible in this case. The most definite points are the loss of weight and the presence of some infection of the upper air-passages and facial bone-cavities. The presence of a rectal stricture is a much more enlightening datum, and suggests at once the possibility of syphilis. This is further strengthened by the irregularity and sluggishness of the pupils, by the general glandular enlargement, the premature sclerosis of the arteries, and the slight elevation of blood-pressure.

Outcome.—All attempts to penetrate further into the rectum were prevented by pain. Dr. Daniel F. Jones believed this sphincter to be of syphilitic origin and advised gradual dilatation with bougies. Wassermann reaction was negative. Mercurial inunctions and iodid of potash were given during his stay in the hospital. Diarrhea soon ceased and the frontal sinus cleared up.

Case 91

A freight conductor of twenty-seven entered the hospital October 27, 1911, complaining of a diarrhea of eight days' duration. His mother died of inflammation of the bowels. His wife was then under treatment for syphilis. Wassermann reaction positive. One child, aged three and a half years, had iritis and was also under treatment. One child died, at two months, of syphilis. The patient himself had a hard chancre six years ago, but no other symptoms, and had considered himself entirely well until of late. In this attack he had been

aware of headache and fever since the second day and had felt increasingly weak, but kept at work until two days before. Since that he had stayed at home, but had not remained in bed.

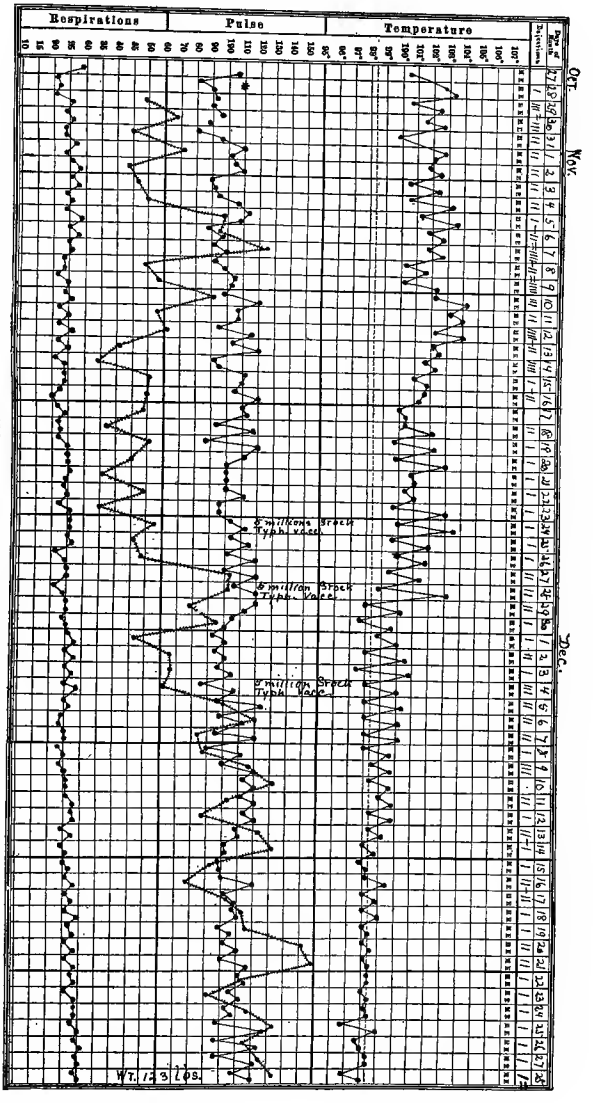

Fig. 94.—Chart of Case 91.

Physical examination showed good nutrition. Nothing abnormal in the internal viscera. Blood-pressure, 110 mm. Hg. Temperature as in the accompanying chart (Fig. 94). Urine normal. White corpuscles, 8000. *Widal reaction negative.*

Discussion.—Here we have an obvious syphilitic history in the patient and his family. In this infection diarrhea may result either as a part of the general intoxication or from a stricture of the rectum, with irritation of the bowel above it from retained feces. But for the blood-culture, mentioned below, it certainly would have been impossible to make a diagnosis of this patient's trouble on the 27th of October. When one looks at the chart and takes it in connection with a physical examination, which enables us to exclude tuberculosis and sepsis with considerable probability, typhoid fever becomes probable, even in view of the negative Widal reaction.

Outcome.—Blood-culture, October 28th, was positive for typhoid bacilli. Widal reaction did not become positive until November 9th. White corpuscles ranged at their highest to 10,000, November 23d. Five days before this he had a moderate-sized intestinal hemorrhage, which was treated by starvation and morphin. The course of his disease was otherwise uneventful, and he left the hospital in good condition January 4, 1912.

Case 92

An unmarried woman of twenty-eight, living at home, entered the hospital December 2, 1911. Her family history and past history were not remarkable. Until six years ago, when she had the measles and was sick for four weeks, she was well, but since that time she says that "her stomach has never been right." Her bowels have moved from two to five times a day, and four times she has noticed a small amount of fresh blood in the movements. She has distress after her meals and belches much gas and sour material. She has no vomiting and no sharp or localized pain. Her discomfort is sometimes relieved by hot drinks. Her weight four months ago was 128 pounds; three weeks ago, 112 pounds. She has worked during the whole of her illness except for a vacation of three weeks in July.

On examination the patient was well nourished. Chest negative. Abdomen showed slight diffuse tenderness and a firm, slightly tender sausage-shaped tumor in each lower quadrant. There was no spasm, but much intestinal noise. The right kidney easily palpable. Blood-pressure, 110 mm. Hg. Blood and urine normal. A stool showed no food residue to the naked eye, but under the microscope much undigested food was seen, with considerable mucus and a positive guaiac test. Bacteriologic examination of the stools showed nothing remarkable. She remained three weeks in the ward and gained 6 pounds. Tube examination of the stomach showed nothing wrong,

except that hydrochloric acid was absent on one occasion. After the 10th of December her bowels moved regularly and her appetite was fair. The epigastric soreness and tenderness persisted. She left the hospital December 24th.

Discussion.—There is nothing in this case to indicate organic disease. The sausage-shaped tumors are probably fecal. Her diarrhea is probably the expression of poor general condition. The presence of undigested food, under the microscope, is of no special importance, in view of the repeated disappearance of her diarrhea under no special treatment except rest. In many cases of this type it turns out that diarrhea is dependent upon constipation and the irritation produced by this. Many of these cases have pain and pass mucus, so that the term "mucous colitis" is applied to them, but the distinction between this type of disease and ordinary constipation is by no means a sharp one, especially when the trouble occurs in high-strung women.

Outcome.—The patient has been followed by Drs. H. F. Hewes and John W. Dewis since leaving the hospital. The former considered the case one of functional diarrhea, with incapacity to take care of fats. When she rests the diarrhea ceases. When she gets tired, it recurs and lasts a month or so. I agree with Dr. Hewes' diagnosis.

January 12, 1912, Dr. Scudder operated, removed an appendix, and severed some adhesions about the ascending colon. There were also adhesions extending from the duodenum to the gall-bladder and some indications of a Lane's kink. There was no evidence of gall-stones. The stomach and pancreas were also explored through the epigastric incision and nothing found.

Through the summer of 1912 she was under the care of Dr. John W. Dewis. In August the hemoglobin was 75 per cent., and a stained specimen showed moderate achromia. Physical examination and examination of the stomach contents and feces showed nothing abnormal. November 13, 1912, she reported, saying that she was doing excellently and feeling like her old self. The blood was then normal.

Case 93

A cigarmaker of forty-two entered the hospital March 17, 1912. Family history and past history are negative except that one sister died of cancer, situation unknown. Four weeks ago he began to have a bloody dysentery. He had committed no indiscretion in diet and

there were no similar cases at his boarding-house. The day after the onset of this trouble he took to bed and has been there ever since, suffering from slight fever with pains in his arms, legs, and throat. For the last two weeks he has had headache, increasing mental confusion, and loss of memory. His diarrhea has now ceased and his bowels are moving daily with laxatives.

The predominating symptoms at entrance are cerebral. Drowsiness, slowness in answering questions, and aphasia are marked. He appears to have forgotten many important events of his life and has no clear idea of his present illness. He would often stop in the middle of a sentence, yet show no consciousness that he had stopped. Occasionally he stuttered or slurred over words.

Physical examination shows exaggeration of the knee-, elbow-, and wrist-jerks. No ankle-clonus or Babinski. The patient's movements seem slightly unsteady, but he can write and pick up objects without difficulty. Physical examination is otherwise quite negative. The urine is negative. Blood-pressure, 140 mm. Hg. Wassermann reaction negative. Stools negative. The blood shows 19,000 leukocytes, March 17th, with 90 per cent. hemoglobin. Among the white cells there are polynuclears, 43 per cent.; lymphocytes, 30 per cent.; eosinophils, 27 per cent. March 21st the leukocytes are 27,500, with polynuclears, 37 per cent.; lymphocytes, 23 per cent.; eosinophils, 39 per cent. Mast-cells, 1 per cent.

On the day after entrance a marked injection of the conjunctivæ and slight edema under the eyes were noticed. This, with the eosinophilia, led to an examination of a bit of calf muscle, where trichinæ were found. Within a week the mental symptoms wholly cleared up and the man seemed entirely normal. At no time was there any marked muscular soreness, but Dr. Henry Jackson, who had seen him previous to his entrance to the hospital, reported that he had been eating poorly cooked sausages before the onset of the present attack.

Discussion.—The mental symptoms which were so prominent in the clinical picture of this patient's illness would naturally suggest arteriosclerosis or dementia paralytica. As his diarrhea had ceased before he came under observation, his only symptoms, beyond the psychosis just mentioned, were headache, slight fever, and generalized pains.

With these data only and without the routine blood examination, which has been long one of our most valuable safeguards against errors of diagnosis, this case certainly could not have been unraveled, but the eosinophilia, once discovered, has enormous importance in this

case because most of the causes for that symptom (causes such as intestinal parasites, chronic skin diseases, and anaphylactic reactions) can be easily excluded. This done, trichiniasis is at once suggested.

Case 94

A clothing salesman of thirty-one, born in Russia, entered the hospital June 3, 1912. He has been troubled for four weeks with diarrhea, severe in the last four or five days, with noticeable loss of weight and strength. These are the patient's chief complaints. At present he has twelve or more movements daily, consisting of mucus, blood, and watery fluid. Preceding each stool there is cramp-like pain in the lower abdomen. At other times no pain. The appetite is fair, but he frequently has slight epigastric discomfort an hour after meals. Has noticed slight dyspnea on exertion and some swelling of the ankles. Four months ago his weight was 155 pounds, with clothes; June 12th it was 129 pounds, without clothes.

Physical examination shows fair nutrition. Negative pupils and reflexes. Chest negative. In the abdomen nothing of interest except a sausage-shaped mass in the left lower quadrant.

Microscopically the stools show mucus, blood, epithelial cells, and leukocytes, with very little fecal matter. The sigmoidoscope shows that the mucous membrane of the rectum and sigmoid, as far up as visible, is red and covered with numerous minute ulcerations and blood-clots. It is subsequently learned that the patient spent six weeks in Rutland, at a boarding-house for tuberculosis, but was not in the sanitarium. This was six years ago, following a cough which had lasted twelve weeks.

The patient's blood and urine are not remarkable except that the blood-smear shows 6 per cent. of eosinophils. The Wassermann reaction is negative. Culture from the stools shows the gas bacillus. A pint of 5 per cent. silver nitrate solution is injected June 5th and 9th, but is held only a minute and produces no improvement.

Discussion.—The presence of 6 per cent. eosinophils in this patient's blood suggests that the diarrhea may be due to some intestinal parasite, but the examination of the stools showed no such parasite and the eosinophilia remained unexplained.

The history of a residence at a health resort for tuberculosis, after a cough which lasted twelve weeks, makes it necessary to consider tuberculosis of the bowel, but the fact that six years have elapsed since the patient has had any pulmonary symptoms, and that his

lungs are now normal, makes it unlikely that tuberculosis now exists in the bowel.

Direct inspection of the bowel proves the presence of an ulcerative colitis, the causal agent unknown. There is no good reason for connecting the presence of a gas bacillus with the diarrhea. Cases of this type represent an unexplored country in medicine. We know nothing of their cause and but little of their prognosis and treatment.

Outcome.—June 12th he left the hospital unimproved. On the 22d of June Dr. Daniel F. Jones opened the bowel at the cecum, producing an artificial anus, and instituted regular washings of the colon with normal saline solution, injected through the artificial opening, twice daily. This was kept up until the 25th of August. By that time the opening had closed so that no feces escaped, yet it was sufficiently open to permit the colonic washes to be continued. He went to work again in October, and by December 5th had gained 25 pounds and was still free from diarrhea, though his movements occasionally contained a little blood. Later he relapsed, and on May 22, 1914, reported that he was in about the same condition as when he first entered the hospital.

Case 95

A mechanic of thirty-four entered the hospital May 17, 1912. The patient's family history was negative. Fourteen years ago he had a chancre and a bubo. Was treated by an army doctor. While in the Philippines in 1899 he had mountain fever and was sick for ten days. Otherwise he had been well until the present illness. In the autumn of 1909, while in Georgia with Buffalo Bill's show, he began to have diarrhea, the stools preceded by severe cramps, and consisting of mucus and dark, clotted blood. In the following winter he was for three months in St. John's Hospital in Brooklyn, New York. The next spring he was able to do heavy work and has kept at it ever since, though having occasional cramps and one or two loose stools daily. He has eaten no meat, potato, cabbage, peas, or corn.

Nine months before entry his diarrhea recurred, and three months before he gave up work. For the past six weeks he had had twelve to eighteen stools a day and a constant burning pain in the abdomen. His appetite was good, but if he ate as much as he desired he had to vomit, though the vomiting was not preceded by nausea. Four years ago he weighed 180 pounds; six months ago, 169 pounds, in his clothes; at this time, 145½ pounds, without clothes.

Physical examination shows slight tenderness along the colon on

the right side of the abdomen. Otherwise the internal viscera are negative. The blood showed 29,000 leukocytes, with a polynucleosis at the time of entrance. Four days later, leukocytes, 16,500. The urine was negative. The stools showed many amebæ in active motion, some of them containing numerous included red corpuscles.

Discussion.—Repeated and prolonged attacks of diarrhea in a patient who has lived in the tropics are strong presumptive evidence of amebic dysentery. A careful study of the characteristics of the amebæ found in the stools dispelled all doubt of the diagnosis. The case is detailed here chiefly on account of the treatment followed.

Outcome.—The patient was given quinin injections, with some relief, but May 20th the following treatment was substituted: The patient received no food except broth after 12 noon of the first day of treatment. At 6 P. M. he was given 40 gr. of ipecac in 5-gr. capsules coated with keratin. Each night, after a similar half-day's starvation, the patient was given ipecac, the dose being reduced 5 gr. each day until a dose of 10 gr. was reached. The latter then continued each night. The patient bore this treatment excellently well. Pain during bowel movements stopped within a few days, the first relief, he says, since the onset of his trouble. The bowel movements at first became very watery, several large evacuations taking place during the night and the day. By May 30th he had only one or two movements in twenty-four hours. The feces were formed and amebæ could no longer be found. Several of the large doses of ipecac caused nausea and slight watery vomiting three hours after taking, but only once was the medicine vomited (the 25-gr. dose). On the 31st he left the hospital, preferring to finish up treatment at home.

Now that we have the emetin treatment, introduced soon after this date by Rogers, we need no longer struggle against the difficulties of administering ipecac.

Case 96

A conductor of thirty, born in Austria, here thirteen years, entered the hospital March 30, 1912. For two years, without known cause, he had been having diarrhea with a few intervals of comparative freedom. His family and past history negative. The stools were three to twelve a day and preceded by cramps. Until two weeks ago his appetite had been good. He had had no vomiting or other symptoms. Three years ago he weighed 198 pounds, with clothes; now 149 pounds, without clothes. His bowels never move at night.

On physical examination he was not emaciated, muscular, but looked

worried. Visceral examination, together with the blood and urine, temperature, pulse and respiration, showed nothing abnormal. Proctoscopic examination in the Out-patient Department was negative. The stools showed no blood or pus or food residue, and were always negative to guaiac. During a week's stay in the hospital the patient had but one movement daily while under treatment by buttermilk, and a diet consisting of eggs, fish, and meat, with one slice of toast three times a day. Toward the end of his stay he was so constipated he had to receive laxatives.

Discussion.—Of special importance seems to me the fact that this man's bowels never move at night. I have never known a case of diarrhea due to ulcerative enteritis in a patient whose bowels move only in the daytime. Moreover, the examination of the stools has never shown evidence of intestinal ulceration, and the patient's weight has been steadily though rather slowly increasing. The case remains a somewhat mysterious one, as it is difficult to conceive that psychic causes or mere habit can be responsible for so long a trouble in a patient of this type and temperament. He shows no evidence of a nervous make-up.

Outcome.—For two weeks after leaving the hospital the patient was free from diarrhea, then it returned, and by the 24th of April was worse than ever. He followed the diet closely, but without good result. There has been no soreness of the mouth. The stool examined at that time showed much mucus, a large excess of meat fiber, no fat. He was given a prescription for paregoric, 1 dram, to be repeated after each loose movement. On the 28th of April, 1914, the patient reported, at my request. He then weighed 170 pounds, with clothes, and averaged about four days' work a week. He never has any looseness of the bowels or any movements at night, but he is still bothered with gas, cramps, and loose movements in the daytime. Spinach, prunes, and pie are especially likely to upset him. He has seen no blood in his movements, but thinks they contain considerable pus.

The cause of this diarrhea I do not know.

Case 97

A laborer of forty-five entered the hospital July 24, 1912. The patient has always been well. Takes two or three beers and one whisky a day. Two weeks ago he began to have diarrhea, loss of appetite, poor sleep. He had been working on a stone-crusher in great heat, but as he felt no better when he stayed away from work a couple of

days, he resumed his occupation; a week ago he gave up once more, although he has not felt very sick. He has no headache and no other symptoms. Ten years ago he weighed 175 pounds; one year ago, 150 pounds; now, 139 pounds.

Physical examination shows the patient well nourished, active, and bright mentally. Right pupil smaller than the left. Both react normally. Tongue clean. Heart's apex in the fifth space, inside the nipple line. Loud, blowing systolic murmur heard all over the precordia, not replacing the first sound. Pulmonic second not accentuated. Systolic blood-pressure, 115. Lungs, abdomen, and extremities negative. Temperature as seen in the accompanying

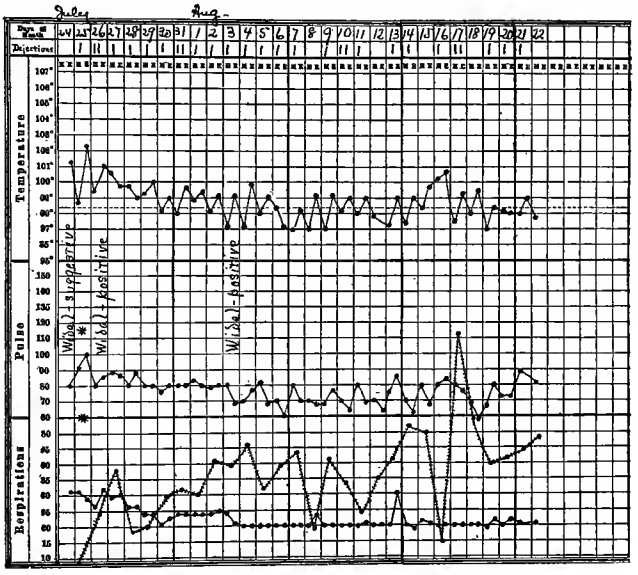

Fig. 95.—Chart of Case 97.

chart (Fig. 95). Urine averages 40 ounces in twenty-four hours, with a specific gravity 1026 to 1032, and occasionally a granular cast. Blood-culture shows pneumococci. The Widal reaction is positive. White cells, 5500, July 24th; 4500, July 26th; 4600, August 2d; 4000, August 11th; 6000, August 21st. The spleen was never felt and no rose spots were seen.

Discussion.—During the early weeks of observation no diagnosis could be made. A latent acute endocarditis or a deep lying bronchopneumonia were thought the most probable explanations of his symptoms. Against both of these, however, a persistently low leukocyte count had to be considered. Without the positive Widal reac-

tion we should have been utterly in the dark. As it is, the positive blood-culture remains a mystery. It may have been a false report. Typhoid fever seems to me clearly the diagnosis.

Outcome.—August 22d the patient seemed to be well and left the hospital.

Case 98

A hotel worker of thirty-one entered the hospital September 27, 1912. The patient's father died at sixty of dysentery; otherwise the family history is not of interest. The patient had left-sided pleurisy when seventeen, but had otherwise been well until he was twenty-four, when he had a diarrhea lasting six months. He was in Australia at this time. After that he was well until six months ago, when the bowels began to be loose and occasionally a little blood was noticed in the movements, yet the condition had not been troublesome until about two months ago, when he began to suffer from tenesmus and noticed mucus in the stools and a little cramp-like pain in the lower abdomen and before movements. Still the frequency of stools was not much increased until within the past month, when all his symptoms had been aggravated and his appetite and strength had failed. Proctoscopy in the surgical Out-patient Department September 17, 1912, was negative.

Physical examination showed a man well nourished and apparently not much pulled down. The viscera were entirely negative. The temperature during the seven weeks in the ward was not elevated. The blood and urine not remarkable. Systolic blood-pressure, 130. The stools were liquid and always showed a positive guaiac reaction, with numerous pus cells and red corpuscles under the microscope, but no macroscopic pus or blood. The gas bacillus was abundant in the stools. No amebæ or eggs were found in the stools. Under the Schmidt diet the frequency of stools was somewhat improved, but the quality not much changed until October 6th, when they became formed and occurred only once a day. On the 14th the patient was put on special diet, consisting of meat, 400 grams; toast, 40 grams; four eggs, and enough macaroni, cheese, and butter to bring the value up to 2000 calories. This produced no special change, and on the 17th the patient was given strict diabetic diet, with 50 grams of carbohydrates, 75 grams of protein, and enough fat to make up 3000 calories. On this diet the stools became more frequent, and on the 20th he was given a fat-free diet for a few days, without improvement. He then was once more put upon the special diet previously

ordered on the 14th, and showed a very marked improvement. On the 7th of November he was given butter and potato in addition to the foods previously allowed, but this did not work well, and on the 10th he was again restricted to the special diet above listed. Improvement once more followed, and he was allowed to go home on the 13th of November in good condition.

Discussion.—This case is typical of a mild degree of ulcerative colitis. It is interesting chiefly because of the dietetic experiments tried.

Outcome.—The patient was seen December 13, 1912, and stated that for the first two weeks, since leaving the hospital, he was as badly off as ever. Since then he has been much better, and though he has not yet gone to work, he expects to do so within another week. For the first two weeks after leaving the hospital he had diarrhea between 2 and 9 A. M. each day, with complete freedom from such trouble for the rest of the day. Now he has but one movement a day, which is preceded by some griping pain. There is no blood in the stools. He states that cold meat always agrees with him, while hot meat makes his bowels loose. He has taken no medicine lately, eats and sleeps well, and feels as well as ever.

CHAPTER IV

DYSPEPSIA

THE vast majority of the causes for indigestion have nothing to do with the stomach, that is, with any disease of the stomach. There is not an organ in the body which may not produce gastric symptoms. The vomiting of brain tumor and of uremia are familiar examples. Indeed, I think we should recognize the fact that the stomach may be thrown out of its regular routine of work almost as easily as the heart. We are perfectly familiar with the fact that any bodily and mental exertion and any sort of illness may increase the heart-beat. We do not, therefore, suspect any disease of the heart itself. We must learn to be as familiar with the fact that when patients complain of their stomachs they are generally free from gastric disease. This is the more important because the patient's own well-meaning efforts go very far to mislead us. A patient whose heart happens to be rapid, by reason of some disturbance in another part of the body, is not apt to complain of his heart, but if a patient has any stomach trouble he always complains of his stomach, no matter where the trouble originates. Gastric complaints are very urgent; they press themselves very forcibly on our notice and bulk large and gloomy in the foreground. This is the source of the old medical adage that "patients with disease above the waist are cheerful; those with disease below the waist are despondent." Disease below the waist means something that produces gastric symptoms, and gastric symptoms are, as I have just said, very plangent, affecting our spirits strongly.

The truly gastric causes of indigestion may be reduced almost entirely to two—*cancer* and *ulcer*. Nervous dyspepsia is fearfully common, but it does not originate in the stomach. It is so with the other varieties, such as functional hypochlorhydria, dyspepsia dependent upon constipation, and other types to be mentioned later. They do not in any sense deserve to be called gastric disease.

What, then, should be especially present in our minds as possible causes of gastric symptoms, when a patient comes to us for these and for these alone?

(1) In a woman who has not passed the menopause, *pregnancy* should always be remembered as a possibility. I have known a number of cases unsuccessfully treated for stomach trouble without any investigation for the possibility of pregnancy, although the latter was later found to be the entire cause of the gastric complaint. I do not think there is any characteristic peculiarity about the stomach symptoms of pregnancy. The early morning nausea and the vomiting, which are so often present, are also seen in dyspepsia of the uremic type, in lead-poisoning, in alcoholism, and in phthisis.

(2) *Chronic nephritis* is much more often a cause of dyspepsia than most of us recognize. It is, of course, the types of nephritis which do not produce edema or obvious changes in the urine which are most likely to mislead us. In my own experience, it has been chiefly the vascular types of nephritis, associated with arteriosclerosis of the heart and brain, that have caused mistakes, owing to the presence of indigestion as a presenting symptom. Since it has become a matter of routine for all conscientious physicians to measure the systolic blood-pressure in every patient, mistakes of this sort are less and less frequent, for the great majority of nephritic cases associated with indigestion show a notably high blood-pressure. A further distinction between true gastric disease and the indigestion due to uremia is the fact that the latter has no association with the presence or absence of food in the stomach. The patient's nausea or distress may come at any time in the day, after any kind of food or no food at all. It is utterly irregular. Further proof that the indigestion is of uremic origin may be obtained by treating the patient for uremia. Rest in bed, low protein diet, purgation, sometimes venesection or hot-air baths, should produce improvement, unless the patient is in the last stages of the illness.

(3) *Tuberculosis*, pulmonary or other, is very frequently overlooked because gastric symptoms are all that the patient complains of. Unexplained indigestion coming on in a person previously healthy, in a person who has not changed his diet or his work, who is not anemic or nephritic or overwhelmed by mental torture and worry, should be suspected of being due to tuberculosis. True gastric indigestion should have a demonstrable cause, either a local cause in the stomach itself (cancer or ulcer), or an external cause in some obvious indiscretion in diet. Such indiscretions are much less common than the diagnosis of them. We often badger the patient and force him into the reluctant admission that he has eaten something out of the way, when, in point of fact, he has not. We are so determined

Dyspepsia

[1] Including cancer, ulcer, and the anomalies of gastric secretion, size, and position.

Dyspepsia

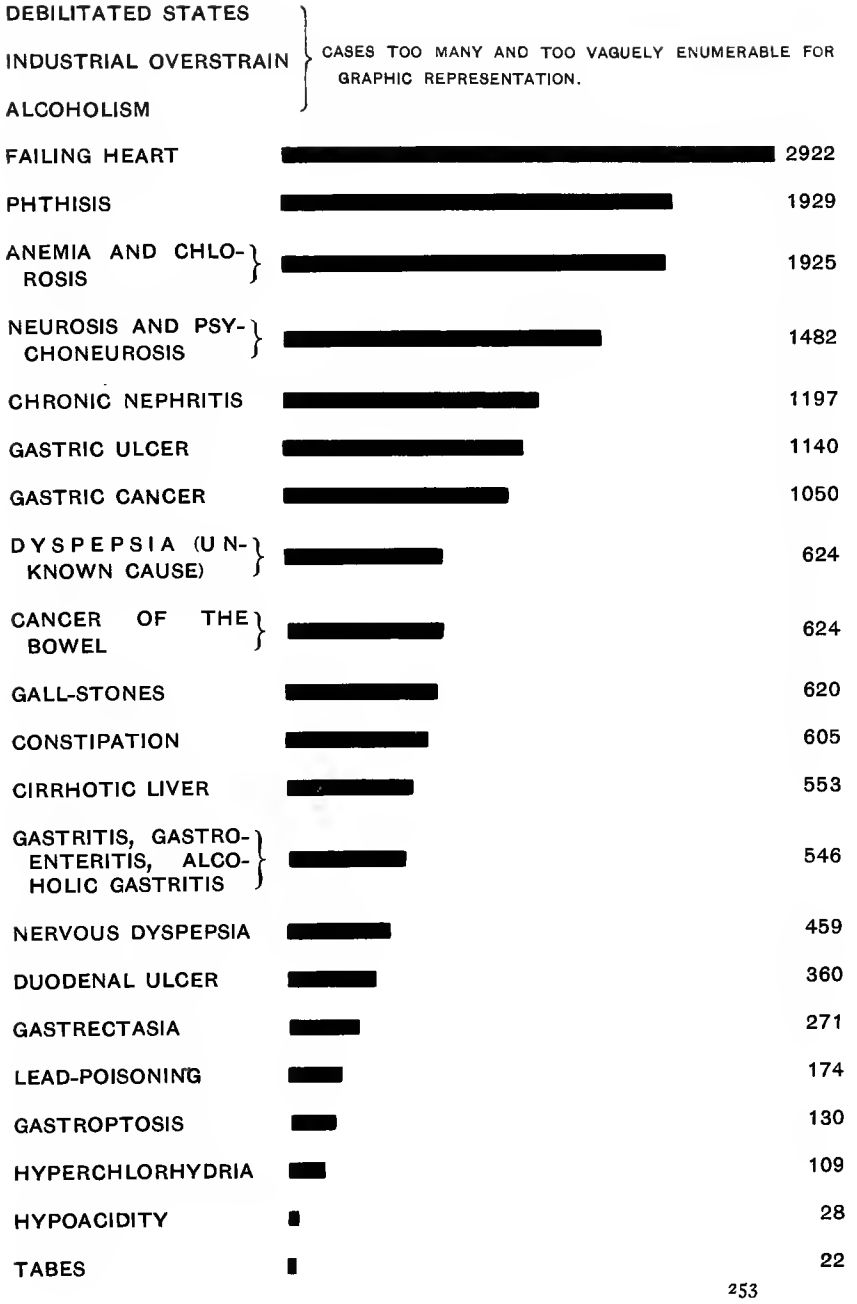
DEBILITATED STATES
INDUSTRIAL OVERSTRAIN
ALCOHOLISM
CASES TOO MANY AND TOO VAGUELY ENUMERABLE FOR GRAPHIC REPRESENTATION.
FAILING HEART 2922
PHTHISIS 1929
ANEMIA AND CHLOROSIS 1925
NEUROSIS AND PSYCHONEUROSIS 1482
CHRONIC NEPHRITIS 1197
GASTRIC ULCER 1140
GASTRIC CANCER 1050
DYSPEPSIA (UNKNOWN CAUSE) 624
CANCER OF THE BOWEL 624
GALL-STONES 620
CONSTIPATION 605
CIRRHOTIC LIVER 553
GASTRITIS, GASTRO-ENTERITIS, ALCOHOLIC GASTRITIS 546
NERVOUS DYSPEPSIA 459
DUODENAL ULCER 360
GASTRECTASIA 271
LEAD-POISONING 174
GASTROPTOSIS 130
HYPERCHLORHYDRIA 109
HYPOACIDITY 28
TABES 22

to find a case of this nature that we find it even when it is not there. A more sensible course would be to have the patient's temperature measured night and morning for a week, inquire carefully into his family history, and to examine his lungs with the utmost care in a perfectly quiet room, and, if possible, by the *x*-ray as well as by the ordinary methods. It is surprising how many cases of unexplained dyspepsia will yield to treatment directed toward tuberculosis and to no other treatment.

(4) In women a great many cases of indigestion are due to *starvation*. This comes about as follows: Something, we need not now inquire what, produces an upset of digestion. The patient attributes it to certain food, probably what she took last, just before the attack occurred. Accordingly, in future she omits this article of diet from her bill of fare. The indigestion recurs, an article of diet is again blamed, and something else is cut out of the diet because she thinks it hurts her. So in this way food after food is given up, until the patient gets down to a regimen of slops or their equivalent. We have now a typical vicious circle. The patient is ill-nourished because she is dyspeptic, and she is dyspeptic because she is ill-nourished. We can break this circle by forcing her to eat despite grievous suffering. An ill-nourished stomach will complain, yet it must be nourished nevertheless. If we can persuade the patient to undergo such suffering, we can honestly hold out the hope that at the end of it she will break her chain, will get back her nutrition, and lose her symptoms. The trouble is that ordinarily the physician does not believe this himself. He has not seen enough cases in which forcing the patient to eat achieves this happy result; but anyone with extensive hospital experience knows that what is called "dieting"—that is, cutting out of one's diet most of the foods that ordinary people live on—is usually a most pernicious process, and leads to a great deal of long and unnecessary suffering. Most cases of this type can be cured by nothing in the world but forced feeding.

The greatest improvement that I have seen in the management of stomach cases in the last twenty years has been the recognition of causes outside the stomach and the successful attack upon these causes. Next to this, the greatest improvement has been through giving up our habits of making strict, narrow diet lists which result in more or less chronic starvation. Whatever we do for a gastric patient, we must not starve him. We must get in food enough to maintain the caloric needs of the body, and the greatest error in the treatment of the past has been the failure to recognize this necessity.

(5) *Gall-stones* are a very frequent cause of attacks attributed to the stomach. When cancer and ulcer can be excluded, it is almost invariably wrong to attribute to the stomach any malady that causes severe pain. Otherwise stated, the only gastric diseases that cause severe pain are cancer or ulcer. All other forms of indigestion run their course with varying degrees and combinations of flatulence—heart-burn, distress, pressure, nausea, vomiting, but not with severe pain.

Now, gall-stones often produce pain squarely in the pit of the stomach and not in the region of the gall-bladder. Failure to realize this accounts for many mistakes. If the patient has many attacks, *some* of them are likely, sooner or later, to be localized in or to radiate to the right hypochondrium, but in the early stages of the disease we may not have any such symptom. True stomach trouble rarely begins in the night. Gall-stone pains are very apt to begin in the night. Gall-stone pains are generally relieved promptly and permanently by morphin. Gastric disease can seldom, if ever, be so relieved. Further details as to this differential diagnosis will be given later in this chapter.

(6) *Angina pectoris* is again and again treated for dyspepsia. The pain may be at the epigastrium, and is very often preceded or accompanied by flatulence and belching. Moreover, it not infrequently comes after meals. These three facts, taken together, lead to many erroneous diagnoses of stomach trouble, when a measurement of blood-pressure or a careful history would have revealed the obvious presence of angina pectoris. A characteristic of angina pain is that it is almost invariably excited by exertion or emotion, and promptly quelled by rest and peace. Gastric indigestion does not behave this way. In the majority of cases careful questioning brings out the additional fact that epigastric pain of anginoid origin is associated, sooner or later, with pain in the left arm.

Why angina attacks are associated with belching I have no idea. It may be that this, like most belching, is really due to air sucking, produced by the attempt to gain relief from previous gastric discomfort, and followed by the discharge of the air thus sucked into the stomach. Why do angina attacks sometimes come after meals? Because the muscular work of digestion, like any other muscular work, increases the work of the heart.

(7) *Tabes Dorsalis.*—Among 136 gastric cases reported by Dr. Frederick T. Lord before the Bristol County Medical Society at Fall River, May 14, 1914, 12 were tabetics, and 3 of these were operated

upon for supposedly local disease of the abdomen. Such a mistake is inexcusable when previous evidence of tabes, such as an Argyll-Robertson pupil or absent knee-jerks, can be obtained. But we have had at least 2 cases in which the syphilitic nature of the underlying disease was discoverable only by lumbar puncture, the pupils and knee-jerks being normal. What we are learning in the last few years, since lumbar punctures and Wassermann reactions in the blood and spinal fluid have become matters of routine in doubtful gastric cases, is that *any type of stomach trouble*, acute or chronic, mild or severe, sharply painful or merely distressing, *may be due to cerebro-spinal syphilis*. Until within the past few years one was on the look-out, if he were conscientious, for so-called gastric crises in tabes, *i. e.*, for sudden paroxysmal attacks of abdominal pain and vomiting, associated with the obvious nervous lesions of posterior spinal sclerosis. What we have learned lately is—

(*a*) That we must suspect the possibility of tabes, even when the pupils and knee-jerks are normal, and must investigate this possibility by means of spinal puncture.

(*b*) That any sort of gastric abdominal pain or distress may be due to tabes.

Actual syphilitic disease of the stomach, resulting in an hour-glass configuration of the organ or in scars of other kinds, must be remembered as a possibility and investigated, so far as possible.

(8) *Lead-poisoning* is not a common cause of indigestion among well-to-do people, but among factory workers, especially rubber workers, painters, and printers, it is much more common than is ordinarily recognized. Any causeless dyspepsia in a person exposed to lead and even any causeless loss of appetite should be suspected of being due to lead-poisoning. When this dyspepsia is associated with colic, and especially when a lead line or characteristic blood changes are present, there is no excuse for failing to make the diagnosis, but in the earliest cases we cannot get beyond a presumption, and we should act upon this presumption by urging the patient to put himself, at any rate for a time, under conditions in which lead absorption is impossible. If, then, he rapidly improves, he should be urged either to change his job or to take more effective precautions against the ingestion of lead.

(9) *Cancer of the large intestine* sometimes deceives even the elect when presenting itself with irregular periods of nausea, distress and vomiting, and without any special intestinal complaints. I have known such cases in which there was no flatulence, no severe

pain, and no more constipation than might be associated with any type of indigestion or even with seasickness. Should any question arise, a bismuth enema and *x*-ray study should be carried out and, if a doubt still remains, exploratory incision should be advised.

(10) *Organic cerebral disease*, arteriosclerosis, syphilis, or tumor are not often mistaken for indigestion; headache and vertigo usually call attention to the brain. It should be remembered, however, that all of these cerebral lesions may be associated for weeks and months with headaches of a type ordinarily called "bilious" and attributed to indigestion. Such attacks are often unilateral and get called "migraine." This mistake can only be avoided by early and frequent examination of the fundus oculi and by a careful history, such as will bring out transient paresthesias of one or another extremity, transient fits or paresis, aphasia, or clouding of consciousness.

(11) *Industrial, mental*, and *moral causes of indigestion* are very common and, by physicians not trained to investigate every part of the patient's life, often unrecognized. Fatigue, worry, fear, or remorse may, quite unknown to the patient, be at the bottom of his sufferings. In the hospital a social service worker is indispensable in the diagnosis and treatment of such cases.

WHAT IS SIMPLE INDIGESTION?

When the stomach is upset, yet is free from organic disease, and, so far as we can ascertain, from any outside influences, such as those which have been detailed in the preceding paragraphs, what has occurred? We are very apt to say that the patient has eaten something indigestible, and doubtless this is sometimes true, although I think it is rarely a sufficient explanation. Or, again, we say that gastric fermentation has occurred; but this is always secondary to some cause producing arrest of digestion and stasis of gastric contents. This is where our attention should be focused. In healthy persons, now and then, something causes an arrest of digestion. The gastric contents are not passed on into the duodenum. They remain in the stomach and undergo abnormal fermentation, causing flatulence and other forms of distress. But why do they remain in the stomach? What inhibits digestion? Two causes are known, others suspected.

(*a*) We know that severe bodily exertion immediately after a meal may slow or altogether stop digestion, presumably by calling away so much blood from the stomach that its motility is interfered with.

(*b*) Psychic disturbances, such as fear, grief, rage, worry, may frequently upset digestion by slowing or inhibiting the gastric movements, possibly also by affecting secretion. One cannot help being somewhat skeptical as to the importance of secretion, its lack or excess, when we see how well patients with tabes or pernicious anemia may digest their food for long periods of time without any HCl discoverable in the gastric contents. I am not yet convinced that deficient gastric secretion is, in itself, enough to produce dyspepsia. Many tired, anemic, or tuberculous patients have deficient gastric secretion and also indigestion, but in these cases motility is usually disturbed as well. When motility is good and secretion absent, as in diabetes, digestion seems to go on perfectly well.

Beyond the two known causes for gastric inhibition—bodily exertion and excessive emotion—there are doubtless many others, concerned, perhaps, with the action of the glands of internal secretion about whose bearing and suggestion we know, at present, very little. What, it seems to me, important that we should recognize is that the majority of all gastric upsets are not easily explained, and that the old idea of improprieties in diet has been seriously overworked. If we will recognize how little we know in this field, we may progress more rapidly.

Case 99

A shoemaker of sixty-seven entered the hospital May 16, 1908. The patient's mother died of cancer of the throat at sixty-eight; otherwise his family history is good. He was sick for a month, when twenty years old, with a fever of unknown nature. He says he has had dyspepsia all his life, distress after eating being the chief symptom. There has been no vomiting. Four months ago he weighed 175 pounds, with clothes; now, 142½ pounds, without clothes.

Four months ago his dyspeptic symptoms became worse, and he began to have sharp, constant pain in the epigastrium, not radiating and not affected by food. At times this pain is severe enough to double him up. For three weeks he has had nausea and vomiting immediately after meals, with some relief of pain. The vomitus shows no blood or coffee-grounds and no food taken the previous day. For the past month he has eaten almost nothing, and, according to his statement, his bowels have moved but twice during this time. He has emptied his stomach either by vomiting or by the help of the stomach-tube each day.

Physical examination showed rather poor nutrition, skin and

mucous membranes pale, but was otherwise negative. Weight, 142¼ pounds, without clothes. Temperature, blood, and urine negative. With the stomach-tube no contents were obtained from the fasting stomach. The capacity of the organ was 84 ounces. When inflated it occupied the position shown in Fig. 96. After a test-meal free HCl was present, 0.18 per cent.; total acidity, 0.26 per cent. Guaiac negative. Microscopic examination negative. The patient improved markedly on a liquid and soft solid diet with nux vomica and a laxative.

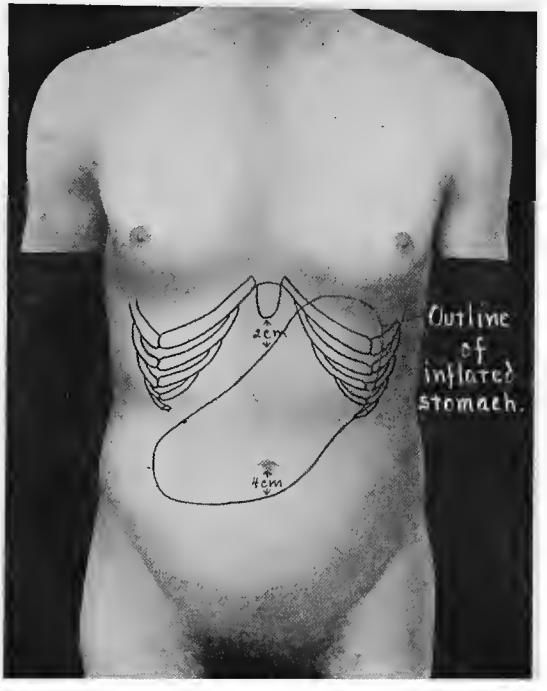

Fig. 96.—Gastric outlines in Case 99.

Gastric neurosis was the preliminary diagnosis. On the 24th he had moderately positive guaiac test in the stools. Tube examination of the stomach was repeated on the 26th, with practically identical results. The patient was examined in a warm bath and seen by several consultants. Nothing further developed. He ate and slept well and felt subjectively much better. Lavage was repeated every third morning. A surgical consultant saw no indication for operation, and the patient left the hospital on the 6th of June very much improved.

He re-entered on the 6th of July, 1908, having done no work since he left before, and having lived upon a diet of milk, crackers, grape-

nuts, and eggs. Once he took clam chowder and vomited, but this was the only time. He has no pain except when he takes a deep breath or on certain motions, and he has no distress except after a hearty meal. His belching has not returned. His bowels move every other day. He has dull, constant headache.

Physical examination shows poor nutrition, but is otherwise negative. Blood and urine negative. Stomach-tube examination showed a little food residue in the fasting stomach. Guaiac test on that residue negative. After a test-meal free HCl was present, 0.18 per cent.; total acidity, 0.26 per cent. Guaiac test in the stools was positive on the 9th, 12th, and 13th. His weight was 140 pounds, 2 pounds less than at the previous entrance.

Discussion.—The age, the family history, and loss of weight point toward cancer, but we note also that this patient has been dyspeptic all his life, and that his pain does not seem to be affected by food and is more severe than we usually see in gastric cancer. It is rare to hear a person say that the pain doubles him up when gastric cancer turns out to be the cause.

Physical examination shows a large but apparently competent stomach. There is practically no stasis, always the most important thing to know about a stomach. This does not exclude cancer, but militates more or less against such a diagnosis, because at least three-fourths of all gastric cancers obstruct the pylorus and produce stasis. The presence of blood in the stools with no stasis, and an abundant secretion of HCl, is quite compatible with a diagnosis of peptic ulcer, although the patient's age makes us doubt the probability of this lesion.

We have no evidence of any disease outside the stomach, such as nephritis, gall-stones, or tuberculosis. On the whole, gastric cancer seems the most probable diagnosis.

Outcome.—Operation on the 17th of July showed a stomach not enlarged, thickening of the pyloric ring, and a small, whitish patch on the anterior surface of the pylorus. The pyloric opening was considerably obstructed. On the duodenum was a small, whitish patch, 3 cm. in diameter, similar to that at the pylorus, but there was no thickening of the duodenal wall. In the head of the pancreas there appeared to be a small tumor, about the size of the end of the thumb. At this point the patient stopped breathing, and only after ten minutes of artificial respiration could he breathe spontaneously. A posterior gastro-enterostomy was then done. He recovered well from operation, but had rather a poor appetite, and vomited from time to

time large amounts of greenish fluid. He left the hospital August 9, 1908. August 19, 1909, he wrote that he had been distinctly better, but not well. For the past several months he had not vomited and had gained some weight. He could eat almost anything in moderation. His bowels were normal. March 24, 1910, he wrote that he was better than before operation, had no pain, and weighed 145 pounds. He felt finely at bedtime, but had some hunger pain after 1 A.M. He had done no work, but walked two to four miles daily and had done so for the past year.

In view of the fact that this patient was so well two years after the operation, we may feel confident that no cancerous growth was overlooked at the time of operation. We cannot say that any positive evidence of ulcer was discovered, but the obstruction of the pyloric opening and the whitish patch upon the duodenum makes it probable that we are dealing with a peptic ulcer and cicatrix. The patient's improvement, after gastro-enterostomy, gives support to this belief.

A point of some interest in the findings at operation is the statement that the stomach was not enlarged, although when distended with water, through a stomach-tube, it held nearly three quarts. This tends to show that these measurements by water distention are by no means conclusive. The most useful test of gastric dilatation is the presence or absence of food in the fasting stomach ten hours or more after the last meal.

Case 100

A motorman of forty-four entered the hospital September 12, 1900. Two weeks before entrance the patient began to feel tired and to lose his appetite. A week ago he gave up work and went to bed. His only local symptoms are pain in the epigastrium on taking food and general soreness in the abdomen. For the past week he has vomited almost every day and has had diarrhea. The pain in the epigastrium has been very severe, requiring poultices and plasters. For a week he has had fever. No cough at any time.

Physical examination showed good nutrition, a dull and heavy expression. Normal pupils, glands, and reflexes. No stiffness of the neck. Chest negative. Scattered rose spots on the abdomen. Some tenderness and muscular rigidity in the epigastrium. Some tenderness on the tibiæ and lower calves. On the 14th the spleen was also palpable. The white count was 6000. Widal reaction strongly positive. Hemoglobin, 83 per cent. The specific gravity of the urine was 1023; slightest possible trace of albumin, no sugar;

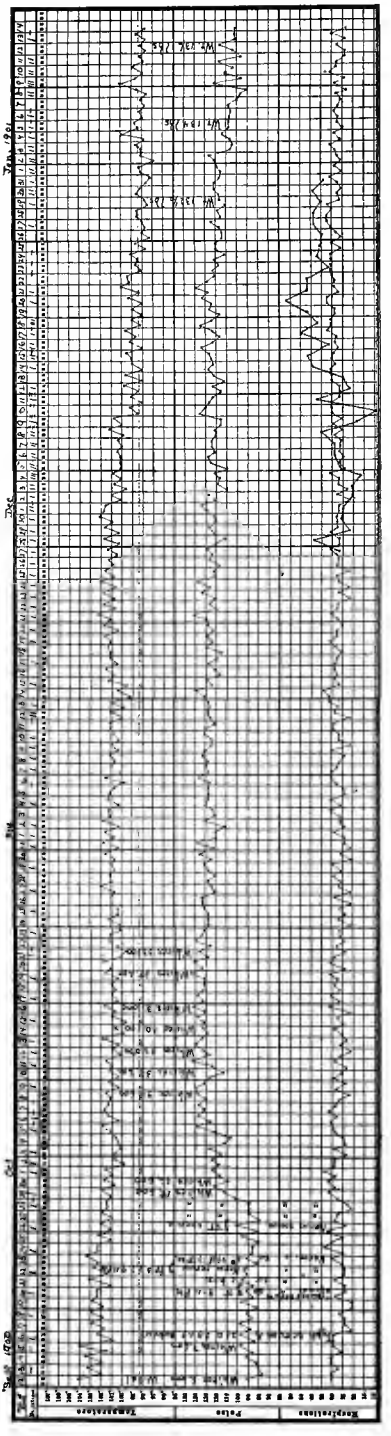

Fig. 97.—Chart of Case 100.

in the sediment a few hyaline and granular casts, with an occasional cell adherent, now and then a fresh blood-corpuscle. The patient ran a continuous fever, never below 100° F., and usually between 101° and 102° F., from September 12th to December 10th, practically three months (Fig. 97).

The pulse remained between 80 and 90 from the 12th to the 28th of October, then a left-sided orchitis developed, and the leukocytes rose to 18,600, and to 26,000 the next day, when a friction rub appeared in the left axilla. By the 2d of October the tenderness and swelling were gone from the testicle and the friction rub had disappeared. Nevertheless the pulse continued elevated, and from October 4th to December 30th, nearly three months, was rarely below 120, often above 130. Routine examinations during October revealed no local complication, but on the 8th of October the white cells numbered 35,600, and on the 10th, 36,000. He had drenching night-sweats in the early part of October. After the middle of the month harsh breathing and bronchophony were detected over a dull area, about the size of the palm, in the right back opposite mid-scapula.

On the 25th of October the white cells were 26,800, and there were fairly clear evidences of solidification at the right apex on the level of the spine and the scapula, over an area the size of a silver dollar. These signs were vaguely corroborated from time to time up to the 8th of November, when the note says that they seemed sometimes more marked than at other times. The white cells were then 41,000. On the 14th of November there was sharp pain in the splenic region followed by a drenching sweat, with general abdominal rigidity. The blood at this time showed red cells, 3,880,000; white cells, 40,800; hemoglobin, 43 per cent. Among the white cells there were 88 per cent. of polynuclears, 11.8 per cent. lymphocytes, 0.2 per cent. eosinophils. The red cells showed considerable irregularity in size, slight irregularity in shape. There were 160 normoblasts per cubic millimeter. November 20th the note reads, "Dr. R. H. Fitz finds signs in the lungs the same." White cells 28,400. December 4th signs were gone from the right lung; white cells, 22,800. He eats very little.

At this time, although the patient's temperature was still over 100° F., he was gotten out of bed, and within a week the temperature fell almost to normal, although on the 18th the white cells were still 23,100. On the 29th he was up and walking about, gaining daily; white cells, 12,400. January 14th he was able to walk about fairly well, had gained 6 pounds in two weeks, had a negative physical examination, and was allowed to go home, although his hemoglobin was still only 48 per cent.

Nine years later he entered the hospital again, stating that for the first year after leaving the hospital before he felt very well, then he once more began to have distress in the epigastrium, especially on the left side. It was not increased by hearty meals and did not produce vomiting. Sometimes hot drinks relieved it. This condition remained unchanged and did not prevent his working.

A year ago the pain began to grow worse and extended also to the left flank, under the ribs. It was now described as a dull, sickening feeling.

For a month he has noticed some headache. For three days the pain in the epigastrium has been increased, and the pain in the flank has disappeared from time to time. During these days he has vomited each morning once, and has noticed a slight dyspnea on exertion and some palpitation. His appetite, until the last week, has been excellent. Up to a year ago he weighed 200 pounds (136

pounds on leaving the hospital after his typhoid), but within the past year he has lost somewhat in weight, and now weighs 167 pounds, without clothes. He kept at work until three days before entrance.

Physical examination showed fair nutrition, the right pupil larger than the left and slightly irregular; both, however, reacting normally. Glands and reflexes normal. The heart's impulse seen, felt, and percussed in the fifth interspace; nipple line 11 cm. from midsternum. Right border of dulness 6 cm. from midsternum. At the apex the second sound was louder than the first, which was accompanied by a harsh, systolic murmur, loudest in the apex region. The aortic second sound was markedly accentuated. The arteries thickened and tortuous. Blood-pressure, 260 mm. Hg. The lungs were negative, save for slight dulness and crackling râles at both bases. The abdomen showed shifting dulness in the flanks. There was a slight tenderness and resistance in the epigastrium and very slight edema of the shins. The urine averaged 25 ounces in twenty-four hours; specific gravity from 1001 to 1005; albumin a trace; sediment, few hyaline and granular casts. Blood negative. During the first week of his stay in the hospital the temperature ranged between 99° and 100° F. The patient did not improve at all. Vomiting and headache, with poor sleep, continued despite purgation, hot-air baths, and cardiac stimulation. On the 6th leeches were applied over the liver. Very free bleeding followed. Next day the vomiting and general condition seemed improved, but his arms had meantime become very much swollen and tender. After the 10th of March edema of the feet and legs increased. He took little food, passed less urine, complained of dyspnea and precordial distress, not relieved by nitroglycerin or amyl nitrite. On the 10th he had an attack of very severe precordial pain with dyspnea which was not relieved. At six in the evening he died.

Discussion.—There is no reason to doubt that the illness from which this patient suffered in September, 1900, was typhoid, with thrombi in the lung and spleen. Doubtless the pyrexia toward the end of November and the early part of December was of the type known as "bed fever," since it so promptly subsided when the patient got up. Just what bed fever is we do not know, but may surmise that it is due to some disturbance of metabolism or of heat regulation, connected with the abnormal existence of the patient deprived of the normal stimuli of exercise and the normal variations in temperature.

Nine years later this patient suffered from a dyspepsia associated

with a good appetite. Had not the urine and blood-pressure been tested, we might have had no suspicion of the true origin of this dyspepsia until the edema of the peritoneum and lungs appeared. The latter is probably of comparatively recent origin, since the patient has only had dyspnea for a few days. Uremia, then, is doubtless the cause of this patient's symptoms.

We are accustomed to say that when a patient past forty begins to have dyspepsia out of a clear sky—that is, without any obvious cause or any previous habit—cancer is the most probable diagnosis, but when saying this we must remember that the cancer age is also the arteriosclerotic age, and, therefore, the time for nephritis and uremia. Furthermore, the cancer age is also the gall-stone age and the age for angina pectoris. All of these possibilities should, therefore, be investigated before we settle down on even a preliminary diagnosis of cancer.

Outcome.—Autopsy showed chronic glomerulonephritis; slight arteriosclerosis; hypertrophy and dilatation of the heart; serofibrinous pericarditis; cholelithiasis; slight chronic pleuritis on the right.

Case 101

A ship carpenter of forty entered the hospital March 15, 1909. The patient was sent in from the Out-patient Department (No. 123,290) with a diagnosis of "splenic anemia." His family history is excellent. He states that ten years ago he had what he calls "rheumatism," which began in the instep of each foot, was associated with fever for the first week, and kept him in bed for six weeks. He says he was paralyzed from the waist down, could not move his legs at all, and had much pain in the backs of them. Recovery, however, was complete. He takes three or four beers a day, some whisky Saturday nights, and a pint over Sunday.

Two years ago he began to feel run down, had considerable cough when working in a dusty mill, but this cough ceased when he got an out-of-door job. At this time he weighed 155 pounds. Last December he had a day or two of indigestion, relieved by taking salts. At the end of January he stopped work after a hard job aboard ship. He had then a crowding feeling in the epigastrium after meals, and an "all gone" feeling later. He took an abundance of salts and lost in strength and weight. This he has continued to do in spite of medicine and diet. His appetite has increased, and he takes two quarts of milk a day. He had no pain, no edema, an excellent appetite, better than usual, fairly good sleep. Nevertheless, he had to

stop work January 20th on account of weakness, and now weighs only 125 pounds.

Physical examination showed fair nutrition, skin and mucous membranes pale. Red cells, 3,912,000; whites, 14,200; hemoglobin, 55 per cent.; polynuclear leukocytes, 78 per cent.; lymphocytes, 21 per cent.; eosinophils, 1 per cent. Urine negative. Pupils equal and react normally, slightly irregular in outline. Reflexes normal. Glands enlarged in the neck, axillæ, groins, and epitrochlear regions. Artery walls thickened and slightly tortuous. Visible pulsation in the brachialis. Chest negative. The liver extended from the sixth rib

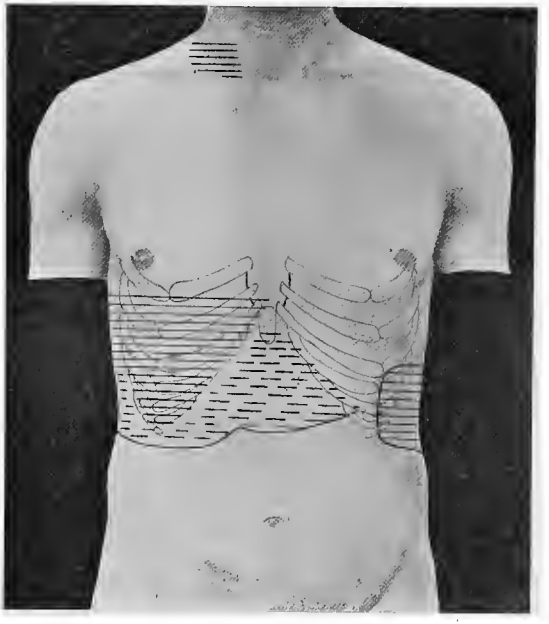

Fig. 98.—Condition of the spleen and liver in Case 101.

to a point 11 cm. below the ensiform, where an edge was felt. Splenic dulness was 11 by 15 cm. The edge of the organ was felt (Fig. 98).

I made the diagnosis of questionable syphilis of the liver, as the surface of that organ was irregular, its edge rounded. Examination in a hot bath showed no palpable spleen, but otherwise confirmed results of previous study. Stomach-tube showed no contents in the fasting stomach. After a test-meal there was no free HCl or other acidity. Guaiac was positive. On the 23d there was some food residue in the fasting stomach. After a test-meal the contents were

still alkaline. The patient's gastric distress was considerably relieved by resorcin, 5 gr. three times a day, which was given after a fruitless trial had been made of antisyphilitic treatment. After losing 7 pounds in the first week he got most of it back again. His temperature was somewhat elevated throughout (Fig. 99). His stools were always negative to guaiac.

Discussion.—Apparently this patient had an alcoholic neuritis, or possibly a rheumatic attack, ten years ago, and a decided cough, possibly tuberculous, two years ago, but there seems no good reason to connect either of these illnesses with his present six weeks' attack of rather mild dyspepsia, in which he has lost weight and strength despite an excellent appetite. (This last combination, it should be noted —loss of weight and an excellent appetite—is a rather rare one, occurring chiefly in diabetes and Graves' disease.)

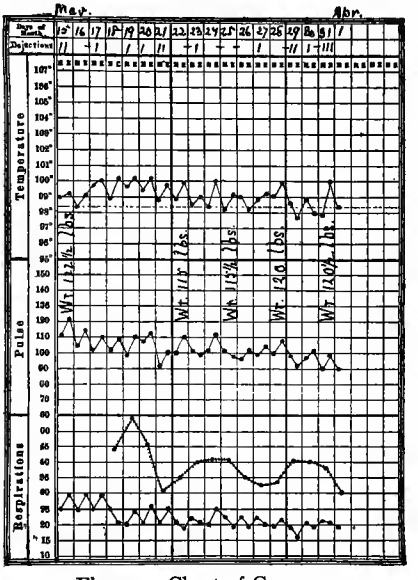

Fig. 99.—Chart of Case 101.

The presence of an unexplained anemia in a man of this age, with a generalized adenitis and enlargement of the liver and spleen, may mean syphilis. Sailors are notoriously apt to have syphilis. Whether ship carpenters are as bad, I do not know. The condition of the liver edge gives support to this surmise, yet it must be confessed that we have no positive evidence of syphilis in this case.

His habits are neither of the best nor of the worst as regards alcohol. It is certainly possible that he may have acquired cirrhosis of the liver, and cirrhosis might account for all his symptoms except his adenitis and his rather premature arteriosclerosis. The absence of free HCl in the gastric contents and the presence of positive guaiac reaction are not infrequently associated with cirrhotic liver.

Why may not the patient have peptic ulcer? His anemia might be accounted for by some unrecognizable hemorrhage which passed out by the bowel. His good appetite is entirely consistent with such a diagnosis, and is more easily explained than by either of the diagnoses previously considered.

Ulcer, however, has a much longer history of paroxysmal dyspepsia than is present in this case, and it is not often associated with absence of HCl in the gastric contents.

We have some hints of phthisis in the case, especially the causeless indigestion and the slight fever. No one of the diagnoses yet considered, unless possibly syphilis, will account for this fever, and it still remains a mystery in this case. No explanation of it has ever been offered. Arteriosclerosis might be imagined as a cause of the patient's troubles, even though his urine is negative, as we have no blood-pressure measurements recorded. An arteriosclerotic kidney or arteriosclerosis of the abdominal blood-vessels cannot be excluded as a possible cause of his symptoms, but if we adopt this theory we cannot explain his anemia. I have never seen any good reason to believe that arteriosclerosis can, by itself, account for anemia.

Cancer of the stomach would explain the anemia and the achylia, but not the fever, enlarged spleen, and good appetite. I was unable to make a diagnosis in this case, and recommended exploratory incision in view of our uncertainties.

Outcome.—On the 5th of April operation revealed a mass in the greater curvature of the stomach and a larger mass underneath the stomach. Both masses were presumably cancerous. No operation was attempted. The patient was sewed up. He left the hospital April 25, 1909, and a letter sent to his address a year later was returned marked "Dead."

Case 102

A married Russian Jewess of forty-four entered the hospital February 22, 1909. Her family and past history were not remarkable. For three months she has vomited in the morning whenever she takes anything to eat or to drink. At times when vomiting her fingers stiffen out, but her thumbs do not turn inward. During this same period she has had some shortness of breath on climbing stairs, and for two months has used two pillows at night and passed urine once in the night.

Physical examination showed poor nutrition, good color, negative pupils and reflexes. The heart showed no enlargement, but there was a rough systolic murmur, best heard at the apex and transmitted to the axilla. The pulse showed increased tension, but no blood-pressure measurement was recorded. There was visible pulsation in the brachial arteries and some thickening of the radials. The

aortic second sound was loud and ringing. Both hands showed in the ward a tendency to a spastic contraction of the fingers, with occasional turning in of the thumbs. The little finger and fourth finger would turn under together, so as to make the knuckle of the middle finger very prominent. Vaginal examination was negative.

The urine averaged 35 ounces in twenty-four hours; specific gravity, 1005; slight trace of albumin. No casts. Blood normal. The fundus oculi showed narrowing of the arteries at various points, no hemorrhages or areas of retinal degeneration. Stomach-tube revealed no contents in the fasting stomach and no enlargement of the organ. After a test-meal there was no acid in the gastric contents. Despite various measures designed to relieve it the vomiting continued until the 2d of March, when she was given cornmeal mush and did very well, but with more varied diet vomiting recurred.

Discussion.—Morning vomiting in a woman always suggests pregnancy, but there is no possibility of that in this case. Next to that, nephritis is the commonest cause that I know for morning vomiting. The condition of the heart and urine strongly suggests that there is a nephritis in this case. It is, moreover, notable that dyspnea began at the same time as the vertigo.

This patient is at the cancer age, and any such symptoms beginning in a patient of that age who has never had stomach trouble before should suggest cancer, but we have here rather more vomiting and rather less evidence of objective gastric disease than one expects with early gastric cancer. The absence of HCl in the gastric contents is not in any way characteristic of cancer, and does not constitute evidence against the diagnosis of chronic nephritis, which seems to me the most reasonable one.

The contractions of the fingers are to be regarded as tetany, a disease about which we know very little, except that it seems to have some association with gastric dilatation and with extirpation of the parathyroid glands. There seems no good reason to believe that either of these conditions is present in this case. Nevertheless, I suppose the tetany would be classed under the general type of gastric tetany.

It is worth while noticing that the vomiting was checked in this case by the administration of cornmeal mush. I have seen a similarly successful result in a good many cases. In the treatment of vomiting, when starvation does not suffice and when the patient must be fed, it is generally a mistake to give bland liquids, such as milk

and broth. The patient needs something with a fairly strong taste to it, and solids are usually better than liquids.

Outcome.—The pulse grew steadily weaker, and on the 10th the family decided to take her home, where she died March 11, 1909.

Case 103

A housewife of thirty-six entered the hospital April 17, 1909. The patient's father died of "rheumatism of the heart," her husband, of consumption; one child also of consumption. She had typhoid at fifteen, and a year later had jaundice which lasted almost a year.

For many years she has had stomach trouble, especially in the last three years, in which time she has been vomiting about twice a week and had pain after taking food; also burning sensation in the epigastrium, with marked constipation. August 31, 1908, she entered the Boston City Hospital with a diagnosis of gastromesenteric ileus. The stomach was found markedly dilated. Posterior gastro-enterostomy was done. Four days after operation nausea and vomiting began. September 23d she was discharged against advice. She now states that since the operation she has been much worse than before. She vomits everything that she eats and has constant epigastric pain, which confines her to bed about half the time and causes her to lose weight rapidly. She has never vomited any blood.

Physical examination showed fair nutrition. The pupils, glands, and reflexes normal. Chest negative. Abdomen negative, save for moderate epigastric tenderness. Urine negative. The blood showed 20,000 white cells with polynuclear leukocytosis; hemoglobin, 85 per cent. Four days later the leukocytes were 17,600. Later it was discovered that for the last three months she had had morphin to relieve the pain, usually $\frac{1}{2}$ to $\frac{3}{4}$ gr. Her stomach was washed out and its contents found to be mostly bile. She continued to vomit and needed a great deal of morphin, bromid, and chloral. On the 23d she was seen by Dr. C. A. Porter, who advised exploratory operation. On learning this news the patient stopped howling and vomiting, became cheerful and intelligent, said there was nothing the matter with her stomach, and that the only trouble was she had been given too much morphin. She said she would not be operated upon and wanted to go home. Said she wanted some food, was given an egg on toast, turned over, and slept comfortably all night. The next morning she again began howling and vomiting. In the afternoon the patient, who was in a private room, was found with a towel wound into the shape of a rope. Fearing that she might do herself

harm, the house officer ordered restraint. The patient escaped from the restraint, but was so enraged with the treatment that she ceased howling and vomiting and became rational. After that she took considerable nourishment and vomited less.

Discussion.—A patient who has been exposed to tuberculous infection, has suffered from a long-standing dyspepsia, was shown at the Boston City Hospital to have a dilated stomach and has acquired a morphin habit, now comes under observation with a leukocytosis of unknown origin. What the cause of that leukocytosis may have been we are unable to discover.

As we read over the history, we are inclined to say at once, "Oh, yes! hysteria!" but the question is, is there not something behind her lack of mental control? Are we certain that, even at her age, she has not some arteriosclerosis or cerebral syphilis? All we can say on this point is that there is no evidence of either trouble. I am inclined to think that it is correct to attribute her troubles wholly to her mentality, though we cannot account satisfactorily for the leukocytosis.

It is a point of interest in this case that although she had demonstrably a dilatation of the stomach, for which gastro-enterostomy was done without any relief, she later got along with her stomach perfectly comfortably when mental conditions were changed. I have become very skeptical of the diagnosis of dilated stomach as a pathologic entity. I doubt if we know enough to make such a diagnosis in the absence of stasis. We do not know how large a stomach may be and still be normal, nor what temporary stretching the organ may be subject to without becoming in any way diseased or inefficient. The diagnosis of dilated stomach used to be a very frequent one. In the better clinics of the country it is now becoming rare and, as it seems to me, should disappear altogether. A dilated stomach with stasis is important, but it is of precisely the same importance as stasis without the dilated stomach. In other words, the stasis is the point, and that is to be proved either by *x*-ray or, better still, as I think, by the passage of the stomach-tube before breakfast. We cannot be sure that a bismuth stasis discovered by *x*-ray represents the actual functional ability of the stomach when working upon food materials. Bismuth is, after all, a foreign substance, very different from anything that we ordinarily ask our stomachs to deal with.

Outcome.—It was learned later that her mother had died in the Danvers Insane Hospital. On the 29th she left, against advice.

Case 104

A widow of sixty-four entered the hospital December 18, 1911. She says she had stomach trouble for twenty years, and mentions "auto-intoxication" and "dilated stomach" as causes. Occasionally has colic or acute distress, otherwise she has been well, and, despite habitual constipation and frequent headaches, has led an active life. Now and then her activities have been interrupted by a paroxysm of what she calls "meat-poisoning," with some vomiting and diarrhea. She passes urine twice at night. Has had no other urinary disturbance and has never been jaundiced.

For about a month she has had frequent attacks of nausea and epigastric pain. Ten days ago, after lunch, she had a severe attack of her usual trouble and since then has been constantly nauseated and in pain. She has been losing weight and getting worse in other respects for a month. She stated that her bowels had not moved for the ten days preceding December 16th. She has taken no cathartics or enemata. She has had considerable cough, but no fever or chill.

Physical examination showed a poorly nourished woman, negative pupils and gums, very poor teeth, many of them missing. Chest showed nothing of interest except a scattering of coarse râles in both backs. Abdomen was slightly distended, and showed slight spasm and considerable tenderness in the right upper quadrant, where an indefinite mass could be felt to move with respiration. There was also a tenderness over the pubes. The reflexes were normal. Urine normal. Blood at entrance showed 19,000 leukocytes. Hemoglobin, 85 per cent.

Soon after entrance she vomited 100 c.c. of grayish fluid, with a positive reaction to guaiac, but no free HCl. This reaction was present also in the stools. Throughout the ten days' stay in the medical wards (808–241) the abdomen remained moderately distended, and despite the good results of enemata and cathartics there was often general abdominal pain, occasionally crampy. She vomited more or less each day, retaining liquids until about 12 ounces had been taken and then rejecting almost the entire amount. The temperature during this period was normal, but the pulse gradually rose from 80 to 110.

Discussion.—Although this patient has been habitually constipated, we cannot attribute her present stomach trouble to that cause, for the present trouble is acute, the other chronic.

We note that this patient has had a good deal more pain than the typical dyspeptic. We note, also, that she is at the cancer age,

though we put less stress upon this, in relation to gastric cancer, when the patient has had *chronic* stomach trouble, as in the present case.

In favor of gastric cancer we have the presence of a mass in the right hypochondrium, with blood in the stomach, absence of HCl, and stasis. The fact that she has had no movement of the bowels for ten days makes it necessary to consider cancer of the bowel also. It is always to be remembered that cancer of the bowel can reproduce almost all the symptoms of cancer of the stomach. The persistence of crampy abdominal pain, after she had been put at rest and had had her bowels emptied, favors intestinal neoplasm. The condition of the lungs shows a weak heart. The leukocytosis is not accounted for. No definite diagnosis was made.

Outcome.—December 18th the abdomen was opened and hard masses found all about the lower border of the liver, the gall-bladder, and the pylorus. The abdomen also showed a number of other hard masses, presumably in the omentum and mesentery, but no evidence of intestinal obstruction was found. After operation she vomited less and was more comfortable, but gradually lost strength, and died December 31st. Autopsy showed cancer of the gall-bladder, with extensive metastases in the neighboring lymphatic glands. There was also a streptococcus septicemia, with a small abscess in the right lung, together with obsolete tuberculosis at the apex of each lung and a moderate amount of arteriosclerosis. There is very little in the case, as we look back over it, to set us right in diagnosis. The absence of jaundice and of any tumor, recognizable as the gall-bladder, makes it difficult to see how a correct diagnosis could have been made. It is striking that with a normal stomach and intestine such marked gastric and intestinal symptoms were nevertheless present. Possibly the metastatic masses may have had some connection with this.

Case 105

A housewife of forty-eight entered the hospital December 19, 1911. Her father and grandmother died of "stomach trouble," otherwise her family history is good. Six years ago she had some abdominal operation done at the Homeopathic Hospital. The nature of the operation is not known, but menstruation has been absent ever since. For twenty years she has been troubled with indigestion, chiefly a form of epigastric distress, without apparent relation to meals. The distress comes at irregular intervals, and is associated with nausea

and flatulence, but not with vomiting. Besides this distress she has several times had attacks of very severe pain in the epigastrium, which double her up and need morphin for their relief. She has never been jaundiced and had no fever, but she has had a series of chills which often accompanied the epigastric pain. The most recent chill accompanied an attack of pain last night. The urine has been dark, the stools sometimes black. The last severe attack was four weeks ago. As a rule, pain lasts about six hours.

The physical examination is negative, except for rigidity of the whole abdomen, preventing further examination. Tenderness is complained of throughout, but it is not severe. It is apparently most marked in the right half of the abdomen, which is tympanitic and level throughout. The blood and urine are normal; likewise the pulse, temperature, and respiration.

Discussion.—What can we infer from a family history such as is present in this case? Nothing definite. The so-called stomach trouble from which her father and grandfather died may have been uremia, angina pectoris, hepatic cirrhosis, pernicious anemia, or many other diseases. We have no good reason to suppose that it was really connected with the stomach.

The patient has had twenty years of indigestion, but the striking thing is that there has been no relation between this indigestion and the taking of food. In other words, there is no good reason to attribute the distress to the stomach itself. The occurrence of severe pain, relieved by morphin and associated with chills, leads us to conjecture that gall-stones are present. Indeed, the chief difficulty before us is to avoid jumping at the conclusion that it must be gall-stones before we have adequately thought out the other possibilities. The history is certainly typical of gall-stones, and the physical examination also, since the physical examination of most gall-stone cases reveals nothing whatever, as in this case. What else could it be? Duodenal ulcer, first of all, for it is notorious that gall-stones and duodenal ulcer may absolutely simulate each other. The presence of gastric trouble, between the sharp attacks of pain, is what one would expect with ulcer. Against ulcer, however, is the absence of any typical hunger pain, any definite relation to meals, or any relief by food. Positive evidence of ulcer, such as blood or *x*-ray findings, is absent, and it is certainly unusual to meet with ulcer pain requiring morphin and promptly relieved by it.

It is now the fashion to attribute symptoms of this kind to chronic appendicitis and to remove the appendix for their relief, but it seems

to me that it is becoming more and more difficult to defend this standpoint. The revelations of Dr. E. A. Codman's paper on "Chronic Appendicitis"[1] are more impressive the more thoroughly we study them. Personally, I do not think there is the slightest evidence that symptoms like this patient's were ever produced by chronic appendicitis.

Renal colic, due to stone or other causes, might produce such a pain, but I have never known it to be confined to the epigastrium. Moreover, we have no confirmatory evidence in the urine.

Outcome.—December 20th the abdomen was opened and the gall-bladder found to be distended. About ten gall-stones, of various sizes, were removed from it, but none were felt in any of the ducts. The patient made a good recovery and was discharged the 9th of January. December 16, 1912, her family physician reported that she is and has been perfectly well.

Looking back over the case, with the operative findings in our minds, have we good reason to believe that the patient's twenty years of indigestion were due to the gall-stones removed at operation or to other similar stones? It is customary to answer this question in the affirmative, but I cannot see that the custom has any good basis in experience. There are plenty of patients who have just such indigestion yet who show postmortem no evidence whatever of gall-stone. The association may well be a coincidence.

Case 106

An Irish housewife of twenty-three entered the hospital August 19, 1909. Two months ago she began to have nausea, vomiting, and headache. Previous to that she has always been well, and has a good family history except that one sister died of tuberculosis, nine years ago, while living in the same house with the patient. Early in the present illness the vomiting was accompanied by nausea, and occurred especially on rising in the morning. Later, it occurred more generally through the day. After three weeks of this trouble she began also to have headache, a dull frontal and occipital pain, with frequent sharp attacks, which have continued ever since. A week ago the sight of the right eye began to be dim, and now she cannot distinguish objects with it. About the same time she noticed slight numbness in the left side of the face and occasional slight vertigo. Within the last week she has fainted twice.

Physical examination shows a well-nourished patient, with a

[1] Boston Med. and Surg. Jour., October 2, 1913.

marked internal squint of the right eye. The left eye does not move past the median line toward the left. Other movements are well made. Pupils normal. Choked disk in both eyes. Chest and abdomen negative. Slight dulness of sensation, especially to pain, on the left side of the face, neck, and upper arm. She cannot count fingers with the right eye. The reflexes of the jaw, biceps, wrist, and knee are exaggerated. The ankle-jerks not obtained. Babinski's reflex is negative on both sides. Gordon and Oppenheim positive on the right side. Blood-pressure, 140 mm. Hg. Temperature, blood, and urine negative.

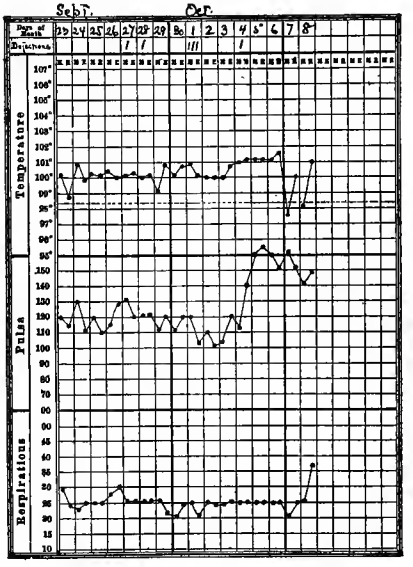

Fig. 100.—Chart of Case 106.

Discussion.—The age of the patient and the exposure to tuberculosis hint at a dyspepsia symptomatic of that disease, but the loss of sight in one eye, the numbness about the face, and the unexplained fainting makes it pretty clear that we must look for some deeper cause for the patient's vertigo.

The physical examination makes it reasonably certain what this case is. The choked disks, the increased reflexes, and paresthesia of the focal type constitute a symptom complex pointing without any considerable doubt to a circumscribed intercranial lesion, of which the vastly most common example is brain tumor.

Syphilis can cause similar symptoms, but we have no definite evidence of that disease, and double choked disk is not common in the early stages of cerebral syphilis. Arteriosclerosis at twenty-three is rather a far-fetched surmise. Tuberculous meningitis does not produce double choked disk and rarely presents such definite focal symptoms. Brain tumor is the only reasonable diagnosis.

Outcome.—Operation August 21st for decompression; the record does not state which side, but apparently in the temporal region. There was no improvement in her condition after this operation, and on the 11th of September the same opening was enlarged, still without any gain. After the 23d of September the patient ran a steady fever, most of the time above 100° F.

On the 9th of October she died. Autopsy showed glioma of both frontal lobes and of the basal ganglia on both sides. The fever was unexplained (Fig. 100).

Case 107

A fisherman of thirty-eight entered the hospital November 15, 1909. Family history and past history negative. For three years he has been bothered with attacks of epigastric soreness and distention, somewhat relieved by belching. In the intervals between these attacks he is perfectly well and never vomits at any time. During one attack, three weeks ago, he thinks he was slightly jaundiced and had dark urine. His appetite is ravenous. He eats at irregular intervals and bolts his food. His bowels are very constipated. The last two attacks have been more severe than usual, and pain has been referred to the back. In the past three years thinks he has lost 5 pounds.

Physical examination shows a marked funnel breast, but is otherwise negative. A stomach-tube is passed and shows no contents in the fasting stomach. The water capacity of the organ is one quart. After a test-meal the stomach contents show free HCl, 0.027 per cent.; total acidity, 0.116 per cent. Blood and urine are normal. There is no fever.

Discussion.—The patient has had three years of typical dyspepsia in paroxysms, with a fine appetite and a marked constipation. Physical examination shows nothing. Is the constipation in itself enough to account for the patient's symptoms? If we take it in connection with his bad dietetic habits, I think we can say yes. It is not quite certain whether the bad habits are the cause of the constipation or *vice versâ*, but taken together they should be enough to upset his digestion. At any rate, treatment should proceed upon this theory until it is clearly disproved.

This is the sort of case in which many a surgeon rushes in where the internist fears to tread, and it is perfectly possible that in the long run, after thorough study, an exploratory incision might be justified in such a case, but certainly not until we have obtained reasonable assurance that the correction of his symptoms is not all sufficient.

Outcome.—He went home November 18, 1909, seemingly quite well. November 1, 1912, his family physician writes that the patient has been able to work steadily since leaving the hospital. He still has some left epigastric pain and is badly constipated, but when he keeps his bowels open he gets along quite comfortably.

Case 108

A janitor, a negro of forty, entered the hospital November 2, 1909. The patient's family history is good. His wife has had two living children, followed by seven miscarriages early in pregnancy. The patient has been in excellent health, and, according to his own account, has excellent habits.

Last June he began to have excessive flow of saliva, eructations with epigastric pain, and vomiting. He had never had any trouble with his digestion before. His pain was never severe. His vomiting was at first about once a week, now after almost every meal. He ejects part of the food eaten, sometimes more than he can account for. The vomitus is always sour, never bloody. He is somewhat eased by soda. Recently he has been getting weak and short of breath and has had night-sweats. Since June he has lost 30 pounds.

Physical examination showed fair nutrition, considerable loss of flesh. Pupils equal, slightly irregular, reacting normally. Aortic second sound much accentuated—loud, ringing, deliberate. Blood-pressure, 260 mm. Hg. No evidences of cardiac enlargement. Lungs and abdomen negative. Blood negative. Urine averaged 40 ounces in twenty-four hours; 1005 to 1009 in specific gravity; trace of albumin; no casts.

The stomach-tube, passed before breakfast, showed some remains of food eaten the day before. Gastric capacity, 34 ounces. After a test-meal HCl was absent. On the 4th of November the patient began to complain of nocturnal headache, dizziness, muscular tremor, and vomiting of an expulsive character without preceding nausea. He continued to vomit once or twice a day, but in other respects seemed somewhat improved after antispecific treatment had been stopped and purgation begun. Examination of the fundus showed exudate and hemorrhages around each optic disk.

Discussion.—The chief features in the history is the occurrence of seven miscarriages in the patient's wife, the six months' salivation, epigastric pain and vomiting, with a loss of 30 pounds in weight, and, more recently, dyspnea and sweating. This is just the sort of case in which anyone who tries to practice medicine without routine measurement of blood-pressure will go clean astray. Without the blood-pressure measurement one might not feel at all sure of cardiac hypertrophy, and without that it would be impossible to be positive that the patient has nephritis. The combination of the urinary findings, the examination of the heart and the blood-pressure would

be practically diagnostic of nephritis, even if we did not have the retinitis to make certainty doubly sure.

It is to be noticed that the vomiting is distinctly of the cerebral type, the type often associated with brain tumor, but more properly associated with increase of intercranial pressure, whether by reason of brain tumor, hypertension, or other causes.

One might easily have been puzzled in this case if one were in the habit of putting undue stress on the significance of gastric stasis and achylia. These findings are often of great importance when there is nothing outside of the stomach to account for them, but only then should we think of them as direct evidence of gastric disease.

Outcome.—The headache after the 8th of November was slight and he slept well. The vomiting seemed to have no relation to eating, and on the 17th his relatives became alarmed and took him home. His blood-pressure by this time had fallen to 200.

Case 109

A married woman of fifty-two entered the hospital January 10, 1910. Family history and past history negative. Always subject to sick headache, and thinks that fifteen years ago she had same trouble as now. States that she always had "delicate" stomach, but no particular trouble with it until the 16th of September, when she began to have epigastric pain and vomiting. These symptoms lasted a few days and then she was comfortable, but there have been three similar attacks since December 15th, and a good deal of flatulence between them. The epigastric pain comes at a variable time after eating. Since the middle of December her appetite has been poor and her bowels have needed laxatives. She has lost much strength and considerable weight. Her diet has been mostly rice, milk, Indian meal, and raw eggs. For the past five days she has not vomited, but has been troubled a good deal with vertical headache. For the past four or five years she has passed urine twice each night after bedtime.

Physical examination of the chest was negative. General nutrition was good. Had a well-marked herpes upon the lips. The heart's apex was in the fifth space, $14\frac{1}{2}$ cm. from midsternum. Pulse of high tension and aortic second sound accentuated. Blood-pressure not measured. On right side of the abdomen a hard, elastic, insensitive, slightly movable tumor was felt, about the size of a grape-fruit. It was easily felt in the flank with bimanual palpation and did not descend with respiration. It was not fluctuant and did not seem to be connected with the liver. The colon was inflated and the tympany

so produced came in front of the tumor. Urine and blood were entirely normal. Cystoscopy by Dr. Lincoln Davis, January 14th, showed a normal bladder. Indigocarmin was excreted from the left ureter in ten minutes, but none came out of the right. The ureteral catheter, passed into the right ureter, met an obstruction about 2 inches from the orifice. Dr. Davis made a diagnosis of right hydronephrosis, due either to stone or a kink in the ureter. The obstruction above referred to was only partial, for a pressure over the tumor caused a flow of urine on that side. The urine obtained by catheter from the right kidney showed 0.06 per cent. urea; that from the left, 1.5 per cent. After indigocarmin the urine from the right side was pale greenish; that from the left, dark blue.

Discussion.—The history gives us merely the knowledge that the patient has had three months of epigastric pain and vomiting. Apparently the pain is not severe. There is nothing that suggests the severity of the average gall-stone colic. In addition to this, we have one month of anorexia and constipation. Previous to the physical examination, then, we have nothing distinctive.

In the internal viscera, the most important items are the cardiac hypertrophy and the tumor in the right loin. The increase in blood-pressure is also significant, though we have no exact measure of it. Turning attention to the tumor, it certainly occupies the position of the kidney, and, from its characteristics, should be either a neoplasm or a hydronephrosis. The absence of fever and leukocytosis is against the existence of a pus sac. The further cystoscopic examination leaves little doubt that we are dealing with hydronephrosis. The obstructed ureter and diluted urine are characteristic. There can be no reasonable doubt, it seems to me, as to the diagnosis, but why should a hydronephrosis produce gastric symptoms? As the disease has, in all probability, come on gradually, the other kidney should have taken up the renal function as it diminished upon the diseased side. We should not expect, therefore, any evidence of renal insufficiency or uremia, especially as the mixed urine of the two sides presents apparently normal characteristics. It is hard to believe that merely by pressure a hydronephrotic sac could bring about the gastric symptoms of this case, and I am unable to answer the question which I have just put. It is, however, a not unfamiliar fact that such symptoms are frequently associated with hydronephrosis, although the other kidney remains sound.

Akin to the same problem is the question why an operation does good, and I am unable to answer this question any better than the

other, although I think there is no possible doubt that operation is of benefit.

Outcome.—January 21st the kidney was operated upon and found to be hydronephrotic. The pelvis and calyces greatly dilated, cortex very thin and consisting mostly of fibrous tissue and thickened blood-vessels. The glomeruli sclerosed and atrophied. The cause of the hydronephrosis was not discovered. The hydronephrotic sac was a single one. After operation the patient did very well, and February 15th reported that she had no symptoms, but was still rather weak.

Case 110

A canvasser of forty-five entered the hospital January 18, 1910. His family history, past history, and habits not remarkable. He considered himself perfectly well until October, 1909, when he began to notice an acid taste in his throat, about three hours after eating. This taste would soon be followed by partly intentional vomiting of the contents of the previous meal. This continued until five weeks ago, when the vomiting ceased. Since October his appetite has been failing and he can now hardly taste his food. At that same time he noticed jaundice and pain in the region of the navel, increased by exertion. Early in November a diarrhea appeared, and this has recurred whenever he is tired. He is much troubled by flatulence, especially at night. The old discomfort two or three hours after eating and the acid taste in his mouth still bother him, but meat and eggs seem to go as well as any food and his appetite is fair. Bowels now move daily. He has lost 20 pounds since October.

Physical examination shows poor nutrition, distinct yellowing of the skin and scleræ, normal chest, general rigidity and tenderness of the abdomen, most marked in the upper portion. No abnormal dulness or masses. Liver and spleen not felt. Reflexes normal.

A stomach-tube shows no fasting contents. On water-distention the stomach contains 61 ounces, its lower border reaching 1 inch below the navel. An hour after a test-meal nothing can be recovered. The stools always show slight reaction to guaiac. Blood and urine normal; no fever.

By examination in a hot bath an indefinite mass can be felt in the right hypochondrium (Fig. 101).

On the 26th of January I noted, "No gastric trouble at present. The lumps above referred to does not seem to be connected with the kidney. It is probably associated with the gall-bladder."

Discussion.—The history is not distinctive, but when taken with the observed facts of jaundice, a large but rapidly emptied stomach, and a small mass in the region of the gall-bladder, it seems to me that the recorded data point strongly toward gall-bladder disease. The mass shown in the diagram might perfectly well be attached to the stomach or kidney, but we have no gastric or renal symptoms, while we have one definite liver symptom, jaundice.

If, then, we are dealing with gall-bladder trouble, what is that trouble? The lump, as described, does not sound like a dilated gall-bladder. If it is not a dilated gall-bladder, and yet is connected with

Fig. 101.—Mass felt in Case 110.

the biliary tract, it must, in all probability, be cancer. The main point to doubt is whether we are right in supposing that it is connected with the gall-bladder at all. It is mainly the presence of jaundice which gives us the assurance on this point. But suppose the jaundice was due to some independent cause, such as catarrhal cholangitis, gall-stones, or cirrhosis of the liver, the palpable mass might then be attached to some other organ. It might arise from the pyloric end of the stomach, despite the absence of any evidence incriminating that organ. On the whole, however, the weight of evidence seems to be against this theory.

Outcome.—January 28th the abdomen was opened. The gall-

bladder was found much enlarged and tense. Considerable greenish fluid was evacuated; no stones found. The second part of the duodenum seemed to be filled by a hard mass, and on opening this a cauliflower-like mass, about the size of a pigeon's egg, was found in the region of the pancreatic duct, with its base in the ampulla of Vater. The tumor was removed. Microscopic examination showed it to be a papillary adenoma. After operation the patient did very well until February 1st, when he suddenly vomited about 3 pints of altered blood, and had, at the same time, a large liquid movement. He collapsed and became pulseless, his extremities cold. February 3d the lower end of the wound opened and there was a profuse discharge of intestinal contents, evidently coming from the upper bowel. All fluids taken by mouth issued from this opening, and he was unable to retain food by the rectum. He died February 9th. Autopsy showed chronic interstitial hepatitis and the evidences of the recent operation, together with a duodenal fistula. The presence of a cirrhotic liver was presumably a coincidence. There is no good reason to suppose that it had any connection with the tumor which was removed.

Case 111

A married Russian Jewess of thirty-eight entered the hospital May 8, 1910. Her family history was negative, likewise her past history, except that three and a half years ago she had an attack similar to the present one, lasting three weeks. Her menstruation has been normal until seven weeks ago. None has been seen since. Has had three children, youngest thirteen years old. No miscarriage. For seven weeks she has been troubled by pain in the epigastrium and by vomiting. Now she can retain no food, and vomits immediately after eating. Pain is sharp, but does not radiate. The kind of food makes no difference. She has never vomited blood. She has lost 15 to 20 pounds in weight.

Physical examination shows emaciation, moderate pallor, normal pupils and gums. Heart's apex not seen, but felt in the fifth space, 18 cm. from midsternum in the nipple line. Right border, 4 cm. from midsternum. The sounds are regular and of good quality, no murmurs. Abdomen and reflexes normal. Gastric examination shows a stomach capacity of 32 ounces, the position of the organ being as in Fig. 102. There is no food residue before breakfast. The test-meal was so largely disposed of at the end of an hour that nothing of importance was recovered. In the wash-water free HCl is present.

The blood and urine are normal. Blood-pressure, 115. No fever. Ten examinations of the stools in two weeks show nothing remarkable. Guaiac reaction always negative. Wassermann reaction is also negative.

Vaginal examination showed uterus enlarged, about the size of a three months' pregnancy, and displaced decidedly to the right. On the surface of the fundus several nodules can be felt. She ceased vomiting on the 29th and went home June 3d in very good condition, though she had lost $1\frac{1}{2}$ pounds since entering the hospital.

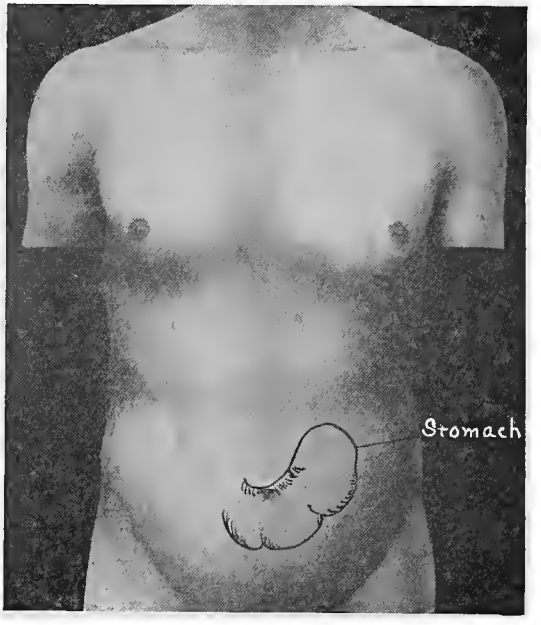

Fig. 102.—Position of the stomach in Case III.

Discussion.—This is a case of obstinate vomiting associated with absent menses, and apparently with displacement of the heart's apex to the left. The latter finding suggests cardiac hypertrophy and possibly uremia as the basis for the dyspepsia, but the low blood-pressure and normal urine make this improbable and the results of pelvic examination give us a much more plausible hint.

In view of the negative results of gastric and intestinal investigation, there is every reason to believe that pelvic tumor is the cause of the patient's symptoms. That tumor might be a fibromyoma, ovarian cyst, or a pregnant uterus. The other possibilities are too rare to need discussion. A fibroid or a cyst would be less likely to be associated

with vomiting and amenorrhea. The most reasonable supposition, therefore, is that we are dealing with a case of vomiting of pregnancy.

Outcome.—The patient was visited January 7, 1914, and said that a son was born to her in the autumn of 1910. She has since had another child and is perfectly well, though she looks sixty rather than forty.

Case 112

A laborer of forty-nine entered the hospital April 26, 1910. His family history was good. He states that he had lung fever, typhoid fever, intermittent fever, and pleurisy, one right after the other,

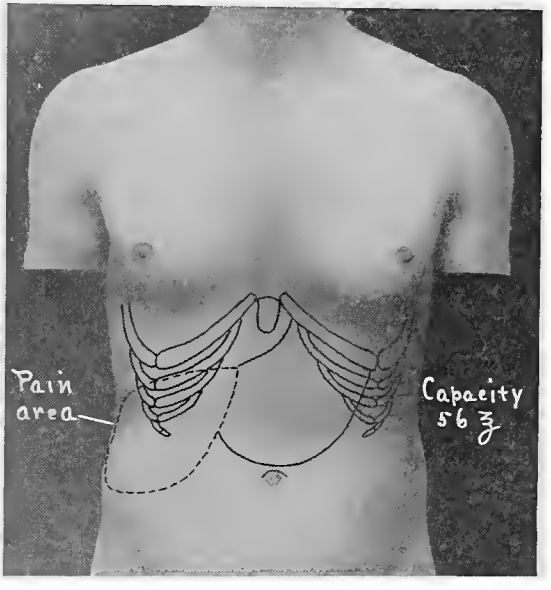

Fig. 103.—Physical signs in Case 112.

when very young. Otherwise he has been well, except that for the past eight years he has had a little stomach trouble, which he did not notice enough to give a clear description of until February 26, 1910, when he began having sharp pains in the pit of his stomach and right hypochondrium, coming at any time of day without relation to meals or kind of food. He also had spells of vomiting three to five hours after a meal, the act usually relieving him. He never vomited large amounts at one time, nor recognized any blood or any substance eaten the day before. The pain which immediately precedes vomiting is very sharp and "cuts his wind." He now vomits three or four times

a week. His bowels have always been very costive, and he has once gone twelve days without a movement. Nevertheless, his appetite has remained good. Since February he thinks he has lost 40 pounds and has been practically unable to work. He uses no alcohol and is generally a man of exemplary habits.

Physical examination was negative except for slight rigidity of the whole abdomen. Preliminary diagnosis was malignant disease of the stomach or intestines. Stomach examination showed a capacity of 56 ounces (Fig. 103), but no fasting contents, and a motility so active that an hour after test-meal there could be nothing recovered. Free HCl, however, was present in the wash-water. May 1st he had some spasm and slight tenderness in the region of the cecum and above it. He was eating well and had vomited but once since entrance. Examination of a stool by Dr. W. F. Boos showed about $1\frac{1}{2}$ mg. of lead calculated as lead sulphate. The blood showed no stippling or achromia and was in all respects negative, as was the urine. No elevation of pulse, temperature, or respiration. Systolic blood-pressure, 130. Ten examinations of the feces in three weeks were uniformly negative to guaiac. During most of his stay in the hospital, which ended May 21st, he was comfortable and his weight increased $2\frac{1}{2}$ pounds. No source of lead-poisoning was discovered.

Discussion.—The loss of 40 pounds of weight in two months with epigastric pain and vomiting in a laborer of forty-nine suggest especially a gastric cancer, gall-stones, and tabes dorsalis. Uremia is also to be considered.

The results of physical examination enable us to exclude all of these possibilities with reasonable certainty, although it is conceivable that his trouble may have been tabes, as no spinal puncture was done. The finding of lead in the stool does not seem to me altogether conclusive evidence that the patient's sufferings were due to lead-poisoning, since we have no possible inkling as to the source of any lead and no other symptoms characteristic of lead-poisoning. I have no better diagnosis to suggest, but do not feel at all certain that we have hit upon the real nature of the man's trouble.

Outcome.—Three and one-half years later, in the autumn of 1913, the patient was perfectly well. This excludes tabes, but does not settle the question of diagnosis in any positive way. If he had lead-poisoning, why should his symptoms have ceased, since we have discovered no source whence he might have absorbed lead?

Case 113

A billiard clerk of fifty-nine entered the hospital June 2, 1910. Until March 1st of that year he was perfectly well, when he began to have dyspepsia and severe constipation, followed later by diarrhea and considerable loss of weight. Solid food caused nausea and distress, followed by vomiting. He has never vomited blood or large amounts of any material. He has had no severe pain. He has lived on cocoa, rice, milk, and eggs, and has eaten as much as he wanted, yet in the past three months has lost 27 pounds. The bowels are regular and he had never seen any tarry stools. For the past month he has not worked on account of weakness. He has had no other symptoms.

On physical examination he was poorly nourished and showed evident loss of flesh. Over his chest, shoulders, and back were many irregular, raised, scaly areas, bright yellow to brown in color, and from $\frac{1}{8}$ to 1 inch across. They were papular or flat, sometimes verrucose. The pupils and gums were normal. He had practically no teeth. The left tonsil showed an excrescence, size of a pea; no exudate. There were a few inguinal lymph-nodes, the size of large beans.

The heart, vessels, and blood-pressure showed nothing abnormal, except that the arteries were thickened and beaded. At the base of the left lung the breathing was somewhat diminished and there was a slight dulness; otherwise the lungs were negative.

In the left loin a mass corresponding to the position of the left kidney was palpable. There was no tenderness and no movement with respiration; otherwise the abdomen was normal, likewise the remainder of the physical examination, including temperature, pulse, and respiration. The urine averaged 25 ounces in twenty-four hours, with a specific gravity 1015 to 1020. It contained from 0.1 to 0.3 per cent. of albumin and a sediment of pure pus from 50 to 120 c.c. in a urine-glass containing 5 ounces. One centimeter of this sediment injected into a guinea-pig June 5th. Six weeks later the animal was killed; autopsy showed nothing. Half a centimeter of the urine collected under aseptic precautions was planted on appropriate culture-media and found to contain a pure culture of Staphylococcus aureus. The pus was present in the urine intermittently, some specimens being quite clear of it.

Cystoscopy by Dr. Lincoln Davis showed normal bladder, with a slight intravesical projection of the prostate. From the left ureter, which appeared normal, there issued at regular intervals a stream of thick pus. Clear urine came from the right. Stomach examination

showed no fasting contents and no reaction to guaiac. After a test-meal, free HCl, 0.09 per cent.; total acidity, 0.2 per cent.

During his two weeks' stay in the medical ward the patient seemed comfortable, complained of nothing, lost 5 pounds, but subsequently regained it.

Discussion.—This man has no teeth, but as he has gotten along without them for fifty-eight years, more or less, it is not probable that their absence would suddenly begin to produce such severe symptoms as are now troubling him.

He is at the cancer age, and, unless evidence of other disease is positive, one must certainly consider gastric neoplasm.

The mass in the loin, when considered with the pyuria, which is of the intermittent (that is, the renal) type, leaves little doubt that the patient has a pyonephrosis. The negative guinea-pig test excludes tuberculosis with practical certainty. Cystoscopy confirms what was reached as the result of other methods of examination, and the negative results of stomach tests further reassure us with regard to that organ. It remains somewhat mysterious that the patient has no fever. But for the presence of pus in the urine, we might suppose that we were dealing with a hydronephrosis.

From the condition of the patient's arteries we may assume that he also has arteriosclerosis, but there is no reason to believe that this is connected with his present suffering.

Outcome.—June 20th Dr. F. G. Balch cut down upon the left kidney, which consisted only of a pus sac, containing large quantities of dark reddish pus and blood. Two or three large rough calculi were found in the sac. Attempts to ligate the pedicle were useless on account of its infiltration. Histologic examination of the mass showed a kidney 16 by 8 by 6 cm., the wall consisting of fibrous tissue, with occasional remains of tubules and glomeruli. One of the calculi removed in the sac measured 4 by $1\frac{1}{2}$ cm. No evidence of tuberculosis was found. The patient gained rapidly after operation and was discharged July 6, 1910, to the Waverly Convalescent Home, the wound not quite healed. November 7, 1912, he reported that he had been perfectly well for over two years.

Case 114

A clerk of twenty-seven entered the hospital June 13, 1910. His family history, past history, and habits were not remarkable. Three years ago he began to have "water-brash" and nausea, coming on at any time without relation to food. He is sometimes free from it for

three weeks at a time, but in the past two years his troubles have been aggravated, and there have been occasional attacks of vomiting and of dull pain in the epigastrium, which attacks make him feel like lying down. At the present time he usually vomits twice or thrice daily and has no appetite.

Formerly he ate a good deal of candy, hurried through his meals, chewed them very little, and took them at very irregular hours. While in Ireland, a year ago, on a vacation, he lived upon simple food and had no trouble. For the past two years his bowels have needed laxatives. He has worked steadily up to entrance. His best weight was 135 pounds; now he weighs 112 pounds.

Physical examination shows poor nutrition, no teeth upon the upper jaw, negative chest and abdomen, normal reflexes, blood-pressure 100, normal urine and blood. Four examinations of the feces showed a positive guaiac test but once, when streaks of fresh blood were visible in the sediment. A stomach examination showed no contents in the fasting organ and no enlargement. After a test-meal the percentage of free HCl was 0.09 per cent.; total acidity, 0.17 per cent. He remained two weeks in the ward, taking at first nothing but water by mouth, and undergoing a good cleaning out of the bowels with magnesium sulphate and calomel. Twenty-four hours later he was fed on milk and toast, with gastric lavage daily before breakfast and sodium bicarbonate when needed for gastric distress. On the 20th of June he was taking all liquids and soft solids, and on the 21st, house diet.

Discussion.—We do not know whether the 23 pounds which this patient has lost left him gradually or suddenly. The patient's poor condition is the most important fact in his case, and makes us hesitate somewhat to attribute his symptoms to his dietetic habits and the lack of any upper teeth. Physical examination, including the investigation of the stomach, is practically negative. The single positive guaiac test is of no importance. Doubtless his constipation aggravates his other troubles, and, if no deeper cause can be found, we may be content to believe that a reform of his habits will cure him.

Many such cases, however, turn out later on to have tuberculosis, lead-poisoning, or some extra gastric cause for their complaints. The decision must rest upon the results of treatment and the subsequent course of the case.

Outcome.—June 25, 1910, he had gained $2\frac{1}{4}$ pounds and was practically comfortable, and that day he was discharged. August 2, 1914, he writes that he is still troubled with dyspepsia, but is at work.

Case 115

A clergyman of sixty-one entered the hospital June 13, 1910, stating that in March, 1910, he had overworked and "his stomach struck for higher pay," causing flatulence and sourness usually after meals, relieved for about an hour by eating more food or by taking hot water with a half-teaspoonful of soda. This medicine caused the escape of gas. His pains have never radiated and have been diffused in different parts of the abdomen. He has never previously had any acute attacks of abdominal pain, and until the present time has been absolutely free from nausea and vomiting.

Aside from the symptoms just described, he is also troubled by weakness. He has lived the last two months on liquids and soft solids.

Three weeks ago he noticed a slight yellowing of his eyes and the darkening of the color of his urine, while his stools became lighter colored, though daily movements occurred. He gave up work two weeks ago and has been in bed since. He thinks he has lost 10 pounds.

Physical examination shows marked jaundice and emaciation. The pupils are slightly irregular and do not react to light or distance. There is a lymph-gland, the size of a bean, at the angle of the left jaw. Chest is negative. Liver dulness extends from the fifth rib in the nipple line to a point three-fingers' breadth below the ribs, where a sharp, irregular, nodular edge can be felt (Fig. 104). Spleen is not palpable. Knee-jerks are sluggish. Plantars normal. No edema. Except for the presence of bile, his urine is normal; likewise his blood, the coagulation time seeming to be unusually short. Wassermann reaction was negative. Stomach examination showed a content of 54 ounces and no evidence of stasis. On inflation the lower border extends two and a half fingers below the navel. After a test-meal the percentage of free HCl was 0.07; total acidity, 0.16.

He stayed two weeks in the medical wards, suffering no pain and seeming generally comfortable. His jaundice, stools, and urine remained the same. Stools always clay colored. The condition of the belly is seen in Fig. 104.

Discussion.—Previous to the appearance of jaundice and emaciation—that is, during the first two or three months of his illness—I see nothing in the history of this case to tell us what is the matter. Our first thought would naturally be cancer of the stomach because of the sudden appearance of gastric symptoms in a man of sixty-one.

I do not see that we could have done better than a guess until the jaundice appeared.

Besides cancer another guess previous to the appearance of the jaundice would have been tabes, as presumably at that time, as well as in June, the pupils failed to react to light and the knee-jerks were sluggish. The gastric disturbances are a good deal less intermittent and paroxysmal than those traditionally associated with tabes, but, as I have already stated, this tradition is by no means a reliable one, and any sort of stomach trouble associated with evidence of tabes should be assumed to be due to that trouble until proved to the contrary.

Fig. 104.—Palpable mass as described in Case 115.

With the appearance of jaundice and emaciation, our attention is naturally drawn to the liver or gall-bladder as the probable source of the trouble. The nodular mass in the region of the gall-bladder is necessarily another alarming fact. But for that one might imagine that gall-stones were the root of his trouble, for emaciation as well as jaundice may be marked in gall-stone obstruction of the bile-ducts and pain is not a necessary symptom of such obstruction. But the absence of fever or any waxing and waning of the jaundice is evidence against stone in the common duct, and if the stone were elsewhere jaundice would be unusual.

If the observation of a nodular mass be taken as correct, one

cannot well suppose that the diagnosis is gall-stones. The patient's best hope rests in the possibility that this observation may be mistaken, and that the supposed mass might be nothing but an enlarged gall-bladder or the edge of a distended liver. The probabilities all point to cancer in or about the gall-bladder. This cancer may be secondary to a similar growth in the stomach or may be primary in the biliary passages.

Outcome.—He lost weight steadily and went home on the 25th, diagnosis being malignant obstruction of the bile-duct. On the 6th of July he returned for operation, which was performed by Dr. F. G. Balch. The gall-bladder was found moderately distended with a thick greenish pus, about 4 ounces in amount, and contained no bile. A stone, size of a robin's egg, was found low down in the gall-bladder, close to the duct. It was removed. The entire course of the common duct showed infiltration and suggested a malignant process. After operation he improved slowly, but his stools still remained very light and his urine dark, always containing bile. On the 25th of July he went home. During the summer he was tapped five times for the relief of ascites. The presence of ascitic fluid previous to these tappings seemed to produce most of the discomfort which he experienced. Emaciation and cachexia were progressive. He died November 7, 1910. It is notable that even at operation the surgeon was not perfectly sure that the stone found in the common duct was not the whole cause of the illness. He suspected a malignant process, but he was not sure of it. The patient's steady downfall, despite the removal of the stone, and especially the fact that ascites accumulated repeatedly, proves beyond reasonable doubt that the trouble was cancerous, and that it later spread into the abdominal glands so as to block the portal circulation.

It seems to me a point of great interest, as we look back over this case, that although the stomach was presumably free from any disease, the only symptoms in the earlier months of the illness were dyspeptic symptoms. These were not due to jaundice, and I do not know how they are to be explained. The association of such symptoms with malignant disease of the gall-bladder has often been observed, but never, so far as I know, elucidated.

Case 116

A factory hand of twenty-three entered the hospital June 17, 1910, stating that two nights ago he ate some hashed ham and pickles at supper, and that about midnight he was seized with sharp, colicky

pain in the abdomen. The pain did not radiate, and was somewhat relieved by pressure and by vomiting. He has continued to vomit since, mostly brown stuff. Last night his pains ceased. He has had green slimy movements of the bowels. This morning his stomach was washed out, and since then he has felt better and is hungry.

Physical examination negative except for rigidity of the abdomen. Slight spasm throughout and dulness in the flanks, which shifted freely with change of position. He ran a slight fever, 99° to 100° F., until the 21st. For the week following that date he was afebrile. At entrance his white cells were 24,000, showing polynuclear leukocytosis. Next day the leukocytes were 10,000. The blood otherwise negative, likewise the feces. Systolic blood-pressure, 140. On the 28th he seemed entirely well and had no physical signs of disease. His vomitus at the time of entrance was brownish and had strong reaction to guaiac. His treatment was starvation for twenty-four hours, and then small feedings of simple ingredients. He gained 2 pounds during his ten days' stay in the hospital.

Discussion.—The history starts out in this case like an acute gastric upset due to indiscretion in diet, but when physical examination revealed abdominal rigidity and leukocytosis, with shifting dulness in the flanks and a fever running to 100° F., it certainly looked as if something more serious was going on. Peritonitis has often been diagnosed on slighter grounds than these, especially with a brownish guaiac positive vomitus.

But, to my mind, all such possibilities are negatived by the prompt improvement within twenty-four hours; also by the fact that the patient is hungry and that his leukocytosis promptly fell. I do not see how we can attribute any serious disease to a patient whose troubles clear up so rapidly.

Just what was the nature of his attack I do not know. Something checked his digestion and started him vomiting. Gastric crises in tabes may begin in just this way, but we have absolutely no evidence of that disease, and the course of the trouble, as shown in the outcome, makes this very improbable. The case seems to me of great interest, as showing how many serious signs may be present in an acute gastric upset, which yet disappears within twenty-four hours. I take it that the observation of shifting dulness in the flanks need not necessarily be incorrect, but probably was due to the shifting of intestines distended with fluid feces.

Outcome.—In November, 1912, a friend reported that he was in perfect health.

Case 117

A cook of twenty-nine entered the hospital June 15, 1910, for the third time. One sister died of consumption, nineteen years ago; family history otherwise not remarkable. November, 1902, she was in bed for three weeks with a sharp epigastric pain and vomiting, the latter persisting until she entered the Boston City Hospital, December, 1902. While there she once vomited a pint of blood. She remained under treatment at the hospital until February, 1903, but still vomited daily at the time of her discharge. During her stay in the City Hospital she was on rectal feeding for three weeks, but has been no better since discharge.

March 31, 1903, she entered the Massachusetts General Hospital, complaining of five months' suffering with sharp pain in the epigastrium, often lasting all night and accompanied by tenderness of the abdomen. Such attacks occurred frequently, often many times a day, lasting about ten minutes each. After about three weeks in bed these pains gradually ceased, but a few days after getting up again she began to have chills every morning and vomited everything that she ate; yet the previous pains did not return. For the ten days previous to March 31, 1903, she vomited even small amounts of milk and lime-water, and had a good deal of burning pain after the attacks. In the week before entrance the vomitus had contained material resembling coffee-grounds. For the same period she had also a slight cough, with frequent attacks of spasm of the glottis, lasting a few moments. On a few occasions she has had moderate sweating at night, and for the past two months moderate frequent headache. Has not menstruated since December 4th.

At this time physical examination showed considerable spasm of the left rectus near the ribs, with tenderness, but no other abnormality, except a slight elevation of temperature, usually $99\frac{2}{5}°$ or $99\frac{3}{5}°$ F., during the whole twenty-four hours, with an occasional fall to normal. This persisted during the twelve days of her stay in the hospital. Her pain was relieved by soda, and after April 2d she had no vomiting. She developed a good appetite during the period of rectal feeding, which lasted until the 11th of April; then her friends decided to take her home.

She was not seen again for five years, when she re-entered the hospital July 18, 1908, stating that after her last hospital treatment the vomiting persisted, occurring at least once a day. About a year after leaving the Massachusetts General Hospital she had a

gastro-enterostomy done at the Boston City Hospital. Four weeks later she was again operated upon; six weeks after that, again, and six weeks later, still again, for adhesions. Again, later, she was subjected to still a fifth operation at St. Elizabeth's Hospital, also for adhesions. Since that time she has vomited three to six times a day a sour, green fluid, mixed with unchanged food. She has had no pain, but a distress which is relieved by vomiting. Her bowels have moved only with enema. She has a dull, constant pain in the right flank and right lower quadrant. When she walks she has a pulling sensation near the navel. Despite all this suffering her appetite

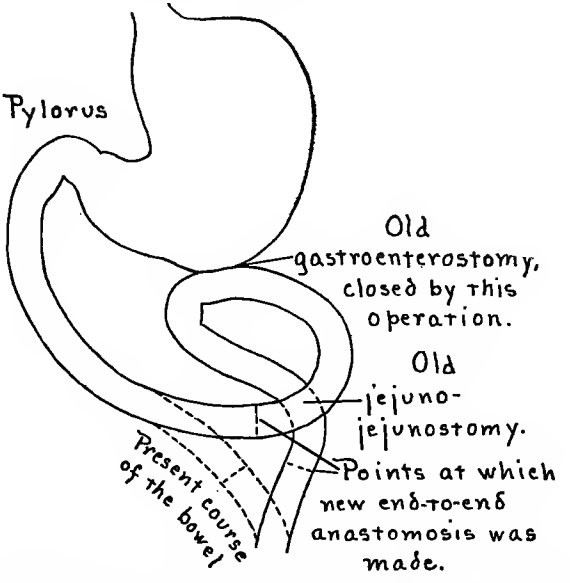

Fig. 105.—The solid lines show the course of the bowel as found at the sixth operation. The dotted lines show the new course made.

has remained good. Her best weight was 135 pounds six years ago. Last winter she weighed 120 pounds.

At this time her chief complaint was still of vomiting. The vomitus always contained bile and often pancreatic juice; *i. e.*, 10 c.c. of vomitus plus 5 c.c. of 0.05 per cent. $NaCO_3$ digests egg-albumin. At none of the operations was any ulcer, scar, or evidence of organic disease found. The patient's sister says that she eats well and only vomits a little "off the top."

On examination the patient was well nourished, and, aside from tenderness in the region of her numerous scars, showed nothing abnormal.

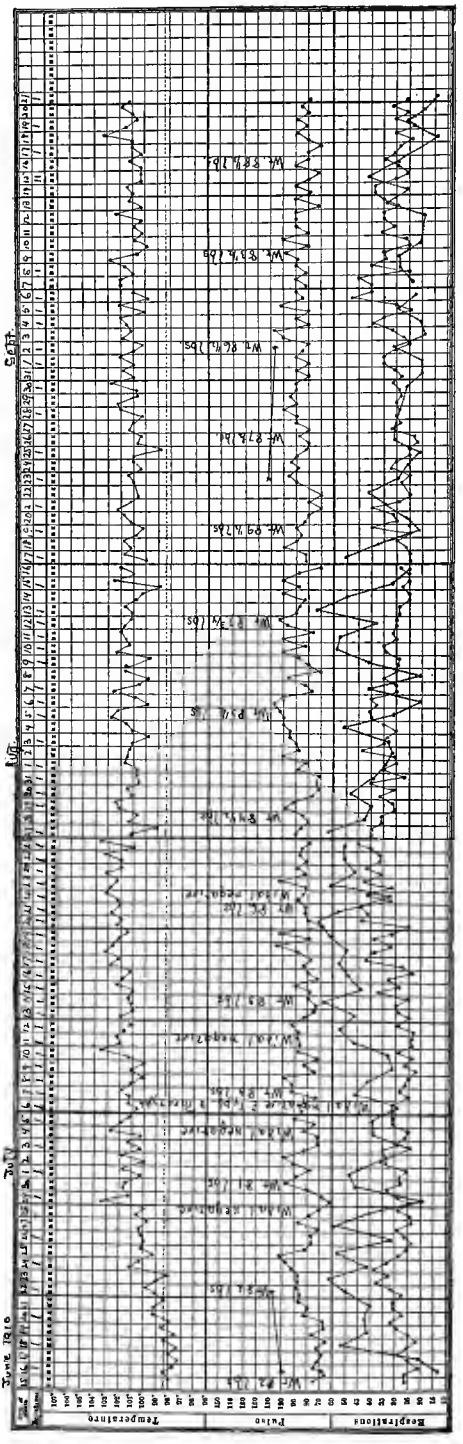

Fig. 106.—Temperature chart of Case 117.

July 20th the abdomen was opened for the sixth time with considerable difficulty, the omentum being found adherent in many places to the anterior abdominal wall. The gastro-enterostomy was found in good condition and freely admitted the tips of two fingers. A jejunojejunostomy, about 8 inches below the stomach, was likewise found in good condition. The pylorus was found to be patent. The old gastro-enterostomy wound in the stomach was closed and the old direct route through the bowel restored (Fig. 105).

During the month of this stay in the surgical wards after this operation she had three waves of fever, ranging in the neighborhood of 100° F. and lasting about a week each, with four or five days intervening. She continued to vomit, but somewhat less severely, and also gained in strength.

A year later, August 27, 1909, she reported, feeling well but looking thin. She was at that time eating no meat and was given advice as to her diet.

She was next seen June 10, 1910, and stated at that time that she had not been troubled with vomiting since her last operation, but that two or three months ago she was kicked in the abdomen by a drunken man and since that has gradually lost strength, though her pain has been only slight. A week ago she began to have more or less persistent retching and slight epigastric pain when standing. She had much nausea and tenderness, and was unable to stand on account of weakness. There was also edema of the feet on standing. July 15th she was transferred to the medical wards, where she remained until September 21st.

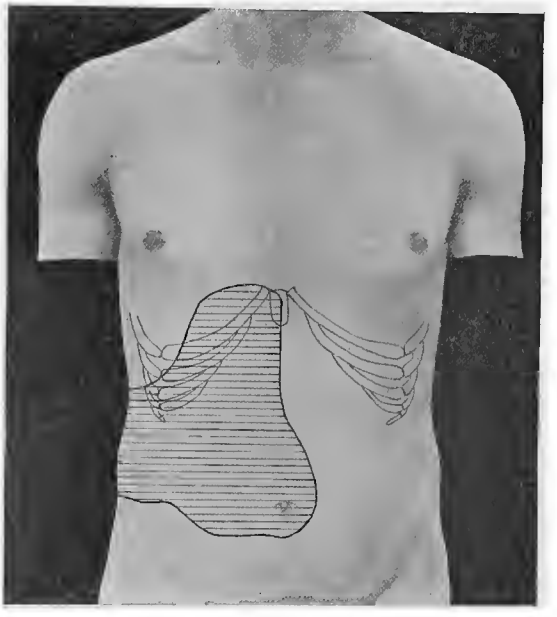

Fig. 107.—Area of cutaneous hyperesthesia in Case 117.

The most striking feature of her case during that period is shown in Fig. 106, which displays a continuous fever, lasting thirteen weeks. It will be noted that *during the first week* of her stay in the medical wards *there was no fever* to speak of. Another remarkable feature of her stay was a *gain of weight during this period of prolonged pyrexia*. She weighed 82 pounds June 22d, when her fever began, and September 16th, after three months' fever, weighed 88½ pounds. During most of the three months of this third stay in the Massachusetts General Hospital she complained of epigastric pain for which nothing could be found to account. An area of superficial skin tenderness was constant and marked (Figs. 107 and 108). The

leukocytes were never increased. There was at no time any spasm or deep tenderness, but the pain was severe enough to require morphin at times.

There was at no time any agglutinative reaction with typhoid culture or with alpha or beta paratyphoid. The Wassermann reaction was negative. "Bed fever" was excluded by having the patient sit up for a number of days without producing any diminution in the fever. A perinephric abscess, subacute peritonitis, tuberculous peritonitis, subphrenic abscess were among the diagnoses suggested. The urine was never abnormal. Orthopedic examination by Dr. R. B.

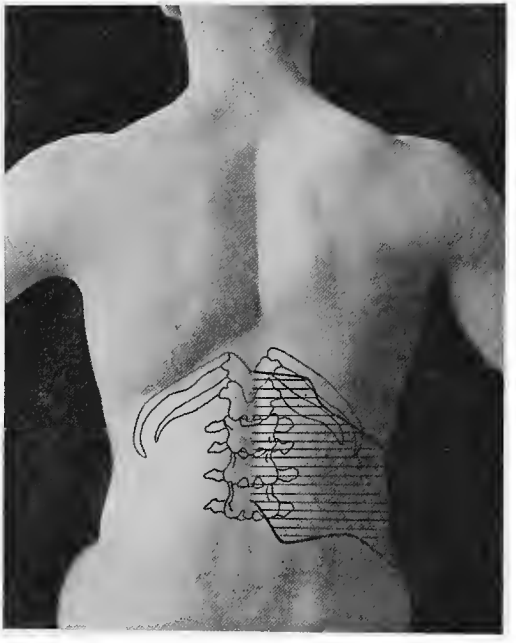

Fig. 108.—Area of cutaneous hyperesthesia in Case 117.

Osgood showed nothing of significance. The fundus of the eye was normal. Blood-culture and cultures from the urine remained sterile. The color fields were plotted (Fig. 109) and found normal. Ten tests of the feces were negative to guaiac. She was repeatedly *x*-rayed without result.

Her pain was partly relieved in August by the aid of high oil enemata, but she remained very nervous and thin and ate but little. Agar-agar increased the bulk of the stools, but had no effect upon the temperature. The skin reaction to tuberculin was slightly positive; 15 minims of the sediment of a catheter specimen of urine was

injected into a guinea-pig July 22d. The animal was autopsied September 1, 1910, and no results found. On the 21st of September she went home quite unimproved, quite unexplained, and still markedly febrile.

October 24, 1910, she returned to the hospital to report, and stated that she had been up and about the house at home, gaining strength, and having less pain. She has kept her temperature chart, the range of which is shown in Fig. 110.

The area of cutaneous tenderness was as before. She stayed only a few days this time for observation and went home on the 27th, weighing 92 pounds.

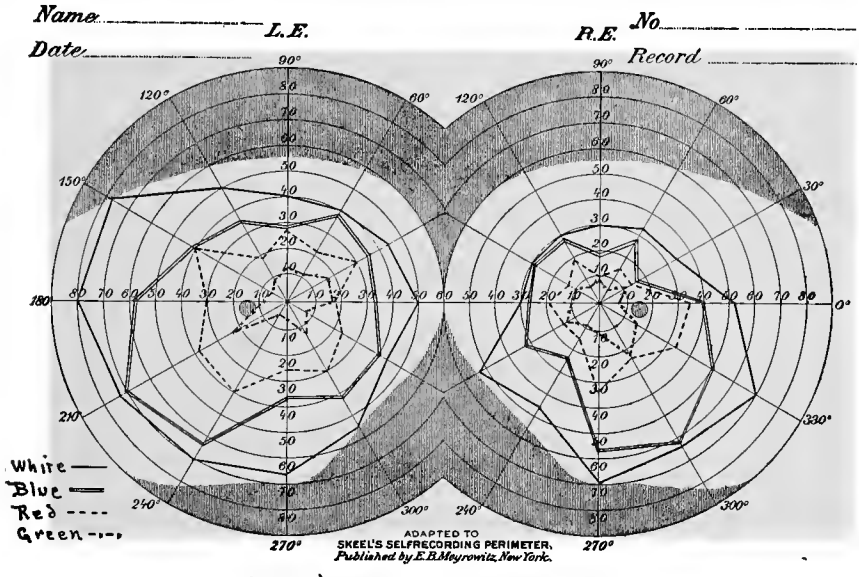

Fig. 109.—Chart of color fields of Case 117.

Discussion.—It does not seem to be worth while to discuss the various possibilities of diagnosis at the time of this patient's first visit to the Massachusetts General Hospital. The most mysterious and interesting part of her illness begins when she returned to the Massachusetts General Hospital, after five years, of what she called vomiting and five operations for supposed adhesions about the stomach. The fact that she was well nourished at this time makes me tolerably sure that her "vomiting" never deserved that term, but was wholly a matter of regurgitating a small part of the meal last eaten, a process familiar enough in babies, whose mothers often refer to it as "spilling over." At this time *the rather unusual operation of undoing gastro-enteros-*

tomy and attempting to restore the normal course of the bowel was performed. The idea of this operation was that the patient's troubles were due more to meddlesome surgery than to any other one factor, and that the best help we could give her was to restore her as nearly as possible to her natural condition before surgery was attempted.

Apparently, then, this attempt to undo the bad effects of surgery was a successful one, for she had two years of good health, despite a curious and quite unexplained fever during convalescence from this last operation.

We come next to the most inexplicable chapter of this patient's hospital life, namely, her thirteen weeks of unexplained fever asso-

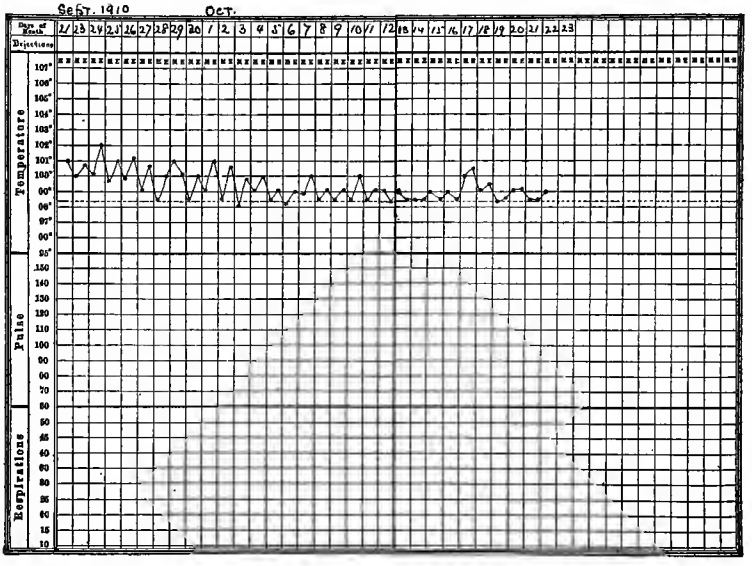

Fig. 110.—Second temperature chart of Case 117.

ciated with gain in weight. I have never been more thoroughly baffled in the study of a case than in this. As the record shows, we did everything that anyone could suggest to find out the cause of her fever, but in the end we knew as little as in the beginning. The important point is that after she left the hospital and without any reference to treatment given by us or anyone else, her fever went down and she got entirely well. To my thinking, the case illustrates several points: First, the harm of operating merely for adhesions. The more I see of such operations, the less I think of them. I have yet to be convinced that adhesions about the stomach, gall-bladder, or appendix are the cause of symptoms in any considerable

proportion of the cases in which they occur. The vast majority of operations done for adhesions and carefully followed afterward prove to be useless or worse. The second point of interest is the definite record of what our grandfathers used to call a "simple fever," or perhaps a "gastric fever," wholly unexplained, entirely benign, and, strangest of all, concident with gain in weight! They covered up their ignorance with names. We are as ignorant, but confess it. I have no explanation to give of the area of cutaneous tenderness which occasioned some of the bitterest of her complaints, and was just as marked after her complete recovery as during the worst of her illness.

Case 118

A housewife of thirty-five entered the hospital June 26, 1910. At the age of seventeen she says she had trouble with both lungs and "pined away to nothing," as the result of a cough with which she raised blood. For the last four years she has again had a cough, but has not raised blood. Four years ago she used to have what she calls "nervous fits," but for the past two and a half years has not had any. Within the last four months she has taken a little brandy for her symptoms. She states that her menstruation comes every two weeks. She has had no children, but two miscarriages, the last eight years ago.

Four months ago her food began to "lie like a lump" in her stomach, and she had nausea, but no vomiting. The epigastric distress was not worse after meals and was not relieved by cooking soda. Three weeks ago she vomited a teaspoonful of blood after violent retching before breakfast. Morning nausea has been frequent since that time. Meat is particularly distressing to her. She states that she has lost no weight, but feels very weak.

Physical examination showed an obese Scandinavian woman with pupils irregular, but reacting normally. The heart was negative and the lungs likewise, except for a few squeaks scattered in both backs and in the left front. The abdomen is full, tympanitic, and somewhat tender throughout, especially in the epigastrium, left flank, and right iliac fossa. In the left front, near the second and third ribs, inspiration is interrupted and high-pitched. Blood and urine are normal. Systolic blood-pressure, 145 mm. Hg.

The patient was starved for thirty-six hours, after which she was given a diet of crackers and milk and speedily recovered her strength. By July 3d she was able to take an ordinary diet, and by

the 5th she seemed perfectly well and ready to go home. Our suspicions were that she took more than a little brandy.

Discussion.—Evidently this patient had pulmonary tuberculosis in her younger days and got over it without any special treatment. It is worth noting that this often happens. It may serve to make us somewhat less confident that the recoveries following sanitarium treatment are always due to that treatment.

We have no way of telling what her "nervous fits" were. No trained observer watched them, and they did not occur during the period of illness which we studied.

The dyspepsia of the last four months is not characteristic in any way of any particular disease. It obviously has not interfered with the ordinary functions of the stomach, for the patient is still obese. That it resulted in the vomiting of a teaspoonful of blood after violent retching is not especially significant or helpful as to diagnosis. It seems clear to me that this may result, whatever be the cause of the retching. I have seen it occur on shipboard as the result of seasickness.

The physical signs in the chest are presumably those of a healed phthisical process. Otherwise the physical examination tells us nothing of importance. In the end we could not be sure of the diagnosis, but the prompt improvement, dating from the time when she was separated from her brandy, is certainly suggestive.

Case 119

A Scotch-Canadian laborer of fifty-eight entered the hospital August 28, 1910. For about twenty years he has had attacks of indigestion at intervals of a few weeks to two or three years, lasting a few hours to several days. Between attacks he is fairly well, except for constipation and a little vague abdominal distress. The present attack, which he considers a fair sample of others, began nine days ago with slight heart-burn. Next day his stomach soured and he vomited twice, but worked all day. This continued for the following day and more or less ever since. Pain is increased during the hour following the meal, but relieved by soda or by vomiting. Six days ago he had severe cramps in different parts of the abdomen, and heard a good deal of gurgling, accompanying a slight diarrhea, which ceased the same day. He has worked until three weeks ago, and says that in those three weeks he has lost 20 pounds. According to his statement, he has passed urine but once in the last six days without catheterization, though he never had to be catheterized before.

On examination he was emaciated and looked twenty years older than he was. His pupils and gums were normal, chest negative, artery walls tortuous and thickened. Abdomen tender on deep pressure in the left hypochondrium. Reflexes normal. Blood and urine normal. The feces, examined every day or two for a month, showed a slight or moderate reaction to guaiac in about half the examinations. They were not otherwise abnormal. The stomach showed no fasting contents, and, after a test-meal, free HCl 0.03 per cent.; total acidity, 0.07 per cent. No reaction to guaiac. Rectal examination negative. Capacity of the stomach was 1900 c.c., and the inflated stomach reached from the ensiform to a point 3 cm. below the navel.

The patient was exceedingly reticent and morose, but did not appear to suffer much. During the month of his stay in the hospital he gained 3 pounds in weight, showed no fever, and complained chiefly of gas in his stomach. His abdomen was always soft. He had one or two attacks of vomiting, but nevertheless improved very much. Upon the whole, it was thought that there was no basis to warrant surgical interference. He was seen by Dr. C. A. Porter, who did not desire to operate.

A year later, July 7, 1911, he entered again, and stated at that time that he got along comfortably until two months ago and had gained 5 pounds over his weight at the time of leaving the hospital. About May 1, 1911, he began to vomit approximately once a week, but by care in his diet could usually avoid it. The vomitus has never been bloody, but sometimes brown. He has distress in the epigastrium about fifteen minutes after meals. This distress is relieved by sodium bicarbonate, but he regards this as an unnatural and dangerous drug, vicious as whisky, hence has used it very little. At the time of entering the hospital he had a spasmodic stiff neck which troubled him more than his stomach. Physical examination was essentially the same as before; *x*-ray examination showed no important abnormality in the spine. The stiff neck disappeared in the course of ten days. It was not accompanied by any fever. During the last of his three weeks' stay in the hospital he complained of nothing and seemed to be entirely well, though on the day following entrance he vomited 16 ounces of a brownish watery fluid, with a strong reaction to guaiac. Dr. Porter saw him again and did not advise operation. Guaiac test was positive in the stools on the day following the vomiting of blood, not at any other time.

Discussion.—This patient has had twenty years of short dyspeptic

attacks associated with diarrhea. At the present time he shows a positive guaiac test in about half the stools examined. His stomach is a little large, but shows nothing of importance. We did not settle, to my satisfaction, the cause of his troubles. Possibly his arteriosclerosis may have accounted for them, but my impression is that some mental or social trouble was back of all his symptoms. There was no proper follow-up work done upon the case, so that I cannot record anything better than my own impressions; but I have seen a number of similar cases in which the study of the patient's personal and family life revealed an abundance of disturbing causes, such as were quite sufficient to upset anyone's stomach. In many hospital cases these causes are entirely neglected or forgotten. The old-fashioned family practitioner, who still plies his beneficent work in smaller towns and country districts, understands and treats this sort of a case far better than the so-called scientific physician, whose clinic is so arranged that he cannot possibly know anything about the mental life or personal problems of his patient.

Case 120

An Italian laborer of fifty-six entered the hospital August 28, 1910, complaining of a month's abdominal pain, nausea, and vomiting. For two years he has had also a persistent cough, and a year ago a slight hemoptysis, lasting intermittently for a week and recurring three or four times since. Never been sick in bed. He denies venereal disease, but has drank heavily until two years ago, since when he has been moderate. The family history is good.

At the present time the cough has subsided and the gastric symptoms are his main trouble. His bowels have moved two or three times daily and the movements have sometimes contained blood. His appetite has been good, but food causes gastric pain. Last night he vomited three or four times and was afterward unable to retain any food. The vomitus was said to be black.

On examination patient was somnolent and slightly pale. Pupils negative. No lead line. Heart's apex in the fifth interspace nipple line, right border 2.5 cm. from midsternum, no murmurs. Pulmonic second greater than the aortic second.

Lungs showed throughout increased resonance, diminished breath sounds, prolonged expiration, and many squeaks and crackles. Showers of fine crackles were especially numerous at the right base. The abdomen showed considerable tenderness in the right upper quadrant with involuntary spasm. The liver dulness was normal, reflexes

normal. The rectum was ballooned and empty, and a little pure pus was expelled soon after entrance. Next morning his chief complaint was of severe pain across the upper abdomen and lower chest. The urine was 17 ounces in the first twenty-four hours, the small amount being accounted for by profuse catharsis. Specific gravity, 1012, with a trace of albumin and no recognizable sediment. White cells numbered 22,500, with 89 per cent. of polynuclears. Hemoglobin, 75 per cent. A specimen of urine planted on blood-serum showed no growth. His purulent sputum planted on blood agar showed no growth of influenza bacilli, though film specimens of the same sputum showed influenza bacilli. No tubercle bacilli. Examination of the feces August 29th and 30th showed large amount of pus, but little food residue and strong reaction to guaiac. No blood-pressure recorded.

The patient could retain nothing by mouth or by rectum. He was given subpectoral injections of glucose solution, but they were not well absorbed. On account of the abdominal spasm and the purulent rectal discharge it was thought that the patient had a local peritonitis which had broken into the intestine and was draining by rectum. As a source for this peritonitis, perforated duodenal ulcer and empyema of the gall-bladder were considered. The oliguria soon improved, and it was thought to be due either to some serious kidney lesion or simply to the fact that he was absorbing no fluid to speak of either by the stomach or otherwise. The similarity between the sputum and the pus passed by rectum, both in its appearance and bacteriologic contents, was remarked upon. He was seen twice by Dr. C. A. Porter in order to determine the question of surgical interference, but no such interference was advised.

Discussion.—Very possibly this patient had phthisis at the time of his persistent cough two years ago, but, so far as we can see, the net effect of this illness was good, for it seems to have resulted in his giving up alcohol or, at any rate, moderating his reaction to that stimulant.

At the present time he has a dyspepsia without any special diagnostic ear-marks or peculiarities. From the history alone no one could guess its cause.

From the physical examination one would suppose that he had had a bronchiectasis, an ulcerative colitis, and some type of nephritis. When the predominating organism in the sputum is the influenza bacillus, when the patient's lung signs are distributed throughout both lungs and are presumably of long duration, bronchiectasis is usually the correct diagnosis. His dyspepsia is presumably a resultant of the different infections above enumerated.

Outcome.—The patient died August 31st, the diagnosis being chronic bronchitis, emphysema, bronchiectasis, and some suppurative process in the abdomen, perforating the colon.

Autopsy showed amyloid nephritis, hypertrophy and dilatation of the heart, localized bronchitis, and purulent bronchitis of the left lung; bronchopneumonia of the right lung; chronic pleuritis, ulcers of the gall-bladder, ulcerative enteritis, and colitis.

Case 121

A shoemaker of sixty-four entered the hospital September 10, 1910, complaining that for the past year he has gradually lost his appetite

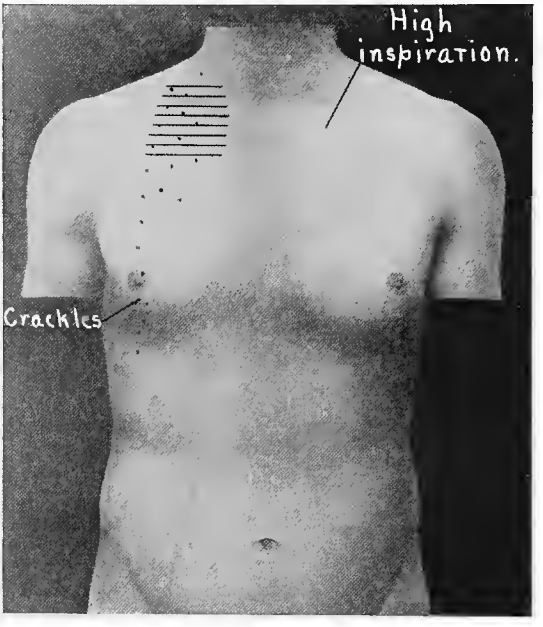

Fig. 111.—Lung signs in Case 121.

and strength. He has been more constipated than usual and has had severe headaches. For about two months he has had constant soreness in the epigastrium and a sensation "like a bullet trying to come up." The latter usually comes on about 9 P. M. and lasts several hours. Somewhat relieved by hot drinks. During the last ten days he has begun to vomit, the vomitus being always small in amount, but once containing skins of peaches eaten twenty-four hours previously. It has never contained blood or coffee-grounds. Usual weight up to last winter, 145 pounds; his present weight, 125 pounds. He retired

from work two years ago to take care of an invalid wife. He entered the hospital with a diagnosis of gastric cancer.

On physical examination he was fairly nourished, normal pupils and gums, heart negative, abdomen negative, knee-jerks and other reflexes negative, lungs as per Figs. 111, 112. His sputum negative for tuberculosis. No single type of organism predominates. The stools September 13th and 15th gave a reaction to guaiac. The stomach-tube was introduced and showed no fasting contents. Test-meal was gone at the end of an hour. In the wash-water no free hydrochloric acid was detected. Capacity of the organ was 870 c.c.

Fig. 112.—Lung signs in Case 121.

During a week's stay in the hospital he had no fever and his blood and urine were normal. He seldom coughed, and had no gastric symptoms after the first few days of thorough rest.

Discussion.—But for the negative results of gastric examination, this case might well be one of gastric cancer. As it is, I see no good reason to doubt that it is similar to many others which I have studied within the past ten years in which the entire foreground of the clinical picture is occupied with gastric complaints, while phthisis is their real cause. It is to be noted that this patient said nothing about cough or any other pulmonary symptom, yet the signs in his lungs were very marked. Although bacilli were not found, there is no considerable doubt that he had had tuberculosis.

Outcome.—It was subsequently learned that twenty-six years ago he had a fistula *in ano*, lasting about a year and cured by operation. At this time he was having a slight cough, and one day, during a fit of laughter, blood gushed in great mouthfuls from his throat and nostrils. He was very weak after this and spent a year in recuperating, but after that time seemed to be well. For the last fifteen winters he had coughed a good deal, but had never given up work.

The patient died a few months after leaving the hospital.

Case 122

A house painter of fifty-seven entered the hospital September 28, 1910, with a diagnosis of "family jaundice" or gall-stones. His mother died at sixty-three of dropsy. She suffered from jaundice for twenty years before her death and had attacks of pain and vomiting at various times. One of her children was slightly jaundiced, off and on, for years, but died at fifty-nine. Another, still living at sixty-eight, has had attacks of abdominal pain with vomiting and jaundice in periods covering thirty years. Five other children have never been jaundiced. The patient's maternal aunt had similar attacks of pain, vomiting, and jaundice for a number of years.

The patient's own past history is negative. He takes three sherries a day and an occasional drink of rum. Sometimes he has whisky before breakfast. Otherwise his habits are good.

For twenty years he has had attacks of jaundice once or twice a year, lasting from one to three weeks. Of late these attacks have been somewhat more frequent. At the onset of such attacks he feels unusual sleepiness and is sometimes feverish. Shortly after this he begins to vomit, usually from one-half to one hour after meals. Vomitus has never been large in amount, but has sometimes contained food eaten the day before. Twenty years ago he vomited about a pint of blood, and twelve years ago saw streaks of blood in the vomitus. He has sometimes noticed that his stools are "black as ink," even when taking no medicine. At other times they are clay colored. He complains of three varieties of pain: First, heartburn, coming on an hour or two after meals, for the relief of which he has consumed large quantities of soda; second, colic in the middle and upper abdomen, relieved by passing gas downward; third, a vague discomfort in the right flank, which makes him unable to lie upon his right side, but bears no relation to meals.

For ten years he has had to urinate about twelve times each

night, the aggregate result being about a quart. Twenty years ago he weighed 160 pounds, a year ago 131 pounds, now 121 pounds. He has followed his present occupation as a house-painter for eighteen years, but says that he had these attacks "before he ever saw a paint-brush."

Physical examination showed poor nutrition and marked weakness. The abdomen was strikingly freckled with brown spots, 2 to 3 mm. in diameter. Mucous membranes were pale and slightly cyanosed. The scleræ showed a slight lemon tint in the deeper parts, but around the iris were white. There was no lead line, but his teeth were all gone on the upper jaw and few were left upon the lower. The heart and lungs showed nothing abnormal. Blood-pressure, 150 systolic, 80 diastolic; urine, 70 to 90 ounces in twenty-four hours; specific gravity, 1011 to 1017, sediment not remarkable. Examination of the blood showed red cells 3,000,000; white cells, 4000 to 8000; hemoglobin, 55 per cent. The stained specimen showed no achromia and a tendency to an increased size in the red cells; some variations in size and shape, no nucleated forms, no stippling. The general appearance of the blood distinctly suggested pernicious anemia.

The abdomen was tympanitic throughout, and showed a slight general tenderness on deep palpation, most marked on the right flank. The liver dulness extended from the sixth rib to a point 5 cm. below the costal margin. Its surface and edge were apparently smooth. Spleen not felt. Reflexes normal.

Discussion.—Our attention is at once attracted by a number of different diagnostic possibilities:

(1) In the first place he is a painter, and almost any sort of indigestion might be the result of lead-poisoning.

(2) In the second place he is an alcoholic, and the same might be said as to the effects of alcohol.

(3) In the third place he gives a history of vomiting a large amount of blood and having black stools. The commonest cause of these occurrences (if they really did occur) is hepatic cirrhosis.

(4) He, as well as his mother and two other members of the family, seem to have suffered from jaundice. According to his own account he must have had forty attacks, which seems highly improbable.

(5) His nocturia may mean failing heart or prostatic obstruction.

(6) Besides all these definite possibilities, he launches us upon a wholly uncharted sea, as he tells the story of his three varieties of pain. None of these pains gives us anything characteristic or definite

to take hold of. We must look to the physical examination to orient us.

One of the first facts to be noted in the physical examination tends to mystify us still further. Why should he have freckles on his abdomen? I know no way to answer the question. As we go on through the physical examination, we note that he has a type of urine often associated with a contracted kidney, whether of the arteriosclerotic or glomerular type of nephritis. We note, moreover, that he has a severe anemia, which might perfectly well be of the pernicious type, as the history suggests. In the internal viscera the enlarged liver is the most striking abnormality.

Putting this all together, it seems to me that the two most probable diagnoses are cirrhosis or syphilis. Either of these might cause all his symptoms. For the one we have an efficient treatment, for the other no treatment at all. The reasonable course, therefore, is to treat him for syphilis.

Outcome.—It was subsequently learned that three years ago he spent eighteen months at an almshouse hospital, with marked edema of the legs and ascites. At that time he was tapped three times, and on the first occasion 4 gallons of slightly bloody fluid were evacuated. For the last eighteen months there has been no edema and no ascites. He worked until ten days ago. After ten days' stay in the hospital, with laxatives and an occasional hypnotic, he presented no symptoms, seemed very cheerful, and was discharged.

Case 123

A factory girl of nineteen entered the hospital September 28, 1910, complaining of stomach trouble, constant and increasing in severity for the last year, especially for three months. She has continual dull, non-radiating pain in the epigastrium, less severe in the first hour after meals, then sharper for the next hour. It bears no relation to the kind of food. In the last two months she has vomited about an hour after almost every meal. Vomitus never contains blood, has been small in quantity, occasionally showing traces of the food eaten the day before. During the past two months her appetite has failed and she has lost weight. Usual standard weight being 158 pounds, she now weighs 145 pounds. She has worked about half-time until four days ago. There are no disturbing mental factors as far as she knows. Bowels move daily. She has no cough. Family history, past history, and habits are good.

On physical examination she is well nourished, skin and mucous

membranes very pale. The heart's apex is 13 cm. from midsternum and 2 cm. outside the midclavicular line. The right border 2 cm. from midsternum. There is a soft systolic murmur heard all over the precordia and in the axilla, but loudest at the apex. The pulmonic second sound is accentuated. The pulses are not remarkable. Systolic blood-pressure, 105. Urine averages 30 ounces in twenty-four hours; specific gravity, 1009, no albumin, no sugar. There is moderate tenderness in the epigastrium, but visceral examination is otherwise negative. Blood examination, September 28th, shows the following: red cells, 2,500,000; white, 3000; hemoglobin, 30 per cent. The stained smear shows marked achromia, moderate variations in size, shape, and staining reaction of the red cells, no nucleated forms. The feces were negative to guaiac on four occasions.

Discussion.—The dyspepsia of anemic factory girls is a very familiar phenomenon and dependent, I believe, upon many causes. In the present case the anemia is so marked that all other causes must be relegated to a secondary or tertiary position, but when the anemia of such a working girl is of lesser grade we often find a multitude of hygienic errors and mental worries which have to be corrected before we can help the patient.

Some years ago one would have felt pretty certain of the existence of gastric ulcer in a case of this sort. To-day we know that such lesions are far less common in young girls than they are in middle-aged men, and that most of the symptoms formerly attributed to ulcer in young girls are due to errors in hygiene, to industrial overpressure, to incipient tuberculosis, to thyrotoxicosis, or lead-poisoning.

It is, of course, possible that this patient may have lost blood from a peptic ulcer of the duodenum, and that her anemia may be secondary to this, and there is nothing in the case which enables us absolutely to exclude such a diagnosis, but the history is certainly not at all typical of ulcer, and much more nearly resembles that of chlorosis, a disease which used to be common and is now rapidly becoming a rarity in all parts of this country. No doubt her working conditions have contributed something to her troubles or have aggravated her chlorosis, but it is not at all probable that they are a sufficient cause of her anemia. Chlorosis is the most probable explanation.

Outcome.—By October 19th the red cells had risen to 3,500,000, the hemoglobin to 55 per cent., and there was less abnormality in the individuality of the red cells. She was able to eat everything without discomfort. The treatment during this period consisted of gastric ulcer diet and Blaud's pills, 20 gr. three times a day, and an

occasional dose of sodium phosphate. On further questioning, it was found that she had for a long time been taking a scanty and hurried breakfast, or none at all, and a cold lunch, bought at a lunch counter and eaten at the factory, where she had been working ten hours a day. Dr. E. A. Codman considered the case one of ulcer of the lesser curvature, but advised against operation. Patient gained 4 pounds during her stay in the hospital. In November, 1912, she reported that she was at work and feeling perfectly well. Further details were obtained at this time regarding the conditions of her work. She has been in industrial life since thirteen, and for the past five years has been fusing wires into the glass stems of incandescent electric-light bulbs. The fusing is done with a gas flame. She has been doing piece-work, and in a ten-hour day fixed 3000 of these wires in their glass stems. No windows could be opened in the room where she worked, and the temperature was very high. A month ago she changed to a paper and pasting job, and now has good air where she works and only an eight-hour day. At the present time her hemoglobin is 85 per cent. and her weight 145 pounds.

Case 124

A housewife of forty entered the hospital October 27, 1910. The patient's complaint was that for six months she had had slight epigastric distress and regurgitation of sour material soon after eating, especially after eating cabbage or acid fruits. Her father died at seventy-two of "pleurisy," and her mother at sixty of "bronchial trouble." The patient had rheumatic fever at fifteen, and was three months in a hospital. In 1908 a painless lump, the size of a pigeon's egg, was removed from her right forefinger, near the tip. It had been growing there four years. The patient has one healthy child, ten years old, and has had one miscarriage.

Five days ago, just after taking a little toast and tea, she experienced an entirely new sensation—a queer feeling of fulness at the epigastrium, followed in a minute or two by dizziness and blackness before her eyes. She was chilly and perspired profusely. She had to lie down and wanted the windows open, but remained conscious. Within a few hours she seemed to be nearly as well as usual, and in the next two days washed and ironed and felt as well as usual. Two nights ago she felt a little faint, but this soon passed off. Yesterday morning, while ironing, she fainted away, and soon after recovering consciousness vomited over a quart of bright red blood. Since then she has been in bed, starved, but comfortable.

Her physical examination was negative except as concerns the blood and the feces. The course of her blood changes is seen in Fig. 113. A strong guaiac reaction was present in the feces continuously from the time of entrance until November 16th; after this it was slight or absent for a few days, and on November 26th disappeared altogether. At entrance she vomited 26 ounces of bright blood. The pulse was almost impalpable at the wrist, but was counted later at 150. She was given $\frac{1}{4}$ gr. of morphin subcutaneously, a hot-water bag at the abdomen, while the foot of the bed was raised. Under this treatment the pulse rapidly improved, but she was given nothing by

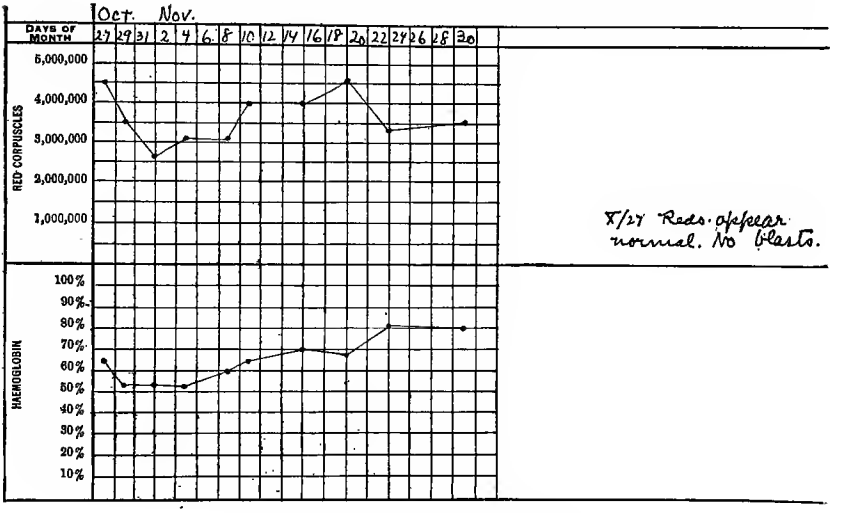

Fig. 113.—Blood chart of Case 124.

mouth until the 31st, when 2-ounce feedings of milk were given every two hours.

During the first twenty-four hours of her stay in the hospital she received $1\frac{1}{2}$ gr. of morphin, and her respirations were kept at from 12 to 15 per minute. Normal saline solution was given by rectum, 6 ounces every six hours, and was well retained. An ounce of brandy was added to each enema. The bleedings did not recur. The amount of milk was gradually raised to 5 ounces every two hours, and November 3d crackers were added; November 4th, lactose; November 13th, eggs, toast, and potato. She had no symptoms and gained steadily, and by December 8th she felt well and was allowed to go home.

Discussion.—The most outstanding fact about this patient at the present time is her anemia (Fig. 113). This is presumably due to loss of blood vomited the day before entrance. It is notable

in the blood chart that her anemia did not reach its maximum until four days later. This is just what one should expect. The blood mass is diminished from the start, but the sample drawn for examination is unchanged. Later, fluid is absorbed into the blood-vessels from the surrounding tissues. The blood mass is restored and the blood-corpuscles diluted at the same time. This ordinarily takes from one to three days, sometimes longer.

What is the source of this patient's hemorrhage? Cirrhotic liver and peptic ulcer are the most probable causes. There is nothing in her history to substantiate the idea of cirrhosis, but such negative evidence is by no means sufficient to exclude it. The patient is about the right age for peptic ulcer, though her previous history is not at all typical of that affection. Possibly much light might be thrown upon her case could we know the nature of the painless lump which was removed from her finger two years previously, but it does not seem at all likely that this was either a gumma, a tuberculous lesion, or a neoplasm.

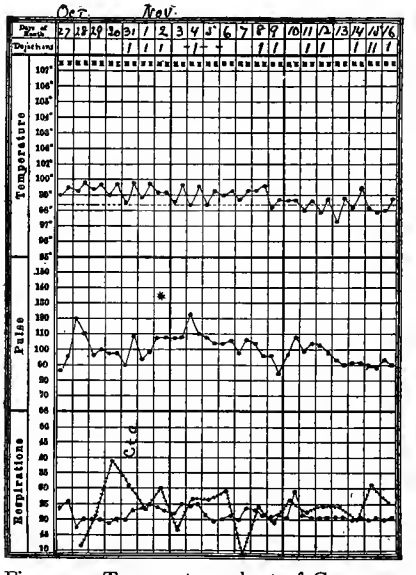

Fig. 114.—Temperature chart of Case 124.

The slight fever which was present in the first two weeks of this patient's illness is characteristic of earlier stages of posthemorrhagic anemia and does not indicate any infection. This point is not always sufficiently realized when we are busy with the differential diagnosis of a fever following hemorrhage. On the whole, peptic ulcer seems the most reasonable diagnosis.

Outcome.—On the 8th of March, 1911, she wrote that she was feeling remarkably well and had gained in weight. The course of her temperature during the first three weeks in the hospital is seen in Fig. 114.

Case 125

A dressmaker of thirty-six entered the hospital October 30, 1910. She has been recommended, October 7th, from the Out-patient De-

partment by Drs. Badger and Lincoln Davis, for subacute appendicitis, and was in the West Surgical wards from October 22d to 30th. During that time the patient was afebrile and had negative urine, but complained of vomiting, pain, and tenderness in the epigastrium and right hypochondrium, with a leukocytosis of 25,000 and 90 per cent. of polynuclear cells. The fasting contents of the stomach showed food, hydrochloric acid, and a negative guaiac test. Vaginal examination was negative.

The more careful history taken in the medical wards showed no hereditary taints. Her husband died two years ago of a paralytic shock, at forty-six. He had been hemiplegic for four years. His mother, sister, and brother have had similar paralyses in middle life. She believes that her husband never had venereal disease. She herself had chorea for two years, from her sixth to her eighth year. Her habits have been good. She has had no children and no miscarriage.

For three months she has had attacks of the above distress, first three at intervals of a week, after that almost daily until her entrance to the hospital. Between attacks she has some vague epigastric discomfort. A typical attack begins with a sense of bloating, extending from the level of the breasts to the pubes. This bloating she asserts, very confidently, is such that at times she bursts her corsets. After a period varying from a few moments to an hour a lump the size of a fist seems to form in the epigastrium and right hypochondrium. It becomes hard, relaxes, and contracts again, rhythmically, with about two contractions per minute. By this time the bloating subsides, but without escape of gas. She may then vomit several times with considerable relief, and the rhythmic contractions are replaced by a distressing sense of emptiness in the lower abdomen. The whole attack lasts an hour or more, and is not relieved by food or drink. There is very little pain connected with it, and none that radiates to the back, scapula, or groin. The attacks prevent sleep, but not work. They may come at any hour of the day or night without relation to meals, rest, or exercise. The vomitus is never large in amount and never contains food eaten the day before. It occasionally shows a fine dark-brown sediment not accounted for by food eaten. There has been no jaundice, no colic, no change in the color of the urine or feces. Appetite and sleep are fair. She has worked steadily. Her best weight, seven years ago, was 142 pounds; now, 136 pounds.

Physical examination showed good nutrition, pupils equal, circular, and reacting normally to light and distance. No glandular enlarge-

ment. Chest negative, save for a very soft systolic murmur heard over the whole precordia, loudest at the apex. Abdomen was also negative. Knee-jerks not obtained. Examination in a hot bath showed nothing abnormal in the abdomen.

Discussion.—The account given of this patient's husband leads us to surmise that he may have had syphilis, especially as the patient has had no children.

The account of the epigastric pain sounds like that often present in appendicitis. It also reminds us of pyloric spasm, the gastric movements representing gastric peristalsis. The gastric symptoms, however, do not read true to any single type of recognized gastric disease, and this fact makes us all the more keen to look elsewhere in the body for a source of the stomach symptoms. We naturally alight on the absence of knee-jerks as a most significant fact in this connection. It is true that the pupils give no support to the hint aroused in our minds by the absence of knee-jerks. The pupils are not those of tabes. But if the disease is confined to the lower segments of the cord we do not expect involvement of the pupils. Further evidence of tabes should certainly be sought, and until this is ruled out no other diagnosis should receive equal consideration.

Outcome.—It was subsequently learned that for the past four or five months she had felt darting pains, as if a needle were thrust into the fleshy part of both calves and passed rapidly through at right angles to the limb. Occasionally she has had similar sensations in the heels or on the dorsum of the foot. There has been no disturbance of sphincteric control, no ataxia or abnormal sensations. A spinal puncture was done November 1st and 5 c.c. of colorless fluid obtained, the cell-count in which was 3 per cubic millimeter. Differential count showed small lymphocytes, 80 per cent.; large lymphocytes, 4 per cent.; endothelial cells, 13 per cent.; polynuclears, 3 per cent. The patient had a typical attack on November 6th, although the bowels by this time had started and were moving well. The attack was apparently aborted by giving 5 minims of a mixture containing equal parts of tincture of capsicum, tincture of belladonna, tincture of aconite, and tincture of actea racemosa.

Case 126

A housewife of fifty-one entered the hospital November 17, 1910, complaining of epigastric distress which has troubled her for three years. It seems to have no relation to meals, but is worse at night. She has considerable nausea and vomits very easily. In November,

1909, she consulted Dr. Chase, of Plymouth, on account of vomiting of yellowish-green bitter fluid. Later she came to the Out-patient Department and was benefited by treatment, but still occasionally vomited. Her bowels are costive, and at times she has seen blood in the movements. Nocturia, two to three times, for several years. Slight hacking cough for a few months. She has no severe or paroxysmal pain. Her best weight, 163 pounds, with clothes, was three years ago. She thinks she has lost 20 pounds in the last four months. Her weight, without clothes, November 18th, was found to be 129 pounds. She has had considerable vertigo and some mental confusion at times.

Yet the patient was well nourished and rosy. Chest negative. Abdomen slightly tender on deep pressure on the right half. Reflexes normal. Blood and urine negative. Systolic blood-pressure, 160. Examined in a hot bath, nothing could be made out except considerable tenderness under the right costal margin. She was seen by Dr. Maurice H. Richardson on the 20th of November. His opinion was as follows: "The history is suggestive of gall-stones or thick, dark, tenacious bile in the gall-bladder. The pain is probably due to irritation and spasm of the gall-bladder. I find no physical signs of disease. I advise an *x*-ray examination of the kidney. If this is negative for stone and other renal lesions, I advise exploratory operation, at which I should expect to find a gall-stone too large to pass the cystic duct."

Discussion.—We certainly must assume a large element of arteriosclerosis in the pathology of this case. The nocturia, the slightly raised blood-pressure, the vertigo, and mental symptoms are best explained in this way. The question then arises whether all the other symptoms, including the abdominal symptoms, can also be thus explained. It must be confessed that we have not as yet any clearly recognizable picture of abdominal arteriosclerosis from the clinical point of view. At the postmortem table it often seems as if there must be clinical manifestations corresponding to the decided predominance of the sclerotic changes in the vessels of this part of the body, yet, as a clinical entity, abdominal arteriosclerosis rests chiefly upon scattered observations by French writers and has never yet been put upon a firm foundation.

Dr. Richardson's theory of gall-stones was probably based upon the occurrence of an unexplained epigastric pain in a stout elderly woman, but surely there have been no typical gall-stone attacks and nothing to give us any certainty of this diagnosis. On the other

hand, gall-stones are probably the most frequent cause of vague symptoms of this type in a woman of her age, and, in the absence of any other well certified cause, it is perhaps as good a hypothesis as any to follow up, especially as the attacks have no relation to meals and are often nocturnal.

Her loss of weight can be explained either by the poor nutrition attendant upon her dyspepsia or by arteriosclerosis.

I see nothing in the case to suggest renal stone.

Outcome.—Since *x*-ray proved negative, operation was done November 23d. The gall-bladder was found to contain several stones, one large stone being firmly fixed in the cystic duct. Colorless fluid was removed by aspiration from the gall-bladder, which was then removed.

The patient left the hospital in good condition, December 11, 1910. December 15, 1911, she wrote that she had gained in weight and had a good appetite, but that pain had returned in her left side, and she still vomited frequently in the morning. In May, 1911, she had some trouble in her back, for which a corset belt was prescribed in the Orthopedic Out-patient Department. This she has worn since.

In November, 1912, she had a dull, steady ache near the heart and under the left shoulder-blade. There was no vomiting except after hot water taken before meals, as a rule, to cleanse the stomach. The water was taken into the stomach and rejected, bitter. Constipation was extreme, requiring laxatives constantly. She bled much at times from the rectum, sometimes had to wear a napkin. Complained of vertigo and queer feelings as if she would fall—as if she were walking on sponge. These were accompanied by precordial and wrist pains, especially on hurrying. She was confused and disoriented at times, but much better in most ways. Examination showed a blood-pressure of 160 and the aortic second sound accentuated. At this time arteriosclerosis, cerebral and cardiac, was evident. No evidence of other disease.

Case 127

A butcher of forty-seven entered the hospital November 6, 1910. His family history and past history were negative. Habits good.

Three months ago he began to have sour stomach and to vomit about ten minutes after every meal. Constipation was troublesome. Appetite was absent, so that, though he continued at work, he would eat almost nothing for two or three days at a time and lose flesh rapidly. After two or three weeks he got his bowels regulated with

the aid of Epsom salts. He then felt much better, and gained in weight and strength during the following three weeks. After that he has been gradually running down again up to the present time.

The physical examination showed emaciation, but was otherwise negative, except that the heart-sounds were somewhat irregular, an entire beat being skipped every four to seven cycles. There was no lead line and no stippling in the red blood-cells. The patient showed distinct mental deficiency with memory defect. In a hot bath nothing could be felt in the abdomen and the urine was negative. Blood showed red cells, 3,800,000; white cells, 15,000; hemoglobin, 65 per cent. The stained smear showed slight achromia, but no other changes of importance. Stools showed a slight reaction to guaiac on about half the examinations. With a 6-inch proctoscope nothing abnormal could be found in the rectum. Lead was found by Dr. Boos in the stools, and examination of the patient's drinking-water showed in 100,000 parts 0.0086 of lead.

During his seven weeks' stay in the hospital the patient had no fever, normal blood-pressure, and gained 1½ pounds in weight. He complained during the first ten days chiefly of paroxysmal cramps in the abdomen, unaccompanied by any distention, visible peristalsis, or constipation. He ate everything that was given him and called for more. Each morning he greeted the house officer with the remark, "My friend, I never felt better in my life." On the 16th of November, at seven in the evening, the patient cried out loudly. His right hand began to twitch and the spasm followed up the arm to the face, then to the arms and legs, and the whole body became stiffened in convulsions, with slight cyanosis and deep respirations. He was unconscious for several minutes, but had no disturbance of the sphincters and seemed practically all right when he came to.

On the 20th he suffered again from severe cramps and the abdomen was slightly distended. In a subsequent attack of cramps the abdomen was rigid. On the 11th peristalsis was quite visible, and, despite the patient's emaciation, the belly was slightly distended. In the day time he frequently slept with his eyes open. He left the hospital December 22d, without any considerable improvement in his condition.

Discussion.—Three months of sour stomach and vomiting, associated with emaciation, abdominal cramps, and visible peristalsis with anemia and blood in the stools—such a group of data should surely make us investigate the stomach and bowels as carefully as possible for evidence of malignant disease. Yet there were indications

pointing in another direction. Extrasystoles and memory defects, together with such twitchings and spasms as were exhibited during his hospital stay, certainly gave us an inkling of arteriosclerosis, cerebral and cardiac.

The finding of lead by Dr. Boos does not seem to me in any way conclusive evidence that this patient was suffering from lead-poisoning. Such a supposition is perfectly conceivable, but it is a well-known fact that lead circulates throughout the bodies of many of us quite undetected and harmlessly. The same is true of arsenic, in small amounts. The mere presence of these metals, therefore, is no evidence of their toxic effect, and, in the absence of any stippling in the red cells, any lead line, or any occupation leading to the ingestion of lead in considerable quantities, it seems to me we should look elsewhere for a more plausible explanation of the patient's cramps and dyspepsia. It is certainly unusual to see lead-poisoning with so fine an appetite.

There was hardly any symptom in the case which might not be explained either by dementia paralytica or by sclerosis of the cerebral arteries. The anemia would be unusual in this connection, and the patient is a little young for arteriosclerosis. The absence of a syphilitic history does not seem to me of any importance.

Toward the end of the record we get the definite observation of visible peristalsis in the abdomen, with some distention and rigidity. This is not easily accounted for by any of the hypotheses thus far considered, and I am not able to explain it. When the patient was in the hospital we were quite suspicious of a cancer in the large intestine, but we got no proof of it. Such a growth would explain the anemia and guaiac-positive stools, but would not account for the mental symptoms, the convulsions, and extrasystoles. It is also very unusual to see a ravenous appetite with any such growth. On the whole, I think arteriosclerosis, involving the heart, brain, abdominal and peripheral arteries, is the best conjecture that I can offer.

Outcome.—The patient entered the Massachusetts State Infirmary at Tewksbury January 25, 1912; that is, more than a year after he left the Massachusetts General. At Tewksbury the provisional diagnosis was cancer of the stomach, but he was so noisy and violent that he was seen by alienists and some psychosis diagnosed. He had previously been committed to an asylum, February 17, 1911. In January, 1912, he no longer complained of severe abdominal pain, though he had occasional attacks of diarrhea. He was then cachectic and confined to bed on account of general weakness.

A year later, January 15, 1913, he died, and there was found a diffuse chronic peritonitis, most marked about the liver and stomach, but also involving the right lower quadrant. The appendix was normal. The right lung showed extensive tuberculous infiltration, there being practically no normal pulmonary tissue in any part of the lung. The upper lobe contained several large cavities. The upper lobe of the left lung was also filled with cavities, while its lower lobe showed smaller ulcerating areas. The kidneys showed a chronic nephritis. There were numerous adhesions between the heart and pericardium and some firm outgrowths in the mitral valve. The rest of the organs were not remarkable.

Remarks.—Presumably, the abdominal symptoms were due to the chronic peritonitis just described. As we have no record of an examination of the brain, it is difficult to make any definite statement about this, but the Tewksbury records show that the patient was much more alcoholic than we had gathered when he was at the Massachusetts General Hospital, and it seems quite probable that his psychosis was due to alcoholism. I trust that the tuberculosis, so extensive at the time of his death, had not made much progress when we saw him. Certainly we had no idea of its presence.

Case 128

A naval engineer of thirty-one entered the hospital November 21, 1910. Previous to November, 1909, he was chief engineer of a United States scouting cruiser, and for eighteen months was in a position of great responsibility and fatigue. In November, 1909, he noticed that smoke did not taste right to him. He began to diet and cut out his daily beer, but two weeks later he began to feel nauseated and occasionally vomited. This time he had the feeling of a lump somewhere in his upper chest, and a sense of indefinite distress when he spoke or swallowed. He was given two months' sick leave and went home to Maine, but in February, 1910, and while on sick leave, he had an attack of nausea and vomiting without any known cause and was in bed seventeen days, part of the time on rectal feeding. He gradually recovered from this attack, but still felt weak after it. May, 1910, was his third attack, after he had been on duty for a month. In this attack he got great benefit from hypodermic injection, the nature of which he does not know. Ten days after he had taken the test of walking fifty miles in three days. In June, August, and October, 1910, he also had attacks like the others, feeling fairly well in the interim.

For five or six years he has noticed a little bright blood in the movement of the bowels and some difficulty in controlling the sphincter. In the morning he also has slight incontinence of urine. At irregular intervals he has sudden, sharp pains in the thighs, knees, or heels, less often in the chest or arms. These pains may trouble him for half an hour or continue all night. His best weight was in 1899, when he weighed 145 pounds. October, 1910, he weighed 125 pounds; now, 133 pounds.

On physical examination he was found to be thin, nervous, with cold, moist hands. His pupils were slightly non-circular and equal. The left reacted normally to light and distance; the right, to distance only. The lymph-nodes showed slight general enlargement to about the size of a pea. Heart and lungs were negative, likewise the abdomen. Knee-jerks were lively and equal. The plantars normal. All the superficial reflexes, especially the abdominal, seemed to be abnormally lively. There was no Romberg sign, but slight hypotonus of the hamstring muscles. No paralysis of the cranial nerves, but the hearing of the left ear seemed to be impaired. No disturbances of tactile or muscular sensation. Wassermann reaction was positive. The blood otherwise negative, likewise the urine. Systolic blood-pressure, 140. No fever.

Discussion.—It is worth noting, first of all, that in November, 1909, before any other distinctive symptoms were present, the patient noticed, as the first deviation from the normal, that tobacco did not taste right to him. I have been told this by many a patient at the very beginning of his illness, long before any other distinctive symptoms appeared to suggest disease of any particular organ. I think the disinclination to smoke and drink is often one of the most delicate indications of the beginning of ill health. It is not that the patient leaves off these habits as precautions, but that he actually loses his taste for them.

Between November, 1909, and November, 1910, there is a history of six attacks, with good health between times. One of these attacks was relieved by hypodermic injection.

Still further back in the history, some time before he considered himself in any way indisposed, we note that there was difficulty in controlling the sphincters, also some sharp pains, which remind us of tabes.

The physical examination supports the theory mentioned at the end of the last paragraph. We have an Argyll-Robertson pupil on the right side, a general adenitis, a positive Wassermann reaction, and

abnormal slackness of the hamstring muscles when the leg is hyperextended upon the chest. Although the knee-jerks are normal, this is abundant evidence on which to found an inference of tabes dorsalis.

Gall-stones are suggested by the sharp gastric attacks and the relief by morphin, but there are many features in the case which cannot be thus explained, and with such definite indications of organic nervous disease we have no right, certainly, to suppose a merely functional or dietetic upset.

Outcome.—At this time the patient stayed in the hospital only a day or two, but January 6, 1911, he re-entered, stating that he had been in first-rate condition since leaving the hospital before, but had had at times slight prickly sensations in the thighs, legs, and heels. To-day there is a small area of superficial tenderness on the upper front of the right thigh. Physical examination was otherwise as before. January 9th he was given "606," and a few days later left the hospital.

Case 129

An unmarried girl of twenty, a mill hand, entered the hospital November 23, 1910, complaining of a burning pain in the stomach two or three hours after meals, often relieved by vomiting. She has had this pain for a year and has been disabled by it. It is never relieved by eating or by water. It often wakes her in the night. She has never tried soda for it. The vomitus is green and bitter, but never contains food or blood. Nine months ago she was operated upon for appendicitis without relief of her symptoms. She feels best when on a diet of milk and eggs. Bowels are costive. Best weight, 122 pounds, at the present time; six months ago, 114 pounds. When she was two, and again when she was ten, she had for some weeks difficulty in passing urine. This was somewhat relieved by hot fomentations. Otherwise her past history, family history, and habits are not remarkable. She is a French Canadian; speaks no English. Menses began at seventeen, but have now been absent for a year. For most of the last year she has been in bed, suffering from pain in the head, back, and legs.

On physical examination patient is well nourished, skin very dry. Hands cold and clammy, with eczematous patches over the knuckles. Chest negative. Abdomen shows slight tenderness on deep pressure in the left flank. There is a surgical scar on the right iliac fossa. The little fingers of both hands cannot be straightened entirely, and there is an apparent atrophy of the fingers about the proximal pha-

langes and some swelling of the knuckles. She attributes the condition to being cut with a sickle when harvesting. There is slight edema of both ankles and both shins, which the patient had noticed for the last two weeks.

Patient stayed five weeks in the ward and failed to gain weight. The blood and urine showed nothing abnormal, and the stools were negative to guaiac on five examinations, scattered throughout the month.

Discussion.—At twenty years of age most dyspepsias are functional, temporary, and, when they occur in a girl, very dependent upon psychic causes or bad hygiene. As usual in such cases at the present day the appendix was taken out, and, as usual, without relief. The case is typical of the most popular and most signal abuse of surgery tolerated by the profession at the present time. A few years ago a similar case would have been subjected to an operation for suspension of a low right kidney, which doubtless was present, although we had not taken the trouble to record it. Ten years earlier she might have suffered an ovariotomy. Doubtless it will be many years before we shall rid ourselves of the curse of unnecessary surgery.

Twelve months' cessation of menstruation is not so significant at this age as it would be later in life, and, when menstruation has been established for only a few years, it needs but little depression of the general vitality to suspend the function for a number of months. Yet, even at twenty, amenorrhea should make us suspect serious disease, such as tuberculosis, and do our best to exclude it. This was done in the present case, and I do not see that we can profitably consider tuberculosis any further.

A point of great importance, it seems to me, in the history of this case is the simple statement that the patient has been in bed for most of the last year. In a person not already seriously ill, such a procedure is enough to produce very great discomfort, if not actual illness. All our sensations are greatly magnified under those conditions, and it needs a very steady head and strong character to keep us out of the clutches of a psychoneurosis, when cut off by "rest in bed" from the normal stimuli and interests of life. While no positive diagnosis can be made upon the facts given us in this case, we can say that sincere and earnest effort has been made to find organic disease and that such efforts have been wholly unsuccessful. This did not necessarily mean that we must incriminate the nervous system. Not all sick patients, with a normal physical examination, have a psychoneurosis. Many

of them have chronic industrial poisonings. Many more are subject to chronic malnutrition, due to faulty habits and poor hygiene. Still others have been thrown off their balance and put out of normal converse with the world by some misfortune, by some secret sorrow, some half-recognized source of worry, or of remorse. In other words, they are in need of the sort of help which a social worker can give. They need to be carefully and sympathetically studied by some one who is used to the commoner sources of trouble in girls of her age, and can gradually find and help to remove the obstacles which for the time have incapacitated them. In the course of such a study, the patient's environment, mental as well as physical—her total environment so far as we can reach it—must be studied. This is difficult, sometimes impossible, but recovery is often out of the question on any other terms.

Outcome.—During most of her stay she had no stomach symptoms. She vomited only once in the five weeks. The treatment consisted mostly of massage, electric-light baths, and Zander exercises. Mild laxatives, occasional doses of sodium bicarbonate and of veronal sodium were given.

Case 130

A housewife of thirty-five, a Russian Jewess, entered the hospital December 4, 1910. Family history negative, and she has always been well and strong. She has had three children, the youngest six years old, and has done all of the work of her household without fatigue. She has had no special cause of worry and has had plenty of sleep. Six days ago she began to be nauseated about 10 A. M. A physician was called, who gave castor oil and put her to bed, where she has remained since, suffering from more or less constant nausea and vomiting, especially at night. The sight of medicine makes her worse. She has eaten nothing for six days, but has been wholly free from pain. Her vomitus has been green and watery, without food or blood. Bowels moved daily.

On physical examination nothing abnormal was detected, except that there was slight dulness and bronchovesicular breathing at the right apex, above and below the clavicle, as far down as the second rib. After cough a few crackles were elicited. The systolic blood-pressure was 95. Vaginal examination negative. The vomiting continued intermittently until the 14th of December. *X*-ray, No. 18,341, showed slight but suggestive shadows in both lungs, especially the left. On the 19th she was given subcutaneous injection of tuber-

culin, 0.005 gram, and showed the temperature reaction indicated in Fig. 115. At entrance the urine showed an intense reaction for diacetic acid, but was otherwise negative, as was the blood. Stool showed no guaiac reaction.

Discussion.—This is the history of what we would ordinarily call simple acute dyspepsia. It comes out of a clear sky, as it were, without previous illness, without known cause. Yet, on physical examination, there is enough in the lungs to hint strongly at pulmonary tuberculosis. The low blood-pressure and the *x*-ray examination afford confirmatory evidence. It is noteworthy that in the *x*-ray picture the left lung appears more extensively involved than the right. The tuberculin reaction does not seem to me of much importance. Almost any one of her age and living in a large city will have a positive tuberculin reaction, although the size of the dose which produced this reaction gives it, perhaps, some significance.

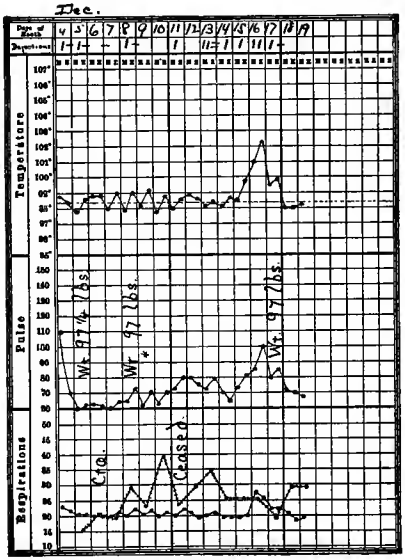

Fig. 115.—Chart of Case 130.

The chief point of interest in the case is the presence of gastric symptoms, which may conceivably have had no relation to the pulmonary processes, but are yet extraordinarily common in association with such a process.

I may mention in connection with this a similar case in a man of forty, who came to the hospital December 5, 1910, complaining of nothing whatever except pain in the stomach, so severe that he could take only liquids. He had no loss of weight and no cough, yet there were well-marked signs of phthisis at both apices and down as low as the second rib in front. There was, moreover, an old healed tuberculous process in the lower third dorsal and first two lumbar vertebræ.

Outcome.—She left the hospital on December 19, 1910, and on March 10, 1911, Dr. Cleaveland Floyd, of the Boston Consumptive Hospital, reported that she was doing very well at home, under the guidance of the hospital nurse.

Case 131

A cutler of forty-six entered the hospital December 4, 1910. The night before he went to bed feeling perfectly well, after a supper of simple foods, except for two pig's feet. At four this morning he waked from sound sleep with a feeling of pressure in the flanks. At the end of an hour this pain traveled to the median line in front and became severe and constant, causing him to double up. It did not radiate. Was accompanied by a slight nausea, but no vomiting. The bowels had moved normally the morning previous. A year ago had an attack like the previous one after a meal of rather indigestible food, but a movement of the bowels completely relieved him. Was at work again within thirty-six hours. As a rule he takes no alcohol, but several times a year he stops work and drinks until he "sees cats and dogs." The last occasion was three weeks ago. Otherwise his past history, habits, and family history are not remarkable.

When examined he was in considerable pain. His pupils slightly irregular, but reacting normally. No lead line. Chest negative. The whole right side of the abdomen, especially the upper portion, was rigid and moderately tender. The knee-jerks normal, and there was no other abnormality. In the course of the afternoon the pain and spasm subsided, and next morning he seemed to be well and was accordingly discharged.

Discussion.—Here is a case which we may (although with some hesitation) call acute dyspepsia, meaning thereby an arrest or delay of digestion without known cause and running a short, afebrile course to complete recovery. Such a diagnosis is warranted only when the patient's history and physical examination reveal absolutely nothing except the digestive attack itself, and when, moreover, the outcome of the case supports this hypothesis. I know of no diagnosis more often contradicted by the subsequent outcome than that of acute indigestion. We are constantly reading in the newspapers that so and so was seized at a banquet or while making an address with an attack of acute indigestion. The statement practically never turns out true. In the great majority of cases the attack is a cardiac or a cerebral one.

Outcome.—The patient was seen November, 1912, and stated that he had been working steadily since he left the hospital. A year ago he had one attack similar to that described above, although it lasted but a few hours and went off of itself as soon as his bowels moved.

This attack, he says, he is quite sure was brought on by overeating. "I am like a boy with a stick of candy," he said. He was at work again the next morning and has been perfectly well since.

Case 132

J. C. E., a pattern maker of seventy, entered the hospital March 20, 1911. Was formerly a hard drinker, and twenty years ago had sores on his shins and knees. Later a chancre, but no secondary symptoms. Was never treated for this. For the past thirty years has taken practically no alcohol. Tobacco, ten cents a week.

His present complaint is of indigestion, which has troubled him more or less for twenty years. An uncomfortable, empty feeling under the left ribs is present off and on, but he may be free from it for months at a time. At its worst this discomfort is never severe, and until the past few months has never disabled him or needed treatment. During these twenty years his bowels have been regular, but the daily movement has been loose. During the past two years he has been constipated and has taken agar-agar and sodium phosphate in the Out-patient Department, with relief. During the past few months the bowels have moved only with enemata.

Besides the discomfort above mentioned, he sometimes has a dull ache in the abdomen and back, especially after a day's work or when he is worried. Food seems to make no difference. The pain never comes at night. Though he has periods of improvement, often lasting weeks, on the whole, he grows weaker and more miserable. Until the past few weeks there has been no vomiting; since then he has often raised a little sour water after periods of pain. A bowel movement gives more relief than anything else. Since last summer he has been unable to work. Five years ago he weighed 150 pounds. Within the last two years he has lost weight and now weighs 119 pounds. Lavage by Dr. H. F. Hewes last September showed no food residue, no positive guaiac test either in the stomach contents or in the stools. After a test-meal a free HCl was 0.08 per cent. The family history is negative.

Physical examination showed a marked emaciation. Good color, normal pupils, no glandular enlargement. There was a marked depression at the lower end of the sternum. The heart and lungs negative. The abdomen showed slight tenderness on deep epigastric palpation. There was a marked right inguinal hernia and slight left inguinal hernia, otherwise the abdomen is negative. The right shin showed a brownish discoloration. Reflexes were normal.

On the 21st the stomach-tube, passed before breakfast, showed a few shreds of orange fiber, but no other food residue. The capacity of the stomach was 1900 c.c. On inflation, the lower border came just below the navel, the upper border at the ensiform. After an Ewald meal the stomach contents showed a faint guaiac reaction and free HCl 0.04 per cent.; total acidity, 0.07 per cent. On the 24th there was a very considerable food residue before breakfast. Free HCl 0.07 per cent.; guaiac test negative. It was difficult to wash the stomach clean on this or on subsequent attempts. Guaiac test was positive in the stool of March 24th, though negative two days previously.

Discussion.—Points of interest in this case are: (1) The history of twenty years' gastric discomfort upon a basis of alcoholism and possible syphilis. (2) The fact that throughout the illness pain has been comparatively slight. (3) The negative stomach examination seven months ago, although at the present time his stomach shows obvious evidence of stasis. (4) The presence of HCl in the gastric contents. (5) The negative physical examination, except for the evidence of emaciation, which apparently has been going on for two years.

In a man of seventy such history certainly justifies us in surmising that gastric cancer is present. At the same time we must remember that renal insufficiency (that is, uremia or its equivalent), gallstones, arteriosclerosis, or cirrhotic liver might produce the same troubles.

The physical condition seems to be fairly good despite the marked emaciation, and it seems to me that he has a right to exploratory incision for possible gastric cancer.

Outcome.—On the 30th of March Dr. G. W. W. Brewster advised exploration, which revealed a mass just above the pylorus, and extending along the lesser curvature nearly to the cardia. The mass at the pylorus was the size of a hen's egg. Posterior gastro-enterostomy. Patient made a good recovery, and left the hospital on the 13th of April with the wound well healed and with a considerable gain in weight. Seen May 19, 1912. States that since leaving the hospital has been in good health and gaining weight, up to about four weeks ago. He has not vomited at all. For the last four weeks he has been having severe pain in the left loin and back. A tumor the size of two fists is now palpable in the epigastrium and to the left of it. The patient is now losing weight.

Remarks.—It is notable that the patient had at least a year of

good health and gain in weight. Presumably within the last four weeks the growth has begun to progress, but it seems to me clear that the gastro-enterostomy was well justified.

Case 133

A bacteriologist of forty-three entered the hospital April 6, 1911. He states that he has always been below his proper weight in spite of careful and long-continued efforts to raise it. His digestion is capricious and uncertain. Eggs, fish-chowder, oysters, and creamed soups have been hard to get in and easy to get out of his stomach for a num-

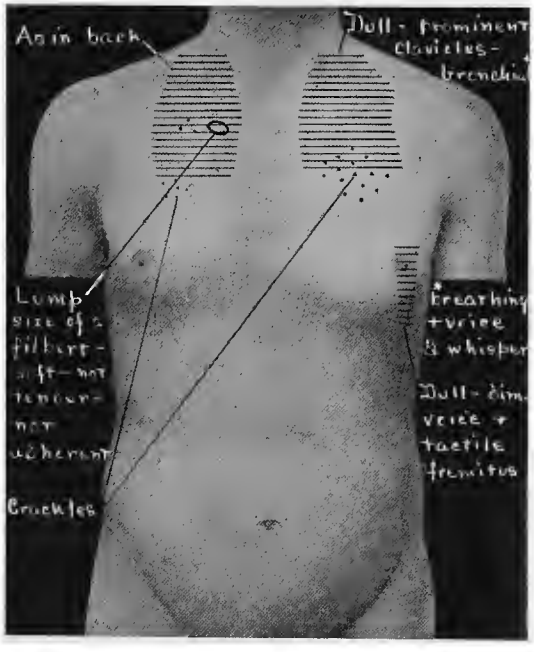
As in back
Dull - prominent clavicles - bronchial
Lump size of a filbert - soft - not tender - not adherent
Crackles
Breathing + voice & whisper
Dull - dim. voice + tactile fremitus

Fig. 116.—Chest signs in Case 133.

ber of years. For the last four years he has had pain following any acid food. Meats agree with him well. If he eats rapidly he gets in more food than if he stops to talk between times, and chiefly on this account he has found it impracticable to dine in company. He says that he has not eaten a square meal for years, partly from lack of appetite and partly from fear of consequences.

As a rule, he wakes up about 4.30 A. M. very hungry. Hunger ripens into epigastric pain if he does not get breakfast by 8 A. M. He has some epigastric pain all the morning, and by 11.45 it is severe, If lunch is prompt he gets relief from food, but if it is delayed, a pain

as sharp as toothache in the epigastrium causes distaste for all food. After lunch he has a sense of weight, which gradually develops into pain and bothers him all the afternoon. After an early supper he goes to bed and to sleep. He is rather chagrined to be obliged to state that immediate sleep prevents the completion of the history of his pains for the day.

In December, 1909, he had a pulmonary hemorrhage after the inhalation of the fumes of hot glacial acetic acid. During the next two weeks there were several more hemorrhages, 2 or 3 ounces at a time. Associated with these, there was a slight cough. Dr. J. J.

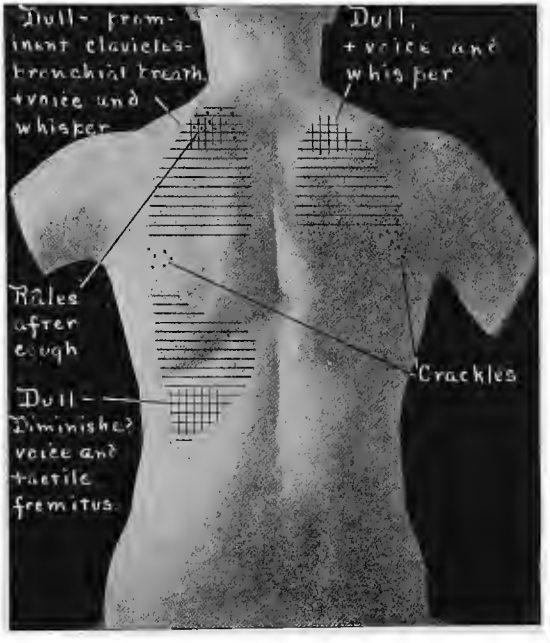
Dull- prominent clavicles- bronchial breath +voice and whisper
Dull, +voice and whisper
Rales after cough
Crackles
Dull- Diminished voice and tactile fremitus.

Fig. 117.—Chest signs in Case 133.

Goodale examined him at this time and found varices at the base of the tongue.

At the same time of these hemorrhages the patient had also three attacks of hematemesis, about 8 ounces in amount, with tarry stools. He was quite sure that this blood was not previously swallowed.

Since June, 1909, he has done no work, as he had at that time a heat-stroke and has had irregular fever ever since. Most of last winter he was in bed, apparently because that was the only warm place he could find.

His family history is excellent.

Physical examination shows emaciation, flushed face, slight cyanosis, chest as in Figs. 116 and 117. Pulmonic second sound sharply accentuated. Apex first sound reduplicated. Heart otherwise negative, likewise the rest of the visceral examination. The blood shows a leukocytosis of 15,000 to 19,500. Range of temperature shown in Fig. 118. Stomach-tube reveals no fasting contents. A test-meal was not given, as his stomach improved rapidly under a diet of liquids and soft solids. He was soon changed to a normal diet.

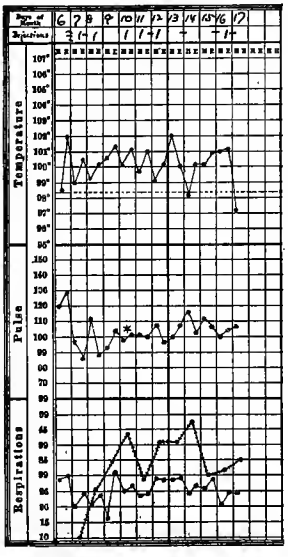

Fig. 118.—Chart of Case 133.

Discussion.—The nature of the variegated dyspepsia from which this patient has suffered for four years ought to have been clear long ago, when it was known that he has been having fever for at least two years, yet it is clear from the way in which the history was given that the pulmonary hemorrhage of December, 1909, was not at once recognized for what it must have been, namely, an evidence of pulmonary tuberculosis, but was faultily connected with the inhalation of acid fumes. The fumes may have started the patient to coughing, but the hemorrhage was undoubtedly of tuberculous origin.

The same fatuous eagerness to avoid facing the facts, and to snatch at any explanation other than the obvious one, is shown in the importance attributed to finding dilating varices at the base of the tongue. Such findings are not uncommon when people are trying with all their might to blind themselves to the existence of pulmonary tuberculosis.

There is some doubt as to the origin of the blood vomiting. The patient may be right in supposing that he had not previously swallowed the blood, but I do not feel nearly as sure upon this point as he did. There can be no reasonable doubt of the diagnosis in this case, but to me the point of chief interest is the rapid improvement following the administration of a good deal more food than the patient had believed himself able to take. As in so many other cases, dyspepsia is due to starvation and starvation to dyspepsia. Break the circle by forced feeding, despite discomfort, and we soon get back to normal digestion.

Outcome.—Tubercle bacilli were abundant in the sputum. Stools were always negative to guaiac.

Case 134

A rivet driller of forty-nine entered the hospital May 26, 1911. Twelve years ago the patient was troubled with indigestion for a week, otherwise he has been well all his life until his present illness, despite the fact that he smokes and chews thirty cents' worth of tobacco a week. His family history is negative. For the past year he has been troubled more or less by indigestion, showing itself in gas and epigastric distress one-half to one hour after food, relieved by belching of gas or by vomiting. He has never tried soda or food for relief. The onset of this trouble was rather sudden, and it has grown neither better nor worse. He is never free from it more than a few days at a time. He never has vomited any blood or coffee-ground material, but only food recently eaten. His bowels have been constipated throughout the year of his trouble with indigestion, though they had never been so previously. In February, 1911, he did not feel up to his work, but he kept at it until a month ago, when increasing weakness and lack of ambition compelled him to desist. He first came to the Out-patient Department on account of stiffness, lameness, and swelling of his feet. He has no other complaints.

Physical examination showed poor nutrition, but was otherwise negative. Systolic blood-pressure, 120. Urine negative. Stools negative to guaiac on six examinations and free from any abnormal constituents. Red cells, 1,600,000; white cells, 6000; hemoglobin, 50 per cent. Blood-plates, 196,000. Differential count normal. The stained specimen showed many large and well-stained red cells and a few that were achromic, marked variations in size and shape, occasionally an off-colored or stippled cell. Four normoblasts were seen while counting 200 whites. Wassermann reaction was negative. The patient stayed two weeks in the hospital and improved considerably in all respects, his red cells rising to 2,500,000, hemoglobin 70 per cent. during that period. On the 8th of June he left the hospital.

Discussion.—There is nothing characteristic in the history, although at his age any abruptly appearing dyspepsia threatens cancer. It is, however, rather suggestive that when he gave up work it was on account of weakness and not for any other reason. This state of things is especially apt to be associated with a blood-count like that recorded in the physical examination; in other words, with pernicious anemia, of which that blood-picture is almost typical.

It has been repeatedly said in text-books and elsewhere that gastric cancer not infrequently is associated with a blood-picture indistinguish-

able from that of pernicious anemia, and, doubtless, in rare cases this must be true, since it has been believed by excellent observers, but in my own twenty years of observation of pernicious anemia and of gastric cancer I have never known a case in which a mistake was made. Indeed, in comparison with the frequency of mistaken diagnosis in other diseases—a frequency on which I have insisted[1]—it seems to me very notable how rarely one makes any such mistakes in differential diagnosis involving pernicious anemia as one of the diseases considered. Prior to autopsy in such cases I have repeatedly made positive statements as to what would be found by the pathologist —statements which I should not be willing to make regarding any other disease.

Case 135

An Irish housewife of fifty-six entered the hospital July 1, 1911. The patient has always been well until the winter of 1910 and 1911, when she noticed that she became easily tired when at work. She had had no previous illnesses and had an excellent family history. For the past three months she has had epigastric distress, coming an hour or two after eating and lasting from two to four hours. It comes especially after eating potatoes or other heavy vegetables. She never vomits and has noticed no jaundice or blood in the stools, but her epigastric distress is constantly aggravated.

For the same period she has been losing strength and weight, about 20 pounds in all, she thinks. She has also had a great deal of sweating and a dull, heavy feeling at the top of her head.

Physical examination shows good nutrition, normal pupils, glands, and reflexes. Chest negative, save for a soft systolic murmur following the first sound at the apex, and not transmitted. The liver dulness extends from the fourth interspace, mammary line, to a point 3 cm. below the ribs, where a smooth, tender, rounded edge is felt. The splenic dulness is increased, and the spleen is palpable and very slightly tender. It extends into the left flank and can be felt bimanually (Fig. 119). Urine negative. No fever in two weeks' observation. Systolic blood-pressure, 120. Fundi normal. Stools negative. The blood shows reds, 5,000,000; whites, 212,000; hemoglobin, 100 per cent. The differential count showed polynuclears,

[1] "Diagnostic Pitfalls Identified During a Study of Three Thousand Autopsies," R. C. Cabot, Jour. Amer. Med. Assoc., December 28, 1912, vol. lix, pp. 2295–2298; "A Study of Mistaken Diagnoses," R. C. Cabot, Jour. Amer. Med. Assoc., October 15, 1910, vol. lv, pp. 1343–1350.

44 per cent.; myelocytes, 47 per cent.; eosinophils, 2 per cent.; mast-cells and basophilic myelocytes, 4 per cent.; transitional forms, 2 per cent. Ten normoblasts and one megaloblast seen while counting 500 cells. The red cells show no changes except rarely a little fine stippling. Blood-plates, 572,000.

Discussion.—The cause of this woman's three months' dyspepsia, with emaciation and sweats, could never have been found without a general physical examination of the kind that many physicians rarely make in an office visit, because of the waste of time involved in getting rid of corsets and other impediments. The case is typical of many

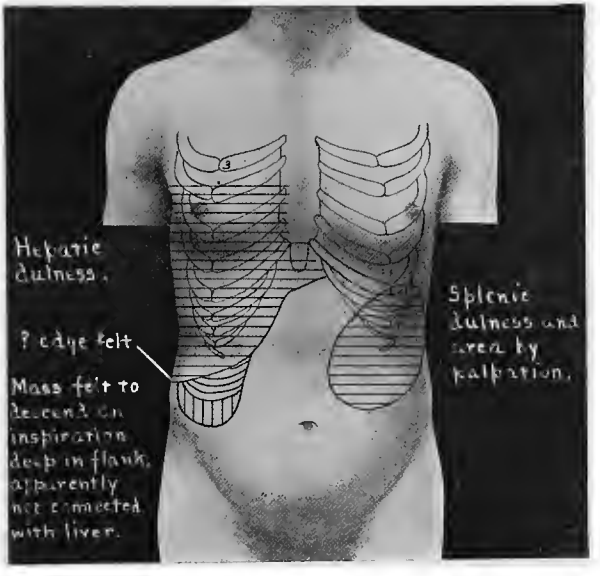
Hepatic dulness.
? edge felt
Mass felt to descend on inspiration deep in flank, apparently not connected with liver.
Splenic dulness and area by palpation.

Fig. 119.—Physical signs in Case 135.

others in which diagnosis is so easy as to be almost inevitable, provided we make a general physical examination, but wholly impossible if we neglect this procedure. As soon as the spleen was felt (and it could hardly have been missed by anyone who went through with the routine procedures of abdominal examination) it would naturally occur to any educated physician to examine the blood, which, in turn, would lead straight to the diagnosis of myeloid leukemia.

Outcome.—The patient was given *x*-ray treatment, and showed a fair degree of improvement during the two weeks of her stay. She left the hospital on the 15th of July.

Case 136

An Irish housemaid of thirty-nine entered the hospital August 10, 1911, after considerable study in the Out-patient Department. For the past year she has been troubled almost constantly by flatulence and slight epigastric distress, coming either directly after meals or an hour or two later, relieved by soda or by hot water, which expelled gas. There has been no vomiting, no nausea, no pain, no loss of weight, and no weakness. In the Out-patient Department her case was studied by Dr. F. T. Lord and no evidence of stasis found. The guaiac reaction was slightly positive in the wash-water before breakfast and no free HCl was found after a test-meal.

For three months her symptoms have been aggravated, and have consisted chiefly of pain and vomiting. The pain is in the epigastrium, extending to the left axilla and back. It is sharp and cutting, comes within a very few minutes after the taking of any food, liquid or solid. It is intermittent, the sharp attacks lasting not over five minutes and being relieved by belching. In the intervals between these attacks there is a sense of epigastric soreness.

The vomiting which began three months ago has gradually increased in frequency. Now she vomits after almost every meal. The vomitus is small in amount, white or greenish, never dark or blood stained, and never containing food eaten the day before. Throughout the day and night she belches large quantities of gas. The bowels are no more constipated than they have been all her life. A year ago she weighed 135 pounds, and until the last three months she thinks there was no loss of weight. Since then she believes she has lost 25 pounds, together with much color, and has become very weak. For three weeks she has been unable to work. Her appetite, formerly very good, has failed during the last two months, and for five weeks she has eaten scarcely anything. There has been no jaundice.

The patient is emaciated and slightly pale, skin very dry. Pupils and mouth negative. Over the left clavicle are a few small painless glands. There is marked suppuration at the roots of the teeth, which are in very poor condition. The chest is negative. The abdomen is relaxed, and shows just above the umbilicus in the middle line a small rounded mass, moving slightly with respiration and moderately tender (Fig. 120). The outlines of the stomach by auscultatory percussion are shown in the same diagram. The reflexes and pelvic examination were negative except for moderate chronic thickening in both culde-sacs. Blood-pressure, 110 mm. Hg. Blood and urine normal. No

fever in four days' observation. The stomach-tube is easily passed for a distance of 49 cm. Attempts to pass it further are unsuccessful and cause pain. No fasting contents are obtained. After a test-meal, which was vomited, the vomitus contains no free HCl. The gastric capacity was not measured. Well-marked visible peristalsis is observed. The patient continued to vomit frequently during the four days of her stay in the medical wards, free HCl being always absent in the vomitus. The diagnoses considered were gastroptosis, gastric stasis, and cancer of the pylorus and cardia.

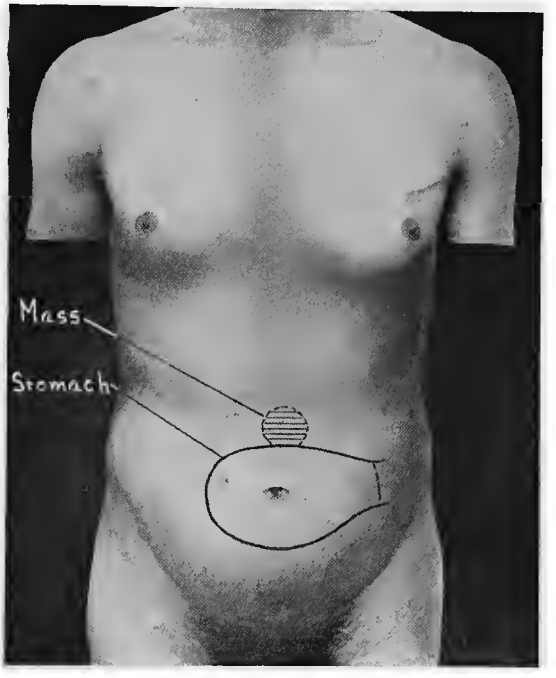

Fig. 120.—Signs detected in Case 136.

Discussion.—Although this patient is only thirty-nine, and although the amount of pain which she has suffered is greater than that which we usually see in gastric cancer, the fact that she now has a palpable epigastric mass (Fig. 120) and has lost 25 pounds' weight within three months, must surely make us very apprehensive of cancer, especially with a positive guaiac test and no HCl in the gastric contents on repeated tests. The fact that the stomach-tube would pass no farther than 49 cm. from the teeth is evidence that the growth involves the cardiac orifice of the stomach, but, in all probability, it is not confined to that region, since we observed peristalsis, appar-

ently gastric in origin. Such peristalsis usually means pyloric obstruction, although in a very thin person it may sometimes be observed with a normal pylorus. Further evidence pointing toward an obstructed pylorus is the great dryness of the skin.

With pyloric stenosis, water is not passed into the intestine as it should be, and, as water is not absorbed in the stomach, the tissues become abnormally desiccated. This should always be remembered when we note striking dryness of the skin in a patient complaining of any gastric symptoms.

A point of notable interest in the case (provided that I am correct in the diagnosis of gastric cancer) is the preservation of a good appetite until the last two months before she came under observation.

Outcome.—Bismuth *x*-ray, August 14th, showed dilatation of the lower end of the esophagus and obstruction of the cardiac orifice. On the 16th Dr. Scudder opened the abdomen and found a hard nodular mass along the lesser curvature, most noticeable at the cardiac end. The pylorus was patent and normal. No liver nodules were made out. An opening was made in the anterior wall of the stomach, 3 inches above the pylorus, a soft rubber tube was introduced, and the wound closed around the tube. The patient did very well after operation until about the first of September, when she began to lose ground despite the attempt to nourish her through the tube. She was, accordingly, discharged. Three months later she died at her home.

Case 137

A school-teacher of thirty-two entered the hospital September 23, 1911. Her father died of tuberculosis three years ago, and was taken care of by the patient some months before death. The mother also died of tuberculosis last May, and was also taken care of by the patient. One maternal uncle died of the same disease. Four brothers and four sisters are living and well. Patient has been well until four years ago, when, during a period of very hard work, she began to have attacks of "stomach trouble," characterized by epigastric pain, moderately severe, not radiating, coming most often before breakfast and somewhat relieved by food. The attacks were accompanied by flatulence, but not by vomiting.

These attacks come when she is especially overtired and last one or two weeks. For the last two years she has noticed a very gradual loss of strength, though she has continued to do her work with occasional "days off." During the last two years she has had occasional "breathless spells," varying from half an hour to a day in length.

The slightest exertion makes her very weak and short of breath at these times. These spells have increased in frequency of late. There has been no edema except from varicose veins and when she has been standing all day. She has had grumbling pain in the lumbar region, ascribed to much walking. During the past summer there have been occasional "fainting spells," in which she prevents a complete loss of consciousness by quickly lying down. During this same period singing and buzzing noises in her ears have also troubled her. Her bowels are habitually constipated. She has had no cough and no sputum at any time. She has kept steadily at work until five days ago, when, without known cause, she began to vomit, and has not since been able to retain any food. Her best weight, 132 pounds, was a year ago, but she thinks she has lost somewhat since that time.

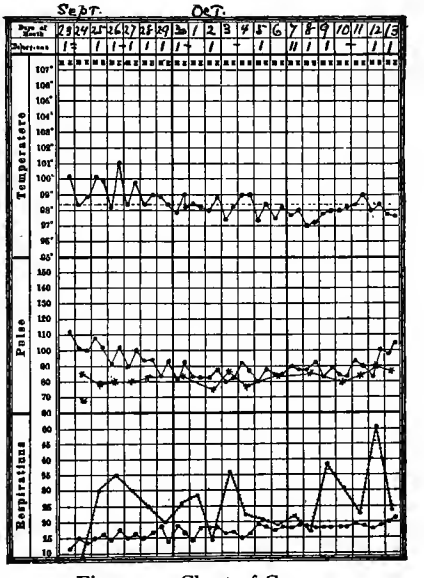

Fig. 121.—Chart of Case 137.

Physical examination showed the patient poorly nourished and looking sick. The face and neck showed marked brown pigmentation and the skin of the body was generally dark. Patient insists that she has always been "almost as dark as now and that last spring she was much darker." Later she admitted that the lower part of her body had definitely, but very gradually, been growing darker during the past year. The lower part of the sternum, where the corset presses, was more deeply pigmented than elsewhere, except in the axillæ and groins. The pupils slightly irregular, otherwise normal. There was no pigmentation in the mouth.

The heart's impulse was not seen or felt, but its sounds were best heard in the fifth space, 9.5 cm. from midsternum. There was no enlargement on the right. The apex first sound was distinct, reduplicated, and accompanied by a faint systolic murmur, not transmitted. There was no accentuation with the pulmonic second. Lungs and abdomen showed nothing abnormal. Reflexes were normal. There were moderate varicose veins in the left lower leg. Blood-pressure was 85 mm. Hg. systolic, 68 mm. Hg. diastolic, and during

her month's stay in the hospital the systolic pressure ranged close to 80 (Fig. 121). Blood showed red cells, 4,960,000; white cells, 10,000; hemoglobin, 80 per cent. The stained smear showed slight achromia. The polynuclear cells, 49 per cent.; lymphocytes, 49 per cent.; eosinophils, 2 per cent. The urine averaged 25 ounces in twenty-four hours; specific gravity, 1010 to 1012. Trace of albumin was always present, and in the sediment there were many hyaline and finely granular casts with cells or fat adherent. At three examinations the feces were in every way negative.

The vomiting was controlled by limiting the nourishment to liquids in very small amounts, 1 to 2 teaspoonfuls at a time, given frequently. Meantime 6 ounces of normal saline solution, containing 15 per cent. glucose, were injected every six hours by rectum. Iced champagne in small amounts helped to relieve her. Later, albumin-water, oatmeal gruel, toast, and minced chicken were added. She ceased vomiting the day after entrance and gained somewhat in strength. By October 3d she was eating meat and vegetables, and was able to sit up with a bed-rest and read a little. Up to the 16th of October she seemed to be gaining, sat up out of bed, and was cheerful. On the 16th nausea began again and could not be checked. By midnight on the 18th she was pulseless and completely exhausted. At 2 A. M. she went into a stupor and at 7 A. M., October 18th, died.

Discussion.—A family history of tuberculosis, four years' trouble with dyspepsia, two years' suffering with cardiac attacks, and three months during which the patient has been subject to fainting spells—such data lead us to look carefully for any evidence of Addison's disease, and, despite her statement that her skin has always been brown, despite the absence of pigmentation in the mouth, we can hardly fail to interpret the discoloration of the skin and the low blood-pressure as confirmatory evidence of Addison's disease. This holds good despite the fact that the brownish areas are more marked where the corsets bring pressure.

The only question which seems to me deserving of further discussion is this: Has she, in addition to her Addison's disease, any nephritis? The urine has a notably low specific gravity, but this may very possibly be accounted for by deficiency of solids, especially of proteins, in her nutrition. The number of casts is somewhat greater than that ordinarily seen in the urine of Addison's disease, and one might well conjecture that some amyloid disease of the kidney is present, were it not for the fact that amyloid disease is usually associated with those forms of tuberculosis which involve chronic sup-

puration. We have nothing to suggest any such suppuration in this case.

If the diagnosis is Addison's disease, we have in the family history a reason for believing that the adrenals are tuberculous.

Outcome.—Autopsy No. 2940 showed Addison's disease, but no nephritis. The cortices of the adrenals were very atrophic, but there was no tuberculosis.

Case 138

A housewife of twenty-nine entered the hospital October 18, 1911, for the third time. Her first entry was August 10, 1906. At that time she stated that she had had dull constant pain in the epigastrium for a year, not affected by food and not literally constant, and also a similar pain low down in the back, not affected by menstruation or by posture. For a week she has had six to ten watery movements a day, without blood or tenesmus. Yesterday the pain in her back became very severe, and was compared, by her, to the pains of childbirth. Morphin was given subcutaneously. Since yesterday there has been no movement of the bowels.

Physical examination showed normal pupils and gums, normal chest and abdomen, normal reflexes. No tenderness along the spine or over the sacro-iliac joints. Hip movements and back movements free and painless. Uterus was slightly antiflexed, but freely movable and of normal size. There was tenderness and thickening in the region of the left broad ligament. Blood and urine negative; no fever. Patient seemed so slightly sick that she was allowed to go home in four days.

Her next entry was April 18, 1911, when she said that she had felt pretty well until a year previously, when she began to have an intermittent blood-tinged vaginal discharge, lasting during June, July, and August, 1910, and accompanied by epigastric pain. The latter has persisted ever since. Catamenia began April 17th, a week before time. Previously to that time it had not been abnormal.

Three months ago she began to notice a sense of pressure in the epigastrium, producing eructations of gas and regurgitations of fluid after meals. Soon after that she noticed a pain in the small of the back, especially when lying down, and subsequently frequent and scanty though not painful urination, occurring by night two or three times and more often in the daytime. Two weeks ago she became conscious of a mass in her abdomen which feels to her different from the enlargement present when she has been pregnant.

Physical examination showed a mass the size of a very large grapefruit, extending from the pelvis to a point 2 inches above the navel, broader below than above, and extending into the right lower quadrant farther than to the left. It was freely movable from side to side, felt firm and not fluctuant, but also not nodular. Bimanually the uterus was felt in front of and below the tumor mass, with which it seemed only slightly connected. Pressure upon the tumor was not transmitted to the cervix, but pressure upon the fundus uteri was transmitted to the cervix. April 22d the abdomen was opened and a single solid fibroma of the right ovary, the size of a grape-fruit and weighing 2000 grams, was removed. Microscopically, it consisted of edematous fibrous tissue, with occasional small cysts in the midst of it. The appendix was normal, but was removed on general principles. The uterus was suspended from the abdominal wall.

After operation the patient did very well, and was discharged May 8th. October 18th, of the same year, she entered once more, and this time it was learned she had been treated in the Out-patient Department since October, 1904, complaining chiefly of pain in the back and constipation. A diagnosis of chronic bronchitis and also of obesity was made at that time.

After leaving the hospital in June, 1911, she remained well for about three weeks and weighed 140 pounds. Then she began to vomit more and more frequently, and went to the Baptist Hospital about July 1st, where Dr. M. H. Richardson removed a large left ovarian cyst. She stayed in the hospital until August 1st and vomited occasionally throughout this period. Since discharge she has vomited once or twice every day, usually after meals in the latter part of the day, but she sometimes is awakened in the night by vomiting. She has ejected large amounts—a gallon, she says—at one time, always green and slimy, but without blood. Vomiting bears no relation to the kind of food taken. She has no severe pain and no jaundice, but some irregular cramp-like discomfort in the lower abdomen. Her appetite is very poor and she says she has lost 56 pounds. Her present weight, without clothes, is 102 pounds. At the Baptist she weighed 134 pounds.

Physical examination showed moderate emaciation, marked tympany in the epigastrium, a sense of resistance in the right lower quadrant, and a sausage-shaped, probably fecal, tumor in that region. The firm sharp edge of the liver was felt at the costal margin, and an irregular, rounded, firm, insensitive mass was also felt across the epigastrium, under the costal margin. This mass descended with respira-

tion, but the examiner was in doubt whether it was continuous with the liver, and surmised that it might be of fecal origin. Except as above, external examination was negative. In the fasting stomach a large amount of dark-brown fluid was present, probably 200 c.c. or more. Microscopically, it contained many sarcinæ, yeast cells, and epithelial cells. The reaction to HCl was strong; that to guaiac, negative. A test-meal was vomited at the end of fifteen minutes. Second test-meal, removed at the end of an hour, showed free HCl 0.039 per cent.; total acidity, 0.135 per cent. No guaiac. The capacity of the stomach was 1560 c.c.; it was almost impossible to wash the organ

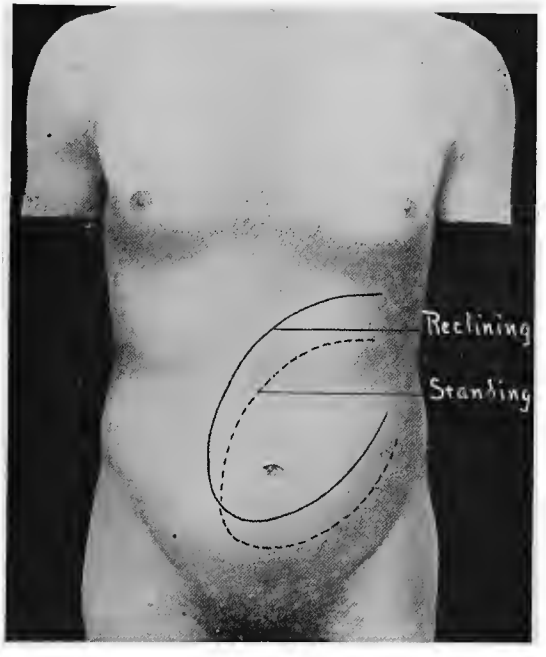

Fig. 122.—Gastric outlines in Case 138.

clean. On inflation the outline was as in Fig. 122. The mass described in the epigastrium disappeared after the first examination and was not found again. Vaginal examination was negative, likewise the blood and urine. Systolic blood-pressure 105; no fever. No guaiac reaction in the stools on three tests. October 22d peristalsis was seen in the region of the stomach, especially in attacks of pain and distress. She vomited large amounts of partially digested food each evening, fifteen minutes to one hour after supper.

Bismuth *x*-ray examination showed a typical picture of dilated stomach, with practically complete obstructions at the pylorus and

absence of peristalsis. When standing up the patient's stomach was low and far to the right. The cause of this obstruction was not clear, but the record states that ptosis and adhesions were considered the most probable cause.

Discussion.—Summing up this rather prolonged case, one may say that a woman of twenty-nine, complaining of a year's dyspepsia and of a recent diarrhea, with very severe lumbar pain, is first treated in 1906 for a few days, and recovers so speedily that no definite diagnosis is possible.

Five years later she notices intermittent metrorrhagia and a return of the dyspepsia, which in the meantime has been in abeyance, although she has had some constipation and lumbar pain and been treated for obesity. She is operated on in 1911 for fibroid of the right ovary and soon after undergoes a second operation for a cyst of the left ovary. After this second operation she becomes rapidly emaciated, losing apparently 56 pounds within six months. At the end of that time a mass is found in the epigastrium, associated with gastric stasis, visible peristalsis, and *x*-ray evidence of pyloric obstruction. All this evidence, despite the fact that the epigastric mass soon disappeared, would lead us to conjecture that the patient now has gastric cancer. Whether or not this growth has any connection with her previous ovarian tumors I have no means of judging.

Outcome.—October 24th she was operated upon the third time, and a hard tumor found at the pylorus, extending down upon the duodenum about 1 inch and also in scattering areas over the anterior surface of the stomach. Hard glands were found along the lesser curvature as high as the pyloric vessels and behind the stomach. The liver was apparently not diseased. Posterior gastro-enterostomy was done, and she was allowed to go home November 14th, after having an uneventful convalescence.

Remarks.—The case is worth remembering as a proof that gastric cancer may occur at twenty-nine.

Case 139

A housewife of thirty-six entered the hospital November 16, 1911. For the past two months she has had indigestion, characterized by a heavy ache and distressed feeling with a sense of pressure in the epigastrium, one to three hours after meals. Never any sharp pain. Distress lasts one to two hours, and is relieved by lying down, but not by medication. Occasionally vomits in these attacks, vomitus being sour and containing food eaten the same day. At first she was re-

lieved by vomiting, but at present is not. Bowels have always been constipated, but are specially so of late. She has had no jaundice, no headache, or edema. She has gradually eliminated everything from her diet except milk and lime-water. A year ago her weight was 125 pounds; now, 100 pounds.

Physical examination shows poor nutrition, negative chest. Systolic blood-pressure, 110; abdomen rigid, tympanic, not tender. Reflexes normal. Before breakfast stomach contained about 20 c.c. of brownish turbid fluid, with a slight reaction to guaiac, and 0.04 per cent. HCl, but no evidence of food. After a test-meal the contents showed HCl 0.05 per cent. The blood and urine were normal.

Discussion.—Here we have the familiar picture of a person who, with the best intentions, has been starving herself to death by gradually eliminating from her diet one food after another which seem to her the cause of her discomforts.

The chief point of interest in the case is that merely by starving herself she has brought her dyspepsia to such a point that it is now associated with gastric stasis, doubtless of the atonic type. Such a stasis need cause no apprehension, and should never be considered a ground for operative interference.

A great many such cases are allowed to run on into chronic invalidism because the medical attendant has not the courage or the personal force to compel his patient to eat despite her own certainty that she cannot do so, and despite the very real discomforts which follow all attempts to take the foods which have previously troubled her. To such patients I frequently quote a saying of a lady whose force of character should be more widely admired and emulated, "I am not going to be bullied by my stomach. When a thing disagrees with me, I eat it again."

Outcome.—She remained in the hospital until December 4th, and it became evident that she was thoroughly tired out. She steadily improved under rest and an occasional dose of sodium bicarbonate and cascara, with mild tonic baths. Stools always negative to guaiac. She gained 4 pounds in seventeen days.

Remarks.—Genuine fatigue (which must be clearly distinguished from the nervous sensations of fatigue often seen in persons who have undergone no physical or mental strain and have done no physical or mental work for many months) is not infrequently a source of very persistent gastric and cardiac weakness. Prolonged rest of mind and body will accomplish, in such cases, the beneficial results for which we look in vain in neurotic cases subjected to a rest cure.

Case 140

A maid of forty-eight entered the hospital November 25, 1911. Family history negative. Five years ago she was taken with sudden severe pain in the epigastrium, coming immediately after a luncheon and lasting three or four hours. It did not radiate and was finally relieved by powders, the nature of which she does not know. In this attack she vomited food just eaten, but no blood.

Eight months ago she had an exactly similar attack every day for a week, and in this attack she was jaundiced. Pain usually relieved by hot drinks and by "something injected into her arm." After this she was free from trouble until her present attack.

For the last month she has had almost daily attacks of indigestion, characterized by gastric distress and a gnawing sensation immediately after meals, lasting one-half to one hour and not amounting to actual pain. Twice she has vomited sour material. There has been no jaundice. Four days ago she had a severe attack of pain in the epigastrium immediately after lunch. The pain lasted until five o'clock the next morning and was very severe. She took no medicine for it and vomited repeatedly.

Two days ago she was comfortable, but yesterday had moderately severe pain, coming on just after she had taken her soup for dinner, lasting six hours, and relieved by "mineral water." No vomiting this time, but the patient felt feverish. For the last four days she has eaten nothing but malted milk, oatmeal gruel, and cocoa. Throughout her last attack her bowels were very constipated and her urine dark. Her best weight, eight months ago, 162 pounds; now, 150 pounds.

For four years she has noticed a bunch in the lower abdomen. Never painful or inconvenient in any way. It has remained of the same size. Her menstruation often lasts between one and two weeks.

Physical examination shows a slight yellowish tint to the skin and possibly a slight yellowish discoloration of the scleræ. The pupils are slightly irregular in outline, but otherwise normal. The gums normal. Chest negative.

In the abdomen an uneven nodular tumor is felt above the pubes, in the area shown in Fig. 123. It is not tender, but extends down well into the pelvis, where it seems to be connected with the uterus. It can also be felt by rectum. Reflexes and other features of physical examination are negative. Blood-pressure, 115. Urine and blood

negative, except for a slight polynuclear leukocytosis. No fever during ten days' observation.

Discussion.—A bunch noticed for four years in the lower abdomen is generally a fibroid tumor of the uterus or an ovarian cyst, but we have no good reason to suppose that this patient's dyspepsia of the past eight months has necessarily any connection with the long-standing hypogastric mass.

The nature of the present dyspeptic troubles becomes much clearer when the jaundice is found on physical examination. This

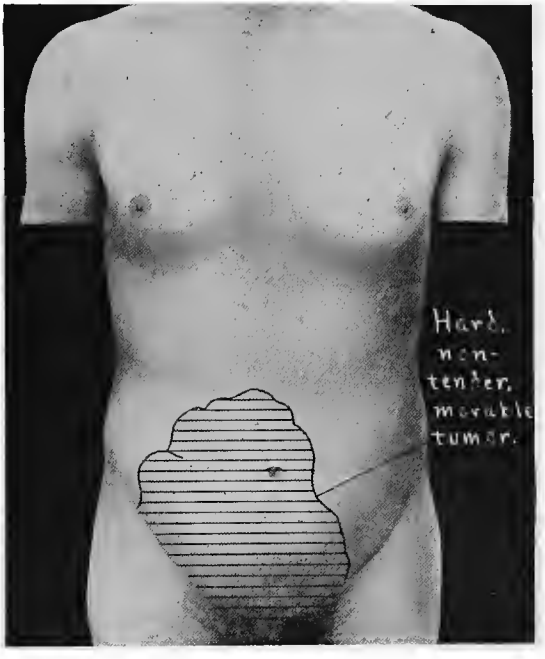

Fig. 123.—Abdominal mass felt in Case 140.

jaundice, taken in connection with the attacks of pain described in the history and relieved apparently by an injection of morphin, makes us pretty confident that we are dealing with an obstruction in the biliary tract. Such an obstruction is most often due to gall-stones, and this may be assumed to be the case in this patient, although cancer and other causes of obstruction cannot be positively excluded without operation. Such an operation should be advised without qualification.

Outcome.—December 6th the abdomen was opened. No stones found in the gall-bladder or ducts. There were firm adhesions from the fundus of the gall-bladder along the whole length of the cystic

and common ducts, attaching them to the transverse mesocolon. When these were detached it appeared that they had constricted the fundus of the gall-bladder.

A large fibroid tumor adherent to the omentum and the intestines was seen, but not disturbed. The patient made a good recovery and went home December 23d. November 3, 1912, she wrote, "I have gained steadily and am now in good health."

Remarks.—It is to be noticed that the surgeon, by a remarkable act of self-restraint, abstained from removing the fibroid tumor. Such an example is to be emulated.

Case 141

A housewife of thirty-two entered the hospital December 14, 1911, stating that since the first week in October she had been treated for "nervous dyspepsia." October 24th she ate steamed clams, and next day was seized with vomiting and diarrhea; also had three convulsions within twenty-four hours, each lasting three or four minutes, the patient becoming cyanotic during them, but recovering consciousness immediately. Her diarrhea soon ceased and she had no more convulsions, but for the next week the vomiting continued and was so obstinate that she was put on rectal feeding. The vomiting always came from two to twenty minutes after eating, consisting of sour, watery material in large amounts. Food rarely seen, blood never.

For the next week following that just described she retained food by mouth, then the vomiting recurred and has continued ever since. There is constant nausea and epigastric distress, but no pain. All sorts of medicines and foods have been given without relief, although her symptoms can be temporarily checked by suppositories of codein. She has lost 15 pounds in weight. Her appetite is always good.

Although the convulsions above described are something entirely new for her, she remembers having had, seven years ago, a "dizzy spell," which kept her in bed all day, and was accompanied by numbness of the tongue, mouth, and left arm. The dizziness has recurred twice lately, "but since the doctor took blood from her arm there has been no numbness in it."

The pupils are irregular, the left larger than the right. Both react well to distance, but not to light. There is a slight general glandular enlargement. Chest and abdomen negative. Slight left dorsal scoliosis. The right knee-jerk was present, the left not obtained; there was no swaying when she stood with the eyes closed and the feet together. Stomach-tube, passed before breakfast,

showed no food and no blood. Capacity of the organ, 1000 c.c. Contents of the fasting stomach showed free HCl 0.31 per cent. After a test-meal, free HCl 0.35 per cent.; total acidity, 0.41 per cent. No reaction to guaiac. Blood and urine normal. No fever in two weeks' observation, during which time she gained 4 pounds. The Wassermann reaction of the blood was negative; in the spinal fluid, December 19th, strongly positive. The *fundus oculi* was normal.

During the first four days in the ward she continued to be nauseated, the nausea bearing no relation to food, and being relieved by vomiting about once in eight hours. Atropin, $\frac{1}{150}$ grain, three times a day on December 17th, twice daily from the 18th to the 26th, seemed to control the vomiting better than any other drug. By the 23d she was eating well. While taking atropin she had night-sweats. Following the omission of this drug they ceased.

Discussion.—This is a fairly typical case of gastric manifestations in tabes dorsalis. The condition of the pupils, knee-jerks, and glands should have made clear the nature of her trouble, especially as she had previously had a convulsion and some symptoms suggesting a focal brain lesion. The positive Wassermann reaction in the spinal fluid put the case beyond any doubt, yet I have known patients presenting symptoms just as clearly tabetic as those just described who were, nevertheless, operated upon because a routine examination of the nervous system has not yet become part of the medical technic of the average surgeon. Failure to recognize tabes dorsalis is excusable when the pupils and knee-jerks are normal, but not in a case like this.

Outcome.—It was subsequently learned that her pupils had failed to react alike at any time in the last eight years. That one year ago she had sharp stabbing pains in her knees, lasting a few days and accompanied by marked hyperesthesia. She has been married for three years, has had no children, and no miscarriages. January 1, 1912, she left the hospital in good condition.

CHAPTER V

HEMATEMESIS

THERE are but two common causes of hematemesis, by which I mean the vomiting of pure blood in considerable quantity, an ounce or more. Those causes are *peptic ulcer* and *cirrhosis of the liver.* When an alcoholic vomits blood, it is often impossible to decide whether the hematemesis is due to cirrhosis or to *congestion of the stomach* itself, but this distinction is not of great practical importance.

At the end of any period of *violent retching,* however produced, a small amount of blood may be ejected without there being any organic disease responsible for it.

A third, but much less common, cause for hematemesis is that vaguely defined condition known as *splenic anemia,* and the later sequel of the same malady called *Banti's disease.*

Gastric cancer is rarely associated with the vomiting of pure blood in considerable amounts. The ulcerated surface of the cancer oozes continually, and the blood thus discharged is digested into a material resembling coffee-grounds. This may be ejected when the patient vomits. It must be remembered, however, that a vomiting of brownish fluid indistinguishable from that of gastric cancer is frequently seen after surgical operations upon the abdomen. It has no special significance, and, although it occurs in general and in local peritonitis, it is not at all peculiar to these conditions.

The differential diagnosis of the causes of hematemesis rests largely upon a good history of the case. Digestive disturbances of the type characteristic of ulcer are usually distinguished without much difficulty from those secondary to cirrhosis of the liver. In ulcer the physical examination is usually negative. In cirrhosis we may be able to make out changes in the liver or portal stasis. In splenic anemia the spleen is usually so much enlarged that anyone who knows enough to feel for it will recognize it.

Case 142

A plasterer of fifty-two entered the hospital June 27, 1904. According to the patient's account he has never been sick until within the past month, when he began to have dull, steady pain in the epigas-

Hematemesis



trium, not increased by food and not relieved by pressure. Yesterday, while in the elevated train, he suddenly vomited much dark-brown fluid. This was repeated several hours later, and this time the vomitus contained blood. Since then he has felt weak.

During the past month he has lost some weight, but previous to that time he positively denies any stomach trouble. His appetite is fair, bowels regular, sleeps good. He takes no alcohol.

Physical examination shows good nutrition. The heart's apex, of a heaving quality, is felt in the sixth space, $1\frac{1}{2}$ inches outside the nipple. There was no increase of dulness to the right. Its action is markedly irregular. There is a presystolic thrill and a presystolic murmur at the apex, transmitted to the axilla and back. At the third left costal cartilage there is a blowing systolic murmur. The pulmonic second sound is greater than the aortic second. The right pulse is larger than the left, artery walls easily palpable. The abdomen is somewhat retracted and rigid, but shows no masses or tenderness. Visceral examination is otherwise negative, as is the urine. The blood shows red cells, 1,728,000; white, 11,600; hemoglobin, 55 per cent.

On the morning of the 28th he had a copious gastric hemorrhage, about a quart in all. At 10 A. M. 6 ounces more were ejected. The blood-smear showed marked achromia, considerable deformities, some stippling, no blasts; differential count negative.

Discussion.—When a man of fifty-two vomits blood without any previous gastric symptoms, cirrhosis of the liver is the most probable cause. In this case there have been gastric symptoms, although moderate in degree and lasting only a month. There has been no alcoholic history, no splenic enlargement, or previous anemia. The amount of blood vomited is large and the resulting anemia extreme. With this picture, peptic ulcer of the stomach or duodenum is the most probable diagnosis, however little the physical examination may show. Gastric cancer may cause a similar hemorrhage, but this is very rare.

We have also the evidence of mitral stenosis, with a markedly enlarged heart, such as many clinicians are in the habit of supposing to be incompatible with mitral stenosis. I see, however, no considerable reason to doubt that the mitral valve is contracted. Has this any relation to the vomiting of blood? I see no reason to believe so. Blood coming from the lungs, as a result of pulmonary infarct in mitral stenosis, may be swallowed and then vomited, but not in any such amount as is here described and not without previous symptoms of pulmonary congestion.

The case illustrates one of the extraordinary varieties in the clinical picture of peptic ulcer, a disease which may produce symptoms lasting over twenty years or may produce no symptoms at all, and may be found at autopsy in a patient who dies of something else. Perforation and general peritonitis may be the first hint that any such disease exists, or, as in the present case, after a brief and mild dyspepsia we may have a large gastric hemorrhage.

I have no idea why the right pulse is larger than the left in this case. Such difference is of significance only when it is linked up with other signs pointing to an aortic aneurysm. As an isolated fact, it is fairly common in health and in a variety of diseases. So far as I know, it has no significance.

Outcome.—About 4 P. M. on the 28th the pulse became very poor, and during that night he vomited 8 ounces more of blood and died on the 29th. Autopsy showed ulcer of the stomach; erosion of a branch of a gastric artery; mitral stenosis; arteriosclerosis; hypertrophy and dilatation of the heart; obsolete tuberculosis of the left lung and of a bronchial lymph-gland.

Case 143

A housewife of thirty-five entered the hospital March 24, 1908. The patient has lost one brother by phthisis, otherwise her family history is excellent. Three years ago she was in St. Elizabeth's Hospital for ten weeks with stomach trouble. While there the uterus was cureted. Five years ago she weighed 144 pounds; now, 110 pounds.

In the intervening five years she has had attacks of vomiting at intervals not exceeding two weeks at a time. At first they came before the menstrual period; later, at other times. The vomitus contains food of the previous meals and some watery material. Pain in the epigastrium comes soon after eating. It is relieved by vomiting. Three years ago she vomited two cupfuls of dark blood. This was at the time she was in St. Elizabeth's Hospital. She was put on a milk diet. In November, 1907, five months ago, she again vomited blood, and this time had black stools and was in bed a week. She has never vomited blood again so far as she knows, but has continued to have epigastric pain and tenderness after eating. The last attack of vomiting was on March 15th. Appetite is poor, bowels costive; no other symptoms.

Physical examination showed fair nutrition, slight pallor, normal pupils, glands, and reflexes. The chest was negative, save for a soft,

systolic murmur, limited to the region of the cardiac apex. The abdomen was negative. Examination of the stomach with a tube showed no evidence of enlargement; negative guaiac test, free HCl, 0.14 per cent.; total acidity, 0.25 per cent. The stools were negative to guaiac at entrance. Upon a diet of eggs and milk the patient did fairly well. The gastric distress markedly diminished and there was no more blood, either by stomach or rectum. May 2d she left the hospital to continue her treatment at home.

August 3, 1908, she entered the second time, stating that two weeks after she left the hospital she had another attack of vomiting, and then was quite well until July 17th, when she had another attack at the time of her menstruation, lasting three days. The vomitus was dark brown in color, accompanied by epigastric pain.

This time the patient was well nourished, and showed no abnormality except for the red cells, which were now 3,050,000; white, 13,4000; hemoglobin, 45 per cent. Differential count showed 82 per cent. polynuclear cells, and in the stained smear there were two normoblasts, some deformities, and achromia of the red cells. The urine was negative. The entrance diagnosis at this time was gastric ulcer, but the morning after entrance a small, hard mass was felt in the epigastrium, just to the left of the median line. There was no food residue in the fasting stomach. On inflation its outlines were normal and the mass could not be felt. Guaiac test was positive in the contents after a test-meal; HCl 0.84 per cent. Stools negative to guaiac.

Discussion.—The patient has had vomiting spells, lasting two weeks or less, for the past five years and has lost 34 pounds in that period. The first hematemesis was three years ago; the second, five months ago. Presumably the association with the menstrual period, at the time of the first hematemesis, was a coincidence. Unlike most patients with gastric ulcer, she had a poor appetite. Nevertheless, the total impressions of her illness during her first stay in the hospital is that of a peptic ulcer. She improved as such cases do, and the condition of her stomach contents was fairly typical of that disease, although the guaiac test was negative.

When she entered the hospital the second time, with a well-marked anemia and a palpable mass in the epigastrium, the question at once arose, Is this lump a perigastric exudate representing a local peritonitis about the site of an ulcer? Such an exudate may feel as hard as any cancer. Against ulcer, however, is the fact of anemia without any recurrence of the hematemesis. It is quite possible, nevertheless,

that there may have been bleeding without the patient's knowledge and without vomiting. On the whole, the evidence for ulcer and that for cancer is very evenly balanced, and it is difficult to make a choice. The rarity of perigastric exudates producing epigastric tumor inclines me, on the whole, toward the diagnosis of cancer.

Outcome.—On the 14th of August the hemoglobin had risen to 50 per cent. and the abdomen was opened. The posterior wall of the stomach contained a firm, hard mass, the size of an almond, with

Fig. 124.—Keloid-like masses in old *lineæ albicantes* (Case 143).

radiating branches extending over the whole posterior side of the stomach, especially at the pyloric end. The omentum was filled with small, hard nodules. An anterior gastro-enterostomy was done, after which the patient did well and left the hospital on the 17th of September. On the 18th of January, 1909, she came back again, stating that since the first of October, 1908, she has had a sense of pressure on the bladder with frequent micturition. This was soon followed by enlargement of the abdomen, which has gone on up to the

present time. The stomach, on the whole, has done very well, except for occasional attacks of nausea or vomiting. Hemoglobin at this time was 75 per cent. Urine negative. The lineæ albicantes below the navel have developed into branching ridges which suggest keloid (Fig. 124).

The lower half of the abdomen is occupied by an irregular, hard, insensitive mass, the size of a football, reaching as high as the navel and extending into the iliac fossæ, with slight depression in the median line. There are no sounds over it on auscultation. No blueness of the vulva. Vaginal examination shows just behind the pubes a mass, which is interpreted as the fundus of the uterus. Pressure over the abdominal tumor causes movement on the part of the cervix. On the 25th the abdomen was opened again and found to contain several quarts of fluid and two tumors, each the size of a large grapefruit, nodular, grayish-white in color, and apparently arising from the ovaries. These were removed and showed the microscopic structure of fibroma, with small cyst-like cavities. The patient left the hospital on the 23d of February in good condition, but died at the Vincent Hospital June 11, 1909. After May 20th she was kept under opiates.

Remarks.—The mass felt in the lower abdomen in January, 1909, was at first interpreted as a metastasis from the stomach. Later the question of pregnancy arose, as the tumor seemed obviously connected with the cervix uteri. The final interpretation given to this mass was that it represented a uterine fibroid. No one suspected ovarian tumor.

The condition of the abdominal wall is fairly well suggested in the accompanying photograph (Fig. 124). Those curious scars, ordinarily known as *lineæ albicantes*, had, in this case, become hypertrophied like keloid and then edematous and at times inflamed. They stood up from the surrounding tissues $\frac{1}{4}$ inch or more, and were as thick as a finger.

Familiar as are *lineæ albicantes* upon the abdomen of women who have borne children, I do not think their nature is yet well understood. One sees them not only in this situation, but over the deltoids, along the lower ribs in the axillæ, and in many other parts of the body, under conditions which makes their occurrence distinctly mysterious. They seem to have something to do with loss of weight, yet in the abdomen we have usually explained them as a result of stretching of the skin and splitting of its superficial layers. This explanation, however, will not hold, when one sees them about the

shoulders and back during the convalescence of a case of scarlet fever or after other infectious diseases. Under such conditions there can have been no stretching of the skin, as neither emaciation, obesity, nor other cause for pressure and stretching has been present.

It is not always realized that these lines, which in their later stages are white, are in their earlier stages bright red and suggest inflammation or, at least, hyperemia. As far as I know, they have no useful lessons to teach us, so far as diagnosis is concerned, but it is important to be familiar with the variety of appearance which they may present, otherwise one may be unduly puzzled when discovering them in a case which seems in other respects clear.

Case 144

An unoccupied man of thirty-six entered the hospital January 29, 1909, with a diagnosis of "gastric ulcer." One month ago he began to vomit immediately after eating. Ice-cream and raw oysters were the only foods that he could take. For the past two weeks he has vomited blood, dark and clotted, as much as a cupful at a time, both after eating and between meals. The blood is sometimes clear, sometimes mixed with food.

Physical examination showed loss of weight, marked pallor, normal pupils, glands, and reflexes. Chest negative, save for a soft systolic souffle at the apex, not transmitted. In the epigastrium and right upper quadrant there was tenderness and muscular spasm; otherwise physical examination was negative. Red cells, 800,000; white cells, 21,000; hemoglobin, 20 per cent. Differential count normal. The stained smear showed marked achromia, slight deformities of the cells; otherwise normal. Urine normal. He was given at entrance horse serum, 20 c.c., subcutaneously. By the 5th of February the red cells had risen to 2,400,000, the hemoglobin to 40 per cent. On gastric ulcer diet he had had no bleeding.

By the 10th of February he could eat a full diet without any trouble, and the diagnosis of gastric ulcer would undoubtedly have been made but for the following additional facts, which were added to the history at this time. He first entered the hospital September 21, 1899, when it was learned that there was a good deal of mental deficiency on the mother's side of the house. Some of her family were "queer and silly." The boy had convulsions for five days after his birth. He was born jaundiced. This lasted two weeks. He was, nevertheless, a healthy baby, and had no more convulsions until he was five. Ever since then he has had them frequently, sometimes

twice a week, sometimes skipping several weeks. They are preceded by a typical aura and cry. The head always turns to the right, and he bites his tongue unless his jaws are kept separated. After two or three minutes he awakes from his coma with severe headache. Under treatment he once went two years without convulsions, but when medicine was stopped the convulsions returned. He often has spells of what he calls "smothering," when his lips get blue and he cannot speak for a minute or two.

He has always been subject to bleeding on slight provocation since he was six years old, when he cut his face, and the bleeding lasted five weeks; it was finally stopped by cautery. In 1895 two teeth were pulled to stop his biting his tongue and the bleeding lasted four weeks. Four years ago he had "some bones taken out of his chest," and he raised a great deal of blood at that time. On one occasion a puncture of the ear, made for blood examination, bled for three days.

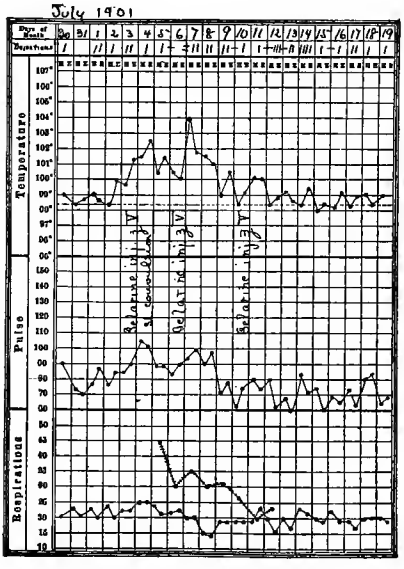

Fig. 125.—Chart of Case 144.

Eight years ago, July 30, 1901, he was recommended to the surgical wards with a question of renal stone or tuberculosis, because for a week his urine had contained much blood. He had also had much pain and burning sensation in the back and in the genitals; also pain in the perineum when sitting He had an epileptic fit in the ward, and was soon discharged to the medical service. The urine then contained a large amount of blood, but was not otherwise remarkable. 150 c.c. of 2 per cent. gelatin, in sterile salt solution, were injected on the 3d of August and followed by a rise of temperature, as shown in Fig. 125. There was considerable pain and tenderness at the site of injection, which was repeated on the 6th and on the 10th. On the 5th of August he had considerable abdominal pain and passed bloody stools.

He had several convulsions during this stay in the ward, but his urine became free from blood on the 12th of August and remained so. In the absence of any other special symptoms he was discharged on

the 21st, and was not seen again until his entrance ten years later in 1909, as described above.

The patient left the hospital on the 11th of January, 1909, and re-entered on the 25th of February, stating that five days previously hematemesis recurred and has been frequent ever since. Two days ago, after a violent epileptic attack, he complained of occipital headache, with coldness and chilliness of the left arm. He has slept but little, he says, for some weeks, and has had much heartburn. At entrance he was very restless, asking for hot whisky and mother. His head is described by the house officer as faun-like, with pointed ears, narrow forehead, eyes small and close together. No history of bleeding by any of his ancestors was obtained.

Physical examination was, as before, practically negative. Red cells, 1,056,000; white, 9200; hemoglobin, 20 per cent.; polynuclear cells, 79 per cent. The red cells showed marked deformities in size and shape; no other abnormality. The patient continued to vomit blood in spite of morphin and horse serum. His pulse grew steadily weaker, and he died on the 26th of February, without any other symptoms.

Discussion.—We had no doubt of the diagnosis of peptic ulcer when we made our earliest record of this patient's case. Later, when we learned that he had been a bleeder, we naturally shifted our diagnosis and considered the gastric bleeding as part of the hemophiliac diathesis. It appeared that he had had hemorrhage from the lungs, bowel, and kidney, as well as subcutaneously.

His convulsions were attributed to epilepsy, and we supposed them to be without any connection with his other symptoms. His unsatisfactory inheritance made the epilepsy easily explicable.

Outcome.—Autopsy showed chronic interstitial hepatitis with focal necrosis; hyperplasia of the spleen; fatty degeneration of the myocardium; chronic pericarditis; hypertrophy and dilatation of the heart; obsolete tuberculosis of a bronchial lymphatic gland; chronic pleuritis; internal hydrocephalus of the left cerebral hemisphere, with marked atrophy of the surrounding convolutions.

Remarks.—After the autopsy we were not quite certain how far our previous diagnosis of hemophilia was a mistake. Gastric bleeding in a patient with interstitial hepatitis is naturally attributable to the latter disease. Nevertheless, this patient had had blood in his urine and from other sites not to be connected with any disease of the liver. Since no definite point of hemorrhage was noted in the

autopsy record, there is no proof, so far as I see, that his cirrhosis was the cause of his bleeding from the stomach. Such connection, however, cannot be excluded.

It is quite possible that his hepatitis may have been syphilitic, although no Wassermann reaction was done.

The diagnosis of epilepsy was certainly wrong, as one can only use that term to denote cases in which no organic lesions exist. As to the origin of his hydrocephalus, I have nothing to suggest.

Case 145

A druggist of fifty-four entered the hospital January 20, 1910. The patient's father died of cancer of the face at sixty-one; otherwise his family history is good, and he has always been well. For years he took ten to fifteen glasses of beer or whisky daily, now four or five whiskies daily. On this diet he has seemed to thrive.

Yesterday at 7 A. M., after a coughing spell, he began to raise blood, at first in 2-ounce quantities. At 2 P. M. he vomited 1 pint, at 6 P. M. ½ pint more, and soon after this he passed two dark and tarry stools. At 3 A. M. to-day he vomited ½ pint more, and at noon to-day again ½ pint and had two more tarry movements. In all, he thinks he has raised 1 quart and 18 ounces.

Physical examination shows obesity, pallor, normal pupils, glands, and reflexes. The heart's apex is 1 cm. outside the nipple line. Slight systolic murmur along the left sternal border. Systolic blood-pressure, 125. The right pulse is greater than the left, both slightly irregular. The liver dulness extends from the sixth rib, mammary line, to a point 6 cm. below the ribs, where a rounded edge is felt.

Discussion.—Such a hemorrhage occurring, as we say, out of a clear sky, in an alcoholic, with a palpable liver, can scarcely be attributed to a cause other than interstitial hepatitis. We have no reason to be surprised that the patient has no portal stasis, that is, none of the ordinary evidences of that condition. Whether the hemorrhage is due to passive congestion of the gastric mucosa or to dilatation of the peri-esophageal plexus of veins, we cannot say. The latter is the more common.

Outcome.—On the evening of the 22d he suddenly became delirious and tried to get out of bed, complaining of feeling queer. His pulse soon became slow, weak, respirations labored, and the picture, save for the pulse, was one of internal hemorrhage. In two hours he died.

Remarks.—Such a hemorrhage is rarely fatal. As a rule, the patient lives on for months, often for many years, and may die of some other disease.

Case 146

An Irish cook of twenty-two entered the hospital June 18, 1910. The patient has a good family history and past history, but has always had much pain at menstruation, especially during the last year, when the period has been accompanied by nausea and vomiting for one or two days. Of late she vomits first food, then bile, and finally dark clots of blood at the end of half an hour of steady retching. She is much exhausted by these attacks and sweats profusely. Between periods she has no symptoms, and can eat anything without distress. She has no loss of weight, good appetite, and has worked steadily.

Physical examination was wholly negative, including the blood, urine, and temperature. Stools were negative to guaiac. The stomach-tube showed no contents in the fasting stomach. A test-meal was vomited after thirty-five minutes, the vomitus containing no free HCl and no blood. A retroverted uterus was replaced under ether.

Discussion.—It is notable that the patient has no symptoms at all between the attacks of vomiting; that is, between the menstrual periods. Were there any organic lesion in the stomach it would be almost certain to show itself between times. It might well be aggravated during menstruation, but would not be confined to that time. The negative results of physical examination go to strengthen the assumption of a normal stomach.

Can we attribute the vomiting to retroversion of the uterus? I do not think so. There seems to be no evidence to show that retroversion, *per se*, can produce this or any other symptoms. The chief lesson of the case seems to me to be that violent retching from any cause—for example, from sea-sickness—may produce hematemesis.

Outcome.—The patient left the hospital on the 26th in good condition.

Case 147

A ladderman in a fire department, thirty-three years of age, entered the hospital April 25, 1910. The patient lost one sister, one aunt, and one uncle of tuberculosis. One brother died of drink; otherwise the family history is good. Except for two attacks of gonorrhea, twelve and nine years ago, he has always been well until the present illness.

Eighteen months ago he had a feeling of distress and heaviness in his stomach, as if something was rolling about there. Vomiting relieved this for a time, and now he makes himself vomit whenever he feels any such trouble. The first attack lasted about three weeks and was accompanied by lack of appetite. Since then he has had about a dozen similar attacks, lasting from three days to three weeks. Between attacks he feels perfectly well and eats all foods very heartily. He thinks the attacks are brought on by eating too much, or by eating something which disagrees with him, and that they are usually preceded by more constipation than is his usual habit. He never has any severe pain in the attacks, only a dull ache at the pit of the stomach and in the left hypochondrium. Sometimes he vomits unchanged food eaten twelve hours before. Three months ago, for the first time, he raised a large amount of bright blood. The last attack, seven weeks ago, began after a drinking bout.

In eighteen months he has lost 40 pounds. Following each attack he has profuse cold sweats at night. For two weeks he has had a hard dry cough with slight expectoration, frequently blood-tinged. During attacks he is very nervous and passes urine three or four times each night.

Physical examination showed good nutrition despite evident loss of weight. His skin became cyanotic when he was asleep, otherwise it was of good color. His pupils were small, circular, equal, and reacted very slightly to light. Glands and reflexes were normal. Heart negative. Lungs negative, save for a few fine râles and diminished breathing at the bottom of the right axilla. The stools were positive to guaiac only on the 27th of April. On the other days of his two and a half weeks' stay they were negative. He had no fever during this period, and his blood and urine were negative. The sputum was twice examined for tubercle bacilli with negative results. Wassermann reaction negative. On gastric ulcer diet he made an uninterrupted recovery and left the hospital on the 12th of May.

The patient re-entered the hospital September 22d with a diagnosis made by Dr. H. F. Hewes of gastric ulcer. Since leaving the hospital he had worked only three weeks, vomited much, and been treated mostly by gastric lavage. At this time he admitted that he had had slight pains, quickly darting into his calves and out again, and that in the previous winter and for the past two or three weeks he has had a good deal of pain below his left shoulder-blade, mostly on moving his arms. For the past year he has had slight difficulty in starting micturition. Knee-jerks and Achilles' jerks were active,

the right greater than the left. At this time the right pupil was larger than the left, otherwise they were as before. The stools were four times negative to guaiac; the sputa three times negative to tubercle bacilli. He showed no temperature reaction after 7 mg. of old tuberculin.

Discussion.—Despite the family history of tuberculosis, the two weeks of dry cough with blood-tinged sputa, the loss of weight, and the presence of night-sweats, we have no good reason to attribute this patient's symptoms to tuberculosis. Night-sweats may result from any disease which produces exhaustion, with or without fever. The popular belief that night-sweats mean phthisis is justified only to the extent that phthisis is in all probability the commonest cause of such sweats. Nevertheless, there are many others.

The salient feature of the case seems to be the occurrence of a dozen or more attacks, lasting from three to twenty-one days, characterized by gastric distress and vomiting. Although these attacks are by the patient attributed to bad diet or to constipation, there seems no good reason to agree with him on this point. There are some doubtful physical signs in the lungs, but it seems very improbable that these signs are the cause of his troubles or have anything particular to do with them, for the gastric symptoms are paroxysmal with long intervals of good health between, and stomach symptoms of this type are rarely, if ever, produced by lung trouble.

The condition of his pupils should lead us to make careful search for evidences of tabes, even though the knee-jerks are normal and the Wassermann reaction negative in the circulating blood. In such a patient we should always examine the spinal fluid and look carefully for patches of anesthesia or hyperesthesia.

At the time of his second entrance the evidence pointing to tabes was much clearer, and we need have no considerable doubt of that diagnosis.

Outcome.—Dr. E. W. Taylor pronounced the diagnosis tabes. The patient sweat profusely at night during most of his week in the hospital. Systolic blood-pressure at entrance was 160. He ate very well during the whole of his stay this time. His condition was explained to him when he left the hospital on the 1st of October.

The patient was seen in January, 1913, and stated that his vomiting had now ceased, as it had been cured by a Chinese doctor. The treatment given him at the Massachusetts General did not help him at all, and after leaving the hospital he could scarcely walk and did no work for six months. Since that time, however, he has been

able to work, and his appetite, bowels, and sleep are now normal. Off and on he has attacks of frequent micturition, and about every five or six weeks he has a pain over his right kidney and his urine looks like pea soup. These symptoms, however, do not disable him.

Case 148

A Swedish dressmaker of thirty entered the hospital September 29, 1910. The patient has had slight heartburn and epigastric pain for a few days at a time, once or twice a year, for the past ten years. She has thought nothing of it, and has always been very well and strong up to a year ago, when she began to have almost daily tenderness and burning pain in the epigastrium, the latter coming from one-half to one hour after meals and relieved by soda. She has vomited two or three times a week, sometimes a quart at a time, but has never noticed in the vomited matter food eaten the day before. Two days ago, for the first time, she vomited blood, small amounts frequently, and yesterday she vomited half a basinful. This morning she brought up the same amount. She has worked continuously until this bleeding began and has lost no weight. Immediately on entrance to the hospital she vomited 10 or 12 ounces more of blood. She was given $\frac{1}{6}$ grain of morphin, subcutaneously, repeated every four hours when necessary, to control vomiting. All food was omitted, and she was given 6 ounces of salt solution every four hours by rectum.

Physical examination was wholly negative, save for a soft systolic murmur, loudest at the apex. The stools showed a strong reaction for guaiac every day until October 5th, after that none. The urine was negative. The red corpuscles at entrance were just below 4,000,000, and in the course of the next two weeks sagged nearly to 3,000,000. The hemoglobin remained all the time about 70 per cent. The leukocytes at entrance numbered 15,000, with 80 per cent. of polynuclears. The appearance of the red corpuscles at entrance was wholly normal; no achromia. She had no fever in three weeks' observation. Blood-pressure, 105 mm. Hg.

Discussion.—Any patient who has had stomach trouble for ten years, off and on, and at the end of that time brings up from the stomach a large amount of blood and shows a well-marked anemia thereafter is rightly assumed to have a peptic ulcer until evidence is adduced to the contrary. Cirrhosis of the liver is always a possible source of mistake in such a case, but in a woman of this age, who denies all contact with alcoholic liquor, the chance of mistake is not very great. The rarer and more serious causes of hematemesis are

all of them highly improbable in a patient who is at work when the bleeding begins, and seems, in most respects, healthy on physical examination.

It may here be noted that the physical examination of the abdomen in cases of peptic ulcer is almost invariably negative. The only objective evidence we have is the evidence of hemorrhage and that furnished in some cases by bismuth *x*-ray examination or by the string test. It should never surprise us to find the abdomen soft and free from tenderness, as in perfect health.

Outcome.—On the 3d of October crackers and milk in small amounts were begun, and thereafter the amount of food was steadily increased. She had no symptoms or complaints, and October 20th seemed entirely well and left the hospital. Three years later she reported that she had no further trouble and was perfectly well. Her appearance confirmed this opinion.

Case 149

A housewife of twenty-five entered the hospital February 16, 1911. The patient's family history is negative. Her general health has been always poor. Previous to the age of twenty-one she had a great deal of diarrhea.

For the past three weeks has had a great deal of indigestion and heartburn, with considerable hematemesis, the dates and amounts not being clear. About a week ago she began to vomit three or four times a day for the relief of epigastric distress. Yesterday she suddenly vomited a quart of pure blood, followed by small amounts at intervals since. She worked until two days ago.

While this history was being taken she raised 30 c.c. of bright blood. On the afternoon of the 16th she also passed much blood by rectum; her pulse rose to 156. She was kept under morphin and the bleeding ceased until the 19th, when about 160 c.c. were raised and a few clots passed by rectum. Tarry stools were passed on the 20th and 21st. She was given salt solution under the skin and seepage, 15 per cent. glucose in normal salt solution, 500 c.c. daily. On the 22d she was fed small quantities of milk and lime-water and did well thereafter. No cause was found for the continued fever.

On the first of March the nurses suddenly noticed that she had a fixed stare and did not seem to breathe. The pulse was very small, but not rapid. A few minutes later the left arm and leg began to twitch, and this continued several minutes. Five minutes later she was crying, semirational, objecting to having the pupils tested,

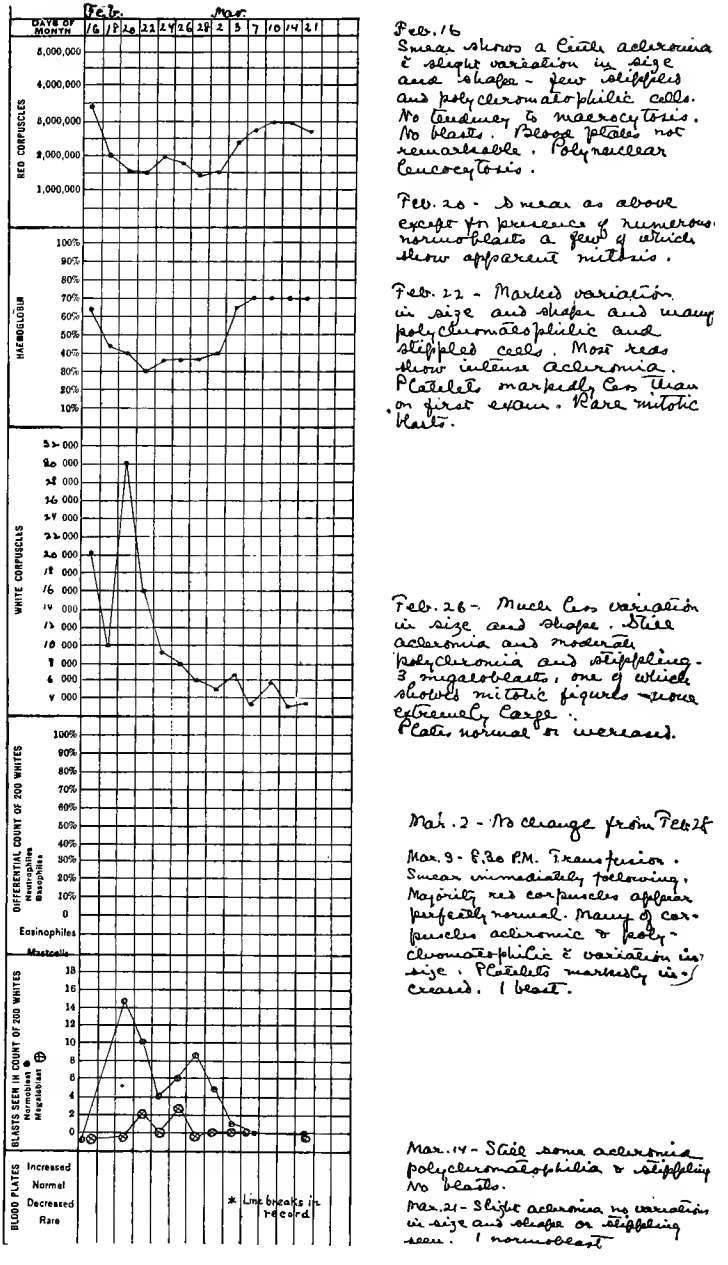
Feb.
Mar.
DAYS OF MONTH
16 18 20 22 24 26 28 2 5 7 10 14 21
RED CORPUSCLES
HAEMOGLOBIN
WHITE CORPUSCLES
DIFFERENTIAL COUNT OF 200 WHITES
Neutrophiles
Basophiles
Eosinophiles
Mastcells
BLASTS SEEN IN COUNT OF 200 WHITES
Normoblast
Megaloblast
BLOOD PLATES
Increased
Normal
Decreased
Rare
* Link breaks in record.
Feb. 16
Smear shows a little achromia & slight variation in size and shape - few stippled and polychromatophilic cells. No tendency to macrocytosis. No blasts. Blood plates not remarkable. Polynuclear Leucocytosis.
Feb. 20 - Smear as above except for presence of numerous normoblasts a few of which show apparent mitosis.
Feb. 22 - Marked variation in size and shape and many polychromatophilic and stippled cells. Most reds show intense achromia. Platelets markedly less than on first exam. Rare mitotic blasts.
Feb. 26 - Much less variation in size and shape. Still achromia and moderate polychromia and stippling. 3 megaloblasts, one of which shows mitotic figures - none extremely large. Plates normal or increased.
Mar. 2 - No change from Feb 26
Mar. 9 - 8.30 P.M. Transfusion. Smear immediately following. Majority red corpuscles appear perfectly normal. Many of corpuscles achromic & polychromatophilic & variation in size. Platelets markedly increased. 1 blast.
Mar. 14 - Still some achromia polychromatophilia & stippling No blasts.
Mar. 21 - Slight achromia no variation in size and shape or stippling seen. 1 normoblast

Fig. 126.—Blood changes in Case 149.

but the left was considerably larger than the right. She complained of a very queer feeling in her left hand, and for a minute or two ground

her teeth furiously. Within an hour she seemed as well as usual. At that time, March 1st, the first physical examination was done and showed nothing remarkable except a much enlarged spleen, reaching 7 cm. below the ribs. Splenic dulness 18 cm. in length. On the 2d of March there was ankle-clonus on both sides, especially on the left, and her general restlessness and poor condition had increased. The course of her blood chart is shown in Fig. 126. The stained smear showed nothing remarkable except achromia and stippling. The red cells were not enlarged. At times normoblasts were numerous, some of them showing mitosis. The fundus oculi was negative. Urine negative. Temperature as in Fig. 127. Systolic blood-pressure, 95 mm. Hg.

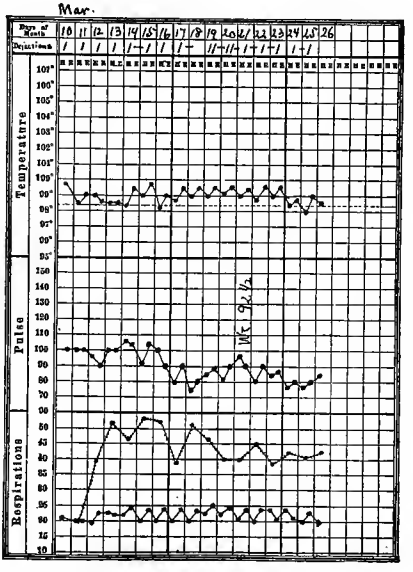

Fig. 127.—Chart of Case 149.

On the 3d of March she was transfused, the blood being allowed to flow twenty-five minutes until the donor became pale and restless, with sighing respiration. The patient was intensely pale at the beginning of the operation, but after it her color had returned and her respiration was deep and regular. She slept well the next night and was very hungry. After that she very rapidly improved. Before operation she was practically moribund, gasping for breath, and very pale.

Discussion.—Association of splenic enlargement with the vomiting of blood has been recognized, since Osler's classical paper,[1] to point with a considerable certainty to the diagnosis of splenic anemia. In most cases the hemorrhage is due to mechanical causes related to the splenic enlargement and to obstruction of venous return, yet the bleeding may result from any of the causes ordinarily associated with cirrhotic liver. That the patient has had three weeks of dyspepsia, and has suffered a good deal in her earlier years from diarrhea, does not invalidate our theory of splenic anemia nor does the convulsion of March 1st upset the diagnosis. Such a convulsion may well be associated with the patient's anemia.

[1] Transactions of the Association of American Physicians, 1902.

The best that can be said against the diagnosis of splenic anemia is that that disease itself represents a very loose and unsatisfactory grouping of symptoms. Of its pathogenesis we know little or nothing. We are not even certain that there is any such entity. Many of the cases reported under this title are doubtless due to malaria, syphilis, or to the ordinary type of hepatic cirrhosis. I say to the ordinary type, since it is generally admitted that what we call splenic anemia may be only the first stages of a disease which in its later course is indistinguishable from liver cirrhosis. To this sequence of events—primary splenic enlargement, with anemia and subsequent development of interstitial hepatitis—the term "Banti's disease" is now pretty firmly attached, but there is much that is unsatisfactory in our knowledge of this disease, as well as in the so-called splenic anemia.

The life-saving efficiency of transfusion, as recently reintroduced into medicine through the technical improvements of George W. Crile, has not as yet been sufficiently realized by the medical profession. Patients die every week, I believe, whose lives might have been saved by transfusion of blood. Unfortunately, even in communities where the importance of the operation is recognized, there are few surgeons who know enough to do it. The technic of the operation has recently been so much simplified that it is a disgrace to our profession that any patient should be without the benefits to be derived from transfusion. The operation is indicated in cases of posthemorrhagic anemia, when the patient fails to show a prompt or satisfactory impetus toward regeneration of blood. It is also indicated in other forms of secondary anemia, where an operation is desirable, but is postponed or frowned upon because of the patient's anemia. In such cases a bad surgical risk may be turned into a good one by transfusion properly performed.

A third and less common indication for transfusion is uncontrollable oozing from cutaneous mucous or serous surfaces.

Outcome.—She returned to the ward in excellent condition, and after two and a half weeks of uneventful convalescence was allowed to go home. The course of her blood changes during this time is seen in Fig. 126. It was noticeable that she ran a slight temperature most of the time, varying between 99° and 99.6° F. during her convalescence.

CHAPTER VI

GLANDS

ENLARGED GLANDS AND WHAT SIMULATES THEM

NOT all palpable glands are enlarged. The normal wear and tear of existence in civilized communities produces enough infection or subinfection to bring about some enlargement of the glands without our being able to say that any disease has afflicted the individual or his glands. It is a mistake, therefore, to suppose or to state that glands are enlarged merely because we feel them, and it means nothing to record in our case histories that they are palpable, unless in some very unusual situation. The best way is to state approximately how large the glands are. In general, it may be said that a considerable proportion of all adults living in cities have in their groins one or more glands twice the size of a pea. In the axillæ glands of this size are less common, and a considerable number of healthy persons have none that one can feel at all in that situation. The same is true of the neck and epitrochlear regions, yet it must be recognized that palpable epitrochlear glands, while less common than palpable inguinal glands, are nevertheless not at all rare in perfectly healthy persons, and should not be made the ground of any suspicion of any syphilitic infection, as has been the custom in certain clinics here and in Europe.

It is a very familiar fact that enlargement of the inguinal glands accompanies infection of the leg, thigh, or genital tract; that enlargement of the axillary glands follows infection of the arm and of certain parts of the chest wall; that enlargement of the glands of the neck is associated with infection of the mouth, throat, face, or scalp.

Beyond this, the attempt is often made to associate certain groups of cervical glands with certain drainage areas, but in practice there is seldom any such actual delineation. The drainage areas surely must cross or anastomose. It is true, nevertheless, that enlargement of the posterior cervical glands behind the sternomastoid is very frequently associated with syphilis and with German measles.

So much is relatively clear. Much less clean cut is the association of certain pelvic and abdominal growths with enlargement of the inguinal glands and of certain thoracic growths with enlargement of

the axillary or cervical glands. In many cases there is no such association. The pelvic and abdominal growths have their glandular metastases in the mesentery and other prevertebral glands, while infections and tumors of the thoracic cavity affect the branchial and tracheal lymphatics. This, I say, is the rule, and, therefore, a considerable portion of all the glandular enlargement altogether escapes our notice on physical examination. We can rarely reach the deep abdominal glands either by palpation or in any other way, and even by the aid of *x*-ray and of spinal percussion we are far from certainty in the diagnosis of enlarged branchial or tracheal glands; yet these sites of adenoid tissue must always be present in the physician's mind. He must never think of the neck, axillæ, and groins as *the* normal sites of possible glandular enlargement, but only as the more obvious and visible sites.

Cancer of the stomach, tuberculous peritonitis, the gall-bladder infections, peptic ulcer of the stomach or duodenum, and most of the abdominal lesions which present the greatest difficulties in diagnosis do not produce, as a rule, any glandular enlargement which we can recognize on physical examination. In a very small percentage of cases, gastric cancer and some other abdominal neoplasms are associated with a glandular metastasis above one clavicle, the so-called *sentinel gland*. Such a gland should always be felt for when we are in doubt about a diagnosis of malignant disease in the abdomen, and if any such gland is present it should be excised and examined microscopically for evidence of malignant disease.

Cervical or axillary metastases are seen with considerable frequency in cancer of the lung and pleura and in lymphoblastoma of the mediastinal glands, yet this association is mysterious, vague, fickle, and unreliable. We do not understand why it occurs as often and no oftener.

Another point hitherto not clearly explained is the occasional extension of a streptococcic sepsis, starting in a tonsil, not only to the cervical glands, but to the axillary glands as well. I have several times seen axillary suppuration containing a pure culture of streptococci in association with a similar cervical adenitis, apparently originating in a streptococcic sore throat of the mild epidemic type. This brings me to another problem regarding the glandular hypertrophies and inflammations of the tonsillar ring. It is ordinarily assumed that when a tonsillar inflammation arises it has been acquired through some food that has passed over the tonsil or through the inspired air and its contact with the tonsil. In other words, it is through the faucial

GLANDS[1]

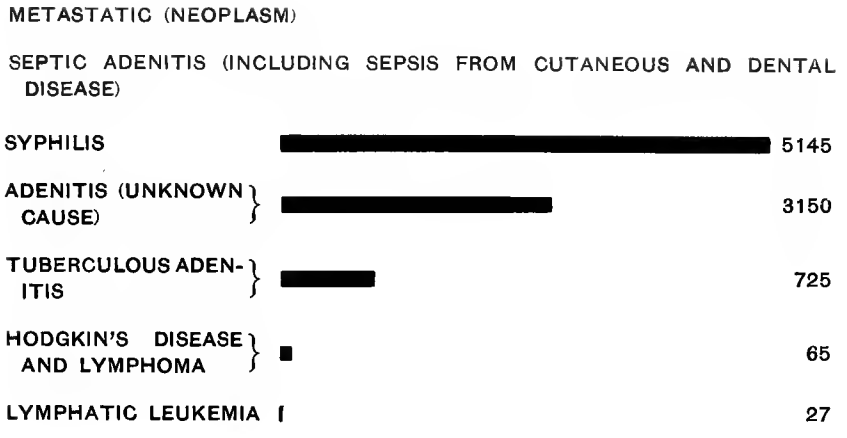

[1] These figures are taken from the records of the Out-patient Department and include no ward cases.

surface of the tonsil that that gland becomes inflamed. This assumption is very natural, but not necessary. It is natural because the tonsillar crypts open into the fauces and because foci of pus or bacterial growth are usually to be found in these crypts. One naturally assumes, therefore, that infection has gone into the crypt through the mouth of the crypt. But this is obviously a superficial view. Tonsillar inflammation is by no means confined to the crypts and often has no obvious connection with them. The so-called quinsy sore throat or peritonsillar abscess has its origin very deep in the tissues, far from their faucial surface. How do we know that the infection does not come from within rather than from without? Such a question has often occurred to me when I have observed in a child, first, endocarditis or arthritis, and later a tonsillitis. Such a sequence suggests that an infection widely generalized within the body has been carried first to the heart or to the joints and later to the tonsillar tissues. Have we any good reason to believe that the tonsils are not often infected in this way, from within rather than from without? I do not see that we have. No one supposes, I take it, that similar glandular enlargements of the intestine (Peyer's patches and solitary follicles) are produced through the entrance of typhoid bacilli from the interior of the intestine. It is generally assumed that the typhoid bacilli, which we can usually isolate from the circulating blood, are carried by the blood-stream and by the lymphatics to all parts of the body and appear in the lymph-glands of the intestine from within rather than from without. Why should not the same be true of tonsillar infection?

In addition to the foci of lymphadenoid tissue which have been mentioned in the foregoing paragraphs, there are, in all probability, minute collections of similar tissue scattered in all parts of the body, including the serous surfaces and subcutaneous tissues. We get no clinical evidence of the existence of these minute foci, except in lymphoid leukemia and multiple lymphoblastoma. In these conditions the minute foci just referred to become enormously enlarged, and the subcutaneous group show beneath the skin as lumps of various sizes scattered diffusely over the body surface. Similar nodules appear in the internal ear, producing deafness; in the orbit, displacing the eyeball, and in many other less conspicuous situations. Under such conditions the body seems to be riddled or honeycombed with lymphadenoid tissue, of whose presence we are not ordinarily aware.

CLINICAL GROUPINGS

Glandular enlargements in the neck, axillæ, and groins are ordinarily of four types, so far as they can be studied by the ordinary methods of physical examination; that is, without the excision of a gland:

(1) Simple glandular hypertrophy.

(2) Glandular hypertrophy with inflammation and with or without suppuration.

(3) Glandular enlargement with caseation.

(4) Glandular enlargements of the hard, nodular type.

The enlargements of the first type are seen in syphilis, in lymphoblastoma, with or without leukemia, and in many cases without known cause.

The septic type of adenitis is commonest in connection with tonsillitis and other inflammations of the mouth and throat, also in septic processes of an arm or one or another extremity, and in gonorrhea. A peculiar type belonging in this group is the idiopathic axillary abscesses (non-tuberculous), a suppuration which arises without known cause, deep in the axillary tissues, pushes forward to the superimposed axillary glands, so that the pus concealed beneath them is often not suspected.

Caseous glands are generally associated with tuberculosis.

The hard, nodular glands are usually neoplastic and may sometimes contain cartilaginous or even bony substances.

But, although these clinical groups guide us in many cases to a sufficiently accurate and prompt diagnosis, there are many other cases in which we are wholly at a loss to decide what type of adenitis is present, unless a gland is excised and examined histologically. This should be done much more frequently than it is. As a rule, some one of the enlarged glands or some portion of one is placed so superficially that it can be taken out under local anesthesia without any considerable pain or hemorrhage.

The other characteristics of the glands are less valuable in differential diagnosis. It usually helps us very little to know whether the glands are discrete or matted together, and almost any of the four types above mentioned may be either hard or soft, either attached to the skin or freely movable beneath it. Nevertheless, it is true that the septic and tuberculous types are more likely to involve the skin than either of the others. Tenderness and redness of the overlying skin are rarely seen except in the inflammatory type of adenitis, but occasionally an inflammatory reaction occurs about a lymphoblastoma.

NOMENCLATURE OF GLANDULAR TUMORS

The weight of opinion among competent pathologists inclines more and more toward a simplification and unification of the terms ordinarily applied to the new growths involving lymph-glands. The terms lymphoma, malignant lymphoma, lymphosarcoma, small round-cell sarcoma, pseudoleukemia, lymphocytoma, leukemic infiltration, leukosarcoma, and others appear to represent different varieties of the same pathologic lesion. The growths of the firmer and more chronic type are apt to be called Hodgkin's disease, especially if they originate in the superficial lymph-glands of the neck, axillæ, and groins. The same, originating in the mediastinal or in the abdominal glands, is apt to be spoken of as a "lymphosarcoma," while, if the spleen is notably enlarged, the term "pseudoleukemia" is applied, so long as the blood remains normal. The same disease may be dubbed "leukemia" a week later, when the blood has become invaded with cells like those of the tumor. I shall follow in this book the terminology of Frank B. Mallory. He names all such tumors by their type cell, the lymphoblast, the cell occurring normally in the germ centers of lymph-nodes and lymphadenoid tissue. Tumors of this group are differentiated both from myeloblastoma—the histologic basis of myeloid leukemia with its subvariety, chloroma—and from myeloma, a tumor arising only within the bone-marrow and never associated with leukemic blood.

WHAT OTHER LUMPS MAY BE MISTAKEN FOR GLANDS?

I have known fatty tumors, subcutaneous cysts, abscesses, and the infiltration of actinomycosis to be mistaken for enlarged glands, but such mistakes are not common. Ordinarily, the soft lobulated surface of the fatty tumor and its situation away from the ordinary sites of glandular enlargement makes it easy to identify.

Cysts, especially those occurring in the neck, are less easily recognized, but they are rare, and, as a rule, their position and fluctuating consistency makes clear their origin.

Abscesses and subcutaneous infiltrations are much less circumscribed and definite in outline when compared with glands.

GLAND PUNCTURE

To introduce a hollow needle into the substance of an enlarged gland and withdraw gland juice has for some years been an important diagnostic procedure in cases of suspected trypanosomiasis, but the

procedure has not yet come into any general use as a part of the diagnosis of other diseases. It seems to me it should be more frequently employed, as by such means the organisms of syphilis, tuberculosis, and the more ordinary varieties of septicemia could perhaps be identified in culture or cover-slip.

Case 150

A clerk of twenty-nine entered the hospital December 7, 1905. For the past nine months a bunch has been noticed in the left side of the neck. It made its appearance rather suddenly and was at first about as big as a walnut. Three weeks ago he was thrown out of a carriage; since then the bunch has grown larger. For a few days he has had some trouble in swallowing.

Physical examination is negative save for scattered squeaks in both lungs, and in the left side of the neck an irregular-shaped, elastic mass the size of a child's fist, slightly tender, not adherent to the skin, but not freely movable. No fever. Blood and urine normal. Diagnosis, tuberculous glands of the neck.

Discussion.—Unlike tuberculosis or Hodgkin's disease, the lump present in this case has been recognized for nine months without anything on the other side of the neck. Another point of peculiarity in this case is the apparently sudden appearance of the bunch. I say "apparently sudden," as we must be on our guard lest the patient quite unintentionally misleads us upon this point. I have repeatedly had patients tell me most earnestly and in good faith that a certain lump had appeared over night, although investigation showed that the lump in question was a portion of the bony skeleton which had presumably existed for forty years or more.

But if the patient is correct in believing that this bunch has made its appearance suddenly, we may be somewhat suspicious that it is not a gland at all, especially as there is nothing in the mouth to suggest an origin.

Outcome.—At operation, December 8th, the supposed gland was dissected out. It was found to be adherent at its base, and in freeing it the gland broke, with the discharge of 2 ounces of watery pus. The wound healed normally. At the end of the operation the diagnosis is written, "Removal of tuberculous glands from the neck." Microscopic examination by Dr. W. F. Whitney showed a cystic tumor, the inner surface of which was lined by low, flat epithelium, the outer wall composed of an extremely vascular connective tissue, *i. e.*, branchial cyst.

Remarks.—Branchial cysts are of three types:

(1) Those that communicate with the mouth or throat through a sinus, so that pressure upon the cyst forces fluid into the patient's mouth.

(2) Those opening externally in the neck and discharging more or less intermittently their contents.

(3) Those which are blind at both ends and have no opening at all.

In the present case the cyst was apparently of the latter type. I saw not long ago a patient with a branchial cyst of the first type, which was about the size of an egg, situated above the left clavicle; on pressing it the patient was conscious of a gush of disagreeably tasting fluid in the mouth.

Case 151

A laborer in a factory, age fifty-two, entered the hospital July 12, 1904. The patient has never been sick before and denies venereal

Fig. 128.—Chest signs in Case 151.

disease. He drinks beer and whisky freely and is drunk about once a month. July 3d he noticed a lump in his left armpit. He has had

no previous cut upon his arm or hand or any sores. July 6th he came to the hospital for advice about it. A mass the size of a plum was felt in the left axilla, freely movable, not tender or fluctuant, with no reddening above it. Lungs as in Figs. 128 and 129. Temperature as in Fig. 130. Poultices were applied to the axilla and the patient was kept in bed. He complained of headache and the spleen was palpable. It was subsequently learned that he had chills and pain at the onset of the swelling in the axilla. The white cells were 9900. Widal reaction negative. Except for the abnormalities above mentioned, physical examination, including the urine, was negative. A stained smear of the

Fig. 129.—Chest signs in Case 151.

blood showed 82 per cent. of polynuclears and no eosinophils. Widal continued negative. By the 24th of July the swelling in the axilla had disappeared. Widal reaction was still negative. There was no reaction to tuberculin—10 mg. O. T.

The patient left the hospital July 27th and remained well until August 11th, when the lump reappeared in the left axilla—red, hot, and tender. At the same time he began to cough and raise yellow sputa, with fever (Fig. 131). Five weeks ago he weighed 160 pounds; now, 149 pounds. The glands were palpable, but not enlarged in the

neck, groins, and right axilla. The left axilla was filled by a mass of matted glands, hot and tender. This time the spleen was not palpable. The blood was negative. By the 17th the tenderness and inflammation was gone from the glands, but the mass seemed larger.

Discussion.—This patient has been conscious of a lump in the axilla for nine months only, but on examination he turns out to have, in addition, an enlargement of the spleen, a fever without leukocytosis, a negative Widal reaction and tuberculin reaction, and no recognizable focus of infection or source of neoplastic metastasis. At the time of the patient's entry the spleen is not felt and the axillary lump shows all the evidences of acute inflammation. Moreover, it is now asso-

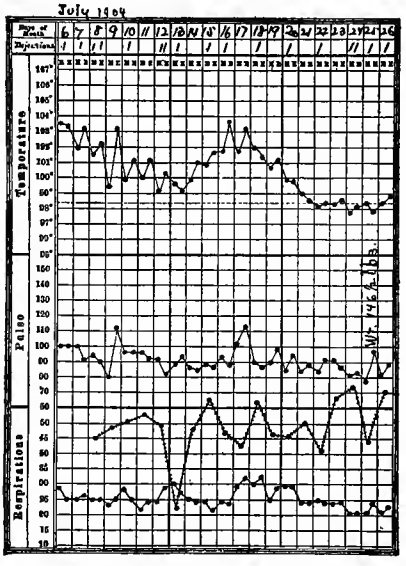

Fig. 130.—Chart 1 of Case 151.

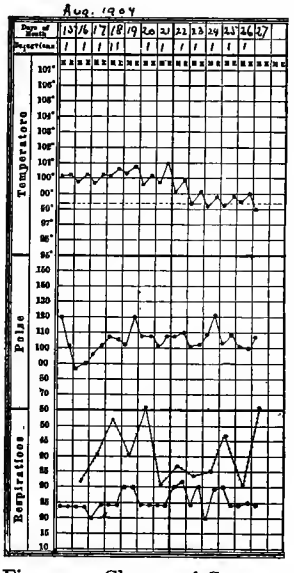

Fig. 131.—Chart 2 of Case 151.

ciated with glands in the neck, in the other axilla, and in the groins. At this time diagnosis is much more possible than at the time of his first appearance. Considering the generalization of the glandular lumps and the absence of any known infection prior to the glandular infection itself, it seems probable that we are dealing with a case of lymphoblastoma of rather an acute type, associated with secondary infection of the gland.

Outcome.—On the 19th a large infiltrating mass, extending deep under the pectoral and down the great vessels, was exposed by operation. A piece, 4 by 3 cm., was removed, and consisted of hard, gray tissue with a few necrotic areas. Examination by Dr. Channing

C. Simmons showed the structure of Hodgkin's disease. Dr. J. H. Wright concurred in the description given by Dr. Simmons, but preferred to regard the tumor as a form of lymphosarcoma. The wound healed well, and the patient left the hospital on the 28th.

Remarks.—I have given the terminology of the last paragraph exactly as it was written in the hospital records, but at the present time I think both these gentlemen would use Dr. Mallory's term, "lymphoblastoma."

Case 152

An Italian teamster of twenty-five entered the hospital March 7, 1911. He has a negative family history and past history. A year ago he noticed a swelling below his right ear and one below his Adam's apple. Both of these have increased in size since. He has had a good deal of trouble with his teeth in the past two years. He sweats much at night and has occasional buzzing in his ears.

Physical examination showed a few pea-sized glands in the posterior cervical triangles. In the region of the thyroid was a symmetric, bilateral, crescent-shaped tumor, about 2 by $1\frac{1}{2}$ inches, moving upward when the patient swallowed. There was no thrill or murmur over it. At the angle of the right jaw a mass of glands, from the size of an English walnut to that of a pullet's egg, somewhat adherent to the surrounding tissues, firm, not tender. There was no exophthalmos, no tachycardia, no tremor or sweating. Blood and urine negative. No fever. Pulse 80.

Discussion.—The case is a very unusual one from a clinical standpoint. Two tumors are present, one occupying the ordinary site of the thyroid gland, the other, at the angle of the jaw, being apparently separate. There are none of the toxic manifestations of Graves' disease, yet the patient is obviously much sicker than most of those in which what is called a simple goiter or enlargement of the thyroid gland is recognized.

The patient is very young for malignant disease, yet the gland at the angle of the jaw suggests metastasis. Possibly he has two independent diseases, a thyroid tumor of some kind or an adenitis, syphilitic, tuberculous, or septic in type. The characteristics of the cervical gland, however, are not those ordinarily seen in any of these forms of adenitis.

As usual in cases of doubt, the excision of a gland is the obvious indication.

Outcome.—One of the glands was removed and examined by

Dr. Wright, who found carcinoma. The tumor involving the thyroid was then removed. The larynx was found to be pushed to one side. The thyroid tumor was also proved to be cancerous when examined by Dr. W. F. Whitney. The patient made a good recovery and left the hospital March 20, 1911.

He returned to the wards December 26, 1911, having been treated regularly in the Out-patient Department in the meantime. Various cancer fluids had been injected without relief and his difficulty in breathing had become steadily worse. Dr. Coolidge suggested a deep tracheotomy. While being etherized the patient stopped breathing. Immediate incision into the cancer, over the windpipe, was followed by profuse bleeding which could not be controlled. The trachea was opened in the midst of the blood, with immediate cessation of part of the bleeding, but there was inhalation of some of the blood. A tracheal tube was inserted and the patient began to breathe. By the 16th of January he was breathing easily through the tube, which had, however, to be adjusted twice a day. He was then discharged to the Long Island Municipal Hospital.

The patient remained at this hospital for some months, and then was discharged at his own request, against advice. Nothing new was ascertained. A letter was sent to him, March 27, 1913, and was returned, marked "Dead."

Case 153

A night-watchman of forty-two entered the hospital October 28, 1909. Five years ago the patient noticed a small swelling, the size of a hazelnut, near the back of his neck. It was painless and very hard. Soon after two similar lumps appeared in the neck and were removed. A month later the side of the neck began to swell slowly, its size varying a good deal from time to time. There was still absolutely no pain. A year later he had the lump removed. It recurred in a month and was removed again a month ago. Since the last operation he has had a slight pain in his neck, but he still complains of nothing except that the growth recurs. Since the last operation he has lost a good deal of weight, he cannot say exactly how much. His appetite is good and he sleeps well.

Physical examination shows good nutrition and color. Right pupil larger than the left, both reacting normally. All other reflexes normal. On the left side of the neck, extending from the ear to the clavicle and from the median line in the back to the sternomastoid muscle in front, is a firm, insensitive, fixed mass, about the size of

two fists, with firm, discrete nodules, from the size of a pea to that of a bean, along its edge. A tongue of similar tissue extends under the chin to join a similar mass on the right side of the neck, about one-half the size of that on the left. In the left axilla a mass about the size of a hen's egg is palpable, but the right axilla is free, and there is nothing in the groins or epitrochlear regions. The chest and abdomen are negative. Blood and urine negative. No fever in two weeks' observation.

Discussion.—The most important point about this case is that the glands (if glands they be) have been present for five years in the postcervical region and have returned and increased, despite removal. There are only two types of glandular enlargement which behave in this way, the lymphoblastoma and the tuberculous gland. Nothing else is so chronic.

Against the diagnosis of tuberculosis is the fact that there has been no softening or suppuration in the glands, although they have been enlarged for five years. Further than that they do not involve the skin. Under these conditions the diagnosis of lymphoblastoma is strongly probable. It is notable that we have a similar glandular enlargement in one axilla only and none at all in the groins. The old idea that glandular growths of the chronic type (Hodgkin's disease) were always generalized or spread over many parts of the body is being gradually abandoned, as the result of histologic examinations which show that we may have a lymphoblastoma either of the slow-growing, hard, scirrhous type or of the more rapid and progressive form, yet remaining confined to a single group of glands.

Outcome.—A gland was removed for microscopic examination by Dr. J. H. Wright, who reported that it consisted of lymphadenoid tissue, but differed from a normal lymph-gland in having fewer sinuses and in not possessing the definite architecture of the lymphatic gland. The patient left the hospital on the 8th of November.

Case 154

A junk dealer of forty-eight, born in Russia, entered the hospital May 16, 1910. Eight weeks ago the patient began to feel weak. Five weeks ago he "caught cold." Two and a half weeks ago he noticed a sore on his left forearm with severe pain there; also pain in the right side of the head and deep in the right eye. Since the trouble began he cannot see with the right eye. There is also pain in the left shoulder, going down the outer side of his arm, and associated with weakness of the arm. The little finger and ring finger are almost useless. The

headache is associated with dizziness, which makes him unable to work. There has been no vomiting and no known fever. His past history is negative, save that he takes one or two glasses of whisky and two or three of wine a day. His wife has had no miscarriage.

Physical examination shows good nutrition. The right eye is blind and the right pupil is larger than the left; both pupils irregular and reacting sluggishly. The right abducens is paralyzed. Reflexes normal. Over the ulnar side of the left forearm are numerous rounded white scars, and others of the same character are seen on the inner side of the knees. On the radial side of the left forearm, at the junction of the lower and middle third, is a thickened, raised, reddish-brown crust, 1 by 1½ cm., surrounded by a red infiltrated area, 5 cm. in diameter.

At the junction of the first right rib with the manubrium is a firm, oval tumor, 4 by 3 cm., 1½ cm. high, cartilaginous in feel, and slightly tender. A slight rachitic rosary is palpable on both sides. Under the angle of the right jaw is a large tender lymph-node, many bean-sized glands in the axillæ and groins. The epitrochlears are palpable. Chest and abdomen are negative. Wassermann reaction negative. Urine negative. White cells, 24,000; hemoglobin, 70 per cent. Differential count of 200 white cells shows polynuclears, 7 per cent.; small lymphocytes, 4 per cent.; large mononuclear cells with "azure" granules, 89 per cent. The fundus of the right eye shows two hemorrhages near the disk.

The condition of the eye and the skin lesions suggest syphilis. Further examination of the left arm showed that there were irregular areas of anesthesia and no power to extend the forearm.

Discussion.—The symptoms are curiously scattered and various. First an intracranial group, with troubles in the arm, pain, paralysis, and soreness. The particular localization of these is unlike that of peripheral neuritis or any other peripheral disease, and suggests trouble in the brain. The condition of the pupils and the paralysis of one eye muscle suggests the same thing. The scars and the infiltration upon the arm, when considered in connection with the ocular lesions, lead us to surmise that the intracranial lesions may be syphilitic.

But the tumor on the rib and the glandular enlargements of the neck, axillæ, and groins draw our attention in another direction. The rib tumor might well be a myeloma, a metastasis from hypernephroma, or possibly a bony or cartilaginous outgrowth. The remains of a rachitic rosary suggest still another possibility that the rib tumor might be rachitic.

All these doubts are settled by the blood examination which is characteristic of lymphoid leukemia, that is, of the type of lymphoblastoma associated with a multiplication of tumor cells in the blood; in other words, with lymphemia. Note the very moderate increase in the total number of white cells. This is what we should expect in a case of this sort. The counts of 100,000 or more per cubic millimeter are usually in the myeloid type of leukemia. The greater number of the lymphoid cases, during most of their course, have a leukocyte count of 40,000 or less.

At the time of the patient's second hospital visit the clinical picture was still clearer. Fever and more infiltrating nodules had now appeared and the growth had doubtless involved the marrow, crowding out the erythroblastic centers and producing an anemia of the type known as myelophthisic anemia, that is, where the red cells of the marrow are starved out, pushed to the wall—the bony wall of the marrow—and gradually exterminated. This is the ordinary type of anemia occurring in the course of a lymphoblastoma or myeloblastoma of the leukemic type.

A nodule was excised from the axilla and examined by Dr. J. H. Wright, showing a lymph-gland, very rich in the larger lymphocytes and continuous with a mass of connective tissue and fat tissue, more or less densely infiltrated with large lymphocytes, associated with some eosinophils and myelocytes and a few small lymphocytes. Diagnosis, malignant lymphoma or leukemic tumor.

The patient left the hospital on the 19th of May and returned on the 27th. Since leaving the hospital he has had constant headaches, very severe and confined to the right side of the head. He has now no pain in the left arm, but much in the left shoulder. His right eye is still blind, the left normal. Since he left the hospital his right ear has become deaf and "roars like an engine." He has been in bed since he left the hospital because of fatigue; increased pain in the shoulder seizes him as soon as he stands up, and is accompanied by an uncontrollable desire to defecate.

Physical examination showed at this time a freely movable lymph-node over the middle of the right clavicle. The epitrochlears were of the size of a lentil. By percussion the spleen measured 8 by 10 cm., but its edge could not be felt. The entire left arm was now atrophic and the deltoid group of muscles soft and flabby. The crust, previously described, was still present, also the tumor near the breast bone.

The red cells at this time numbered 1,780,000, and the white, 37,000. Differential count was practically as before. During the

two weeks of his stay in the hospital the red count steadily declined until it reached 976,000, with 30 per cent. hemoglobin, on the 6th of June. The leukocyte count also declined from 37,000 at entrance to 14,000 June 1, and 13,000 June 6. The differential count, however, did not change in any important respect. The red cells showed slight achromia and abnormal staining, with considerable variations in size and shape. The patient ran a continuous fever, as shown in Fig. 132. The urine was negative. Examination of the ears by Dr. H. P. Mosher showed a moderate diminution of hearing in each ear, apparently due to middle-ear catarrh. Tests for involvement of the labyrinth were negative.

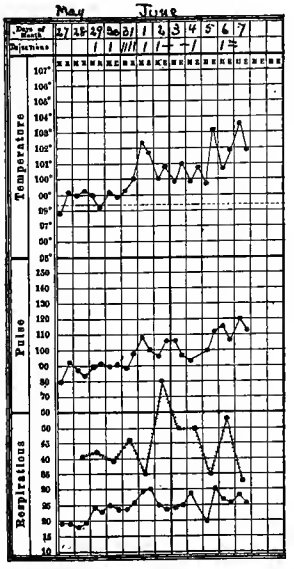

Fig. 132.—Chart of Case 154.

On the 5th of June there was evidence of involvement of the mastoid, and purulent discharge from the ear began the 1st of June. Coincident with the appearance of this suppuration occurred the fall of white corpuscles mentioned before. The patient lost ground steadily, and died on the 7th of June. Autopsy showed lymphoid leukemia.

Case 155

A gardener of fifty entered the hospital August 22, 1910. The patient has been well until the present illness; he denies venereal disease and has a negative family history. Three weeks ago he noticed a small lump in his neck and others in both axillæ and groins. They were then about half their present size. He feels perfectly well, except that he gets fatigued more easily than before. He has lost no weight. He has a good appetite and sleeps well.

Physical examination shows good nutrition, pupils slightly irregular in shape, equal in size, and reacting normally. Tonsils are very large. All the superficial lymph-nodes, including the epitrochlear, mental, submaxillary, and occipital, are enlarged. They vary from the size of a pea to that of a walnut, are freely movable, and not tender. The axillary glands extend along the pectoral muscle toward the nipple. Chest and abdomen negative, except that the sharp, firm, painless edge of the spleen can be felt on deep inspiration.

Wassermann reaction is positive. Blood-pressure, 140 mm. Hg. Urine negative. Blood examination shows red cells, 5,900,000; hemoglobin, 80 to 90 per cent. In stained smears the red cells are normal. The course of the white cells is seen in Fig. 133. The percentage of polynuclear cells is from 5 to 25 per cent., the rest of the

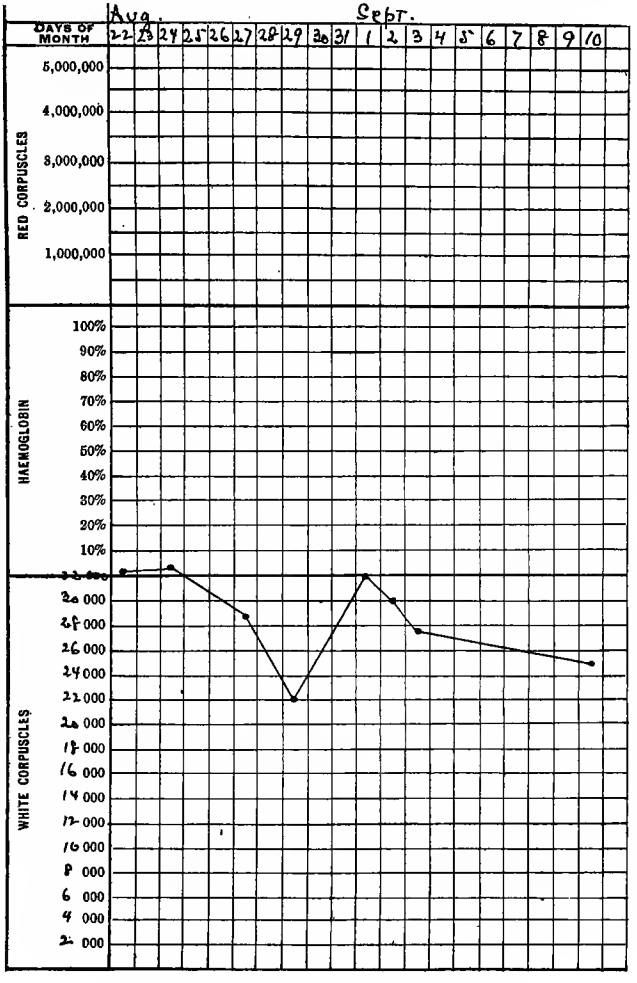

Fig. 133.—Chart of white cells in Case 155.

white cells being of the lymphocytic type. The small lymphocytes markedly predominate and make up from 55 to 66 per cent. of all the white cells present. The fundus oculi is normal.

Discussion.—The patient feels so well that it is difficult to believe that he has any serious disease, yet, with three sets of enlarged glands,

he certainly is far from well. The positive Wassermann reaction, in connection with the generalized adenitis, might lead us to assume that the latter was of syphilitic origin, but no one, I suppose, would undertake to make a diagnosis in such a case without counting the white corpuscles, and if this were done there could be no further doubt regarding the diagnosis of the case. It is clearly one of lymphemia with lymphoblastoma.

Outcome.—Under *x*-ray treatment the glands diminished in size. The health of the patient seemed to be perfect, and after the 10th of September he preferred to continue treatment in the Out-patient Department and was accordingly discharged, having gained 3 pounds since entrance.

Case 156

A carpenter of forty entered the hospital October 3, 1910. The patient's father died at sixty-five of unknown cause; his mother, of cancer of the breast; one cousin, of tuberculosis. Four brothers and one sister are living and well. The patient's wife has had two or three miscarriages, and is said to have had a sore throat, possibly of syphilitic origin. The last child, just born, seems healthy. The patient was always well until June, 1909, when he was in the Natick Hospital and an operation was done upon his left foot. The diagnosis was "osteitis, possibly malignant." July 27th he was at the Carney Hospital, and Dr. Macausland removed a tumor from his left foot which was said to be mixed sarcoma and carcinoma, but no pathologic report could be found. After that he seemed to be fairly well until two or three months ago, when he began to be very nervous and restless, frequently rubbing different parts of his body, bathing his feet to allay itching, complaining of vague abdominal discomforts and belching. Some deafness in one ear was noticed ten days ago. This morning he seemed to be completely deaf in both ears. His bowels are very constipated. Nothing else can be ascertained about his history.

Physical examination showed good nutrition, dry, harsh skin, the right pupil larger than the left, both reacting normally. The tongue showed a very thick, brown coat. Superficial lymph-glands not enlarged. Chest and abdomen negative. Knee-jerks not obtained. Achilles' jerk not obtained. In the left groin are a few confluent glands, making up a mass the size of two walnuts. The left knee is somewhat smaller than the right. On the outer side of the left foot, near the ankle bone, are a depressed scar and some red subcutaneous lumps, free from tenderness. The blood shows leuko-

cytes varying from 12,000 to 16,000, with 79 per cent. polynuclear cells. Urine negative.

During the month of his stay in the ward his temperature ranged usually between 99° and 100° F.; his pulse between 110 and 130; respiration about 25. The feces were negative for guaiac on three occasions. Sputum showed no prevailing type of organism. Examination of the ears by Dr. H. P. Mosher showed acute double labyrinthitis, probably specific. The fundus oculi was normal. A neurologic consultant could throw no light upon the case, though the patient had a well-marked Romberg sign, poor co-ordination in the arms, dull and delayed sensation in the legs. There was much twitching of the muscles of the arms, with scratching and restlessness. October 7th the right pupil reacted poorly.

October 7th, 5 c.c. of clear fluid were withdrawn from the spinal canal. Cell count, 1 per centimeter. Stained smear showed polynuclear cells, 66 per cent.; lymphocytes, 32 per cent.; eosinophils, 2 per cent., and many red cells; in other words, probably an admixture of blood.

Discussion.—The syphilitic history, the absence of tendon reflexes, the condition of the pupils, and the deafness may well be symptoms of syphilis. On the other hand, the presence of the lumps upon the foot and in the groin and the curious restlessness suggest a possible brain metastasis from neoplasm. Possibly he has more than one disease. It seems very difficult to reconcile or organize under one diagnosis all the facts given. As a matter of fact, until the histologic examination of the excised gland (see below) was made, no satisfactory diagnosis was arrived at in this case during life, although we had very little doubt that syphilis accounted for at least a part of his troubles.

Outcome.—On the 8th of October the glandular mass in the left groin was excised. Microscopic examination by Dr. J. H. Wright showed malignant lymphoma. No diagnosis could be made, and the patient remained in the ward without change until the latter part of October, when he became incontinent and delirious at night. On the 23d he had convulsive twitching and jerking of the arms and legs for a couple of days. At this time the reflexes could not be obtained. November 3d the patient died. The clinical diagnosis was malignant disease of the foot and inguinal glands, with metastases in the central nervous system, possibly also syphilis and tabes. Myxedema was also considered. Autopsy No. 2713 showed no sufficient cause for death. There was a syphilitic aortitis, a small hypernephroma of the kidney, and hemorrhagic areas in the lungs.

Case 157

A teacher of thirty-five entered the hospital December 28, 1910. Her family history was negative. She has been subject to colds and tonsillitis in the past and has had a slight dry cough for a year. She has had "bronchitis" every one or two years.

In the summer of 1909 she was at Rutland, with constant low fever, and an eruption which started in the ears and nose and gradually covered the lower part of face. There was a free discharge of pus from it and some blood. This began to go three months ago and has now nearly ceased. Her menstruation is regular and habits good.

In September, 1909, she noticed "glands" on each side of her neck. They were largest in January, 1910, and have been smaller since, but others have appeared behind the left ear and in the right axilla. In January, 1910, she was in bed six weeks with "heavy grip cold" and epigastric pain. She had a similar attack in March, 1909. After it the left leg was lame and the foot was painful and had purple spots on it. She has not walked since January. In June, 1910, she wakened one morning to find her left hand and left leg useless and the right side of her face "drawn down." Her speech was poor. She has gradually improved since, but the left hand is still weak.

She has not worked since March, 1909. There has been no loss of weight and no pain. Her appetite is fair. The bowels are costive; sleep is good.

Physical examination is negative except for hard, matted, nontender, large pea-sized glands over the left clavicle and larger ones in the right neck and axilla.

There is edema in the left leg and foot and the calf is slightly tender. There is ankle-clonus (four to five oscillations) on the left. The left-hand grip is weaker. The blood and urine are negative; blood-pressure, 115 mm. Hg.; Wassermann negative. There is no fever in one week.

Discussion.—Despite the negative Wassermann reaction there is a good deal to suggest syphilis as a cause of the adenitis in this case. The attack of June, 1910, might well be the result of syphilitic vascular lesions in the brain. The presence of ankle-clonus and muscular weakness upon the left side, six months later, gives support to the idea that some organic cerebral lesion is present.

There is good reason for referring the glands to the lymphomatous or lymphoblastic group and there is no evidence of tuberculosis.

The fact that glandular enlargement was noticed immediately after the purulent cutaneous lesions of the summer of 1909 renders it barely possible that a septicemia, with glandular hypertrophy in response to it, may be at the root of her troubles. Such a septicemia, producing not only local but general glandular enlargement, is not infrequently seen in the form beginning with tonsillitis and associated with streptococci.

Outcome.—April 11, 1913, Dr. James L. Wheaton, Jr., of Pawtucket, R. I., the patient's family physician, writes as follows: After leaving the Massachusetts General Hospital the patient was given *x*-ray treatment to the glands, as recommended there. She grew progressively worse and the glands in the neck enlarged. In every way she appeared to be nearing the end, which was predicted when she was at the hospital. She has had a good deal of facial acne, and in the attempt to clear this up a staphylococcic vaccine was given, and, "much to my surprise, not only did the acne improve, but the glands began to diminish in size and her strength gradually returned. Ever since that time I have given her regular doses of staphylococcic vaccine. She has regained her weight and most of her strength. The glands have almost disappeared, and it seems as if she was to be well again."

The diagnosis of Hodgkin's disease or lymphoblastoma was that thought the most probable when she left the hospital, but, in view of the above information, this seems to be very improbable. An adenitis of the septic type seems the most reasonable diagnosis.

Case 158

A cook of forty-one, a Swede, entered the hospital November 22, 1910, on account of frequent attacks of tonsillitis and enlarged tonsils. On the 23d the tonsils were removed, also the adenoids. The patient left the hospital the same day. December 20th, 1910, the patient came into the hospital again, stating that since last July he had been bothered by stiffness and pain in the lower back, increased by quick motion or lifting. For the last eight weeks, in addition to this pain, he has had soreness and stiffness in the right shoulder and elbow. Since his operation of three weeks ago he has had a painful swelling in the glands of his neck. He has no cough, but raises a good deal of matter from his throat. For years he has always had some shortness of breath on exertion and occasional attacks of pain in the left axilla. He uses ½ pint of whisky a day, but has never lost a day's work on account of liquor. His family history is negative, his appetite has

been good, but he has lost markedly in weight. Eight years ago he weighed 172 pounds; a year ago, 154 pounds; now, 127 pounds.

Physical examination showed fair nutrition. Normal pupils and reflexes. Throat slightly reddened, but usually no exudate. In the right side of the neck were tender, matted masses of glands; many similar glands about the size of a pea below this. Axillary, inguinal, and epitrochlear nodes were palpable, but not abnormal. Chest and abdomen negative. There was some tenderness and pain about the left scapula and right sacro-iliac joint. Urine negative. The blood showed a slight polynuclear leukocytosis, ranging from 11,000 to

Fig. 134.—Condition of liver and glands in Case 158

19,000. Dr. Osgood considered the condition of the back an infectious arthritis. On the 14th of January the conditions were as shown in Fig. 134.

Discussion.—This history reveals an alcoholic, with enlarged cervical glands, following a tonsil operation, with pain rather widely distributed in the trunk and right arm, with marked loss of weight, dyspnea, and anginoid paroxysms.

The physical examination shows, besides the cervical mass, an

enlarged liver, the surface of which is so uneven that only three possibilities need to be considered—malignant disease, syphilis, and hydatid. We have nothing in the patient's history nor in his blood to support the theory of hydatid, and his marked loss of weight and severe general discomfort is not what one expects in patients suffering from hydatid disease. As a rule, such patients complain of very little, but we need an explanation of the lump below the ribs. This patient does not want explanation, but relief.

Syphilis cannot be excluded, but we have no positive evidence of it. Malignant disease is probable.

Outcome.—One of the glands was excised and examined by Dr. J. H. Wright, who found it to be a metastatic malignant tumor, the nature of which he could not at first determine. January 15th a red patch appeared on the right cheek, which was pronounced "erysipelas" by a skin consultant. The patient lost ground rapidly, and died on the 30th of January. Autopsy No. 2785 showed a neuroblastoma of the neck, pleura, liver, retroperitoneal and bronchial lymph-nodes; tuberculosis of a bronchial lymphatic gland, chronic perisplenitis, hydrothorax.

Case 159

A farmer of thirty-six entered the hospital January 2, 1911. In the fall of 1909 he was laid up four days with an attack of nausea and vomiting without assignable cause. Before this he had always been well. Family history excellent. His next attack was from the spring of 1910 to the 3d of July, 1910. Since then he has had an attack about every third week, lasting three or four days at a time. The vomitus is brown and never contains blood. His stomach has been washed out a number of times without any special benefit in the way of information or improvement. His last attack was December 15th. His appetite, bowels, and sleep are good and he feels perfectly well. He loses about 10 pounds with each attack, but quickly regains it. He has never had anything like lightning pains or other sensory symptoms.

Physical examination shows normal pupils, glands, and reflexes, and is in other respects wholly negative, save for a rapid pulse and a slight excess of blood-pressure (Fig. 135). Blood and urine were normal. Weight, 119 pounds, stripped. Wassermann reaction negative. Dr. J. J. Putnam found no lesions of the central nervous system. Examination of the eyes was negative, as was examination of the ears. There was a very slight enlargement of the thyroid. The edge of

the liver, firm, smooth, not tender, was felt 2 inches below the ribs on the 3d of January. There was a very slight, fine tremor of the fingers. No bulging of the eyes, no sweating. The patient had no symptoms during his week in the hospital and left on the 7th of January.

On the 28th of March, 1913, he writes that his vomiting spells have been coming somewhat more frequently during the past two years. They are not accompanied by pain, and he recovers very rapidly from them. He states that the nerves of his stomach are stronger, but that his throat seems to be swelling and that he has some spells of choking.

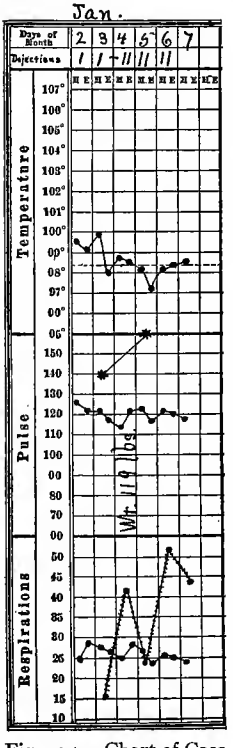

Fig. 135.—Chart of Case 159.

Discussion.—The periodic spells of vomiting are like those often seen in tabes, but there is nothing else in the case to suggest this, and the important points in the physical examination are the palpable liver, the slight enlargement of the thyroid, the tremor, and the rather high blood-pressure. I have never known such vomiting spells as this to result from a thyroid intoxication. Vomiting may form a part of such intoxication, but only in patients whose other toxic symptoms are much more marked. It seems to me very doubtful whether the thyroid has anything to do with this patient's vomiting.

Outcome.—The patient was seen again April 23, 1913. He stated that his vomiting spells now lasted only part of a day instead of two or three days, as formerly. This time he mentioned that during the previous year he had had four spells of pain in the legs, each attack lasting for a whole night, and darting, as he says, like a pleurisy, which, to him, means very quickly. Although the pain, as he says, darts, it is yet confined to one spot, and in each attack this spot has been somewhere between the knee and the ankle. During the past six months his vomiting attacks have come every other day, usually starting about 6.30 A. M. There is no nausea with the attacks, but he is very nervous in them and wants to be alone in a dark room. He has done no work for three years. Occasionally a drink of water sticks somewhere in his gullet and is regurgitated. Food is sometimes regurgitated in the same way, and after such an attack he has for some minutes a

sense of obstruction in the gullet. The patient entered the hospital again on the 23d of April, 1913, stating that the attacks of vomiting had gradually grown more frequent. He has lost 5 pounds in weight.

Examination shows normal pupils, very lively knee-jerks and plantar reflexes, but is otherwise negative. Systolic blood-pressure is 156 to 110 mm. Hg.

His lumbar puncture fluid shows 50 cells per cubic millimeter, all of them lymphocytes. Wassermann reaction in this fluid is positive; in the blood, negative. An *x*-ray shows no change in the outline of heart and aorta, no evidence of aortitis. Cerebrospinal syphilis with gastric crises is evidently the diagnosis, *despite* the normal pupils and knee-jerks. The enlarged thyroid is probably unimportant.

Case 160

A farmer of sixty-five entered the hospital January 23, 1911. The patient had "scrofula" in childhood; that is, the glands in the neck were then enlarged and discharged for a time, but have never bothered him since until three months ago, when he noticed that on the right side of the neck the glands were larger than usual. For a week they have been painful and tender. The tonsil was removed this morning in the Out-patient Department for diagnosis. His appetite is good, and he has slept well until this week, when the pain has kept him awake. He had worked until entrance, has no cough, no fever, no loss of weight.

Physical examination shows a well-nourished, healthy-looking man. Pupils and reflexes normal. Under the angle of the jaw, on the right, is a nodular mass the size of a fist. Elsewhere the glands are not enlarged. The right tonsil is about the size of a plum and is abnormally red. Physical examination otherwise negative, blood and urine normal, no fever in ten days' observation.

Discussion.—Apparently this patient had adenitis in his childhood, perhaps tuberculous, but we have no reason to connect that with his present troubles. The essentials in his present clinical condition are three months' complaint of cervical adenitis, with one week of pain and tenderness, in a man of sixty-five who feels perfectly well. The physical examination adds nothing except on the negative side. There is no reason to assume that the glands represent metastatic deposits, for there is no disturbance in the function of any thoracic or abdominal organ. It is not at all probable that they are tuberculous or syphilitic, since neither of these types of adenitis is apt to appear in a healthy man of sixty-five. There is no evidence of sepsis. A

primary tumor of the gland itself is the only plausible hypothesis remaining.

Outcome.—Pieces were removed from the tonsil and examined by Dr. W. F. Whitney. Diagnosis given, lymphosarcoma. Dr. Maurice H. Richardson saw the patient in consultation and advised no operation. The Wassermann reaction was negative. The patient was given *x*-ray treatment and improved considerably. Nevertheless, on February 1st he felt that he must go home and did so.

Remarks.—Although the diagnosis of lymphosarcoma is here recorded, there is no reason to believe that this represents anything but a variety in terminology. What we are dealing with is that same extraordinary multiple form of disease, already several times exemplified in this chapter, lymphoblastoma. It may be worth while here to indicate some of the extraordinarily wide clinical differences which are now included under this single term:

(1) The disease may be acute or chronic. It may last forty or fifty years. It may run its course within a few weeks and prove fatal within a few weeks.

(2) It may be confined to a single gland or group of glands, either inside the body cavities or in the familiar external sites of glandular enlargement.

(3) It may or may not be associated with involvement of the spleen, the bone-marrow, and the minute lymphadenoid foci situated in the skin and subcutaneous tissues and elsewhere.

(4) It may be associated with normal blood or with lymphemia.

(5) The glands may be few or many, large or small, hard or soft.

Owing to its extraordinary chronicity in certain cases, one hesitates to class it with the malignant neoplasms, yet in other cases no known tumor is more rapidly fatal or invades more disastrously the surrounding parts.

Case 161

A storekeeper of forty-eight, born in Russia, entered the hospital February 21, 1911. A year ago the patient began to get weak and could not do his usual work. Three months ago he noticed a lump under the skin of the right temple; two weeks later, another over the left eyebrow; a fortnight later, two more in the same region. After this last group appeared, he began to have headache and noticed a squint, for which he consulted an eye doctor, three months ago, without benefit. For the last two months he has noticed no change in the size of the lumps, but his headache often keeps him awake.

It was a good deal relieved, a week ago, by a nosebleed. He gave up work, finally, about a month ago, though he had not been working well for some time before that. Eighteen months ago he weighed 148 pounds; seven months ago, 135 pounds, with clothes; now, 118 pounds, without clothes.

Physical examination shows poor nutrition, slight pallor, five tumors about the face, in the positions indicated in Fig. 136. Number 1 was soft, unattached to the skin, not movable or tender, not fluctuant, about $3\frac{1}{2}$ cm. in diameter; No. 2 is firmer, otherwise about the same. The others resemble No. 2. The left eyeball is somewhat protuberant and shows external squint. The left pupil reacts very little to light and not at all to distance. The lymph-glands are not remarkable. The heart is negative, save for a late, blowing systolic murmur, transmitted to the axilla and the whole precordia. The apex extends 4 cm. outside the nipple line in the fifth space. The impulse is diffuse and heaving. At the base hardly any first sound is audible. The pulmonic second is accentuated. Blood-pressure, 135 mm. Hg., systolic; 80 mm. Hg., diastolic. The lungs are negative.

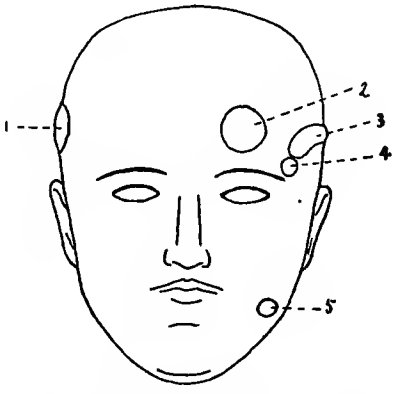

Fig. 136.—Showing position of lumps in Case 161.

The abdomen is negative except for a deeply felt sharp edge, corresponding to the spleen, and a similar edge, probably the liver; both of these edges about 2 inches below the ribs. There was no temperature in ten days' observation. The urine was not remarkable, save for the presence of the Bence-Jones body. The blood showed red cells, 2,100,000; white cells, 7500; hemoglobin, 75 per cent. Differential count not remarkable. Stained smear shows a few abnormally stained or stippled red cells, moderate achromia, and deformities of the red cells. Examination of the fundus by Dr. Quackenbos shows nothing abnormal. Wassermann reaction is negative. On the 26th I examined the blood and found a high color index, with much abnormal staining and stippling, but no other changes in the red cells and no abnormal variations of the white cells. *X*-ray, No. 18,631, shows areas of rarefaction, average size that of a twenty-five-cent piece, throughout the skull bones, also suggestions of similar proc-

esses on one or two points on each humerus and quite clear evidence of a similar tumor on one or two ribs. The sternum, pelvic bones, and scapulæ are negative.

Discussion.—This patient has been losing strength for a year and is 20 pounds under weight, yet his local symptoms are confined to the last three months, when there appeared a group of symptoms confined to the head, namely, palpable lumps, headache—more or less relieved by nosebleed—and a squint. Physical examination shows that there is, in addition, an enlargement of the liver and spleen, a curious atypical anemia, and, most significant of all, the Bence-Jones body in the urine. In the differential diagnosis, chloroma may be excluded by the blood examination. Hypernephroma is possible, but the presence of the Bence-Jones body is strongly against it. Moreover, hypernephroma is rarely associated with any such anemia. Syphilitic gummata are not associated with the presence of the Bence-Jones body in the urine, and after a duration of three months would probably have involved the skin. Moreover, there are no other manifestations of syphilis. The *x*-ray examination excludes syphilis and shows lesions quite unlike those of metastatic hypernephroma. Indeed, our radiologists were quite ready to make the diagnosis of multiple myeloma from the *x*-ray picture alone.

Outcome.—A bit of tumor No. 2 was excised on the 25th and examined by Dr. James H. Wright. He considered it to be a myeloma of the plasma-cell type. The excised tumor was embedded in a crater of bone with a sharp edge. A blunt instrument, inserted 1 cm. over the edge of the crater, did not strike bottom. March 3d the patient's wife insisted on taking him away. He died early in the following May.

Case 162

A laborer of eighteen entered the hospital July 12, 1911. Nine years ago the patient had irregular chills and fever for six months. It was called "malaria," but there was no blood examination. He was never disabled except during chills. There is no other malaria in his region. He has never been out of Massachusetts. November, 1910, he had pain in his ankles, which prevented him from working all winter, and was associated with a gradually increasing weakness. During May, 1911, he gained somewhat in strength and weight, but otherwise he has been losing. In March, 1911, lumps appeared in the right side of his neck, but they are now smaller than they were in March. His best weight was 143 pounds in November, 1910, in

clothes; now he weighs 105 pounds, without clothes. Save for weakness he still feels perfectly well, but has done no work since November, 1910.

Physical examination showed very poor nutrition; normal pupils and reflexes. Enlarged glands were palpable in the neck, on the right side of which is a firm, adherent, insensitive mass, 10 by 6 cm., with a few smaller masses at its edges. Other glands, the size of peas or beans, were to be found on both sides of the neck. The axillary glands were nearly as large as a pigeon's egg. The groin glands were not enlarged. The chest was negative; the edge of the spleen reached nearly to the navel. The edge of the liver was also easily palpable.

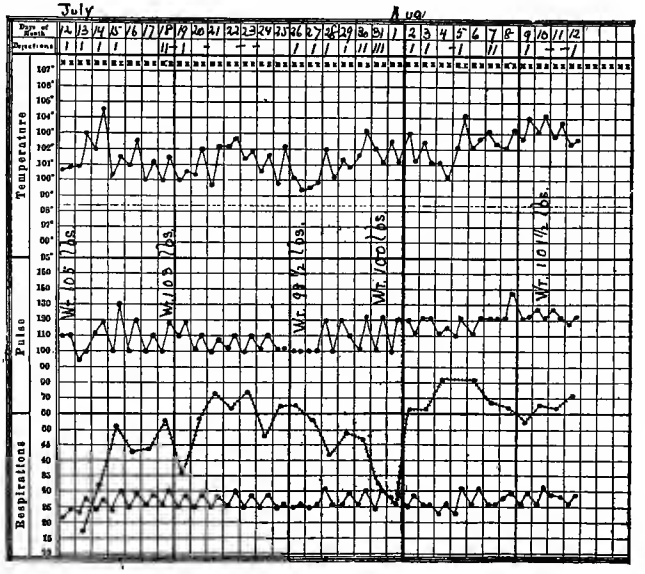

Fig. 137.—Chart of Case 162.

There was no edema. The course of the temperature is seen in Fig. 137. The red cells numbered 2,000,000 at entrance and declined in a fortnight to 1,000,000; later, to somewhat below that point, where they continued up to the 10th of August. The course of the white cells is seen in the accompanying chart (Fig. 138). The stained smear showed almost no achromia, no macrocytosis, considerable deformity, occasional abnormal staining. Blood-plates diminished. By the 29th of July there was marked achromia, and on the 10th of August considerable stippling. The polynuclears were hardly larger than red cells. The patient had severe nosebleed soon after entrance, the source of which could not be located by a laryngologist. A spray of

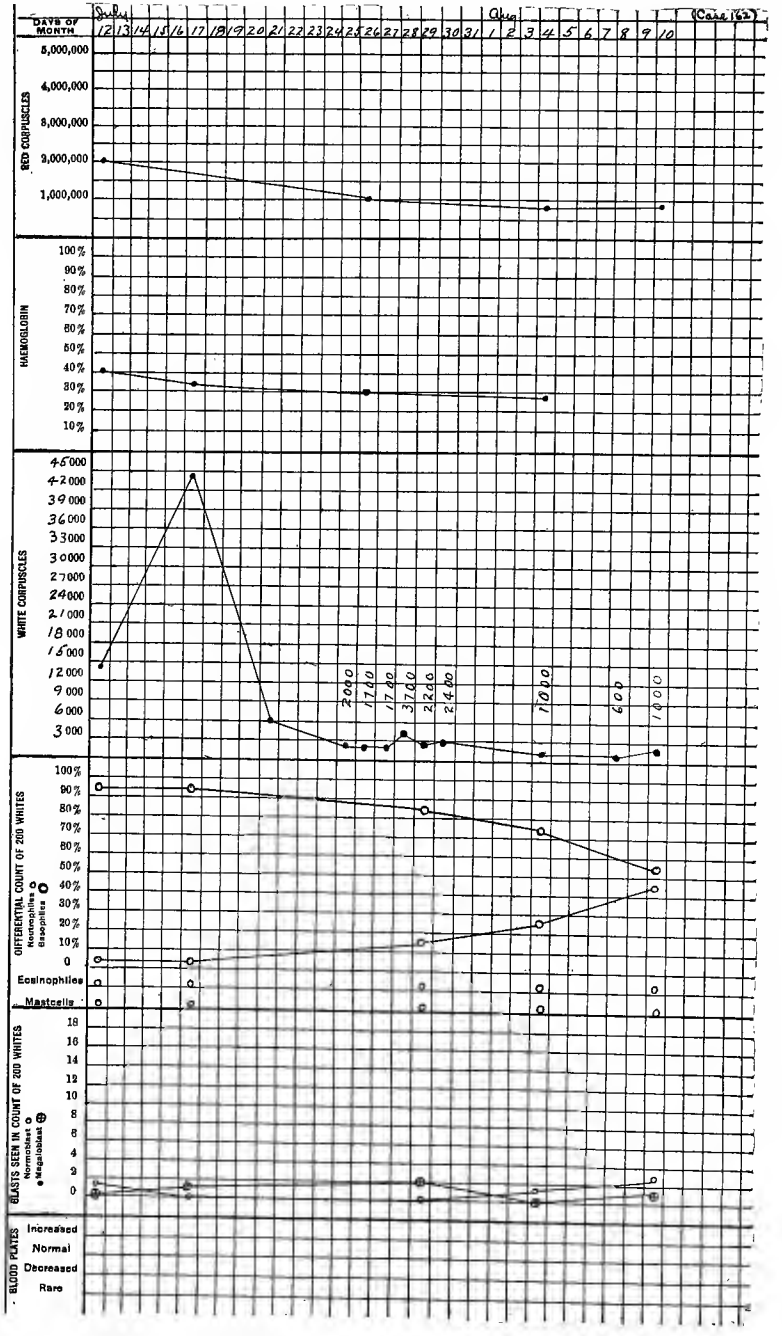

Fig. 138.—Blood chart of Case 162.

adrenalin, 1:10,000, four times a day in both nostrils, checked the bleeding.

Discussion.—No one could have any considerable doubt regarding the diagnosis of this case, provided he examined the blood at all, and with such glandular and splenic enlargements I fancy that few would to-day neglect blood examination. Taking together the results of blood examination and the blood-picture, we have a fairly typical case of what used to be called acute lymphatic leukemia, or of what is now interpreted as the sudden outpouring of lymphoblastomatous cells into the blood-stream.

I have called attention to the fact that for many months this patient complained of but little but weakness; that the appearance of the lumps in his neck occurred considerably later, and that during this period of weakness the diagnosis could probably have been made by blood examination. I have twice made such a diagnosis in a patient complaining of nothing but weakness and presenting no glandular or splenic enlargements.

A second point of interest is the remarkable leukopenia during the last weeks of the patient's life. On the 8th of August the number of white cells was only 600 per cubic millimeter. Such a terminal fall in the leukocyte count is not uncommon in cases of this type. Sometimes the leukopenia is the result of infection, streptococcus septicemia, pneumonia, or erysipelas; sometimes, as in this case, its cause is entirely obscure.

Outcome.—There was no improvement, and the patient left the hospital on the 12th of August.

Case 163

A printer of twenty-six entered the hospital November 8, 1911. The patient's wife has one child, now a month old and apparently healthy. A year ago she had a miscarriage, and two years ago a baby born prematurely at the eighth month. The patient has always been well until three weeks ago and denies venereal disease. Three weeks ago, after recovery from a slight sore throat, he noticed a swelling in the left side of his neck. This swelling reached its present size in about two weeks and has not changed in the past week. A week ago a swelling began on the other side of the neck and was accompanied by some pain. He has noticed sweating in the night several times, especially at the beginning of this illness. His best weight is 142 pounds; present weight, 128 pounds. He has worked steadily, though feeling unusually weak. His family history is excellent. He comes in

from the Out-patient Department with a diagnosis of "acute adenitis of unknown origin."

Physical examination showed poor nutrition, pallor, pupils slightly irregular and reacting very sluggishly. In the left side of the neck was a mass of glands the size of a baseball, hard, not tender, showing no fluctuation. Below this and above the clavicle were small, hard, discrete, insensitive glands. On the right side of the neck a gland the size of a large pecan nut was movable, insensitive, not fluctuant. No other enlarged glands detected. The teeth in very fair condition. The throat showed general reddening and the hard and soft palates look granular. The chest and abdomen were negative. The artery

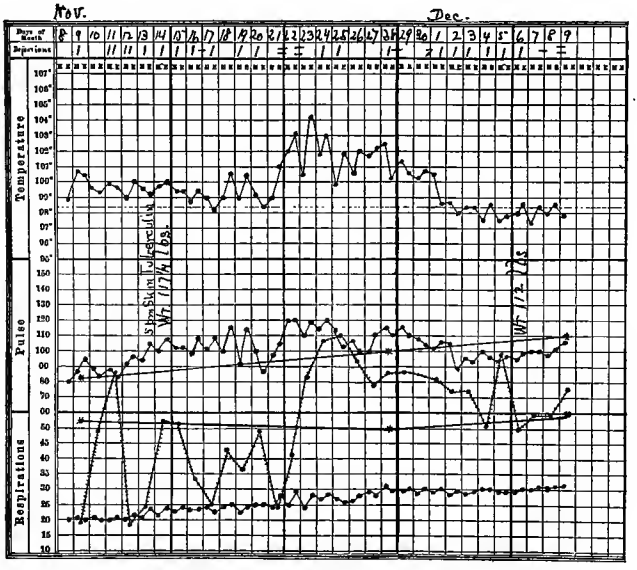

Fig. 139.—Chart of Case 163.

walls showed slight fibrous thickening. The reflexes were normal. Blood-pressure, 82 mm. Hg., systolic; 55 mm. Hg., diastolic, at entrance. A month later, 100 mm. Hg., systolic; 50 mm. Hg., diastolic; December 9th, 110 mm. Hg., systolic; 60 mm. Hg., diastolic. The course of the temperature is seen in Fig. 139. The urine was negative. The blood showed red cells, 3,200,000; white cells, 10,000; hemoglobin, 72 per cent. Stained smear showed moderate achromia, a rare stippled cell, and slight variations in size and shape. Differential count showed a slight polynuclear leukocytosis.

During his stay in the hospital the red cells rose to 3,500,000; the white, to 13,000. There was no other considerable change in the

blood. Wassermann reaction was negative. A throat consultant thought the glands were of tonsillar origin and advised removal of the tonsils. Dr. G. F. Balch advised no operation. On the 14th of November a gland was removed from the neck for diagnosis.

Discussion.—There is a good deal in the case to suggest syphilis, for, although the patient denies venereal disease, his wife has had one miscarriage and one premature child. The pupils have points in common with those seen in tabes, and for a considerable period the glands were smooth, hard, and insensitive, like those seen in syphilis.

The anemia, the fever, the loss of weight, the night-sweats are all perfectly consistent with the diagnosis of syphilis. On the other hand, the negative Wassermann reaction and the very low blood-pressure militate to a certain extent against this diagnosis.

It is of interest that the consultant from the throat department considered the glands of tonsillar origin and advised tonsillectomy, although it would be hard to explain the anemia, the low blood-pressure, and the loss of weight and strength upon this hypothesis.

Tuberculosis and lymphoblastoma remain. Between these diseases only histologic examination can decide. The low blood-pressure slightly favors the former.

Outcome.—Dr. W. F. Whitney reported that the gland showed increase of follicles and some small cheesy centers, with large giant cells and an occasional epitheloid cell. Diagnosis, tuberculosis. On the 20th the tonsils were removed. One of them examined in paraffin section, by Dr. J. H. Wright, showed typical tuberculosis. An emulsion of the tonsil in salt solution was made, and 20 minims injected in a guinea-pig November 20th. December 25th the pig was killed. Autopsy showed tuberculosis of the glands and spleen. The patient ran a higher fever after the tonsillectomy, but otherwise seemed to feel well. No signs developed in the lungs. He seemed considerably better. He ate well and nothing could be found in his lungs, but on the 9th tubercle bacilli were found in his sputum. He promised to report to the Social Service in the Out-patient Department and was accordingly discharged. He went to Rutland State Tuberculosis Hospital, and died there November 13, 1912.

Case 164

A Greek baker of twenty-one entered the hospital April 23, 1912. For three months he has had lumps on each side of his neck, gradually increasing in size. He feels perfectly well in other respects. Family history and past history good. He denies venereal disease.

Physical examination shows good nutrition. Glandular enlargement on both sides of the neck, extending from the mastoid process down behind the sternomastoid. The glands are smooth, rounded, fairly movable, not attached to the skin, and varying from ½ to 5 cm. in diameter. The teeth and tonsils are normal. In the axillæ are several glands, 1½ cm. in diameter. The inguinal glands not enlarged. The chest negative. The edges of the liver and spleen are felt on deep inspiration. No fever in a week's observation. Blood and urine negative. Blood-pressure, 135 mm. Hg.

Discussion.—Tuberculosis, syphilis, and lymphoblastoma were considered in the differential diagnosis, the latter being, upon the whole, thought most probable. Unfortunately, no Wassermann reaction was tried, and there is nothing in the case, as recorded, to exclude syphilis. The presence of splenic and hepatic enlargement slightly favors this disease, although in Greeks and other Mediterranean peoples we often find such enlargements without any known cause.

The fact that the lumps have existed for three months without softening or involving the skin is rather against tuberculosis, but by no means exclusive.

Outcome.—A gland excised from the neck showed on microscopic examination confluent foci of epithelioid and small round cells, with cheesy degeneration and scattered giant cells. Diagnosis—tuberculosis. The patient preferred to continue treatment in the Out-patient Department, and was accordingly discharged on the 29th.

January 1, 1913, the glands were considerably swollen. Soon after this he returned to Greece.

Remarks.—The case is inserted to indicate the frequent impossibility of diagnosis without histologic examination.

Case 165

A farmer of twenty-three entered the hospital May 25, 1912. The patient's father died of locomotor ataxia. His family history, as well as his past history, otherwise good. He denies venereal disease.

Four months ago he noticed a lump in the left side of his neck and in his left shoulder and arm a slight aching, which gradually wore away. Three months ago a similar mass appeared in the left axilla. Two months ago a lump appeared in the right side of his neck and a month ago one in the right axilla. He has lost weight and strength, and for two weeks has done no work. Walking causes his thighs to ache. His appetite and digestion are good. He has no fever as far

as he knows. Four months ago he weighed 165 pounds, with clothes; now, 142 pounds, without clothes.

Physical examination shows a well-developed muscular young man with normal pupils and reflexes. Heart and abdomen negative. On each side of the neck, between the sternomastoid and the trapezius, is a mass of glands, larger on the left side. Similar masses in the axillæ. The left side 5 cm. in diameter, the right somewhat smaller. No enlargement of inguinal or epitrochlear glands. The left lung

Fig. 140.—Chest signs in Case 165.

shows at the apex, posteriorly, dulness, bronchial breathing and whisper, normal fremitus. No râles. At the base, dulness, decreased whisper and fremitus, normal breathing. The substernal dulness is increased (Figs. 140, 141). The course of the temperature is shown in Fig. 142. The urine is normal. Blood-pressure normal. The blood shows 22,000 white cells, with 89 per cent. polynuclears. There is slight secondary anemia.

Discussion.—We have some reason to suspect that the patient's father was syphilitic, but there is no positive evidence of this disease

in the patient himself. Generalized adenitis, with loss of flesh and strength, fever, anemia, and polynuclear leukocytosis, are signs compatible with any of the three causes of general glandular enlargement most frequently demanding consideration in differential diagnosis—syphilis, tuberculosis, and lymphoblastoma.

But against tuberculosis is the presence of mediastinal pressure symptoms, such as, so far as I know, are never produced by tuber-



Fig. 141.—Chest signs in Case 165.

culous glands. I have called the pulmonary signs those of mediastinal pressure, because of the absence of râles and sputum and because of their association with an increase of substernal dulness. But for these facts the lung signs might well be interpreted as tuberculosis.

Leaving tuberculosis out of consideration, we have to consider whether syphilis would be likely to produce so much glandular enlargement without any other lesion, and especially whether it could account for the intrathoracic signs. The substernal dulness might be accounted for by an aneurysm and the pulmonary pressure signs in the same way. It would be rather unusual, however, to find such an aneurysm without any paralysis of the vocal cords or evidence of tracheal displace-

ment. *X*-ray evidence of aneurysm should be sought for. Does the tumor pulsate? Is it typically situated? The Wassermann reaction should, of course, be done. If negative answers are obtained to all these questions, the diagnosis should be lymphoblastoma.

Outcome.—An axillary gland was removed May 28th, and showed entire disappearance of lymphoid structure and replacement by small, round cell growth with a marked excess of fibrous tissue. The

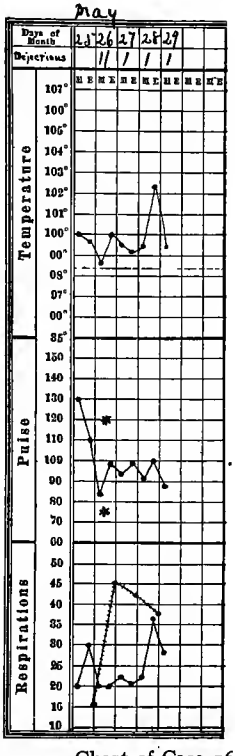

Fig. 142.—Chart of Case 165.

cells were a little larger and more irregular than normal lymphoid cells. Diagnosis—lymphoma. *X*-ray, No. 20,850, showed a shadow in the left side of the chest, more dense at the apex than at the base. The shadow at the base suggested a small amount of fluid. There were enlarged glands at the roots of each lung. The shadow of the heart and great vessels was generally enlarged. The patient entered only for diagnosis, and left the hospital on the 29th.

CHAPTER VII

BLOOD IN THE STOOLS (MELENA)

MELENA means dark blood in the stools, so-called tarry stools. When this is present it means that the blood has been poured out high up in the intestinal tract. In practically every case this means the gullet, stomach, or duodenum. It is very rare to see a tarry stool as a result of any hemorrhage in the small intestine.

Hemorrhages in the large intestine or in the rectum show themselves by the expulsion of relatively fresh and unaltered blood. The latter are common and usually unimportant. The former, tarry stools, are relatively rare and much more important. They often escape observation, as their color is much less alarming and they make less impression upon the patient's mind.

Besides gross hemorrhages of either of the types just mentioned, we have minute hemorrhages, demonstrable by chemical tests, such as guaiac or benzidin. The latter are of especial importance in connection with gastric cancer and gastric ulcer.

Fresh blood in the stools is due in the vast majority of cases to *piles* in case the patient is constipated, or to *enteritis* in case the bowels are loose. These are the common and relatively unimportant causes for the appearance of blood in the stools. It should be remembered, however, that in elderly persons cancer of the rectum is not infrequently mistaken for piles and neglected accordingly. Every case of rectal hemorrhage occurring in an elderly person should be carefully investigated, in order to exclude the possibility of cancer. The diagnosis of hemorrhoids, internal or external, is easily made by inspection, especially if a proctoscopic tube is used.

The supposed relationship between hemorrhoids and cirrhosis of the liver is probably legendary. There is no good reason to believe that piles occur any more frequently in cirrhotics than in other persons of the same age.

Next to hemorrhoids and acute diarrheas, *cancer of the intestine* or of the stomach is the most important cause of a discharge of blood with the feces. The amount of blood thus discharged is usually very small, and recognizable only by the chemical tests above mentioned. In cancerous cases the discharge of blood is usually steady,

Blood in the Stools

(GROSS BLEEDING—NOT MICROSCOPIC)

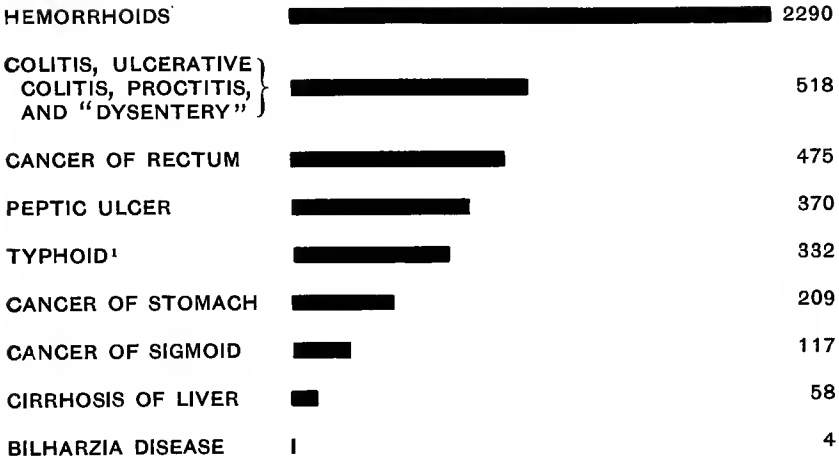

[1] Disproportionately large because of the abnormally great number of typhoid cases treated at this hospital.

(In phthisis, pulmonary blood is often swallowed and passed by rectum. *How often* cannot be said.)

NEW YORK STATE VETERINARY COLLEGE LIBRARY

though small. In gastric ulcer, on the other hand, it is usually intermittent, and the amount discharged is usually larger than in cancer. Tarry stools—that is, the expulsion of a large quantity of blood changed by its retention in the intestine—are rarely seen in gastric cancer or in any affection other than peptic ulcer or cirrhotic liver.

Ulcerations of the large intestine, whether acute or chronic, usually discharge pus as well as blood into the stools, and are to be distinguished in this way from the causes previously mentioned.

In *typhoid fever* the hemorrhages are usually from the large intestine or the lowest portion of the small intestine, and the blood is, therefore, relatively fresh or but slightly altered.

Syphilis of the lower portion of the colon usually shows itself for the first time by symptoms of intestinal stricture, but occasionally in the earlier stages of the same disease blood is discharged in the stools, and is then often attributed to hemorrhoids. Intussusception produces bloody stools in a relatively small proportion of cases. The same is true of infarction of the intestine, which usually results in symptoms indistinguishable from those of intestinal obstruction.

Bilharzia disease is a common cause of bloody stools in tropical climates.

It must also be remembered that blood swallowed, either as the result of a nosebleed or pulmonary hemorrhage or from some ulcerative condition of the mouth, will appear in the stools and may give rise to the mistaken belief that the intestine or the stomach is diseased. A careful history of the case will usually determine this point.

Case 166

An Italian laborer of twenty entered the hospital November 17, 1902. About a month and a half ago the patient began to have difficulty with his bowels, frequent desire to defecate, but would pass only blood mixed with pus and mucus. This continued until three weeks ago, when, under medicine, brown, watery movements began. During the last five days he has passed very little blood or pus. He has never had an attack like this before. Just before movements there is a good deal of abdominal pain. The patient has lost no weight, has a good appetite, no nausea or vomiting.

Physical examination showed good nutrition, and was otherwise negative, save as related to the abdomen, which showed dulness in the right flank, not changing with position. There was some general tenderness, most marked in the left iliac region. The temperature was 100° F.; pulse, 120; respiration, 32. Widal reaction negative.

The white cells were 26,700; hemoglobin, 98 per cent. The urine was normal in amount; specific gravity, 1028; slightest possible trace of albumin; rare hyaline and fine granular cast.

The patient seemed to have little or no control of the sphincter. The stools were semisolid in consistency, dark brown to blue in color. Most of them contained a little blood. Rectal examination showed, projecting into the rectum and narrowing its lumen as far as the finger can reach, frequent nodules, varying in size from that of a large bean to that of a horse chestnut. They were very hard. A surgical consultant could not decide whether the trouble was syphilitic or malignant, but favored the former and advised antisyphilitic treatment, which was immediately given, according to the local custom of that day, in the form of potassium iodid, 5 gr. three times a day, increasing 5 gr. each day.

Discussion.—The symptoms are those of proctitis with fever and leukocytosis in a man of twenty. Such a condition would be of no importance if it were acute. Most brief and mild diarrheas begin in this way, but in this case the symptoms have lasted six weeks and very little true fecal matter is seen in the discharges. Taking these facts alone, one would conjecture that a chronic ulcerative proctitis or colitis is the cause of his troubles. Without rectal examination, such a diagnosis would probably never have been questioned. The whole interest and significance of the case centers around the results of rectal examination.

Nodules, such as those here described, may be due to bilharzia disease, to syphilis, or to cancer, possibly also to a lymphoblastoma, although in this case they would certainly appear elsewhere. The latter observation applies to all of the other possible causes known to me.

Outcome.—A week later, as there was no improvement, a small piece of the rectal growth was removed. Examination by Dr. J. H. Wright showed a tissue characteristic of colloid carcinoma. The cause was explained to the patient, and his friends then decided to take him back to Italy. He left the hospital on the 4th of December.

Remarks.—This case shows that one must always consider cancer of the rectum, no matter how young the patient is. I remember a similar case which I saw many years ago with Dr. Reginald H. Fitz. There was much in the case to suggest cancer of the sigmoid, but as the patient was only twenty-one years of age we excluded this from consideration wrongly, as the outcome of the case showed. The main lesson of the case is the importance of rectal examination, digital or ocular, in all cases of rectal disease lasting more than a few days.

Case 167

A jeweler of twenty-nine entered the hospital May 9, 1904. Twelve days ago the patient had a severe headache and felt weak. He took to bed, but did not stay there. After getting up again, however, he grew rapidly worse; six days ago he woke in the night and had a profuse hemorrhage from the bowels, followed four days ago by another. The day before this last hemorrhage he took to his bed for the second time and has remained there since. Except for the hemorrhages, his bowels have not moved at all as far as he knows. His family history and past history are excellent.

Physical examination is negative, except as relates to the abdomen, which is markedly distended, and, upon the right side, somewhat rigid. It is tympanitic throughout and not tender. The temperature is 103.2° F.; pulse, 130; respiration, 24. The red cells are 2,396,000; white cells, 8900; hemoglobin, 55 per cent. The urine averaged 40 ounces in twenty-four hours; specific gravity, 1023; slight trace of albumin; rare hyaline and granular casts. Widal reaction was doubtful. On account of the spasm of the abdomen a surgical consultant saw the patient on the 9th and found no evidence of peritonitis. The patient was slightly delirious, but had no more hemorrhage and the distention gradually decreased. On the 15th there was evidence of a moderate cystitis, and the bladder was washed three times a day with 2 per cent. boric acid. On the 17th the blood showed red cells, 4,800,000; whites, 4400; hemoglobin, 70 per cent. Differential count normal.

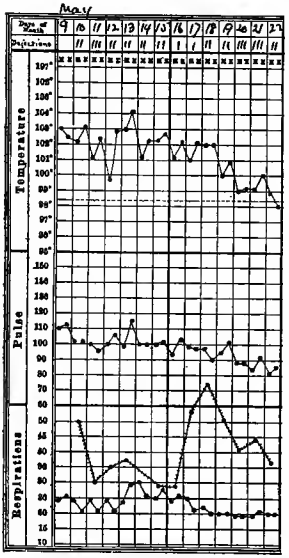

Fig. 143.—Chart of Case 167.

Discussion.—Hemorrhage from the bowels in a patient previously well, or comparatively well, is a very rare occurrence, or, at any rate, is very rarely recognized. Intussusception or infarction of the bowel may occasionally produce such a hemorrhage, but only in connection with the evidences of intestinal obstruction such as are absent here.

The different varieties of intestinal ulceration from which bleed-

ing may occur do not bleed with such suddenness and without previous evidences of intestinal irritation.

I think one would be altogether at a loss for a diagnosis here but for the later appearance of abdominal distention, with fever and delirium. This group of symptoms should make anyone of ordinary intelligence search carefully for evidences of typhoid fever. There are very few causes for intestinal hemorrhage combined with fever. Dysentery may produce both these symptoms, but there is no dysentery present in this case. Syphilis may do it, but the symptoms are usually more definitely localized in or near the rectum and the amount of blood discharged is smaller. I see nothing in the case to invalidate a diagnosis of typhoid fever. A doubtful Widal reaction should not weigh at all against such a diagnosis.

It is unusual to see intestinal hemorrhage so early in the course of typhoid. As a rule, the bleeding comes in the latter weeks of the disease. Still the case is by no means unique, and will be classed as one of "walking typhoid," with early hemorrhage.

Outcome.—Within a few days after this the temperature fell to normal, having been continuously elevated before that time (Fig. 143). Convalescence was uninterrupted. He left the hospital on the 14th of June.

Case 168

A housewife of thirty-eight entered the hospital June 4, 1906. Twenty years ago the patient first noticed bright blood and mucus in the stools, which averaged six a day, almost all of them in the morning and none of them at night. There was very slight pain just before movements and relieved by them. Some of the discharges contained fecal matter, others consisted wholly of blood and mucus. There was no incontinence. Nine months ago she began treatment by daily irrigations, and improved steadily up to three weeks ago. For ten weeks there was no blood in the discharges, and the movements were reduced to one daily and of normal consistency.

Three weeks ago the blood reappeared and the discharges became more frequent. For nearly a year she has lived on nitrogenous diet and has lost in weight, strength, and color. Except for lack of appetite and weakness she feels perfectly well, and throughout the trouble has been able to do most of the work for her husband and three children.

Physical examination showed good nutrition. The patient did not look sick. There was a soft, systolic murmur, loudest in the

pulmonary area, heard all over the precordia and faintly in the axilla. The abdomen was tympanitic in the center, dull in the flanks, the dulness not shifting with change of position. During the five weeks of her stay in the hospital the evening temperature often reached 99.5° or 99.8° F., usually normal in the morning. The pulse during the first two weeks was between 80 and 90; after that, between 90 and 100. The stools contained a moderate amount of mucus and were positive to guaiac. Microscopically, they contained no blood or eggs, but many undigested muscle-fibers. The patient was put on nitrogenous diet, colonic irrigations at 116° F. twice a day, orphol 5 gr., three times a day, after meals. 7 mg. old tuberculin was injected, without any reaction. Proctoscopic examination showed no ulcerations in the rectum. The blood and pus, however, did not disappear from the stools.

Discussion.—When the stools contain only blood and mucus, dysentery is usually the diagnosis, and by "dysentery" in this connection I mean chronic ulcerative colitis. But at first sight this diagnosis seems to be impossible, because the patient has been doing all the housework for a family of four and still shows good nutrition. Any one of large clinical experience, however, has often seen similar cases. It is really extraordinary how bad an ulcerative colitis may exist without disabling the patient or even reducing his nutrition to any extent. In other cases, apparently no worse from the anatomic and pathologic point of view, the patient is utterly prostrated, emaciated, and useless. I know no way to explain these differences.

In the present case we have dulness in the flanks, without any shifting with change of position. This physical sign is often seen in dysenteric cases, acute or chronic. The slight fever present does not help us toward more accurate diagnosis. The negative tuberculin reaction, on the other hand, is of considerable importance. A positive reaction would mean very little, but a negative reaction goes far to exclude tuberculosis. Taking the negative features of the case and the condition of the stools, I do not see how any other diagnosis than ulcerative colitis is possible.

In New England one sees a good many cases like this in which a non-amebic, chronic, and largely afebrile colitis arises without known cause, and runs its course either to recovery or to a fatal termination quite uninfluenced by treatment. Prognosis is never hopeless as long as the patient is alive. I have seen the most seemingly pernicious and virulent cases recover after all treatment had been given up. On the

other hand, cases which, like the present one, seem in many respects mild because their effect on general nutrition is for months and years so slight, may at any time be transformed into a progressive, finally fatal, disease.

In differential diagnosis one might consider cancer of the intestine, but the long duration of the patient's illness makes this very improbable, especially as no tumor has developed.

Outcome.—Pills of camphor, opium, and tannin were tried from June 14th to June 29th, three times a day, before meals, also tannic acid irrigations, 1 dram to the quart. None of these methods of treatment helped her. She left the hospital July 7th, unrelieved.

Case 169

A Canadian brick-maker of fifty-eight entered the hospital January 24, 1910. After fifty-seven and a half years of excellent health the patient noticed last July that for a period of two weeks his stools were tarry black. He felt well, however, until the first of October, when he began to notice a distress fifteen minutes after eating, and would often vomit soon after heavy food. Since this he has vomited, as a rule, about twice a week, a large amount being ejected each time. Soon after meals, always within an hour and a half, he has epigastric pain and gas. He has never vomited blood. Meat and eggs give him special trouble. His appetite is fair. He has no nausea. Bowels are constipated. He sleeps well. Since last spring he has lost 32 pounds. He gave up work last August on account of this illness.

Physical examination shows fair nutrition, slight pallor, the right pupil irregular and not responding to light or accommodation. The left pupil normal. Glands and reflexes normal. Chest and abdomen negative. The capacity of the fasting stomach is 28 ounces, and the wash-water contains fragments of food and shows a positive guaiac reaction. No free HCl. The lower border of the stomach is at the navel after inflation. After a test-meal free HCl is absent and blood present. The stools are strongly positive to guaiac on each of five tests. Blood and urine normal. No fever. Blood-pressure, 105 mm. Hg.

Discussion.—The point of special interest in this case is the appearance of black stools as the first or presenting symptom and at a time when the patient was feeling in other respects well. Indeed, it was not until three months later that the group of gastric symptoms typical of gastric cancer made their appearance. The existence of gastric stasis, with a positive guaiac reaction and no HCl,

in a man of fifty-eight, who has lost 32 pounds in nine months and has always been well until the present illness, leaves us little doubt that gastric cancer is the diagnosis.

Why did the patient first bleed from the bowel? I am unable to say.

Outcome.—On the 5th of February operation showed a markedly contracted stomach, infiltrated with new growth, from one end to the other. There was not even enough normal stomach to allow gastro-enterostomy. The patient was discharged February 15th. A small lymph-node excised at the time of operation showed no evidences of tumor. Nevertheless, he died in January, 1911.

Case 170

An Irish laborer of twenty-six entered the hospital March 3, 1911. The patient's family history was good and his past history uneventful up to the time of the present illness. In 1896 he enlisted in the British Army, and was four years in South Africa and then a year in Mauritius, whence he was invalided home on account of the illness next to be described. In 1900, when in South Africa, he noticed blood in the stools and in the urine, but after a few days off duty felt well, and six months later was transferred to Mauritius. After four months there he began to notice blood in the urine, and stayed in a hospital twelve weeks without improvement. Ever since then he has been unable to work, and has had blood in the urine and pain on micturition steadily. He urinates about twenty times a day and three or four times in the night. Nevertheless, he has done some work, off and on, until eight weeks ago.

Physical examination was negative, except that the urine contained considerable blood and pus and large numbers of bilharzia eggs, with spines at the end. The blood was negative. No temperature in three weeks' observation. On one occasion there was a considerable amount of blood in the stools, but no eggs.

Discussion.—When blood appears both in the stools and the urine of a patient who has been in the Tropics, we should always consider, first of all, bilharzia disease of the bladder and rectum, and examine the urine and feces for the characteristic eggs with their terminal or lateral spear point. In certain parts of Egypt and other tropical regions, bilharzia disease is by far the commonest cause of bloody stools. In this country it is rare, and, so far as I know, has never occurred except in patients who have brought it from some tropical region.

Cancer of the bladder or of the rectum, infiltrating the wall intervening between the two organs, may produce a simultaneous discharge of blood in the urine and feces. Such a growth, however, is easily detected by rectal examination or by cystoscopy, and at the age of twenty-six would be extraordinarily rare. Aside from tuberculous disease and cancer, there is practically nothing else which can produce a simultaneous discharge of blood in the urine and feces, although, in hemorrhagic diseases, such an association is occasionally to be observed.

Outcome.—Bilharzia eggs were later found. The patient was given 0.6 gram of "606" intravenously in alkaline solution, and, after a moderate reaction, left the hospital on the 20th of March.

Case 171

An Italian laborer of forty-one entered the hospital March 20, 1911. The patient lived in southern Italy until fifteen years ago, then was in Russia five years, then in South America a few months. For the past ten years he has been in Massachusetts. He had syphilis four years ago. Up to three years ago he was a heavy drinker of wine, beer and whisky, and was often drunk.

For three or four years he has noticed blood with every movement of the bowels. The movements are soft and occur four or five times a day, but cause no pain. His appetite is ravenous. Any considerable amount of solid food makes his bowels move more frequently, so that he has lived mostly on eggs, milk, and macaroni. For the past four months he says he has had to give up his work as a ditch digger on account of coldness of the feet. He has lost no weight or strength, and feels well in other respects.

Physical examination showed a well-nourished patient who did not look sick. The stools at this time showed no amebæ or other abnormality. Wassermann reaction was negative, and, after two weeks' observation, with normal temperature, blood, and urine, and a systolic blood-pressure of 135 mm. Hg., he left the hospital.

Discussion.—Three causes for bloody stools are suggested by this history—syphilis, cirrhosis of the liver, and amebic dysentery. Of cirrhosis we have no evidence. Syphilis of the rectum or sigmoid should give us some evidence of intestinal stenosis. Nothing of the kind is present here. The further determination of the disease rests upon the study of the stools and proctoscopic examination. If nothing particular is found in the stools, a diagnosis of ulcerative colitis, cause unknown, will be our best surmise. In this case, as in one of

those previously recorded, the good nutrition of the patient is in striking contrast with the long duration and apparent severity of his disease.

Outcome.—Later on he returned and amebæ of the histolytic type were found.

Remarks.—Unfortunately, this patient was not given the benefit of the emetin treatment, which had not at that time been discovered. With such treatment a speedy recovery might have been expected.

CHAPTER VIII

SWELLING OF THE FACE

First of all, it should be recognized that a certain amount of swelling about the eyes and a trifling puffiness of the rest of the face is *normal in certain individuals when they first wake in the morning.*

Doubtless there are individual differences of tissue which explain why some people have this symptom and others do not. Nothing is more striking than the individual differences between healthy people as regards the dryness or juiciness, the firmness or flabbiness of their tissues. Fat people are perhaps a little more apt to have this symptom (early morning edema of the face) than others.

After *an alcoholic debauch* persons who never suffer from this symptom at other times often present it in a marked degree. Just why I do not know.

During *pregnancy* a certain amount of edema, both in the face and elsewhere, is not infrequently seen, despite a normal condition of the kidneys and heart. Such an edema, however, should always lead us to a most searching investigation of the urine and of the precordia.

Local *skin lesions*, such as severe sunburn, eczema, measles, and erysipelas, are associated with edema of the face, sometimes of tremendous degree. Especially in erysipelas one often sees a total closure of both eyes, owing to the accumulation of fluid in the loose tissues around them.

The familiar swollen face of *toothache* leads, as a rule, to no difficulties of diagnosis, because it is unilateral and because the affected tooth calls attention to its presence in unmistakable ways. Occasionally, however, an affection of the *antrum* or a local abscess of the cheek may accompany or simulate the edema of toothache. Careful examination should set us right.

In glomerular *nephritis*, and in some of the degenerative tubular lesions of the kidney, such as corrosive sublimate kidney, marked edema of the face often precedes or exceeds the edema of other parts. The vascular forms of nephritis and the more chronic slow-going types less often produce facial edema. Children seem to be some-

what more subject than adults to severe edema in connection with nephritis, and this applies to the face as well as to other parts of the body.

Some years ago it was customary to say that *cardiac edema* was never in the face, while renal edema was very apt to begin there. This can no longer be maintained in any strict sense, although it represents the truth as regards the majority of cases. Pure cardiac dropsy, without any nephritis, may produce swelling of the face, although such swelling rarely precedes or exceeds the dropsy of other parts.

Of special diagnostic importance is the facial edema of *trichiniasis*, first, because it is often forgotten, and second, because we are dealing here with a disease which is much less simple than that of cardiac and renal causes of edema. In trichiniasis the puffy face accompanies, as a rule, a greater or lesser degree of conjunctivitis, and the swollen lids are often red, in addition. Should such a group of signs be associated with any unexplained fever, trichiniasis should always be suspected, whether the classical pains and soreness are present or not. When trichiniasis is suspected, as it should be, owing to conditions described above, the next step should always be the examination of the blood for eosinophilia. If that is present, trichiniasis is almost certainly the diagnosis, provided, of course, that the renal and cardiac and local dermatologic causes of edema are excluded. If eosinophilia is absent, we cannot exclude trichiniasis, since there are now and then cases in which this symptom is for a long time missing. Wherever it is possible the diagnosis should be further substantiated by histologic examination of a bit of excised muscle, or, failing this, by the study of the sediment of a specimen of venous blood, laked with 3 per cent. acetic acid, according to the methods suggested by Staübli[1] and Janeway.[2]

In *pernicious anemia* edema of the face is much less common than swelling of the lower extremities. Nevertheless, it is occasionally seen, especially in cases which are being treated with large doses of arsenic. How far arsenic-poisoning is the cause of such an edema it is often difficult to discover, but whenever arsenic is being given in supposedly therapeutic doses, edema of the face should make us suspect that we are poisoning the patient.

Tumors of the neck or *mediastinum* may interfere with the venous return from the head in such a way as to produce an alarming edema of the head and neck. Thoracic aneurysm may occasionally produce

[1] Münch. med. Woch., 1908, lv, 2601.

[2] Archives of Internal Medicine, vol. iii, p. 263.

Swollen Face

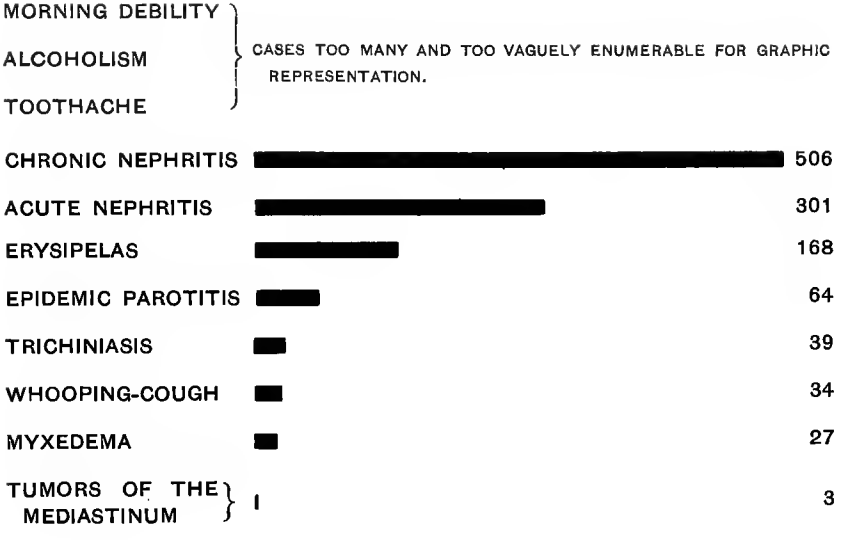

the same result. In such cases the edema usually appears rather suddenly, and is associated with other pressure symptoms, such as pains or dyspnea. Any reasonably careful physical examination should reveal the cause of such an edema. Lymphoblastoma (Hodgkin's disease) is probably the commonest cause of this type of edema. Rarer diseases, leading to the same kind of venous obstruction, are thrombosis of the superior vena cava or one of its main branches, chronic mediastinitis, and angina ludovici.

In *myxedema* there is often some true edema accompanying the myxedematous enlargement, whether in the face or other parts of the body. Such cases are sometimes mistaken for nephritis, especially if there chance to be some albuminuria and cylindruria.

Inflammation of the subcutaneous tissue due to anthrax, the septic cellulitis of insect bites, and actinomycosis are rare causes of facial edema.

In *typhus fever* (Brill's disease) a suffusion of the conjunctivæ is not infrequently associated with some edema about the eyes. *Drug eruptions*, such as an iodid of bromid rash, may be accompanied by marked edema of the face.

Finally, we must always remember the possibility of an unexplained edema, to which we sometimes give the name of *angioneurotic* in an attempt to cover up our ignorance. All that can be said of this variety of swelling is that it may be extreme, may appear suddenly, and almost always disappears within a few days.

Differential diagnosis of the different types just listed is usually easy, provided we know what to look for and give the time necessary to get a good history and to make a thorough physical examination.

Case 172

An electrician of thirty-three entered the hospital September 10, 1907. The patient was perfectly well up to two weeks ago, when he began to have puffiness and redness of the face and hands, more marked each morning, and accompanied by frontal headache. During the past week he has had several chills, and sweats more than usual. Yesterday he had a severe attack of vertigo and was for a moment completely blind. He did not fall. He has gastric distress and flatulence after meals and yesterday vomited once. He is very nervous, and in the last two weeks has lost 8 pounds.

Physical examination showed good nutrition, marked puffiness of the face, in which many muscles twitch involuntarily from time

to time. This twitching, he said, was never present until within two weeks. The chest was negative, save for a systolic murmur at the apex, not transmitted. The spleen was not palpable, abdomen negative. The white cells were 3400; hemoglobin, 100 per cent. Blood normal. Blood-pressure, 100 mm. Hg. Owing to the history of chills the blood was stained for malarial organisms, but none were found. At entrance everything seemed to point to uremia, but the urine and the condition of the blood-pressure seemed to negative this. He was given a hot bath and collapsed twenty minutes later. His temperature when first seen was 102.6° F.; pulse, 120. Both these fell to normal the next morning and remained so throughout the day. On the 14th the temperature again rose, as it had on the 12th.

Discussion.—The history of this case gives us no certain clue to diagnosis. The morning headache, with puffy face, twitching, and temporary blindness, hints strongly at a nephritis, but the negative condition of the urine and blood-pressure enable us to rule this out with reasonable certainty.

The type of fever is very unlike that of trichiniasis, and we have no pain and no blood changes characteristic of that disease.

Since we note that the patient had fever on the 10th, the 12th, and the 14th of September, we at once think of malaria. Nevertheless, it should be remembered that tuberculosis or septicemia occasionally produce a tertian type of fever. Only by careful blood examination can the possibility of malaria be settled. I recently saw a case of tuberculous peritonitis in which the fever was strikingly like that of tertian malaria.

Outcome.—On the 14th a considerable number of malarial parasites were found. Under quinin the symptoms all promptly disappeared, and by the 20th he was well.

Remarks.—How does the malaria account for the swelling of this patient's face and hands? I am quite unable to answer the question and I have seen no explanation of it in literature.

Case 173

A shoemaker of thirty-three entered the hospital August 29, 1911. Fourteen weeks ago the patient had toothache and swollen jaw. A dentist extracted the tooth and later lanced the jaw twice. The swelling continued, and twelve weeks ago the jaw was again lanced and poulticed. Ten weeks ago he was in a hospital and was operated on for abscess of the jaw. The swelling was then much reduced, but four days ago again increased. At entrance, August 29th, the whole face,

jaw, and neck were swollen and tender, especially on the right side. There was no definite fluctuation, save about a small ulcer in the center of the mass, where a crater-like depression was felt.

Physical examination, including the blood and urine, was otherwise negative.

Discussion.—The swollen jaw is like that accompanying toothache and due to alveolar necrosis and sepsis. The history shows that this was the first diagnosis made, but the continuance of the swelling, despite the dentist's best efforts, makes us surmise that this diagnosis may be wrong.

In 1911 the Esch bill prohibiting the use of phosphorus in the manufacture of matches had not been passed. Phosphorus necrosis of the jaw was, therefore, a possibility at the time when this patient was seen, but as he had had no dealings with phosphorus this was not seriously considered. Evidences of syphilis or tuberculosis must be looked for in any lesion in this part of the body.

In relation to syphilis, our best procedure is to take a careful history, do the Wassermann reaction, and, if necessary, try the therapeutic test. Tuberculosis can be diagnosed with any certainty only by histologic examination of an excised portion. It is not common in patients of this age and in this situation. The actual disease found in the outcome would probably be suspected by very few of us.

Outcome.—Operation showed a honeycombed mass of pus pockets. Microscopic examination of the discharges showed the organism of actinomycosis. The patient left the hospital in good condition on the 9th of September.

Case 174

A laundress of twenty-four entered the hospital February 22, 1909. The patient's family history and past history excellent, save for scarlet fever seven years ago. She woke up this morning to find the left side of her face and neck swollen. She had a slight headache and the bowels did not move. Her temperature was 99.5° F. Physical examination was negative, except for swelling and tenderness in the region of both parotids, especially the left.

Discussion.—What else could this be besides mumps? Obviously we have swelling of the glands, which are attacked by mumps. It remains to inquire what else can attack them. A septic parotitis not infrequently complicates typhoid fever, and is sometimes seen as an inexplicable complication of peptic ulcer, gastric or duodenal. Suppurative parotitis also occurs in acute and chronic endocarditis,

in cerebrospinal meningitis, small-pox, Asiatic cholera, yellow fever, and, rarely, in lobar pneumonia. Parotitis complicating heart infection should be regarded as part of a general sepsis, and a similar inflammation of the parotid may be found in other types of sepsis—for example, hepatic abscess.

If none of these causes can be found, any acute parotitis should be called mumps. If previous cases can be discovered and their contagion proved, the diagnosis is all the more certain, but we cannot always acquire such proof.

Outcome.—By the 3d of March the swelling was gone and she was allowed to go home, but kept in isolation for ten days more.

Case 175

An Italian barber of twenty-five entered the hospital April 6, 1909. Five days ago, while at work, he noticed that his eyes were swelling up. Later, he had a severe headache and pains all over his body. The next day he remained in bed, had no appetite, felt feverish, nearly vomited several times, and was constipated.

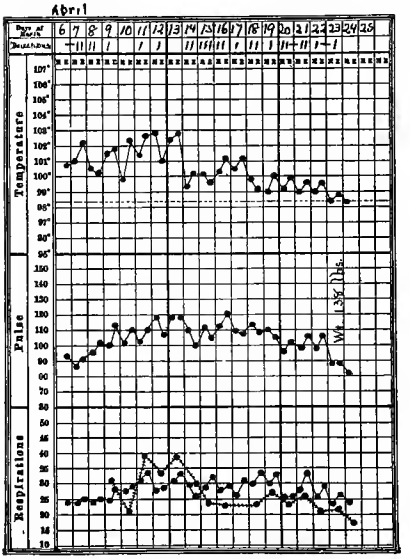

Fig. 144.—Temperature range in Case 175.

Physical examination shows good nutrition, eyelids red and swollen, conjunctivæ much injected and swollen. At the apex of the heart is a very harsh blowing, systolic murmur, transmitted to the axilla. No enlargement of the organ. Pulmonic second sound not accentuated. There is slight tenderness of the biceps and calves; slight edema of the legs. The urine is negative. The temperature is as shown in Fig. 144. The blood showed 12,300 leukocytes, 26 per cent. of which were eosinophils.

Discussion.—The initial symptoms are merely those common to many infectious diseases and peculiar to none, but the fever and leukocytosis associated with conjunctivitis, red and swollen eyelids, should make us very suspicious of trichiniasis. Since there is an eosinophilia, the diagnosis is rendered almost certain. What should

be said regarding the cardiac murmur? In my opinion, it is explained merely by the fever and represents simply one manifestation of the general infection. On the other hand, it is quite conceivable that the murmur may represent the effects of some previous endocarditis. The question can be decided by following the condition of the heart after the fever has subsided.

Outcome.—On the 12th of April the eosinophilia had fallen to 13 per cent., at which point it remained April 14th. About 30 drops

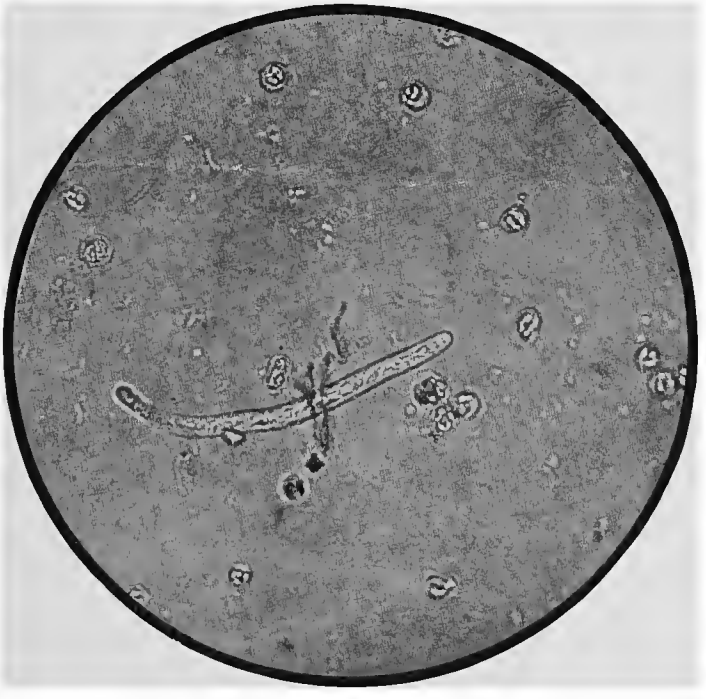

Fig. 145.—Embryo of *Trichinella spiralis* in blood laked with 3 per cent. acetic acid. Leukocytes and disintegrated red cells also are shown (× 800). (Reproduced by kind permission of Dr. T. C. Janeway, from the Archives of Internal Medicine, where it appeared in April, 1909.)

of blood were squeezed out of the ear into acetic acid solution, then centrifugalized, and the sediment examined. Two trichina embryos were found in this sediment without much difficulty. The patient had practically no symptoms or signs except dull aching of the muscles. This was present as late as the 19th of April, but he gained rapidly after that date and left the ward well on the 24th. It was later learned that he had eaten uncooked sausages two weeks before the beginning of this illness.

Remarks.—This method of demonstrating the trichiniasis embryo is of special importance when the patient refuses to consider it a favor for us to take out a piece of his muscle, or when the investigation of such a specimen is negative. In certain cases the embryo may be found in the blood without a long hunt (Fig. 145).

Case 176

On the same day, the 6th of April, 1909, an Italian tailoress of twenty-one (whose case was in all respects similar to that just narrated), was examined in the same way for trichinæ in the blood, but none were found. A teased specimen of muscle, taken from the calf, serial sections of this muscle were trichinæ finally found.
was then examined. It was also negative. Only on examination of

Discussion.—This case is inserted merely to show how difficult it sometimes is to find the trichiniasis embryo. The examination of serial sections is a task which not every pathologist will undertake.

Case 177

A laborer of thirty-two entered the hospital December 23, 1911. About five weeks ago the patient consulted his physician for swelling of the right cheek. The physician made a small incision and let out a cupful of pus. The cheek first looked like erysipelas, and was treated, after incision, with wicks and poultices. Later, the inflammation extended up toward the eye and the cavity had to be explored with the finger. After this the swelling went down under poultices and the patient did well until a week ago, when the edema returned. A dentist declared that the trouble did not come from the teeth. No general physical examination was made, but an *x*-ray showed pus in the antrum and some bone necrosis.

Discussion.—Clearly we are dealing with some suppurative process in the region of the cheek. It might be a local abscess or one originating in a tooth or in the antrum. Careful local examination alone can decide.

As a more remote possibility, however, we should remember that tuberculosis, syphilis, or malignant disease might be accompanied with a good deal of suppuration, and are sometimes mistaken for simple abscess. In the present case, however, the acute onset of the symptoms and absence of any deep inflammation or induration makes these three diseases impossible. It is in the relatively *chronic indurated* cases that the trio—tuberculosis, syphilis, neoplasm—should especially be borne in mind.

Erysipelas, which was considered here, is more superficial in its effects and the amount of redness should be greater.

The case demonstrates the need of *x*-ray examination in all doubtful swellings about this part of the body.

Outcome.—On the 2d of January, 1912, the wound was opened and the probe touched bare bone in the region of the antrum. The malar bone in the superior maxilla showed necrosis, which was chiseled away and a large opening made into the antrum. On the 6th of January the patient felt much better, though there was still some discharge. As he had had no temperature in two weeks' observation he was discharged.

The patient reported at the Out-patient Department, where the wound was treated, but January 22d there was still some edema of the flap, with irregular intervals of pain, lasting twenty to thirty minutes. On the 29th of January the swelling was less, and careful examination showed no reason to doubt the original diagnosis.

Case 178

A coachman of fifty entered the hospital October 30, 1911. Three nights ago he noticed swelling and tenderness of the right cheek. The next morning it was mostly gone, and that night it reappeared and was then accompanied by redness. Yesterday the swelling almost closed his right eye. He has had no pain and no burning sensations. He attributes the trouble to a bad second right lower molar, which has been tender for a year or two. His temperature has been normal until last night, when it rose to 101° F.

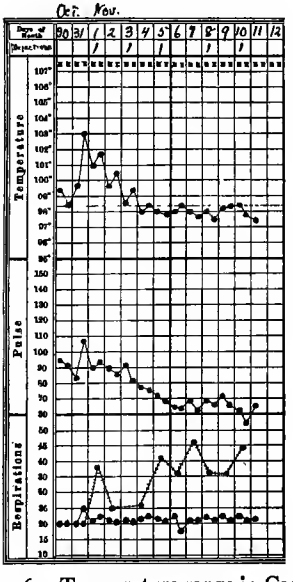

Fig. 146.—Temperature range in Case 178.

Physical examination is negative, save for a rough-blowing systolic murmur at the apex of the heart, transmitted to the axilla, a scar in the appendix region, and a marked swelling of the whole right side of the face, closing the right eye. The color was now bright red, with a sharp border along the right side of the nose, and in the temporal region an area was

indurated and slightly hot. Temperature was as in Fig. 146. On the 31st he had a chill and his temperature rose to 104.4° F. The right ear was now swollen and the left side of the face became involved.

Discussion.—In the early stages of this disease, before the sharp line of demarcation, the deep red color, and the elevation of the advancing margin have made their appearance, the symptoms might be attributed, as in this case, to a bad tooth. The true diagnosis, erysipelas, rests upon the local features just mentioned, upon the presence of marked constitutional symptoms, the history of previous attacks, the situation near the nose, eye, or ear, and the absence of any deeper local cause of suppuration.

Outcome.—On the 3d of November the swelling was subsiding, and by the 7th all redness and swelling were gone. He left the hospital on the 11th.

Case 179

A Russian storekeeper of forty-five entered the hospital January 6, 1910. Family history negative. Had rheumatism in his right leg for eight years. Last August he was in a runaway, broke his left forearm and injured his head. Denies venereal disease. Is not alcoholic.

Five weeks ago his entire head and the upper part of his chest became red, and his head swelled up so that he could not see. This was accompanied by a great edema of the scrotum. The left hand and fingers have been stiff since his accident, and his right hand and arm and both legs, from the knees down, have been gradually getting stiff for five weeks. They have never been swollen. For three weeks he has not been able to walk. His physician has no knowledge of any spinal injury. He has had no pain, no headache or backache, but has lost 28 pounds since his accident eight months ago. For the past month his sleep has been poor and he has been very nervous.

At entrance there was no fever, no edema, and physical examination was altogether negative. After considerable persuasion he was enabled to walk. By the 12th of January he walked about the ward and received Zander treatment. He complained enthusiastically of many weird symptoms, such as fever in his teeth, blood in his belly, and so forth, and, although he improved considerably, went home, dissatisfied, on the 25th.

Discussion.—This is one of those curious cases in which the diagnosis of hysteria or angioneurotic edema represents the best that we can do, but they never should satisfy us or make us believe that

we have got to the bottom of the trouble. Mediastinal pressure was at first suggested by the marked swelling of the entire head and upper chest. Local inflammatory causes are excluded by the absence of fever and leukocytosis. The swelling of the scrotum makes it clear that no local pressure in the mediastinum will account for the edema unless we suppose two separate causes.

There is much in the case to suggest a traumatic neurosis or traumatic hysteria, but the interval of time between the runaway accident and the beginning of these symptoms seems sufficient to exclude this.

By the accumulation of negative evidence against the more exact and well-known causes for edema, we come down to hypotheses about the vasomotor system, hypotheses such as have been expounded at length by Solomon Solis-Cohen in various volumes of the "Transactions of the Association of American Physicians." Vasomotor ataxia, as Dr. Solis-Cohen calls it, is perhaps as good a name as any for many mysterious symptom complications, of which the present cause is an example.

Outcome.—Dr. E. W. Taylor considered the case one of hysteria.

Case 180

A Greek pedler of twenty-five entered the hospital March 21, 1910. He was never sick until four years ago, when he had erysipelas. His habits are excellent, and he denies venereal disease. Three weeks ago he "caught cold." Eight days ago his face became swollen and the next day his feet also. At the beginning of the illness he had a chill, felt feverish, with slight headache and pains in his legs and in the soles of his feet. His bowels have not moved for four days. He has had several nosebleeds and has bled from his ears.

Physical examination showed edema of the face, legs, and feet. The heart's apex was in the fifth space, $2\frac{1}{2}$ cm. outside the nipple, the right border 5 cm. in the median line. Sounds snapping in quality, aortic second accentuated, no murmur; the pulse apparently of increased tension and notably slow, 50 to 60. Systolic blood-pressure, 150. Otherwise physical examination was negative. The urine averaged 40 ounces, slightly smoky in color. The specific gravity was 1025 on the average; albumin, 1.4 per cent. There were many casts, mostly hyaline, with varying amounts of fat and epithelial cells adherent. The blood showed slight achromia, 78 per cent. hemoglobin, no leukocytes. In four days the edema was gone, under milk diet, daily hot-air baths, and 1 ounce of magnesium sulphate every morn-

ing. Toward the end of his stay the edema persisted only in the lungs and on the top of his head.

Discussion.—What else could this be but acute nephritis? We have the sudden appearance of edema, with evidence of infection, bleeding at the nose and ears, anemia, slight hypertension, and the classical urine of acute nephritis.

I have seen a classical picture much like this in cerebrospinal meningitis, but in that case the brain symptoms soon become more marked. Nevertheless, the diagnosis of uremia was actually made in this case and only the autopsy sets us right.

Trichiniasis would account for the edema, the pains in the legs, and the evidence of infection. It is to be excluded chiefly by the negative blood examination, the significant urinary findings, and the course of the case.

Outcome.—On the 10th of May, 1913, and on the 11th of March, 1914, he reported at my request and declared himself perfectly well, although it took him a year to recover his full strength. He went to work three months after he left the hospital and has not had to give up since. At the present time his blood-pressure is 125 mm. Hg. and his urine is normal.

Case 181

A colored laundress of thirty-three entered the hospital February 9, 1910. Her family history was negative. Five years ago she had a red rash all over her body, a severe headache, and falling of the hair. Since that time she has had various skin lesions on her face. In October, 1909, she caught cold and had a severe sore throat and cough. She was unable to swallow anything but milk and eggs on account of pain in her throat. She was in bed four weeks. For the past two weeks she has been hoarse, and for ten days has had difficulty in breathing, with attacks of suffocation, lasting ten to fifteen minutes. She weighed 130 pounds in October, 106 pounds in December, 116 pounds now.

Physical examination was negative, save for the evidences of laryngeal stenosis. There was marked infiltration of the left arytenoid and of the left half of the larynx. Dr. H. P. Mosher considered the condition syphilitic. The Wassermann reaction was positive. Under daily inunctions of mercury and moderate doses of iodid of potash the condition of the larynx rapidly improved, and on the 17th of February the dyspnea was slight. On the 21st she was out of danger and went home.

May 18, 1910, she returned, having been at the Out-patient Department since her previous stay in the hospital, with more or less trouble all the time. Six days ago she was awakened in the night with earache, toothache, and pain in the throat, and the next morning the whole throat was swollen, as it now is.

Physical examination showed the cardiac apex 11½ cm. from midsternum, 2 cm. outside the nipple. Pulmonic second accentuated. No murmur. An irregular area of discoloration was seen on the outside of the right leg, from the hip to the dorsum of the foot. The whole face was somewhat swollen. From the right side of the lower jaw, reaching down on the neck, there was an area of induration, 10 by 7 cm., very tender, and a small area of fluctuation was made out, anteriorly to the sternomastoid muscle. The temperature ranged as in Fig. 147. Blood-pressure, 112 mm. Hg. Blood and urine normal. The laryngeal stenosis was now much less troublesome, and she suffered more from dysphagia than from dyspnea. She was salivated and her gums swollen and tender.

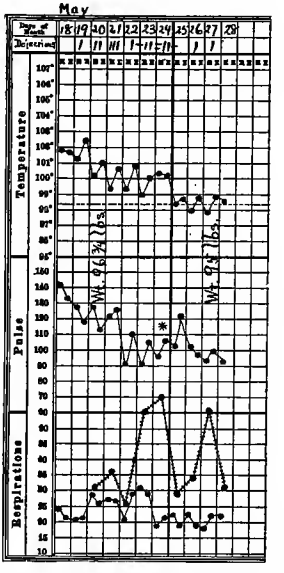

Fig. 147.—Temperature range in Case 181.

Discussion.—The hoarseness and attacks of suffocation following a syphilitic infection leave no reasonable doubt that at the time of the first hospital visit the patient suffered from laryngeal syphilis. At the time of the second hospital visit we have apparently a general cellulitis, representing one of the transitions from the most superficial type of sepsis (erysipelas) to the deeper and more localized infiltrations of pus. The facial edema in this case is of the same type seen in erysipelas. Presumably there is a burrowing of pus deep in the tissues of the neck and face, the type of lesion often called deep cervical abscess or *angina ludovici*.

Just what connection there is between this sepsis and the previous syphilis I do not know. Probably the syphilis has predisposed the patient to septic infection.

Outcome.—On the night of the 20th of May an abscess broke somewhere in her throat and she spat up pus. After that she was more comfortable, and was referred on the 28th to the Out-patient Department.

Case 182

A letter-carrier of forty-six entered the hospital December 2, 1911. The patient had scarlet fever in infancy; otherwise he has been well and has an excellent family history. Denies venereal disease. Takes no alcohol.

Eight days ago, while he was driving his letter-carriers' wagon, he got his feet wet, and next morning his legs were swollen and his eyes puffy, and he had some shortness of breath, with a slight dry cough. His appetite, bowels, and sleep continued normal. For six months he has noticed slight dimness of his eyesight.

Physical examination shows heart's impulse at the sixth rib, 2 cm. outside the nipple, 14 cm. from median line. Aortic second was accentuated. Blood-pressure, 180 mm. Hg., systolic; 110 mm. Hg., diastolic. No cardiac murmurs. Lungs and abdomen negative. Slight edema of the lower legs and ankles. Wassermann reaction negative. Urine 40 ounces in twenty-four hours, with a specific gravity of 1020 and very slight trace of albumin, occasional hyaline and granular casts, with now and then a red blood-cell adherent. Throughout his stay in the hospital, which lasted until December 13th, he felt entirely well.

Discussion.—The history is a good example of the quite unconscious sophistry whereby patients continue the ancient tradition that wet feet have something to do with kidney disease. The more one studies the histories of cases of this type, the less one is inclined to believe that cold and wet have any considerable part in their etiology.

Although the onset is here acute, the condition of the urine and blood-pressure makes it clear that we are dealing with a chronic nephritis, possibly one that originated in the scarlet fever of the patient's infancy. Acute nephritis is a rare disease, and in our hospital records is steadily becoming rarer. This means, of course, that we do not see the patients, as a rule, during the acute stages of their disease, but only in the acute exacerbation of a chronic process or in the frankly chronic stages of the disease. Since blood-pressure measurements have been made a routine, most of the cases formerly called acute nephritis are now labeled chronic.

It seems to me of interest that this patient felt entirely well throughout his illness, and would never have sought medical advice but for the swelling of his face and legs, which naturally alarmed him. Imagine now that the edema had been absent, as in many cases of nephritis

it is, the patient would then have had no knowledge of his disease and would not have consulted a physician. This is presumably what happens in the majority of cases of acute nephritis.

Outcome.—July 6, 1914, the patient writes that he is feeling pretty well, working daily as mail collector, and that his water has recently been examined and found to be normal.

CHAPTER IX

HEMOPTYSIS

THE spitting of pure blood in any considerable quantity means pulmonary tuberculosis in the vast majority of cases, no matter what other symptoms are or are not present. We should always assume such a symptom to be due to tuberculosis until it is proved to the contrary.

But we must distinguish between the raising of pure blood in considerable quantity (a teaspoonful or more) and the raising of streaks of blood mixed with mucopurulent sputum. Blood-streaked sputum is often due to other causes not tuberculous, although it may also occur in tuberculosis itself.

The commonest mistake in relation to true hemoptysis, as above defined, is the assumption that it is not tuberculous in origin merely because the lungs show no abnormal signs and the patient feels perfectly well. This is just what we should expect in early phthisis. The majority of cases of hemoptysis, examined within a few days of the attack, show absolutely no signs in the lungs and the patients feel perfectly well, but if they go on living and working as before the occurrence of the attack, tuberculosis will probably show itself in a few months in an unmistakable form. This advance of the disease should be forestalled by putting the patient, immediately after the hemoptysis, under treatment for incipient tuberculosis, without waiting for absolute proof that the blood spitting is really tuberculous in origin.

Aside from the group of cases just referred to in which blood spitting is the first symptom of tuberculosis, and comes, as it were, out of a clear sky, there is the much less important group of cases in which blood is raised during the advanced and obvious stages of phthisis. Here it is merely worth while to say that such blood spitting is not necessarily or often a bad symptom. The patient need not feel that he is any worse after it or by reason of it, for occasionally a large hemoptysis leads straight on to acute tuberculous pneumonia and a rapidly fatal termination, but in the vast majority of cases the patient is as well within ten days after the hemoptysis as he was before it.

Causes of Hemoptysis in Prussian Soldiers

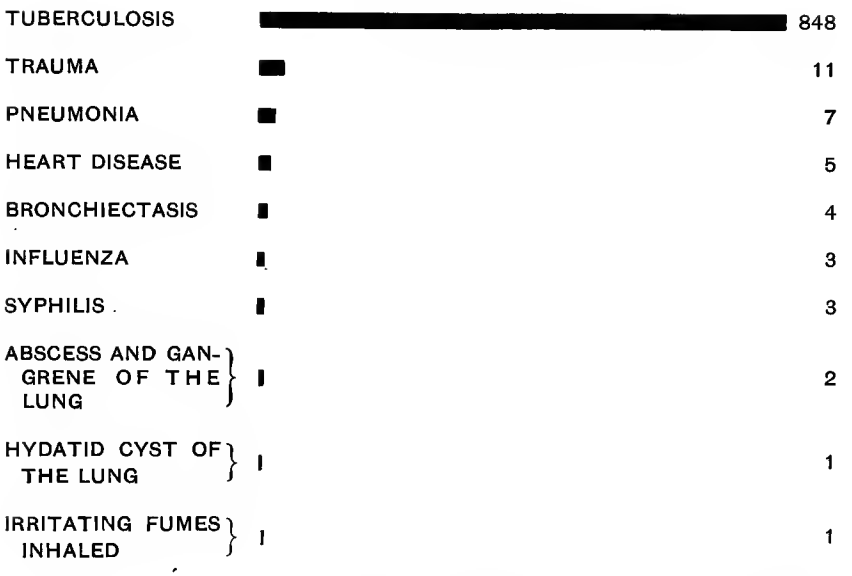

(F. Stricker, Festschrift zur 100-Jährigen Stiftungsfeier des Med. Chirurg. Friedrich-Wilhelms-Instituts, page 183.)

Causes of Hemoptysis

Massachusetts General Hospital

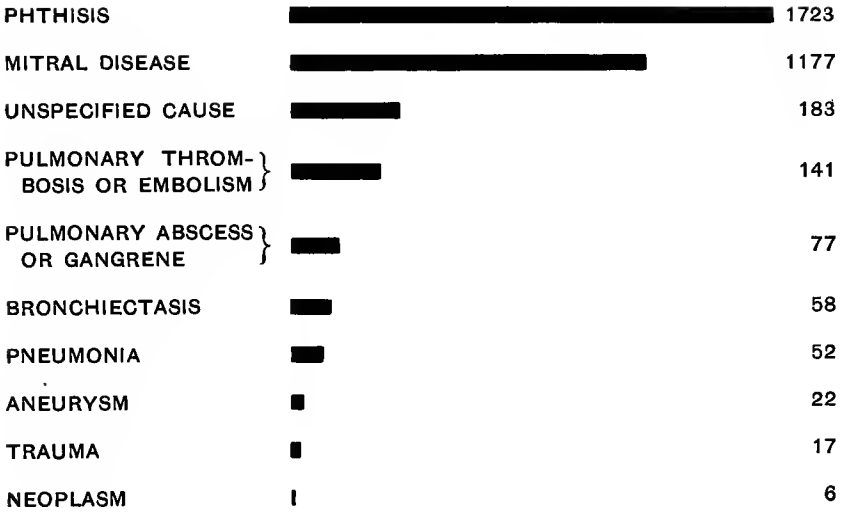

Next to pulmonary tuberculosis, but a very poor second in relation to it, comes pulmonary infarct as a cause of hemoptysis. Pulmonary infarct is usually the result of mitral disease, but may occur in any type of heart disease with failing compensation. It is generally recognized without difficulty, because of the presence of a well-marked heart lesion and of preceding or coincident symptoms of pulmonary enlargement (cough, dyspnea, orthopnea, scattered râles, hydrothorax). Occasionally both phthisis and mitral disease occur at the same time. It may then be very difficult to decide which is the cause of the bleeding.

In the United States there are no other common causes of hemoptysis. All the chronic diseases of the lung, such as bronchiectasis, abscess, gangrene, neoplasm, syphilis, may in exceptional cases produce hemoptysis, but the total number of such cases is very small. This is well shown in diagram, p. 433. In Japan the parasitic lung fluke is a not infrequent cause of hemoptysis, and upon our Pacific coast Japanese immigration has now made this type of hemoptysis a possible experience for physicians in that part of the country.

Thoracic aneurysm is not infrequently associated with hemoptysis. This is usually a result of congestion of the tracheal wall through direct pressure of the aneurysm outside. Less frequently it is due to an actual leaking of the aneurysm itself through a perforation in the tracheal wall. Luckily for all concerned, it is rare to see an aneurysm kill by suddenly bursting into the respiratory tract.

Small amounts of blood, occurring in streaks or mixed diffusely with mucopurulent sputum, are frequently seen in patients who smoke excessively and have acquired the habit of hawking to remove pharyngeal secretions. Such actions now and then scratch and irritate the throat enough to produce a streak of blood. Obviously, anything else that makes the patient cough or hawk violently may give us blood-streaked sputum in the same way.

Occasionally an unhealthy condition of the gums, with or without an obvious stomatitis, produces the same result, and all hemorrhagic diseases, such as purpura, scurvy, leukemia, may show blood in the sputum as well as elsewhere.

Case 183

A bell-boy of seventeen entered the hospital July 13, 1908. The patient's father died of erysipelas four and one-half years ago. All the other members of his family are well. There is no tuberculosis in the family. The patient had measles when three years old, scarlet

fever at four, immediately followed by whooping-cough. Last summer he was sick for three weeks with pain in the left chest, fever, cough, and hemoptysis. Last winter he was in bed three weeks with a similar trouble. Two years ago he weighed 93 pounds; now, 85 pounds.

For a month he has been in bed with pain in the front of the left chest, worse on deep breathing. Three times in this month he has raised about half a cupful of blood, and between these times he has raised a small amount of thick, greenish-yellow sputum. He has had fever without chills. As long as he can remember he has had dyspnea and palpitation, but has been otherwise well.

Physical examination showed poor nutrition, pallor, normal pupils, glands, and reflexes. The heart's impulse seen and felt in the fifth interspace, nipple line, 3 inches from midsternum. Right border of dulness $\frac{3}{4}$ inch from midsternum. At the apex there was a presystolic thrill, and a long, rough presystolic murmur, ending in a sharp first sound. There was no second sound at the apex, its place being taken by a short, diastolic murmur. Just inside the apex both these murmurs were more distinct. The pulmonic second sound was accentuated. Physical examination was otherwise negative. No temperature in a week's observation. Urine negative. Hemoglobin 70 per cent., stained specimen showing moderate achromia. The sputum showed no tubercle bacilli. Tuberculin was injected subcutaneously—on the 16th, $\frac{1}{2}$ mg.; on the 18th, 5 mg.; on the 20th, 10 mg. No reaction followed. The patient's family physician states that he was a blue baby.

He did well while in the ward, and left on the 21st, having gained 4 pounds in the week. On the 15th of February, 1909, he returned to the hospital, having felt well until he got into a fight with the cook at the Waverley Convalescent Home and was chased about and had to be put to bed. He soon recovered and went back to work. Two months ago, after a heavy day's work, he began to cough and raised about a wineglassful of blood. That night he had marked orthopnea. After about two weeks of rest he went back to work again, though still short of breath, but after a day and a half he had to give up on account of dyspnea and pain in the chest. These symptoms have continued ever since and been associated with indefinite pains about the right knee. There has been no hemoptysis for a month, but the cough has been rather persistent. His weight is now 93 pounds. Appetite and bowels in good condition; sleep disturbed by headaches.

At this time the heart's apex extended $1\frac{1}{2}$ cm. outside the nipple line and the dulness extended 3 cm. to the right of midsternum.

The auscultatory conditions are shown in Fig. 148. The heart was regular. Pulmonic second accentuated and doubled. The lungs showed at entrance high-pitched squeaks, scattered in each lung, otherwise physical examination is normal, including the blood and urine. There was no temperature in two weeks' observation. The boy gained 5 pounds. Under rest, magnesium sulphate, ½ ounce in concentrated solution, tincture of digitalis, 5 minims four times a day, and an occasional dose of aspirin, 10 gr., the boy rapidly recovered, and by February 26th was ready to go home. Lungs entirely negative.

He re-entered the hospital for the third time March 3, 1909, only five days from the time when he last left it. March 2d, while dressing,

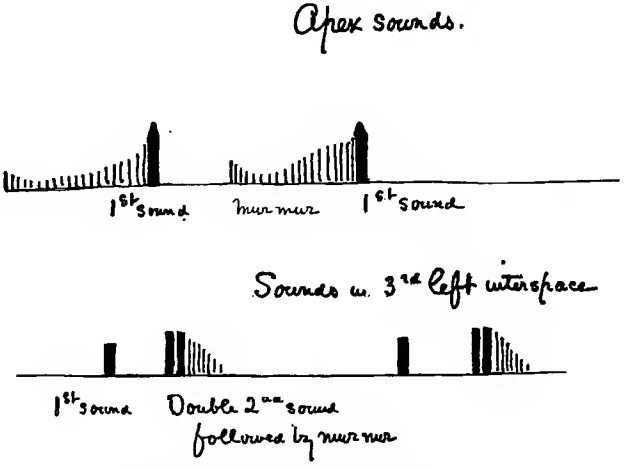

Fig. 148.—Diagram of heart sounds in Case 183.

he began to cough up blood. It appeared at this time that the patient's mother is a drunkard, that there is much trouble at home, and that the boy himself takes some whisky. This time the heart was irregular, and there was some arthritis of the ankles. He remained in the hospital five weeks and gained 12 pounds. On the 6th of March he spat up a cupful of fresh blood. Immediately after this the breathing was harsh and noisy throughout the left chest, feeble throughout the right, and accompanied by crackles. In the right axilla the heart's sounds were very loud. The raising of blood continued until the 11th. At this time a capillary pulse and suggestion of Corrigan pulse were noticed, and he had a good deal of precordial pain, increased by exertion. The diminished breathing in the

right lung was still present March 30th, but no other abnormalities were detected.

November 4, 1909, he entered for the fourth time, having been at work in July and August as a bell-boy. Three weeks ago he began to have hemoptysis as before, and has had four hemorrhages, about a cupful at a time. For the last two days he has been very feverish, ached all over, and had urgent dyspnea. The heart's impulse is now 4 cm. outside the nipple line, right border 5 cm. from midsternum. Otherwise his condition is practically the same as before, except for evidence of scabies. The temperature is as in Fig. 149. Blood and urine normal.

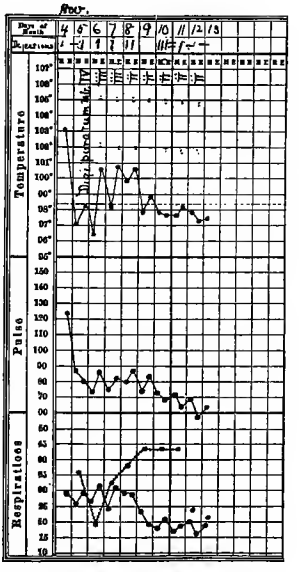

Fig. 149.—Temperature record in Case 183.

Discussion.—The condition of the heart is typical of mitral stenosis, and under observation the patient had more than one attack of arthritis, presumably of the rheumatic or streptococcic type. There have been no signs in his lungs but such as might have been accounted for by passive congestion, the result of his mitral disease. The surprising thing is that he should have so many attacks of hemoptysis without other signs of failing compensation. It is also somewhat remarkable that he should have fever and pain in the chest with each of his attacks, yet this might be explained as a protein fever due to absorption of blood-clot in the infarcted lung.

During his stay in the Massachusetts General Hospital we did our best to discover any evidence of tuberculosis. No bacilli could ever be found in the sputum, and no reaction followed the injection of a large dose of tuberculin. His prompt gain in weight and strength, under conditions not especially favorable for tuberculous lungs, also argued against the existence of any phthisis, yet his cough persisted in a rather inexplicable way. My diagnosis was of mitral stenosis with regurgitation, without lung disease. No doubt was entertained upon this point when he left my wards.

Outcome.—February 1, 1911, he came to the Municipal Hospital for Tuberculosis, in Burroughs Place, Boston, and there a very different family history was obtained. He stated that his step-father

died of pulmonary tuberculosis a year previous, that is, a year after he left the Massachusetts General, and a sister of the same disease two years ago, the same year in which he left us. An examination made by Dr. N. K. Wood showed extensive signs in both lungs—namely, dulness, bronchovesicular breathing, increased fremitus, and a few râles from the top of each lung to the midscapular behind and third rib in front. The sputum was examined and reported as positive for tubercle bacilli. February 16, 1911, he was admitted to the Mattapan Municipal Hospital for Tuberculosis and discharged April 7, 1911, with a diagnosis of "*mitral stenosis, probably not tuberculous.*" At this time the signs were diffuse upon the left and absent upon the right side. Three negative sputum examinations were recorded.

He re-entered this hospital on the 12th of July, 1912, and stayed a month. After 2 mg. of tuberculin O. T. his temperature rose to 100.8° F. The local and constitutional reactions were considered typical. Except for this fever, however, he had no other rise of temperature. The physical examination showed rather more definite signs at the left apex.

On the 7th of August, 1912, Dr. S. W. Ellsworth *x*-rayed his chest at the Boston City Hospital, and reported extensive changes involving the upper two-thirds of each lung and interpreted as tuberculous. In view of this, the discharge diagnosis, August 15, 1912, was "*tuberculosis with mitral stenosis.*" Later he went to Utica, New York. In April, 1913, a letter from a friend of his states that "his health is just about the same." The records of the Associated Charities states that he lost another brother of tuberculosis in 1912. On the whole, the diagnosis must remain in doubt, but I am inclined to believe that he had both tuberculosis and mitral stenosis.

Case 184

A plate-printer of twenty-one, born in Russia, entered the hospital December 18, 1909. The patient's father died of cancer at fifty-six; otherwise his family history and past history are good.

Three years ago he began to cough. Eight days ago, after straining himself with lifting, he began to raise blood and has raised it every day for the past week, the amount being ½ cupful three days ago in the morning and a like amount this morning. He has lost no weight, has never coughed up blood before, has an excellent appetite, no pain, and feels generally well.

Physical examination shows good nutrition and is otherwise negative save as relates to the left lung, at the apex of which there is slight

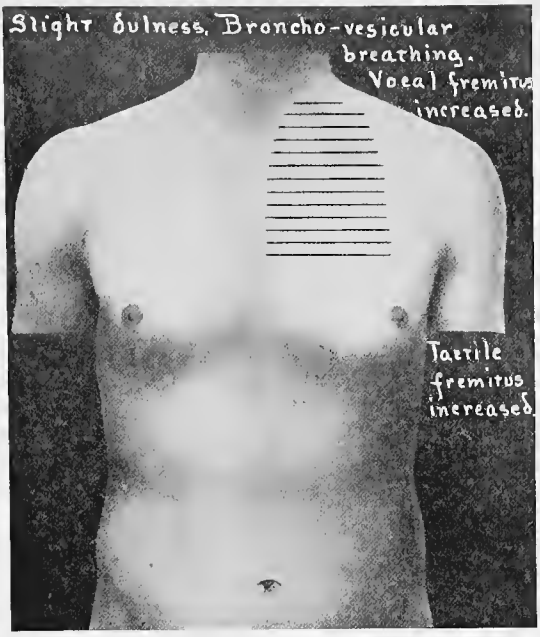

Fig. 150.—Chest signs in Case 184.

Fig. 151.—Chest signs in Case 184.

dulness, bronchovesicular breathing, increased voice, and fremitus extending down to the second rib (Figs. 150 and 151). The

temperature as in Fig. 152. Blood and urine normal. The sputum was examined eight times and no tubercle bacilli found except in one small mass on the 23d of December, when the organisms were seen in very small numbers. Five examinations after that showed no bacilli.

Discussion.—Sudden hemoptysis in good health at the age of twenty-one generally means phthisis. This assumption is verified by the physical signs present at the top of the left lung. Such signs would have been of no special significance had they occurred at the top of the right lung. Their association with the slight fever shown in Fig. 152 makes them sufficient evidence for a presumptive diagnosis of phthisis.

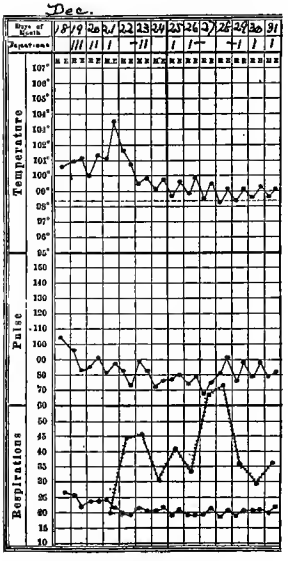

Fig. 152.—Chart in Case 184.

The sputum examination would seem to settle the matter beyond doubt, but I cannot feel quite certain upon this point. When the laboratory observer reports tubercle bacilli present he should, in strictness, say "acid-fast bacilli, having the usual morphology of tubercle bacilli." It has been shown in recent years that other acid-fast organisms besides the tuberculous are not very uncommon (streptothrix group).

In doubtful cases we should be more ready to make sputum inoculation into animals. Nevertheless, it seems to me there is no very great doubt that this patient has tuberculosis. He has none of the other well-known causes of hemoptysis, and there is no other disease of anything like the same commonness which could explain his symptoms.

Outcome.—The hemoptysis ceased on the 29th. It began again on the 10th of January and continued until the 16th, and in small quantities off and on after that. He gained 25 pounds during his three months' stay in the ward, A few râles were heard over the affected area, January 22d, February 5th, and February 19th. March 14th he went to Rutland Sanitarium. In a letter, sent April 20th, 1913, the patient states that he is feeling fine and is at work.

Case 185

A clerk of twenty-one entered the hospital March 16, 1910. A week ago the patient felt tired, feverish, and short of breath. The

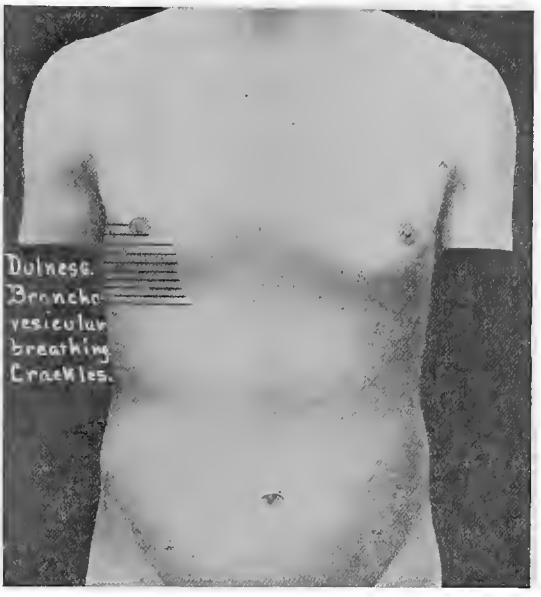

Fig. 153.—Chest signs in Case 185.

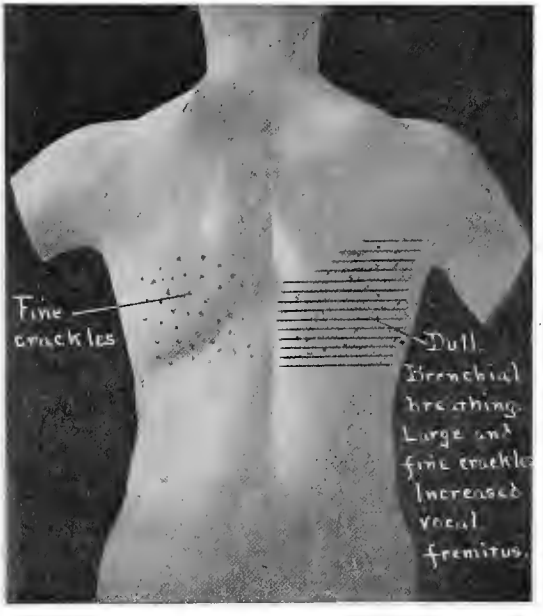

Fig. 154.—Chest signs in Case 185.

next day, Thursday, he began to vomit and continued for three days. On Friday he began to raise bloody sputa, had a pain in the right side

of his chest, and an eruption like cold sores on his eyelids and about his nostrils.

Physical examination shows fair nutrition. Heart's impulse extends 1 cm. outside the nipple, in the fifth space; heart otherwise negative. Lungs as in Figs. 153 and 154. The abdomen is negative save that the liver dulness extends 8 cm. below the ribs, where a tender edge was indistinctly felt. Temperature as seen in Fig. 155. The blood showed at entrance 18,000 leukocytes, and on the 26th, 20,500. The urine showed a slight trace of albumin and an occasional granular cast; otherwise negative. On the 26th the patient seemed perfectly well, and, in spite of his high leukocyte count, he was discharged to the Convalescent Home.

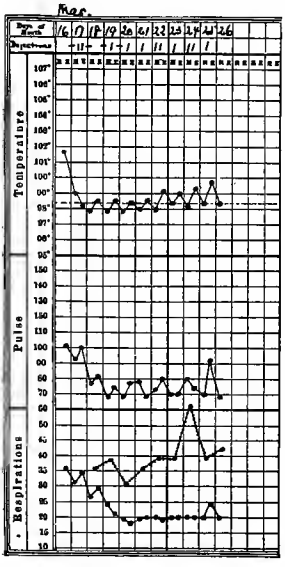

Fig. 155.—Chart of Case 185.

Discussion.—The hemoptysis in this case began with all the evidences of acute infection, especially the vomiting and the herpes. The heart showed evidence of dilatation, perhaps from infectious weakening of the muscle; the lung signs are on the right side, and may account wholly or in part for the position of the liver, 8 cm. below the ribs. The physical signs are those of solidification, and the remaining question is whether we are dealing with a tuberculous pneumonia or an ordinary pneumococcus infection of the lung. These two diseases are notoriously difficult to distinguish, at times actually impossible, until we have been able to follow the case for a number of days or even weeks. Since the pneumonic signs of the two diseases may be identical, diagnosis depends upon the question whether tubercle bacilli later appear, and whether the lung signs clear up as they ordinarily do in pneumonia or persist as they do in phthisis. The persistence of leukocytosis suggests either a tuberculosis or a developing empyema or an unresolved pneumonia; but, as the physical signs were negative at the time of his discharge, we threw out all these possibilities and considered him well in spite of his leukocytosis.

Outcome.—April 16, 1913, the patient writes that he is perfectly well, and has been so since he left the hospital. In view of this outcome, we may feel confident that a leukocytosis in itself is no reason for keeping a patient in the hospital in the fear that an empyema may develop.

Remarks.—Why do certain cases of pneumonia begin with hemoptysis instead of the ordinary rusty sputum? No answer, so far as I am aware, has ever been given.

Case 186

A housewife of twenty-three, with a good family history and past history, entered the hospital March 2, 1912. Three weeks ago the patient began to lose appetite. Two weeks ago she felt a little weak, but still worked steadily. Eight days ago, while at work, she raised several mouthfuls of bright blood. Since then she has had slight

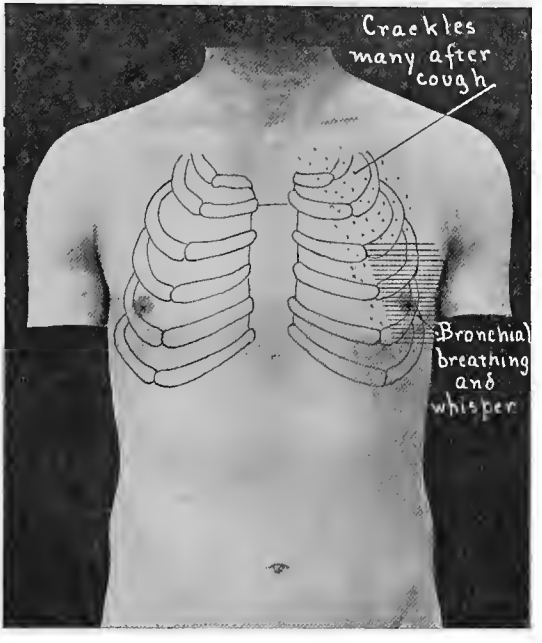

Fig. 156.—Chest signs in Case 186.

morning cough, with a constant sputa, headache, and fever, ranging between 101° and 103° F. She has had no pain, dyspnea, or sweats. She has lost no weight.

Physical examination showed fair nutrition, moderate cyanosis, rapid, shallow breathing, physical signs as in Figs. 156 and 157. Examination was otherwise negative. The crackles, March 2d, were very extensive and very coarse. Through and behind them evidence of solidification was clear in the left front, but hardly any in the corresponding situation behind. The number of white cells was never elevated, March 2d being 9000; March 7th, 8000; March 14th, 10,000.

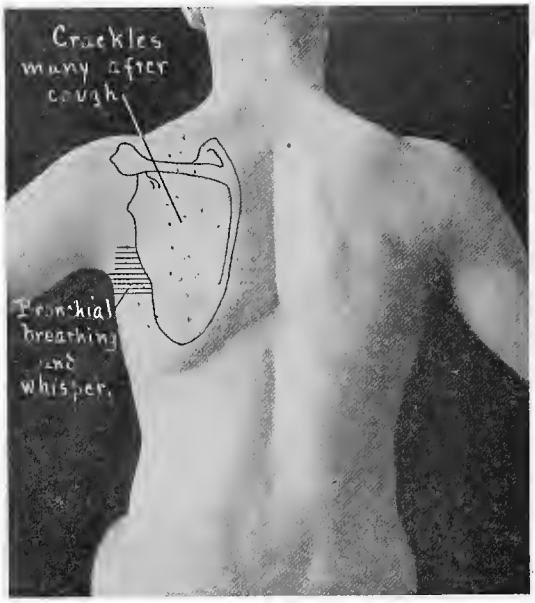

Fig. 157.—Chest signs in Case 186.

Hemoglobin, 90 per cent. Urine normal. Systolic blood-pressure, 110. Temperature as seen in Fig. 158. On the 2d of March I thought the case more probably pneumonia than tuberculosis, but on the 11th tubercle bacilli were found in abundance in the sputum, and the patient was transferred on the 15th to the Somerville Hospital.

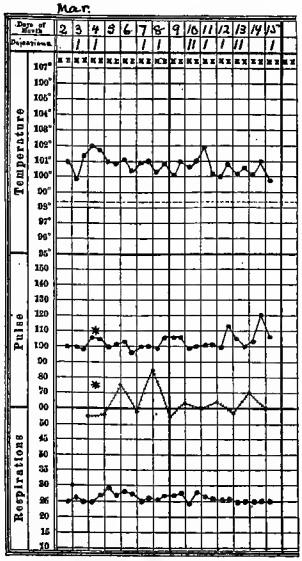

Fig. 158.—Chart of Case 186.

Discussion.—This case makes a good contrast with that last discussed. The onset and the pneumonic signs are not much different. The low white count, however, in a patient not desperately ill, makes tuberculosis more probable than in the last case. Nevertheless, the diagnosis could not be other than pneumonia until the sputum examination finally changed it to tuberculosis.

The point of special interest is that the patient worked steadily until eight days ago, and had no illness at all until three weeks ago.

Case 187

A sign painter of thirty-seven entered the hospital April 15, 1910. The patient has one sister now sick with tuberculosis; otherwise his family history is good. He had bronchitis when sixteen, pneumonia at twenty-two, syphilis at twenty-nine, "rheumatism" at thirty-two. He has always been very nervous. He has been a hard drinker for ten years, averaging three whiskies and six beers a day; twenty cigarettes a day. Six weeks ago he caught cold, and felt weak and



Fig. 159.—Heart sounds at the apex.

tired. Thirteen days ago he began to cough and have pain in both sides of his chest. Five days ago, while working, he coughed up a mouthful of bright blood and ever since then has raised blood and greenish material, 1 or 2 ounces a day. At the same time that the cough began he became short of breath, especially at night, when he needs two pillows. He gave up work eleven days ago. He has lost 8 pounds in three months.

On physical examination the patient was well nourished, pupils irregular and reacting slowly to light; tongue tremulous, brown coated;

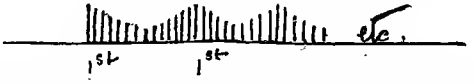

Fig. 160.—Heart sounds at the third left interspace. The point "1st" indicates that part of the cardiac cycle where the first heart sound should be. No first sound is heard. The murmur is continuous, with a systolic accentuation.

general enlargement of the lymph-nodes. The apex impulse was not seen, but was felt in the fifth space, $3\frac{1}{2}$ cm. outside the nipple line, $13\frac{1}{2}$ cm. from midsternum. At the apex a late systolic murmur was audible (Fig. 159). In the left third interspace, near the sternum, was a continuous murmur and thrill, with a systolic accentuation (Fig. 160). No heart sounds were audible in this situation. On the right side of the sternum, in the fifth space, a ringing second sound could be heard, which grew fainter toward the base of the heart. There was no pericardial friction, but many rubs, squeaks, and crackles, scattered over both fronts. By percussion the heart seemed

considerably enlarged to the right of the sternum. Systolic blood-pressure was 115. The systolic portion of the murmur above described was audible over the greater part of the back, especially on the right side. The backs of the lungs showed scattered squeaks and crackles, similar to those heard in front, but there was no evidence of fluid or solidification. The patient showed no fever in three weeks' observation. Blood and urine normal. Four examinations of the blood-stained sputa showed no tubercle bacilli and nothing of note.

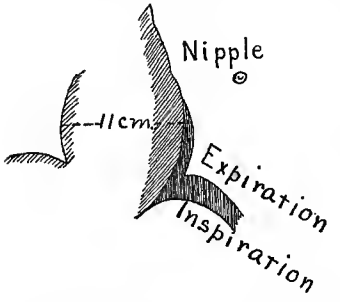

Fig. 161.—Sketch on fluoroscopic screen. Tube at a distance of 7 feet. Notice the absence of any bulge on the left border, and its position with relation to the nipple.

By the 27th the râles had disappeared from the chest and the patient was quite comfortable. At this time *x*-ray (Fig. 161) showed that the heart was not enlarged.

Discussion.—Syphilis, rheumatism, alcoholism, and possibly plumbism are suggested by this patient's history. In favor of tuberculosis as a cause of his hemoptysis are the cough and dyspnea, the family history of tuberculosis, and the acute onset of the trouble. In favor of syphilis are the Argyll-Robertson pupil and the glandular enlargement. The physical signs are not characteristic, though more like those of pulmonary edema than of any other disease.

With so small a heart it does not seem to me at all probable that syphilitic aortitis, the commonest form of cardiac syphilis, is present.

Pulmonary stenosis or mitral disease, which were among the diagnoses suggested in the case, should give a very different *x*-ray picture from that which is shown in Fig. 161.

Moreover, none of these diseases has any right to give a continuous murmur, lasting through the whole cardiac cycle. I think it would be of some interest if I record some of the opinions given in the case.

Outcome.—The following opinions were expressed: Syphilitic aortitis, with ulceration into the pulmonary artery, Dr. Roger I. Lee; syphilitic aortitis, with extension to the aortic valve, Dr. James H. Wright and Dr. Charles H. Lawrence; aortic stenosis and regurgitation, Dr. Wm. H. Smith; aortic and mitral regurgitation, with stenosis of the pulmonary artery, Dr. Frederick C. Shattuck; pulmonary stenosis and regurgitation, Dr. George C. Shattuck; congenital heart disease, with patent ductus arteriosus, Dr. Frederick T. Lord and

Dr. F. W. Palfrey; congenital lesions, probably patent ductus arteriosus or septal defect, Dr. Richard C. Cabot. By May 2d the patient seemed perfectly strong and well, had no symptoms of any kind, and was allowed to go home.

Case 188

A housewife of thirty-one entered the hospital August 31, 1910. Ten days ago the patient had a miscarriage. Since then she has been feverish and had one or more chills each day. Four days ago she had pain in the right side of the chest and began to raise bloody

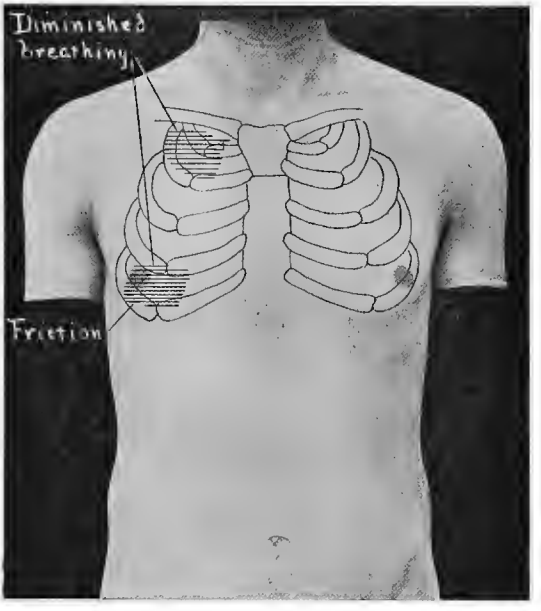

Fig. 162.—Chest signs in Case 188.

sputa. Previous history and family history negative, but she has had three miscarriages, including the one just mentioned. Previous to that she had three healthy children.

Physical examination showed obesity, pallor, cyanosis, twitching of the hands and arms. The tongue was very dry and cracked, with a thick, brown coat. Pupils, glands, and reflexes negative. Heart negative, save for a systolic murmur, loudest in the third left interspace. The left lung was normal. The right showed dulness through the back, with increased voice sounds. Breathing bronchial near the angle of the scapula over an area size of the palm, elsewhere diminished. In the front there was friction between the right nipple and

the axilla, and the breathing beneath the right clavicle was diminished (Figs. 162, 163). Abdomen negative.

There was a foul vaginal discharge. The patient was actively delirious. Temperature as seen in Fig. 164. The urine averaged 35 ounces in twenty-four hours; specific gravity between 1013 and 1018; albumin present in slight traces up to the first of October, and then usually absent. The sediment showed at first granular casts with cells adherent; later on, nothing of interest. The blood showed at entrance 3,000,000 red cells. A week later it had fallen to 2,300,000, from which point it gradually rose until, on the 27th, the cells num-

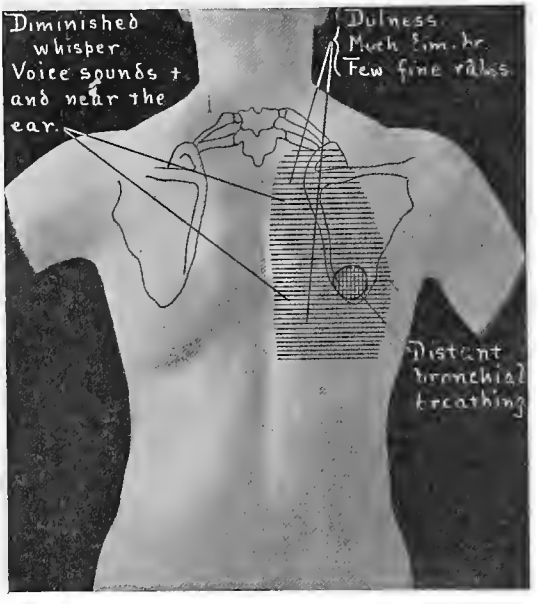

Fig. 163.—Chest signs in Case 188.

bered 4,000,000. Hemoglobin was 40 per cent. at entrance and gradually rose to 60 per cent. The white corpuscles varied from 16,000 to 20,000 during the first week; after that remained in the neighborhood of 12,000. October 12th the last blood examination showed reds 4,800,000; whites, 8000; hemoglobin, 80 per cent. The smear in the earlier days of her illness showed moderate achromia, considerable variation in size, and a good deal of abnormal staining. On the 14th four normoblasts and three megaloblasts were seen while counting 200 white cells. All of these abnormalities disappeared before she left the hospital. Blood-culture August 31st was negative.

The sputum was very profuse, purulent, foul, and contained a variety of organisms. No tubercle bacilli or other predominating organisms could be discovered. The vaginal discharge soon ceased to be foul and the pelvis showed nothing markedly abnormal. Each

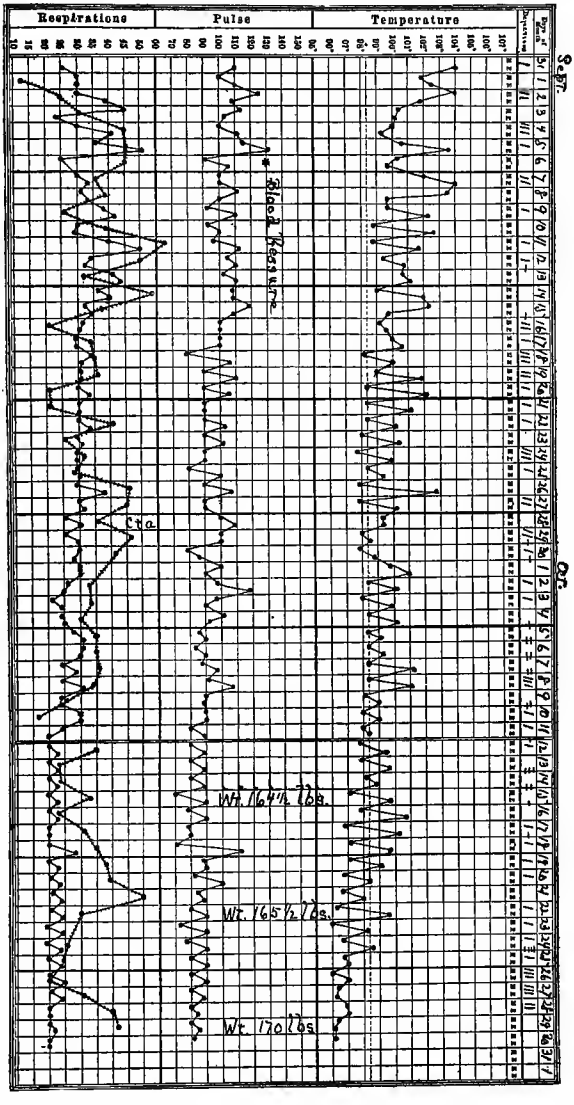

Fig. 164.—Temperature chart of Case 188.

morning she was comfortable and in good condition. Toward night she usually had a chill, became restless and delirious, with a weak pulse, high temperature, and respiration. The evidences of pulmonary solidification were quite clear during the first week, but after the 6th

of September the lungs were much clearer, though the chills and sweats continued.

The uterine discharge had almost ceased by September 6th. September 8th the heart's apex extended to the anterior axillary line and there was a soft systolic murmur there. On the 22d of September the signs seemed obviously those of pulmonary abscess or gangrene, though no localization could be made. On the 9th of October in the right axilla there was tympanitic resonance, amphoric breathing, and cracked-pot sound. Nevertheless, the patient seemed much better. The sputum was still profuse and somewhat bloody. October 11th she was sitting up in a chair daily, and from the 13th of October a chart was kept showing the amount of sputum daily (Fig. 165). Cough was easily brought out on change of position. The fingers were slightly clubbed.

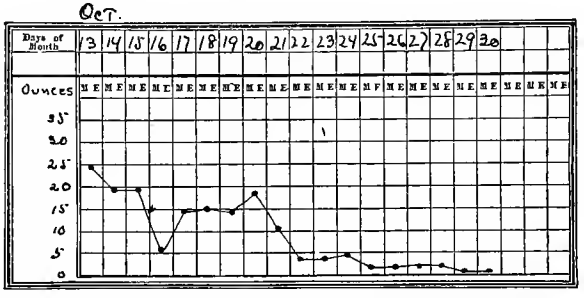

Fig. 165.—Shows daily variations in the number of ounces of sputum.

October 21st *x*-ray showed diffuse shadow throughout the right lung, but no recognizable cavity.

Discussion.—Of special importance, it seems to me, is the fact that this patient's symptoms came immediately after a miscarriage. Pulmonary symptoms at such a time should always suggest thrombosis of the periuterine veins, with resulting pulmonary embolism, bland or septic. The fact that chills accompanied the hemoptysis and chest pains leads us to imagine that the embolism is of the septic type.

In the present case reasoning of this type seems to help us rather more than an attempt to make a diagnosis from the physical signs. The signs in the lungs will fit almost any pulmonary disease—phthisis, pneumonia, abscess, pleurisy, etc. Much more often than we are apt to admit, this is true of pulmonary disease, and the correctness of our diagnosis depends more upon our general pathologic knowledge, our study of the sputa, and the history than upon what we learn by auscultation or percussion.

The anemia, the fever, and leukocytosis are consistent with any one of the pulmonary diagnoses just listed. Of decisive importance is the condition of the sputum, which is characteristic of abscess and distinctly different from that of bronchiectasis, phthisis, pneumonia, or empyema. Of special interest is the sputum chart presented herewith, and showing how the enormous amount of sputum (almost 1 quart in twenty-four hours at the start) gradually fell to zero.

In all probability, then, we are dealing with a septic embolus of the lung, thrown off from the periuterine flexus or veins which had become clogged and infarcted as a result of the septic miscarriage. Hemoptysis is not the rule in such a case, but is not at all rare.

Outcome.—From October 21st the amount of sputum rapidly diminished, the temperature ranged lower, and finally disappeared, while the patient gained steadily in weight and strength. Oil of eucalyptol, 10 minims, three times a day, began September 17th. The patient weighed 170 pounds when she left the hospital in excellent condition on the 30th of October.

Case 189

A housewife of sixty-two, born in Russia, entered the hospital August 19, 1910. The patient states that eighteen years ago she brought up about ½ cupful of blood, whether by coughing or otherwise she cannot state; otherwise she has been well. She has had twelve children and no miscarriages. Menopause occurred twenty years ago.

Two days ago she coughed up about a cupful of blood, and since then has had a slight cough and raised a small amount of blood. Family history is negative; habits good.

Physical examination shows poor nutrition; cataract in the right eye. Left pupil non-circular and eccentric, but reacting normally. Glands and reflexes normal. Lungs negative. The heart's apex found in the sixth space, 14 cm. from midsternum. Aortic second sound metallic and ringing. Blood-pressure, 165 mm. Hg., systolic. No murmurs. Artery walls tortuous and thickened. Abdomen very much relaxed. Right kidney palpable. Liver edge felt three-fingers' breadth below the ribs.

A laryngologist could find no bleeding points in the nose, larynx, or trachea. On the day after her entrance she raised 6 or 7 ounces of bright alkaline blood; 4 mg. of old tuberculin was injected under the skin, and was followed by a rise in temperature to 101° F. without constitutional symptoms. The sputum was examined three times for

tubercle bacilli with negative results. On the 3d of November, as she felt perfectly well, she was allowed to go home.

Discussion.—That the patient's first hemoptysis, eighteen years ago, did not seriously impair her health, seems to be the fact. Apparently she underwent no treatment after it and has had no symptoms. This is all the more interesting and significant because, in the minds of many physicians, this would constitute proof that it was not of tuberculous origin. Yet now, after the lapse of eighteen years, we have a repetition of hemoptysis, which was this time of considerable amount and occurred under observation in the hospital, so that there can be no possible doubt as to the fact, yet still no signs appear in the lungs.

The heart is not normal, but there is nothing about it, nor about any part of the body, to suggest a failing cardiac compensation or any such pulmonary suggestion as could produce hemorrhage by infection. Undoubtedly she has arteriosclerosis and a low, sagging liver, the latter accounted for probably by the abdominal relaxation following her twelve pregnancies.

The tuberculin reaction is proof of tuberculosis, obsolete or active, past or present, but has no necessary bearing upon her present symptoms. If she were younger we should have no doubt of the diagnosis of tuberculosis. As it is I cannot feel sure, and must leave the case in doubt. Tuberculosis, however, seems to me the most probable theory.

Outcome.—She was seen again in December, 1910, and December 30, 1911, and had had no recurrence of symptoms. February, 1913, she reported, looking and feeling perfectly well. Physical examination of the lungs negative; of the heart unchanged.

Case 190

A woman of twenty-four entered the hospital November 1, 1910. The patient has a negative family history and has been well until within the past year, though she has had a number of attacks of tonsillitis. For a year she has felt poorly and been below her normal weight. Varicose veins were excised by Dr. Bottomley at the Carney Hospital a few months ago.

For a month she has complained of pain in her right shoulder, and for a few weeks she has had pain and swelling in the region of the right tonsil. After a chest examination, to see if there were any contra-indications for operation upon the tonsil, the tonsils were removed by Dr. Mosher, six weeks ago. For five days after operation

she did well and had no temperature; then she complained of acute pain in the left lumbar region, but examination disclosed nothing. After going home from the hospital where this operation was done she continued to cough, the expired air being very foul. For a month she has been feverish, the temperature reaching 100° F. in the morning, 103° F. in the evening. She has remained in bed. At the beginning of this period a patch of bronchopneumonia, the size of a dollar, was found half-way between the left nipple and the clavicle. There were also a few fine râles in the left back. Later these disappeared. *Five*

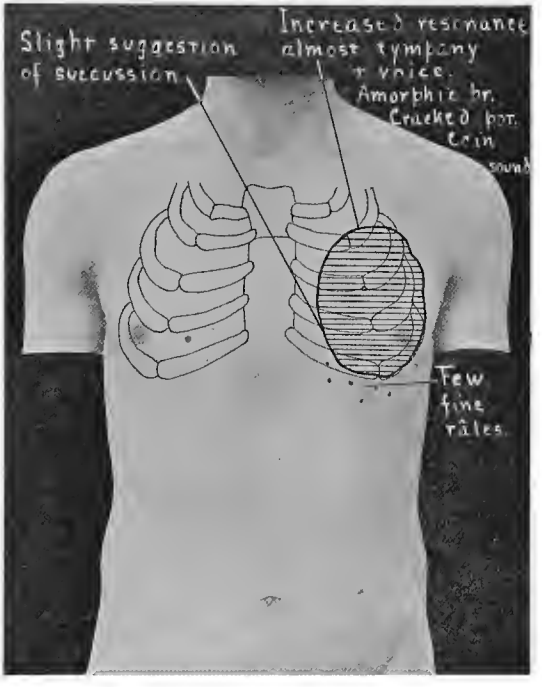

Fig. 166.—Chest signs in Case 190.

days ago the sputum was blood stained. Three days ago a slight dulness was found in the right back, accompanied by fine, moist râles. Last night signs of cavity were discovered in the left chest. The amount of sputum has been 1 or 2 ounces a day.

On physical examination the patient was emaciated and constantly raised very foul sputum. The lymph-nodes in the left side of the neck were enlarged. The pupils and reflexes were normal. In the left front was an area of tympanitic resonance, as depicted in Figs. 166 and 167. Over this area was amphoric breathing, cracked-pot sound, coin sound, and increased voice, also a few fine râles at the lower margin of the

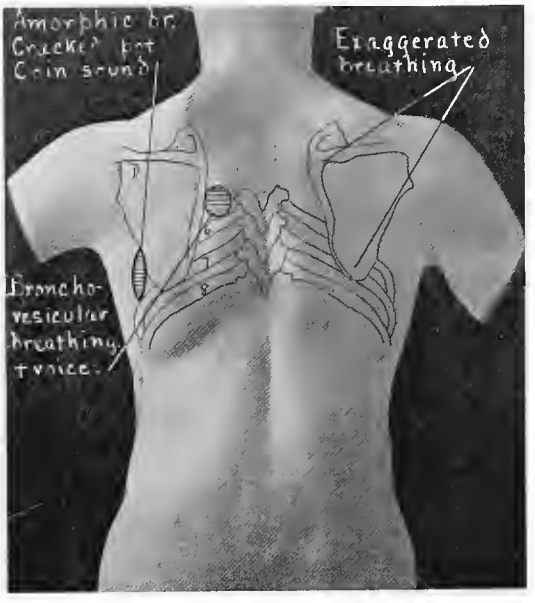

Fig. 167.—Chest signs in Case 190.

area. These signs extended into the left axilla, but were less marked in the back. The heart and abdomen negative. The urine showed a trace of albumin, 0.5 per cent. of sugar, specific gravity 1023; twenty-four-hour amount not accurately recorded. Temperature as in Fig. 168. Leukocytes 20,000, with a polynuclear leukocytosis. Hemoglobin, 70 per cent. On the afternoon of entrance, after a prolonged surgical examination, the patient raised nearly 8 ounces of pure blood.

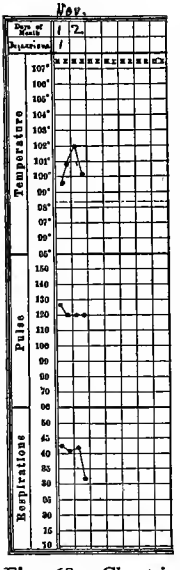

Fig. 168.—Chart in Case 190.

Discussion.—The patient has had two surgical operations, either of which might have resulted in a lung complication. Lung abscesses after tonsillar operations, owing to the inhalation of septic material during the operation, are very rare, but should be reckoned among the possible risks involved in even so slight an operation as tonsillectomy.

On the whole, the operation of excising varicose veins is one that might be followed by thrombosis of the veins higher up, and, finally, by pulmonary embolism and resulting abscesses or infection. The physical signs as shown in such cases are not distinctive, but the odor of the breath leaves no doubt that we are dealing with an abscess.

Can this abscess be tuberculous in origin? The character of the sputum is wholly against it. A patient whose tuberculosis was so extensive as to result in so large a bulk of sputum would almost certainly have demonstrable signs in the other lung.

Bronchiectasis, which may be associated with a very foul sputum, rarely develops in so short a time and is almost invariably bilateral.

Outcome.—At four the next morning she had an attack of cyanosis, with shallow, difficult breathing, and died. Autopsy No. 2712 showed abscess and gangrene of the upper lobe of the left lung with excessive hemorrhage; fetid bronchitis; obsolete tuberculosis of a bronchial lymphatic gland.

Case 191

November 1, 1902, an Irish ward maid of the hospital, nineteen years old, was taken into the ward. She had diphtheria in the previous January and was ill six weeks. Otherwise she has always been well. Her family history is negative. Her habits are good. Her menstruation is normal, except for considerable pain. Yesterday she noticed sore throat, chills, headache, backache, coryza, watering of the eyes. Last evening she vomited four times.

Physical examination showed large reddened tonsils, with whitish exudate and enlarged glands below the angle of the right jaw. Cultures from the throat were negative. After a week in the wards the patient seemed to be practically all right and went back to work. March 16, 1903, she had a similar attack and was in the ward five days, but recovered promptly. January 6, 1905, she entered for the third time, stating that five years ago and three years ago she had had attacks like the present, when she vomited considerable blood, although nothing relating to this is contained in either of the previous hospital records. The patient also stated at this time that one sister had died of consumption.

Thirteen days ago she began to have sharp epigastric pain radiating to the back. It was constant, increased by pressure, not increased or relieved by food. The pain lasted two days, then ceased for two days, began again and lasted twelve hours, then left her until this morning. Twelve days ago and eleven days ago she either vomited or coughed up 3 or 4 ounces of dark blood, none since. She states that for two years she has had pain during micturition.

Physical examination showed good nutrition, normal throat, negative chest and abdomen. The patient remained three months in the ward, and during most of that time had no fever. On a few occasions,

to be mentioned subsequently, there was a short period of pyrexia. The blood at entrance showed 15,400 white cells; hemoglobin, 90 per cent. The urine was negative save for the slightest possible trace of albumin. The patient was kept on nutrient enemata for six days, and after that did well on feeding by mouth. From time to time she had some abdominal distress or vomiting, the vomitus once containing several streaks of blood.

On the 8th of February she vomited about 2 ounces of bright blood. March 3d this happened again. In the meantime she was free from pain and eating well. On the 7th blood was found in the basin by her side. It seemed to be mixed with mucus or sputum. Examination of the lungs showed questionable dulness and increase of voice sounds at the left apex. The sputum was repeatedly examined for tubercle bacilli without results. Guaiac tests of the stools were negative. After 10 mg. of tuberculin the temperature rose to 102.5° F. This was the only period of considerable pyrexia during the whole three months of her stay.

On the 22d of March there was again a question of the source of blood found in the basin beside her. The blood was mixed with mucus and had a faintly acid reaction. It became clear at this time that she was very untruthful as well as impudent. She refused to leave the ward when it came time for her to go, but was discharged, nevertheless, March 30th. Gastric ulcer and pulmonary tuberculosis were the diagnoses considered, but no definite evidences of either disease was obtained.

She was again in the ward in June, 1905, in the meantime having been at Rutland Sanitarium for tuberculosis. While there she had much epigastric pain, increased by food, never relieved by it, and vomited once a day sometimes and sometimes less frequently. She says she has vomited no blood. She has gained nearly 14 pounds, and has not coughed at all, though she has raised considerable sputa, once with a small lump of blood.

Physical examination shows that the gums are spongy and bleeding, the posterior pharyngeal wall covered with mucus. A systolic murmur, loudest at the apex, was heard also in the axilla and all over the precordia; otherwise the chest was negative, likewise the abdomen. Blood and urine normal. The capacity of the stomach was 2 pints, 10 ounces; no residue before breakfast; after a test-meal, free HCl 0.087, total acidity, 0.277; no blood. Her chief complaint was of pain about the bladder during and after micturition and a pain in the lower part of the back, considered by our orthopedic consultant, Dr. Robert B.

Osgood, to be of attitudinal origin. The course of the patient's temperature is seen in Fig. 169. On the 21st she was impudent and disobedient, and told that she would be discharged the next day. The next day she developed earache, abdominal cramps, pain in the back, and many other symptoms. Examination of the ears was negative. She was kept in the ward, and then seemed perfectly contented. No cause for the fever could be found.

On the 2d of July she was allowed to get up and showed no ill effects. On the 3d of July it was found that the thermometer registered 104° F. The patient's pulse was low, skin cool, and there was no other evidence of fever. The patient was given another thermom-

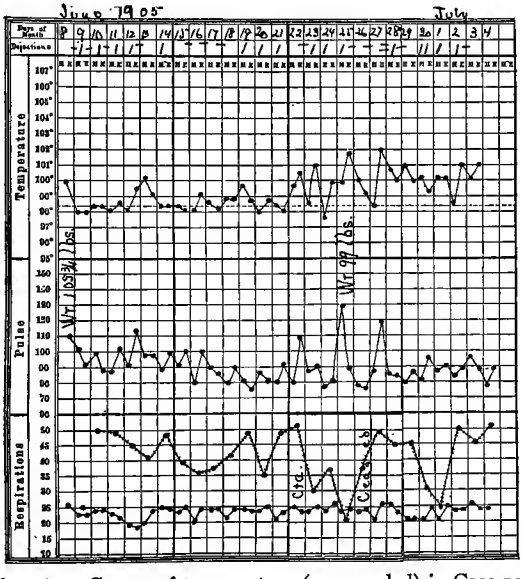

Fig. 169.—Course of temperature (as recorded) in Case 191.

eter and secretly watched. She was then seen to shake the instrument, point upward, so as to make it register high. The nurse then took the temperature by rectum and found it to register 98° F. The next day she refused to have her temperature taken. During this stay in the ward she frequently spat up 1 or 2 ounces of foul-smelling bloody fluid which evidently came from her gums.

She was discharged July 4th and re-entered September 22d, stating that she had felt well and done her work regularly since she was last in the ward. She had vomited five or six times, but never anything abnormal until this morning, when, at three o'clock, after a restless night, she vomited ½ cupful of bright blood. She has a slight cough,

mostly at night. Physical examination showed nothing abnormal. Pelvic examination was negative.

She was discharged September 25th, and re-entered December 23, 1905, having been well in the meantime. Yesterday at 9 A. M. she vomited 1 pint of dark-brown fluid which she thought was old blood, and immediately after this a mouthful of bright blood. Twice since then she has raised blood. Two days ago she had a very dark-colored stool, otherwise she has noticed nothing abnormal about the stools. This time the patient stayed five weeks in the wards. As on previous occasions, blood was found in her spit-cup, but the source of it was not clear. Bleeding points were found on the gums. After the patient was told that the bleeding came from the gums, she ceased to spit blood until January 6th, when, after violent retching, she brought up 2 or 3 ounces of a mixture of food and bright blood. On the 23d she seemed perfectly well, and was discharged from the ward. At the foot of the ward stairs she made a scene—screamed, struck attendants, and finally fell in a limp heap. She was brought back to the ward and was very difficult to manage, insulted the nurses, ran her finger into her throat, and tried to make herself vomit, threatening to take corrosive sublimate. Her condition was explained to her sister, and she was discharged on the 27th.

In February, 1906, she got into the Carney Hospital, then under the management of a very enthusiastic stomach surgeon, and was operated upon for gastric ulcer (exploratory incision; nothing found). After that she had no stomach symptoms until September, 1910, but in June, 1906, she still complained of pain, and her appendix was also removed at the Carney Hospital. At that place she told the house officer that her mother died of phthisis.

In December, 1906, she was in the Boston City Hospital, with a diagnosis of intraperitoneal adhesions, and, after being treated medically, was transferred to the surgical ward with a diagnosis of cystic ovary, which was operated upon in the usual manner, February 14, 1907.

Re-entered Massachusetts General Hospital February 9, 1911. Since operation at City Hospital she has been much less well, has had much sharp pain in the lower abdomen and occasional sharp pains in the rectum; also frequent and painful urination. Physical examination showed nothing new except three surgical scars on the abdomen. February 9th she passed about 80 c.c. of bright red blood into the bed. Twice after that bright blood was found in her bed-pan or in her bed. Proctoscope examination by Dr. Brewster was entirely negative. The

patient was evidently rejoiced by the prospect of some operation, deeply enjoyed the preparations for it and the trip to the amphitheater. *From March 1st to March 6th she ejected a good deal of blood from the mouth and some from the rectum. On the 24th she was transferred to a private ward and constantly watched. There*

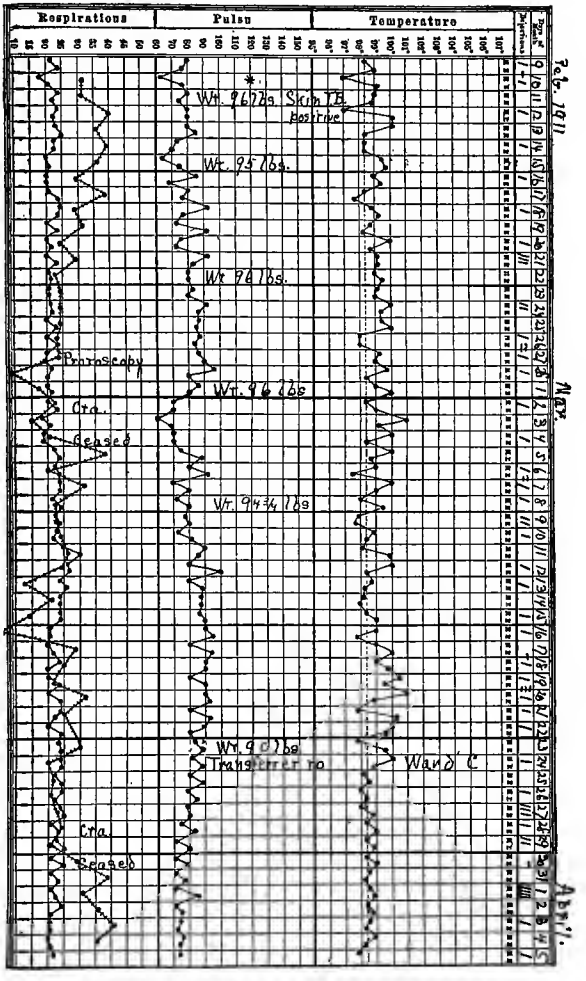

Fig. 170.—Chart of Case 191. Note especially the sudden disappearance of fever in the last two weeks, *i. e.*, after her transfer to a private room with careful watching.

was then no blood passed from any source until the 29th, when she was caught rubbing her gums, and raised a mouthful of watery blood. On the 5th of April she was discharged as a malingerer. Later, she wrote a long rambling letter and something apparently intended for a poem. After her transfer to Ward C, and careful watching, the irregular fever which had been present before (Fig. 170) disappeared. February 9th

the red cells were 3,300,000; hemoglobin, 70 per cent., slight achromia, moderate variations in size and shape. March 11th, 1911, red cells, 4,100,000; hemoglobin, 80 per cent.

Discussion.—This is one of the most interesting and remarkable cases that has ever come to my notice. There is no possible doubt that she was malingering; that she deceived us into the belief that she had fever and hemoptysis when there was no such thing. On the other hand, there is no doubt that her gums were spongy and bleeding and that she did not produce this condition herself. Granted that she did not have any of the diseases which were most seriously considered in her case, especially phthisis and peptic ulcer; granted that the stay at the hospital for tuberculosis was a farce, we still have to explain her hemorrhagic tendency.

Outcome.—Further letters from the patient show that January 1, 1914, she was still in a hospital, making a record of twelve years, during which, to our knowledge, she has been going from hospital to hospital. During that time she has been operated upon seven times and has been in six different hospitals—a most noteworthy example of the harm that can be done because surgeons do not study their cases and because hospitals do not co-operate with one another.

In the spring of 1912 the patient's hemoglobin got down as low as 20 per cent. It is clear that she must have lost a good deal of blood. The cause of this, and what, if any, participation her own morbid actions had in it, I cannot say.

Case 192

A weaver of thirty-three, a Finlander, entered the hospital June 26, 1911. The patient has an excellent family history and was never sick until three years ago, when he had an attack like the present. He takes about 1 pint of whisky each Saturday and occasionally earlier in the week.

Three years ago and one year ago he had an attack like the present. Three times during the past year these attacks have been repeated. On the 10th of June he raised a few ounces of bright blood. This evening he raised about 10 ounces in the same way. He has no cough, no pain, and feels perfectly well in other respects. Seven years ago he weighed 156 pounds; now, 145 pounds. Laryngologic examination in the Out-patient Department showed the vessels at the base of the tongue rather large, the larynx somewhat injected, a little blood on the trachea below the vocal cords. The sputum was examined five times for tubercle bacilli without results.

The patient was powerfully built and looked well. At entrance the lungs and the rest of the physical examination were entirely negative. He continued to raise purulent sputum mixed with dark blood. During the first week of his stay he had no temperature above 99.2° F. The second week it touched 100° F. several times, and never fell below 99° F. His systolic blood-pressure was 115. Blood and urine normal. *X*-ray showed mottling at the roots of both lungs, most marked on the right; the right apex was also mottled (Fig. 171). Some of the blood raised July 1st was injected into a guinea-pig. August 5th the pig was killed. Autopsy showed tuberculosis.

Discussion.—Here we have four attacks of hemoptysis in three years. The laryngologic examination is of great value, demonstrat-

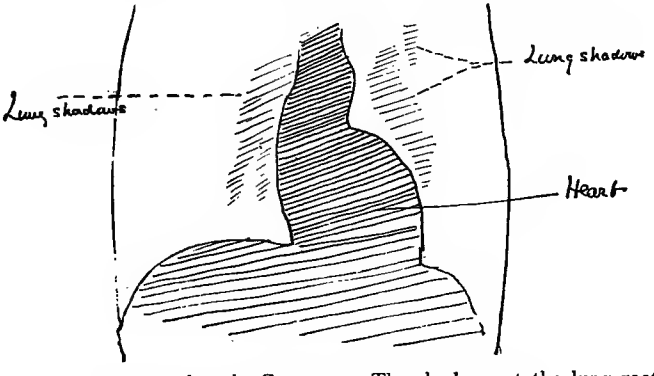

Fig. 171.—Sketch of *x*-ray plate in Case 192. The shadows at the lung roots seemed rather more marked than in the average case.

ing, as it does, that the blood comes from below the vocal cords and in all probability from the lung. Yet against this we have the five negative sputum examinations and the absence of any physical signs pointing to pulmonary abscess, bronchiectasis, or any other local lung lesions ordinarily associated with hemoptysis.

The point of special interest in the case is the fact that through animal inoculation we were able to prove the presence of tuberculosis, when by other methods it would have been impossible. The search for tubercle bacilli in bloody sputa is particularly unsatisfactory, and yet such sputum can well be used for animal inoculation.

Outcome.—The patient left the hospital on the 8th, and returned to Finland, where he cannot be traced.

Case 193

A German gardener of thirty entered the hospital January 10, 1912. The patient has always been well and strong until a year ago, when the right eye suddenly became swollen, painful, and inflamed. An ulcer followed, and he was ill a month with it. Seven months ago, without any warning whatever, he spat up a mouthful of bright blood shortly after eating. There was tickling in the throat, he coughed slightly, and up came the blood. The attending physician could find no cause for the trouble, and he seemed all right again the next day. Five months ago the same thing happened again. Three and a half months ago he had a third attack. Ten days ago he was watching a gang of men blasting, ran to escape a blast, suddenly felt nauseated, and spat up two or three mouthfuls of dark blood. Since then he has raised at least a mouthful of blood daily, and at least twice has raised eight to twelve mouthfuls, the last time two nights ago.

He feels perfectly well, has worked steadily, and never coughs except when raising blood. He has no fever or sweats and has never vomited. Appetite, bowels, and sleep are normal. No dyspnea or edema. No headache or change in eyesight. No loss of weight.

On examination by a laryngologist in the Out-patient Department free blood was seen on the tracheal wall below the larynx. In the ward he proved to be well nourished; the right eye showed anterior staphyloma, the left normal. Glands and reflexes normal. Chest and abdomen negative. Wassermann reaction negative. Examination of the eye by Dr. Quackenbos showed that the iris was tied to the scar in the cornea on the lower and outer side. The ocular tension was increased. The left eye also showed scars on the cornea. Five examinations of sputa were negative. Blood and urine negative. Blood-pressure, 125 mm. Hg., systolic; *x*-ray showed peribronchial thickening to the right of the sternum, calcified spots at both apices, a prominent aortic arch. The patient was given 1 mg. of old tuberculin subcutaneously, had no reaction, but after 5 and 7 mg. the temperature rose to 101° F. No physical signs developed in the lungs after these injections and there was no general malaise. There was a slight local reaction at the site of injection, and the von Pirquet reaction, which had been moderately positive before the subcutaneous injections, was much more markedly so afterward. No further facts could be brought out, and, accordingly, the patient went home on the 21st.

Discussion.—I have no means of knowing what ailed the patient's

eye and no good reason for connecting it with the present seven months' illness. Regarding the hemoptysis, I want to call attention to the fact that the blood came up in the characteristically stealthy way in which blood appears in pulmonary tuberculosis. Now and then blood comes with hard coughing, but in the majority of cases the patient is astounded to find blood in his mouth and is by no means sure where it comes from. Often he is unaware of having done anything whatever to cause it; is quite sure he has not coughed.

This type of hemoptysis, as I say, is particularly characteristic of tuberculosis.

The laryngologic examination, proving that the blood comes from below the larynx, adds a valuable piece of evidence pointing in the same direction. The five negative examinations of the sputa do not in any way exclude tuberculosis. On the other hand, the *x*-ray findings and the tuberculin reaction do not prove anything. They might both of them correspond to a wholly obsolete or healed process of no present significance. This is just the sort of case in which animal inoculation with the blood or sputum raised would be of the greatest importance. Nevertheless, despite the absence of any such inoculation, the subsequent history of many similar cases convinces me that this patient is, in all probability, tuberculous.

Case 194

An engineer of forty-six entered the hospital January 22, 1912. The patient's father died of heart trouble; his mother, of dropsy. He had rheumatism when a boy in two attacks, each lasting all winter and keeping him on crutches. He has slept with at least two pillows all his life. For the past four years he has passed urine five times each night. A year ago he had "pneumonia" in both lungs and was sick seven weeks. His habits are excellent.

Since the pneumonia he has been short of breath on exertion, but otherwise has done his work, as a stationary engine fireman, without any trouble. Seven weeks ago, after a physical strain, he began spitting blood, and in the course of a night raised almost a quart. After that his wind became so short that he could not work and when he lay down he choked. Soon after the hemorrhage his legs began to swell. He has not been in bed, has a good appetite, and no headache or dizziness.

Physical examination shows fair nutrition, marked pallor, normal pupils, glands, and reflexes. The heart's apex extends 3 cm. outside the nipple line. The aortic and pulmonic second sounds are both

sharp, the latter reduplicated. There is no fever; there are râles at the bases of both lungs, and at the right apex dulness, bronchovesicular breathing, and crackles, extending down to midscapula and to the third rib in front. The arteries were very rough and tortuous, the abdomen negative, save for tenderness and resistance under the right ribs. Wassermann reaction negative. Urine, 70 ounces in twenty-four hours; specific gravity, 1008; slight trace of albumin, no casts. Red cells, 3,500,000; white cells, 15,000; hemoglobin, 60 per cent. Stained smear shows deformities in size and shape, polynuclear leukocytosis, with 82 per cent. of polynuclear cells. Blood-pressure at entrance, 220 mm. Hg., systolic; 130 mm. Hg., diastolic. On the 27th it was 290 mm. Hg., systolic; 150 mm. Hg., diastolic. No temperature in a week's observation. On the 24th the evidences of solidification had disappeared, though there were still numerous fine crackles over the right apex, front and back. The edema disappeared soon after entrance and the lungs slowly cleared, but the patient did not gain. He slept a good deal of the time and seemed on the edge of delirium. A hot-air bath made him restless and excited. He died on the 30th.

Discussion.—The patient's history of rheumatism and partial orthopnea at night, together with the supposed pneumonia of a year ago, are suggestive of cardiac mischief and pulmonary congestion. Nocturia points in the same direction. Hemoptysis in such a patient, followed immediately by dropsy of the legs, is excellent evidence that the heart is the source of the trouble.

The pulmonary signs in the lungs are equivocal. They are consistent either with tuberculosis or with pulmonary congestion and infarction. The existing anemia is presumably of the posthemorrhagic type.

In the heart and vessels we have evidence of arteriosclerosis and, very possibly, contracted kidney. In my experience a blood-pressure as high as 290 is generally the result of a combination of arteriosclerosis with chronic glomerulonephritis, both of the ordinary causes of hypertension acting in conjunction. We may call the case one of pulmonary apoplexy, provided we recognize that this does not differentiate it from the infarctions seen in young persons and without arteriosclerosis. It is presumably the back pressure in the lung or the slow circulation through its vessels, not the weakness of those vessels, that leads to the infarct and hemorrhage.

CHAPTER X

EDEMA OF THE LEGS

EDEMA of the legs, like all edemas, has three main causes—the heart, the kidney, and the blood.

(1) *Cardiac edema* includes not only the obvious lesions of the heart valves or heart wall, but also the swelling of the feet seen so commonly in the obese.

(2) The edema of *renal disease* is traditionally believed to begin with the face and show itself later in the feet. This, however, is not invariably the cause.

(3) In *anemia* the edema may quite possibly be of the cardiac variety, *i. e.*, anemia may have produced cardiac weakness and thus an edema, indirectly rather than directly due to the blood.

Besides these causes, all possibly connected with the first of them, the only common type is the slight edema of the hands and feet, not infrequently seen in *hot weather*.

LOCAL CAUSES OF EDEMA

Varicose veins are by far the commonest cause for swelling of the legs. Their presence is usually obvious and needs no discussion. *Local skin disease*, involving the legs, may have the same effects, usually bilateral, usually making clear their nature by the ordinary signs of inflammation. *Phlebitis*, almost invariably unilateral, may be unaccompanied by pain or tenderness, but, as a rule, there is soreness over the course of the vein on the inner side of the leg. The diagnosis can sometimes be made only by study of the associated disease; for instance, typhoid fever or the puerperal state. An enlargement or edema of one leg, coming on in either of these conditions, should always be assumed to be due to phlebitis until proved to the contrary, whether any local pain or tenderness is present or not. Chill, fever, and leukocytosis may accompany the onset of such a phlebitis.

Alcoholic neuritis is a cause of edema often forgotten. It is, presumably, akin to the edema seen in infectious peripheral neuritis (beriberi). The accompanying loss of knee-jerks and changes in sensation usually make the diagnosis clear.

In *cirrhosis of the liver* an edema of the legs, appearing usually subsequent to the development of ascites, is the rule. How far cardiac and renal elements enter into the production of this swelling it is often impossible to determine during life.

Hereditary trophedema, a mysterious condition probably akin to *elephantiasis*, offers no special difficulty in diagnosis, owing to the fact that it is present from the time of birth. It rarely affects both legs, and it is usually associated with some thickening of the subcutaneous tissues. *Myxedema* is occasionally associated with true edema of the legs, the two diseases resulting in a very tough, brawny enlargement, very puzzling at first sight. The coincident changes in the face, skin, hair, and cerebration should make the diagnosis clear.

VARIETIES AND SITES OF EDEMA

Swelling of the legs usually appears first upon the front of the shin and the back of the thigh. This is doubtless due to the arrangement of the blood-vessels. At the very beginning of an edema the shin bones are often notably tender, and it is good practice in making routine physical examinations to press strongly upon the shin bone in search of such tenderness.

Brawny edema, tough and difficult to indent, usually means a relatively long-standing and high degree of dropsy, but it is also dependent more or less upon the quality of the tissues in which it accumulates.

EDEMA IN CONVALESCENCE

After any prolonged illness, such as typhoid fever, the patient is apt to show edema of the legs when he first gets out of bed. This may persist for some days or even weeks, but ultimately clears up, and should occasion no alarm. Doubtless this is due to the fact that the circulatory system cannot at first accommodate itself to the greater strain thrown upon it by the perpendicular position, in comparison with the previous horizontal position of the body.

Case 195

A brakeman of fifty-three entered the hospital October 24, 1903. For six months the patient has noticed swelling of his legs, and for about four weeks some enlargement of the abdomen, with dyspnea, and, of late, orthopnea. Nocturia, 2 to 3. Appetite poor. Bowels normal, sleeps well. The patient takes three or four glasses of whisky and three or four of ale a day. He had typhoid fever at eighteen and fracture of the skull in 1876. He has had gonorrhea twice; denies syphilis.

Edema of the Legs



[1] Affecting almost invariably one leg. The other diseases here listed affect both legs.

Physical examination showed good nutrition; pupils, glands, and reflexes normal. Heart and lungs negative, except for diminished breathing over the lower quarter of the left back, where numerous crackling râles were heard. Abdomen showed shifting dulness in the flanks and the superficial veins were rather prominent. The girth, 2 inches above the umbilicus, was 44 inches. Marked edema of the legs. The urine averaged 35 ounces in twenty-four hours, smoky, acid; specific gravity, 1020; albumin, $\frac{1}{6}$ per cent.; sediment, much normal blood, numerous hyaline, fine and brown granular casts, with blood adherent. Blood negative.

The abdomen was tapped on the 28th and 18 pints of straw-colored fluid withdrawn, with a specific gravity of 1009. The urine continued bloody. The abdomen was tapped again on the 7th of November and an equal quantity of fluid of practically the same characteristics was evacuated. After this tapping the edge of the liver was felt in the epigastrium. For a few days, before and after the 8th of November, there was a slight rise of temperature, associated with nausea and occasional vomiting.

Discussion.—The patient is alcoholic and, therefore, very possibly, syphilitic. No physician should put any weight upon the negative statement of an alcoholic in regard to syphilitic infection. His statement may well represent his belief, but he really knows nothing about the matter.

The patient's dropsy appeared six months ago in the legs, and only a month ago in the belly. Nevertheless, the liver must first be suspected as a cause of the edema, because of the enlarged veins visible over the abdomen, the palpable liver edge, and the alcoholic history.

The condition of the urine makes it probable that some degree of nephritis exists, either acute or acute exacerbation of a chronic process. The low specific gravity of the ascitic fluid may be taken as excluding tuberculous or cancerous peritonitis, and, as the heart shows nothing of note, we may conclude that the edema is of hepatic origin, renal origin, or due to both sources at once. Unfortunately, we have no record of a blood-pressure measurement to confirm our diagnosis of nephritis; in 1903 such measurements were not a routine.

Outcome.—After November 8th the ascites returned more slowly than before, and he did not have to be tapped again before he left the hospital on the 21st of November. The urine at this time showed very few casts, but still contained a large trace of albumin and had a good deal of normal blood in the sediment.

Case 196

A farmer of seventy-seven entered the hospital May 4, 1904. The patient has a negative family history, and has always been very strong and rugged, except for an attack of sciatica in 1885 and a second attack six months ago, lasting five weeks. After this the left great toe and the side of the foot remained numb and have been so ever since.

A week ago, while dressing, he noticed that his left foot was swollen. This has gradually spread up the leg and tenderness has appeared here and there; in other respects he feels perfectly well. Appetite, bowels, and sleep are normal.

Physical examination is negative, save that the left leg and thigh are swollen, slightly reddened, and, along the course of the internal saphenous vein, tender on pressure. Blood and urine normal. The temperature during the first week rose to 99.5° F. each night, falling to normal in the morning.

Discussion.—Edema of one leg narrows the field of consideration at once. We must be dealing with a local cause. The recent history of pain and numbness in the left leg in a man of his age leads us to surmise that arteriosclerosis may have something to do with his troubles. The residual numbness of the foot may possibly be attributed to this cause.

Nevertheless, we must reckon with an acute affair in addition to the long-standing malady. Something has happened within the past week, and that something bears all the marks of a phlebitis. The local redness and tenderness such as is here described is produced, so far as I know, by nothing except phlebitis with the accompanying thrombus. Were the tenderness less accurately limited one might have to consider lymphangitis, erysipelas, or a diffuse cellulitis, a trio of lesions which in the leg may melt into each other in a way to make sharp diagnostic distinctions valueless.

Doubtless the underlying arteriosclerosis and the malnutrition resulting from it have something to do with the acute phlebitis, but just what the connection is I do not know. Phlebosclerosis might be a possible intermediary link, but the physical examination does not confirm it.

Outcome.—Under poulticing and salicylate of sodium the swelling and tenderness were gone from the leg by the 15th of May; by the 20th of May he seemed perfectly well and was allowed to go home.

Case 197

A man of fifty-eight, employed in a paper-mill, entered the hospital August 11, 1904. For four months the patient has had pain and swelling in both feet, worse on standing. In other respects he feels well, though he has used alcohol to excess up to four months ago. His family history and past history are negative. His knee-jerks were not obtained. Both ankles were somewhat reddened and somewhat swollen, the arches of both feet broken down, some varices about the ankles.

Physical examination, including the blood and urine, was otherwise negative.

Discussion.—Alcoholic neuritis is probably the cause of the lack of knee-jerks in this case, and if the edema were spread more widely over the legs the neuritis would probably be accountable for that also. It is notable, however, that the redness and swelling of which he complains are confined to the region of the ankles and are associated with pronated feet.

This combination of inflammatory and mechanical changes about the tarsus is a condition commonly seen and not well understood. Is the flat-foot the cause of the inflammation or the inflammation the cause of the flat-foot? The latter seems more probable, yet in some cases the flat-foot seems to precede the inflammation. On the other hand, treatment of the flat-foot is often the quickest means of relieving the inflammation. Rest and salicylates do something, but do not finish up the job. *Local* measures of relief are the essential thing.

It must be assumed that the cardiac, renal, and hemic causes of dropsy are ruled out by the physical examination in this case; also the more obvious superficial and local causes of edema, such as varicose veins.

Why do people get flat-foot? The ordinary mechanical explanations do not suffice. The people who are most on their feet are not always those who get flat-foot. Physiologic factors of nutrition and general vitality, whatever that means, are certainly of importance. The people who lose sleep, eat irregularly, subject themselves to all sorts of bodily and mental strain are especially predisposed to this apparently quite local affection.

Outcome.—He was fitted with flat-foot plates and left the hospital on the 24th of August. The diagnosis reads, flat-foot and no home.

Case 198

A cook of fifty first entered the hospital March 16, 1908. He entered the hospital the second time February 6, 1909, having been working since his discharge, April 8, 1908. For the past month he has served as a cook in a lumber camp and has felt well and strong, though he noticed that his legs had begun to swell and his face to grow pale. For the past two or three weeks he has also noticed much weakness. Three weeks ago his bowels became more costive than usual. A week later he noticed that the fecal discharges were very irritating to the skin. This condition he has noticed many times be-

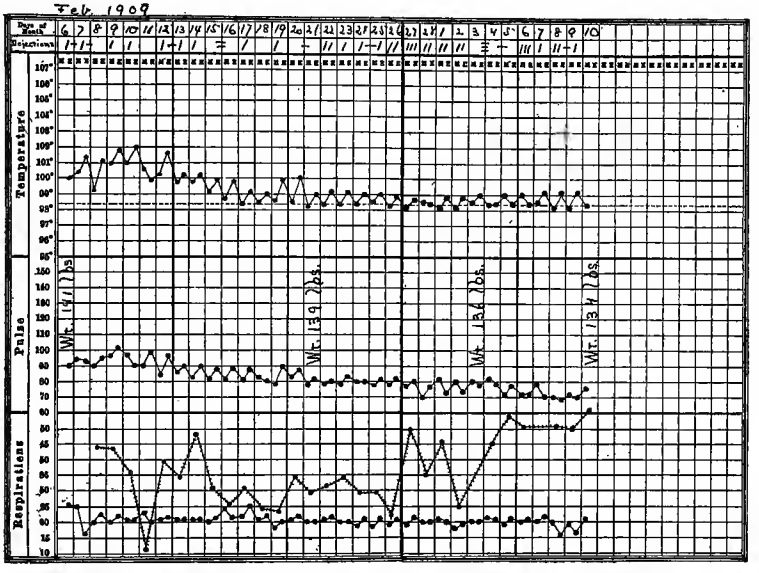

Fig. 172.—Chart in Case 198.

fore. Ten days ago his appetite failed, but he worked until four days ago. He has had a little pain across the small of his back of late, possibly caused by a strain when carrying a quarter of beef which weighed 260 pounds. He has lost no weight. At the present time his bowels are regular.

Physical examination showed poor nutrition, marked pallor. The apex first sound of the heart was sharp, and was followed by a systolic murmur transmitted to the axilla. A harsher systolic was heard over the pulmonary area. Visceral examination was otherwise negative. There was moderate edema of the legs and thighs. For the first two weeks of his stay in the hospital the temperature ranged

as shown in Fig. 172. His urine was of low gravity, but otherwise negative. The red cells at entrance numbered 900,000, and white, 2000. Hemoglobin, 40 per cent. There was moderate deformity of the cells, with stippling and discoloration. Nucleated red cells were occasionally seen, the normoblast type always predominating. The patient remained a month in the hospital, during which time his red cells rose to 2,250,000, his white to 6000, his hemoglobin to 70 per cent. The number of oversized red cells grew more and more marked, but at the time of his discharge there was no stippling, no abnormal staining of the red cells, and practically no deformities. During the last ten days of his stay he passed a large amount of urine and the edema disappeared from his legs. He left the hospital February 10, 1909.

Discussion.—Although the blood in this case makes a diagnosis of pernicious anemia almost inevitable, one hesitates for a moment when one notes that he has been working hard until within four days. A moment's reflection, however, reminds us that this is one of the peculiarities of pernicious anemia, that the patient's working strength may continue despite a degree of anemia which makes it seem almost inconceivable that the patient should be out of bed.

In the present case there should have been no doubt about the diagnosis, because such marked pallor would have attracted attention at once and led, in all probability, to a blood examination. But if this patient had been one of the 10 per cent. of pernicious anemia cases, which are not pale but show a perfectly normal complexion, the diagnosis would surely have been missed by anyone not accustomed to make *some* blood test as a matter of routine. Even the hemoglobin test will not always set us on the right track in this case, for owing to the high color index the hemoglobin is often but little lowered.

It may be well to recall in this connection that cases of pernicious anemia may come to us in many strange disguises. They may appear without any symptoms suggesting anemia and with complaints merely of paralysis in the legs—a paralysis of the spastic type. Another type of the same disease appears with fever as the presenting symptom, so that typhoid fever is not infrequently the first diagnosis made. Others begin with diarrhea, and any anemia that is recognized is apt to be falsely attributed to the diarrhea, when the etiologic sequence is really in the other direction. The majority of all cases, however, are distinguished by the fact that they present themselves complaining of one symptom only—viz., weakness, a weakness unparal-

leled in any other disease, because it is not associated with pain, loss of weight, or functional disturbances, such as almost invariably accompany any other disease producing a similar degree of prostration.

Outcome.—His previous entry, March, 1908, had shown practically the same signs and course, his red cells rising on that occasion from 1,000,000 to 3,000,000 within two weeks. This was apparently his first attack, but he rapidly relapsed and died August 14, 1909.

Case 199

A schoolboy of eleven entered the hospital June 4, 1909. The child has not felt well for a week and has complained of headache and abdominal pain. These are both gone now. His appetite is good, bowels loose. At times he has spoken of chilliness. There is nothing else of interest in his history.

On physical examination the boy did not look sick. The chest and abdomen were negative. Urine negative. White cells, 12,400. No Widal reaction. No eosinophils. The case was considered one of typhoid fever, though the boy seemed unusually bright and active. Blood-pressure was normal. Skin tuberculin reaction negative. On the 6th there was slight stiffness of the neck and Kernig's sign was present on both sides. The next day muscular tenderness and puffiness about the eyes suggested trichiniasis, but there was no eosinophilia. On the 11th a spinal puncture was done and 10 c.c. of clear fluid obtained, containing no cells or bacteria. On the 12th the heart's apex extended a centimeter beyond the nipple line, and there was a slight systolic murmur which led us to suspect acute endocarditis. The reactions with two different strains of paratyphoid were negative. The fundus oculi was examined and found normal. The middle ears were apparently normal.

Discussion.—Fever without known cause in a boy of eleven is most often due to tuberculosis. When I say "without known cause," I mean without any local lesion, such as an exanthem, a sore throat, a typhoid infection, or a septic focus.

In the present case typhoid seemed at first the most probable diagnosis, although the Widal reaction was negative and the white cells somewhat increased. When later the neck became stiff and the hamstring muscles contracted we thought of meningitis, and tried to get proof of the diagnosis through lumbar puncture. This proving negative, we looked for a confirmatory evidence of trichiniasis, but the persistent absence of eosinophilia made it difficult to confirm such a hypothesis. I feel sure but for the house officer's unusual persistence

we never should have discovered any eosinophilia in this case. Why the blood changes appeared so late I have no idea. Had we been unable to get a bit of calf muscle, the diagnosis might well have been missed, or the case might have been put down as one of those mysterious instances of nephritis without albuminuria, which are met with now and then in literature.

I have no explanation of the marked general edema seen in this case. It was as striking as that of typical acute nephritis,

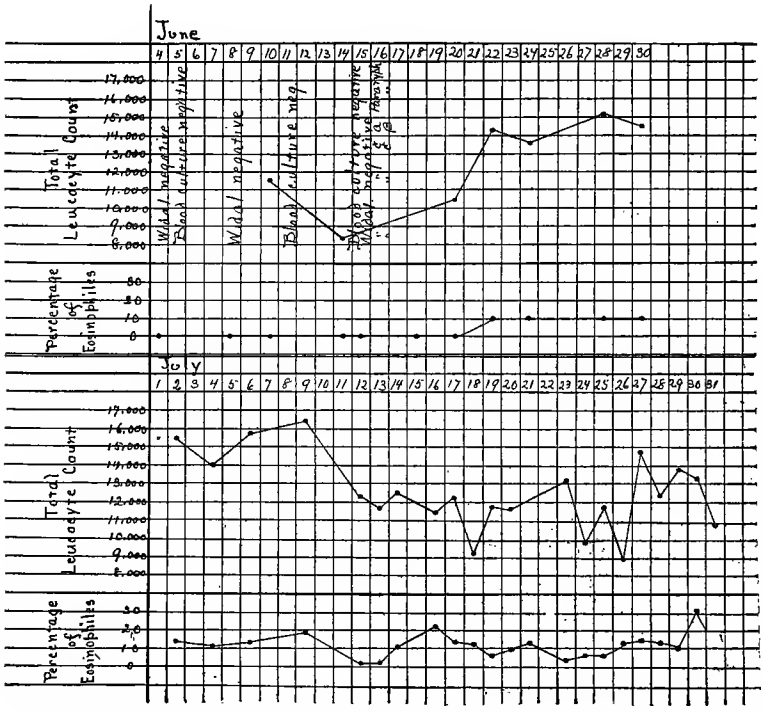

Fig. 173.—Course of (*a*) the total leukocyte count and (*b*) the percentage of eosinophiles in Case 199.

yet the urine gave no support to any such idea. Edema is, of course, the rule in trichiniasis, but it is usually confined to the region of the eyes.

Outcome.—On the 17th a bit of calf muscle was excised and abundant trichinæ were found. There was no infiltration of eosinophils about the parasites. Up to this time there had been no eosinophilia in the blood. On the 22d of June eosinophilia appeared for the first time. On the 4th of July he developed general edema, involving

the hands, legs, back, and abdominal wall. The course of the eosinophilia is shown in Fig. 173. The temperature range is also of inter-

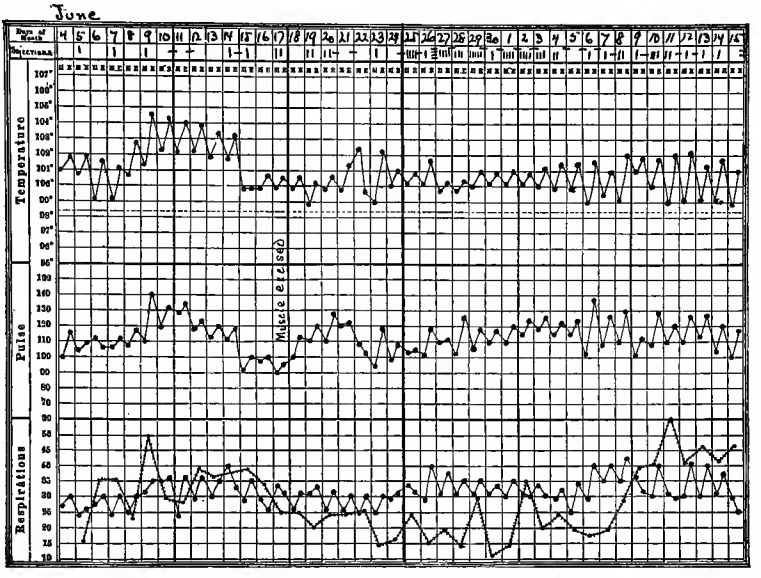

Fig. 174.—Temperature range in Case 199.

est (Fig. 174). By the 20th of July he was up and about, and on the 31st was discharged, the eosinophilia still continuing.

Case 200

A child of four years entered the hospital February 14, 1910. Four days ago the child began to complain of pain and swelling in her legs, said she felt tired, and, later, fainted. At the present time she has pain in the pit of the stomach, in the calves, and the heels. This morning her face became swollen. Her appetite has been poor for six months, and for three weeks she has eaten almost nothing. The patient's father died of tuberculosis and her mother at this child's birth. The child was said to have had tuberculosis of the kidneys when very young, and when two years old had sores all over her hands.

Physical examination shows poor nutrition, heart's impulse in the fifth space, $2\frac{1}{2}$ cm. outside the nipple line, the right border 2 cm. from midsternum. A late diastolic murmur was heard at the apex and, later, a systolic murmur also. Pulmonic second sound was accentuated. In the middle of the left back there were slight dulness and bronchovesicular respiration. The liver dulness extended from the sixth rib to a point $2\frac{1}{2}$ cm. below the ribs, but the edge was not felt.

At entrance the white cells numbered 38,000, from which point they gradually decreased to 17,000, March 14th. The urine was negative, likewise the stools. By the 13th of March the heart was perfectly regular and much slower than at entrance. Although the child was somewhat anemic, she was allowed to go home on the 24th.

She re-entered March 8, 1911. During the year that had passed the child had seemed perfectly well, and had run about as actively as ever. For six weeks she had now complained of being tired and for four days had been in bed, dozing, moaning, and unable to eat. At this time there was a systolic murmur at the apex and a diastolic on the left edge of the sternum. The pulse had a Corrigan quality.

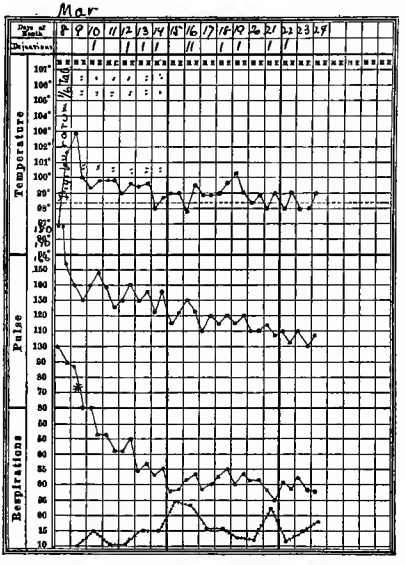

Fig. 175.—Course of temperature, pulse, and respiration in Case 200. Note the extraordinary fall in the respiration. The star near the figure 70 stands for the systolic blood-pressure.

She rapidly improved, the pulse and respiration coming down as shown in Fig. 175. She was discharged on the 24th.

Discussion. — Unfortunately, no Wassermann reaction was done. Without this we cannot exclude syphilis with certainty, but as there is no positive evidence of that disease we may reasonably assume that the other common cause of cardiac lesions in young children—namely, a rheumatic or streptococcic endocarditis—is the correct diagnosis.

The notable point is the extraordinarily high respiration, 100 per minute, as recorded at the time of entrance, and the gradual fall of this rate, which required a full week to reach normal (Fig. 175).

Outcome.—March 8, 1911, the child entered the hospital again, with a clear case of aortic and mitral endocarditis.

April 6, 1913, she reported at the Out-patient Department. She is now going to school regularly and has no cardiac symptoms. The heart's apex is in the fifth space, 7 cm. from the median line. Save for a soft diastolic murmur, loudest over the third left costal cartilage, the heart shows nothing abnormal.

Case 201

A saw-filer of thirty-one entered the hospital January 26, 1910. November 30th, following an active half hour after breakfast, he suddenly vomited "3 quarts" of food and dark clotted blood. After this he felt dizzy and weak, but worked until three o'clock, when he went home and again vomited food and bright blood. In the four days following he vomited blood six times, losing consciousness with the last hemorrhage. He had tarry stools during this attack. Since the 5th of December he has had no more hemorrhages, but soon after that date he had a cramp-like pain in the bottom of his left foot. Tenderness appeared in the inside of the ankle, and shifted up the inside

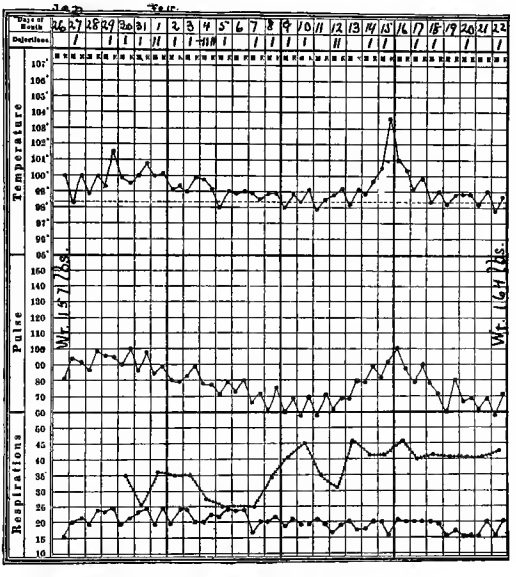

Fig. 176.—Chart of Case 201.

of the leg to the groin in the course of the next seven weeks. Most of the pain at the present time is in the groin. Coincidently with this pain, the whole leg has been swollen. For the past week he has had night-sweats; for the past two weeks, a cough and poor appetite. He sleeps well; since last summer has lost 40 pounds.

The onset of these symptoms was practically acute, though he had noticed some distress in the epigastric region before and after meals for five years. Otherwise his family history and past history are good. His habits excellent.

The course of the patient's temperature is shown in Fig. 176. At entrance his blood showed 3,100,000 red cells, and during his

stay this gradually rose to 3,500,000. Hemoglobin gained during that period from 60 per cent. at entrance to 70 per cent. at discharge. The white cells showed nothing abnormal. There was moderate achromia at all times. The urine was normal. There was no blood in the feces at any time. The heart's apex extended 2 cm. outside the nipple line; the right border 3 cm. beyond midsternum. There was a soft systolic murmur in the pulmonary area, otherwise the organ was normal.

The left foot was reddened and edematous, and from the knee to the groin an irregular cord-like mass was palpable on the inner side of the thigh. The left groin was reddened and edematous and a large mass was felt in the midinguinal region; also at a point 2 inches above the pubic bone, midway between the median line and Poupart's ligament, a small tender mass was indistinctly felt.

On the 31st the patient was seized during the night with a sudden sharp pain in the back of the left lower chest. Morphin was required. Next morning feeble respiration and a few moist râles were detected in a small area in the left back. The edema of the foot thereafter steadily diminished, and by the 13th of February was gone. On the 15th there was a sharp rise in the temperature, headache, nausea, and pain in the right leg. The left leg was then apparently well, and the right leg showed nothing but tenderness in the popliteal space. This lasted until the first of March, when he seemed to be perfectly well and went home with both legs bandaged.

Discussion.—What is the probable relation between the hematemesis and melena with which this patient's illness began and the subsequent edema and pain in the left leg?

It seems to me probable that the slowing of circulation and depression of vitality which the hemorrhage brought about favored the occurrence of phlebitis. That process showed in this case more than the usual evidence of its infectious origin; but there is much to persuade us that most, if not all, cases of phlebitis have an infectious factor in their causation. Very few cultures made from thrombi have ever proved sterile. The anorexia, sweats, and prostration are doubtless due to this infectious element in combination with the weakness induced by loss of blood.

All this, however, does not explain why he has lost 40 pounds in the past six months. Were any evidence of hepatic cirrhosis present, we might easily account in this way for the loss of weight, for the hemorrhage, and the subsequent phlebitis; but, in point of fact, we have not a scrap of evidence on which to incriminate the liver.

The later chapters of this patient's history are to be explained by a migration or recurrence of thrombosis in other veins, first in the lung, later in the right leg. Such recurrent attacks of phlebitis are sometimes extraordinarily tedious and discouraging. They may occur in perfectly healthy people—in my experience generally males—and flit from vein to vein without cause or cessation for a year or more. In the end the whole process usually clears up and leaves good health behind it, but from the point of view of therapeutics we are distressingly helpless.

Outcome.—June 4, 1913, he writes, "I am not what you would call a well man, but I am trying to get by with the rest. In January, 1913, a surgeon removed the veins from both my legs, but they did not come out very well."

Case 202

A butler of twenty-six entered the hospital June 1, 1910. Five weeks ago the patient's ankles were swollen for a few days. Three weeks ago the swelling returned and traveled up the legs and thighs to the abdomen, hands, face, and the top of his head. Except for this he has no symptoms and feels perfectly well, although he has noticed for the past few days some shortness of breath on exertion. His ordinary weight is 155 pounds; now, 172 pounds. Except for a soft, low-pitched murmur at the heart's apex the chest is negative. There is marked edema, as described by the patient. Systolic blood-pressure, during most of the four weeks in the ward, varied between 140 and 150. The highest reading was 170 mm. Hg.; the lowest, 120 mm. Hg. He was afebrile throughout the month of observation. The Wassermann reaction was negative.

The urine averaged 35 ounces in twenty-four hours, was of normal color, slightly cloudy; specific gravity, 1018 to 1023; albumin from 1 to 1.8 per cent. The sediment showed many hyaline and granular casts with a little fat and a few cells adherent. Blood showed at entrance 23,000 white cells, with a polynuclear leukocytosis. This disappeared within a few days. The stools showed ova and live embryos of Strongyloides intestinalis, also a few eggs of Trichiuris trichiuria. He did not improve much during the month in the ward, though his edema readily disappeared when he stayed in bed. Concentrated magnesium sulphate solution, hot-air baths, pilocarpin, and salt-free diet had no considerable effect.

He left the hospital on the 27th of June, and re-entered on the 13th of July in practically the same condition. At this time the abdomen

had to be tapped, and a quart of chyliform fluid was obtained which had a specific gravity of 1006. Examination of the fluid by Dr. W. F. Boos showed the turbidity to be due to pseudomucin. There was no fat present. The sediment was mostly lymphocytes and endothelial cells. He had the same parasites in the intestine and also a varying number of adult hookworms and their eggs.

Discussion.—Bilateral edema, associated with dyspnea, well-marked urinary changes, and a slight increase of blood-pressure, is probably renal in origin, especially as it is associated with such a rapid gain in weight. When there is any possibility of renal or cardiac disease a gain of weight, which we ordinarily welcome, should be viewed, as the politicians say, with alarm.

The only thing to confuse the diagnosis in this case is the presence of three different intestinal parasites and of a somewhat atypical fluid obtained by tapping the abdomen. Neither of these facts, however, is of any importance. Intestinal parasites cannot possibly have anything to do with the production of edema. Only the blood parasite of filaria can produce edema, when it blocks the lymphatics.

The presence of pseudomucin, rendering ascitic fluid milky in appearance, is a spectacular event, often exploited with great satisfaction in clinics, but of no practical importance as far as is known at the present time.

A point of interest in the case is the blood-pressure record. The vast majority of blood-pressure readings are either normal or notably increased. Border-line readings, such as 150, are rare, a fortunate thing for our diagnoses. This means that there is usually no disturbance of function, no symptom that brings the patient to his physician until the hypertension has reached a notable degree. Whether it takes months or years to convert a normal blood-pressure into an elevated one in cases of chronic nephritis or arteriosclerosis we have no means of knowing, but there are certain facts reported by the life insurance companies which lead me to believe that the change may be a relatively sudden one.

If this is true, it would help to explain the fact that we so seldom see the patient when his blood-pressure is slightly or doubtfully elevated.

Outcome.—Blood-pressure ranged between 140 and 150 mm. Hg. for three weeks. The urine was practically the same as during his previous entry. Diagnosis: Chronic glomerulonephritis. He left the hospital on the 29th of July.

Case 203

A clerk of fifty-three entered the hospital June 3, 1910. The patient denies venereal disease, and has never been under a doctor's care before. He has taken five or six whiskies and five or six beers a day for thirty-five years. For a month and a half his legs have been slightly sore and swollen, and for five or six weeks he has noticed some shortness of breath. Yesterday he had a dizzy spell and has had several more since.

On physical examination the patient's pupils did not react to light. There were blotchy pigmented areas scattered over his face and forehead. The heart's apex extended 1½ cm. outside the nipple line. The sounds were very irregular in force and frequency and were of poor quality. Pulses were equal, irregular, of poor volume and tension. Pulmonic second accentuated, occasionally a slight systolic murmur heard at the apex. The abdomen measured 97 cm. the largest circumference, and was markedly dull in the flanks, the dulness shifting with change of position. Knee-jerks were not obtained. There was marked edema of the legs and thighs. Systolic blood-pressure was 130. Blood and urine normal. Laryngoscopic examination showed abductor paralysis of both vocal cords.

Discussion.—In an alcoholic any leg edema is suspected, first of all, of being due to neuritis, but in this case we have, in addition, an ascites suggesting a possible cirrhosis, especially in a man of his habits. Moreover, we have all the evidences of a weakened heart. Syphilis is more than possible in any patient with such a history. Unfortunately, we have no Wassermann reaction, but it may well be that both the heart and the liver have been affected by this disease. Since the knee-jerks are not obtained, and the pupils fail to react alike, there is additional reason for suspecting syphilis and tabes dorsalis as fundamental causes of all his troubles. Whether the heart or the liver is chiefly at fault we cannot, from the facts before us, determine. The abductor paralysis is doubtless of syphilitic origin.

Outcome.—Intubation was considered, but not done. Later in the day tracheotomy was obviously necessary and was done by Dr. Mosher. He died soon after.

Case 204

A maid employed in the hospital, thirty-seven years old, entered the ward July 31, 1910. She has noticed for a week that her legs were

swollen, slightly tender, and slightly painful on walking. At first the right leg was more swollen than the left; now the reverse is true. She has absolutely no symptoms, though the nurses say that she has been inefficient in her work of late.

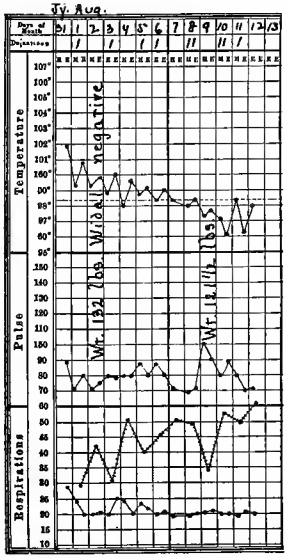

Fig. 177.—Chart in Case 204.

Physical examination is wholly negative, except that the legs and ankles are moderately swollen, the skin red, glazed, and markedly tender. Blood and urine normal.

Discussion.—The general causes of edema are obviously absent. Just what the local cause may be it is not so easy to say, but certainly some cutaneous or subcutaneous disease is the cause of the edema. The absence of leukocytosis makes it improbable that any erysipelas or cellulitis was present. Further than that, without special dermatologic knowledge, we cannot go.

Outcome.—A dermatologic consultant pronounced the trouble **erythema multiforme** in a stage of convalescence. By the 12th of August the whole trouble had disappeared. The range of the temperature is shown in Fig. 177.

Case 205

A fireman of twenty-nine entered the hospital July 12, 1910. A month and a half ago the patient's right ankle and calf became swollen. He felt perfectly well in every other way, and this swelling disappeared in four days. Two weeks ago both legs swelled. This has continued since, although he has absolutely no other symptoms and feels perfectly well. He has had no hereditary taints and no previous illness. He has been a good deal in the Tropics, the last time a year ago. For the past two months he has been drinking heavily and has gained weight.

Physical examination shows that the apex of the heart extends 1 cm. outside the nipple line, the right border 4 cm. from midsternum. At the apex is a soft systolic murmur, heard louder as one approaches the base and loudest at the aortic cartilage. The pulmonic second sound is not accentuated. The knee-jerks are not obtained, and there is brawny edema below the knees; otherwise physical examination,

including the blood and urine, is negative. Systolic blood-pressure, 125. No temperature in ten days' observation, during which time he lost 5 pounds and got rid of his edema.

Discussion.—The patient has been in the Tropics, and the idea of filariasis comes at once to mind as soon as edema of the legs is mentioned. Filariasis, however, almost invariably affects one leg by blocking the lymphatics in the neighborhood of the groin. I have seen no record of a filarial disease affecting both legs.

Beriberi is another tropical disease causing edema and having no predilection for unilateral distribution. This disease, however, is never confined to the legs, though its manifestations may be most marked there. The absence of knee-jerks is compatible with beriberi, but also with the diagnosis next to be mentioned.

It is notable that his excessive alcoholism began shortly before the trouble in his legs. The only reason for any doubt regarding the diagnosis of alcoholic neuritis in this case is the condition of the heart, which appears to be somewhat enlarged, although the abnormality is not very notable. The effects of alcoholism upon the heart have not, in my opinion, been very thoroughly recorded. In some cases we seem to have an acute and ominous weakening of the heart during or after an alcoholic debauch, yet without any permanent changes in the organ. Such, at any rate, is the most natural conclusion from the rapidity with which such patients pick up and their steady good condition thereafter, provided they will stop drinking and continue their abstinence. In the present state of our knowledge it is impossible to determine when one sees a bad cardiac dropsy in an alcoholic whether the condition will result in a permanently weakened heart or whether it will all clear up. We have to wait until the effects of the alcoholism have worn off. After that quite marvelous improvements sometimes occur.

Outcome.—On the 21st of July he seemed to be well and left the hospital.

Case 206

A child of seven entered the hospital July 27th, 1910. Four years ago the boy had a lump appear under the right jaw; after four weeks it was opened and discharged profusely and in two weeks was well. Otherwise he has been perfectly well until five days ago, when small tender tumors were noticed on both sides of his neck. Two days ago he was a little sleepy in the daytime, but played as usual. Yesterday he complained that his shoes were too small and

his ankles were found to be swollen. He lay about the house and would not eat. Last night he seemed feverish and breathed very hard. To-day, for the first time, his urine appeared red.

On physical examination the heart's apex extended 1 cm. outside the nipple line, right border 2 cm. from midsternum. The heart was negative, save that the first sound was somewhat valvular in quality and the strength of successive beats varied a good deal. The lungs were negative. The abdomen showed shifting dulness in the flanks, with moderate edema of the legs. Systolic blood-pressure, 125. The temperature ranged from 99° to 100.5° F. during first week; after that normal. The urine averaged 25 ounces in twenty-four hours, was always smoky in color; specific gravity averaged 1016. The sediment contained much free blood and a moderate number of blood-casts, as well as fine and coarse granular casts. No fat was seen upon the casts in fourteen examinations. At entrance the white cells numbered 25,500, with a polynuclear leukocytosis. This decreased day by day, and was normal August 2d.

Discussion.—Presumably, a tonsillitis or some other oral infection has preceded the glandular suppuration with which this malady was ushered in. When any such infection is followed by edema of the legs, we should at once call to mind the fact that even a very trifling tonsillar infection may be followed by severe nephritis. All the recent milk epidemics of streptococcic sore throats have shown examples of this type of nephritis. The ascites, the fever, dyspnea, anorexia, leukocytosis, and (for a child) the slight hypertension lead us to take the condition of the urine very seriously. The amount of blood in it would probably have made the diagnosis of nephritis inevitable in any case.

What is to be said regarding the condition of the heart? It seems to me more than possible that the same infection which has damaged the kidney has not spared the heart. How great the damage is only time can show. There is no reason, however, to believe that the edema is of the cardiac type. The heart's action is not sufficiently disturbed.

Outcome.—By the 12th of August the albumin had disappeared and the sediment was at that time negative. The edema and ascites had gone and he felt well. On the 13th he went home.

Case 207

A signal man on the Boston and Maine, thirty-nine years old, entered the hospital December 8, 1910. Four days ago the patient

noticed that his calves were swelling. This swelling gradually extended to include the ankles and feet and then the thighs, and was accompanied by constant aching. On further questioning, he remembers that on November 29th he took a 3-mile walk, very unusual for him, after which his legs trembled and felt very weak. For two or three weeks he noticed dyspnea on exertion. For the past four days he has had an unusually good appetite. He worked until last night. He has been steadily gaining weight. There is nothing of interest in his family history or in his past history, except that for several years he has noticed palpitation on exertion or on excitement. He has been a pretty steady drinker for sixteen years, and occasionally takes a drink of whisky before breakfast. He smokes constantly.

Physical examination shows good nutrition, pupils slightly irregular, but reacting normally. The heart is negative except for a very soft systolic murmur at the apex. Abdomen and urine negative. Reflexes normal. Much soft edema of the legs and thighs.

Discussion.—In the absence of any cardiac hypertrophy, and with a systolic blood-pressure of 135, such as is present in this case, with normal blood and urine, it is difficult to explain the symptoms of myocardiac weakness. There is no evidence of any infectious disease and no signs of nephritis. It seems to me that we must attribute the heart weakness, as in a previous case, to the alcoholism. Just why this trouble should have fallen upon him now rather than sooner I cannot say. Only the outcome of the case, carefully followed for months, can tell us whether the heart is permanently crippled or only temporarily poisoned. It is one of the standard wonders, revealed in medical practice, what an alcoholic can throw off in the way of cardiac, renal, cerebral, and other manifestations, provided he can once decide to cut out alcohol.

Outcome.—When examined December 11th the edema had left the calves, but they were still extremely tender. There were then râles in both bases. Wassermann reaction negative. By the 28th of December he seemed to be practically well and left the hospital, having lost 11 pounds in three weeks, owing to the disappearance of dropsy.

Case 208

A cigar maker of fifty-nine entered the hospital March 14, 1912. The patient's only complaint at the present time is of swelling of the legs, which appeared ten days ago. He admits on cross-questioning, however, that a year ago he was in the Out-patient Department com-

plaining of six weeks' dull steady pain across the upper abdomen. At that time he was jaundiced and had morning nausea, but he soon recovered from all these symptoms and has had no treatment since. For the last fifteen years he has passed urine two or three times at night. He now feels strong and works as usual, has a good appetite, and sleeps well. He has no headache, nausea, or dyspnea. He takes two or three whiskies and three or four beers a day. He denies venereal disease.

Physical examination showed a well-developed, flabby patient, making jerky or poorly co-ordinated movements, and with a strong odor of alcohol on the breath. Pupils and reflexes normal. Heart's apex extended 1½ cm. outside the nipple line. Sounds were regular, good quality, no murmurs. Aortic second accentuated. The arterial walls not felt, lungs negative. Abdomen showed dull tympany in the flanks, but no shifting with change of position. The edge of the liver was not felt. There was marked edema of the legs and thighs. Dr. F. C. Shattuck said, "Inferentially, cardiac insufficiency in a potator." My own diagnosis was arteriosclerosis, hypertrophied and dilated heart, cirrhosis of the liver, questionable chronic glomerular nephritis. Stomach-tube examination showed that the stomach was empty before breakfast, was not enlarged or displaced, and contained no free HCl after a test-meal. Wassermann reaction was suspicious March 15th, negative March 19th. Blood-pressure, 190 mm. Hg. at entrance, systolic; 90 mm. Hg., diastolic; 175 mm. Hg. the next day (Fig. 178).

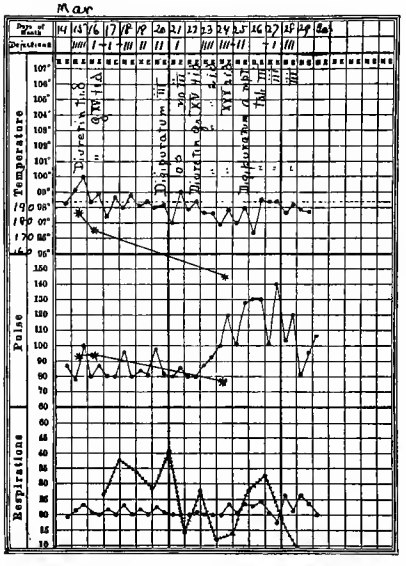

Fig. 178.—Chart in Case 208.

The blood was not remarkable. The urine averaged 30 ounces in twenty-four hours; specific gravity ranged about 1014. There was an occasional granular cast and a little free blood in the sediment. During the two weeks of his stay in the hospital the edema slightly increased, and there was constant mental dulness or confusion. After the 26th he was entirely irrational and took almost no food. On the 30th he died.

Discussion.—Apparently, the first symptom was nocturia. This, as is well known, may be due to either the heart or the kidney, and, as is somewhat less well known, to hepatic cirrhosis. The year's history of jaundice, morning nausea, and steady epigastric pain in an alcoholic patient points strongly toward hepatic cirrhosis. The main question of interest, as it seems to me, is, what else has he? With so high a blood-pressure the heart is almost certainly affected, the kidney very possibly. The presence of free blood in the renal system makes the latter suspicion more probable. We have no reason to believe that the heart valves are damaged. Enlargement and dilatation are the probable inferences. At his age this condition is as likely to be due to arteriosclerosis as to kidney trouble, despite the definite evidences in the urine.

When this patient first entered, we felt that he might clear up like some of the other alcoholics whose history has been given in previous pages. We were not prepared for his steady decline.

Outcome.—Autopsy showed cirrhosis of the liver, arteriosclerosis, hypertrophy, and dilatation of the heart, subacute glomerular nephritis with arteriosclerotic degeneration, obsolete tuberculosis of the left apex.

Case 209

A machinist of eighty entered the hospital March 30, 1912. The patient's father died of what was called "tobacco heart," his mother of shock, one brother of diabetes. His wife died of shock. She has had one child, who is living and well; no miscarriage. The patient lives alone, and spends his time working on an invention for "increasing and transmitting power; that is, for making five pounds lift six pounds." He expects soon to sell the machine for $15,000. For the present he is spending 15 cents a day for food.

For the past three weeks he has noticed swelling of his feet and legs and says that he has lost all ambition. He has no dyspnea. On the contrary, he climbs four flights of stairs a day without resting and without losing his wind. He has no headache, good appetite and digestion, and says he has not lost weight or strength.

Physical examination showed poor nutrition, pallor, and dry skin. Pupils and reflexes normal. Heart and urine negative. Arteries slightly tortuous and beaded. Blood-pressure, 155 mm. Hg., systolic; 90 mm. Hg., diastolic. Blood and urine normal. No fever in ten days' observation. The edema disappeared in a week, during most of which time he was eating or sleeping. At the end of that time

he was anxious to go back to work, and was allowed to go home. Treatment consisted of magnesium sulphate, 1 ounce in concentrated solution before breakfast, for two days. This, with an occasional hypnotic and laxative, was all that was given him.

Discussion.—At this patient's age, and with arteries like those described, it is almost inevitable to attribute his edema to arteriosclerosis, even though he has shown no dyspnea or distinctively cardiac symptom.

At this age an edema of the legs is a much more serious symptom than in a younger person. With the absence of headache, marked hypertension, and anemia it does not seem possible to incriminate the kidney. There is nothing pointing to cirrhosis. Cardiac weakness, therefore, is our best surmise.

Outcome.—He died October 28, 1912, at Tewksbury State Hospital. Diagnosis: Arteriosclerosis and acute bacillary dysentery. Two months earlier he had seemed quite well.

Case 210

A man of twenty-three, in a cotton mill, entered the hospital April 13, 1912. The patient's family history is negative. His mother tells him that when he was a year old his face was so swollen for two months that he could not open his eyes. Otherwise his past history and habits are good. When he was five years old, his right leg, below the knee, began to swell, and a few years later his left. This swelling has slowly increased ever since and has extended into the thighs and scrotum, but not elsewhere. It is always less when he lies down and can be reduced by the use of a rubber bandage. There is no pain or other discomfort. At intervals of from three to five months (except during the last two years) he has had attacks, substantially as follows: Severe pain and tenderness would appear in both groins, soon followed by a shaking chill and the vomiting of much fluid, then by a fever and somnolence. He has not lived in a malarial region, so far as he knows. His urine has never been milky, but he passes it twice or thrice in the night. The swelling of his legs has never interfered seriously with his work, and has sometimes been a source of income in circus shows.

On physical examination the right pupil is larger than the left; otherwise both are normal. The chest and abdomen show nothing of interest. The condition of the legs is shown in Figs. 179 and 180. The skin of the thighs and calves was much thickened and covered in places with crater-like elevations, some old and white, some recent

and red. The right calf is 88 cm.; the left, 68 cm.; the right thigh, 83 cm.; the left, 82 cm. Blood and urine were normal. No fever in two weeks' observation.

By the use of silver ointment the skin became soft and clean. He was kept in bed with the legs raised, but given no medicine. During

Fig. 179.—Condition of legs in Case 210 at entrance.

Fig. 180.—Condition of legs in Case 210 at entrance.

the last three days of his stay in the medical ward he voided 430 ounces of urine (Fig. 181), with marked reduction in the size of his legs.

Discussion.—An enlargement which has existed since the age of five, and which was confined for some years to one leg, has evidently

the local, not the general, type of etiology. The statement that his urine has never been milky and that he has never lived in the Tropics tends to rule out filarial disease. Blood examination is also quite negative.

We cannot call the condition hereditary, since he was free from it for the first four years of his life. What was the cause of his swollen face when he was a year old? We can only conjecture. With the exclusion of heredity, trophedema, and filariasis, we have nothing but elephantiasis left, and the local signs support this diagnosis.[1]

Of much interest was the prodigious diuresis which we were able to observe when we got him at rest in bed. Clearly, the juice was

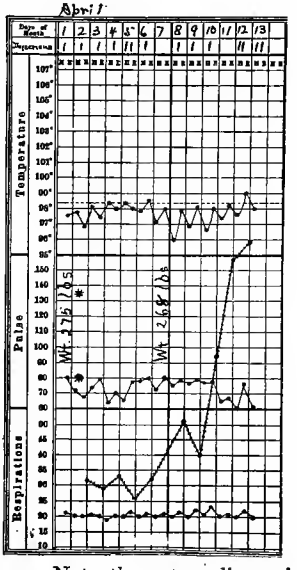

Fig. 181.—Chart of Case 210. Note the extraordinary increase of urinary secretion (recorded in ounces).

running out of his legs. Edema was, therefore, an element in his condition. Of further interest is the result of operation shown in Figs. 182, 183.

Outcome.—He was transferred to the surgical wards, where a considerable amount of the hypertrophied tissue was removed. The resulting changes are shown in Figs. 182, 183. The thighs after operation measured 22 inches; the calves, 17½ inches. Examination of the

[1] "Three Cases of Sporadic Elephantiasis of the Lymphatic Type," by George C. Shattuck, M. D., Boston Med. and Surg. Jour., January 27, 1910; "Etiology of Elephantiasis," by George C. Shattuck, M. D., Boston Med. and Surg. Jour., November 10, 1910.

excised tissue, by Dr. W. F. Whitney, showed fibrous tissue filled with lymph-spaces containing serum. The fibrils were more or less separated by serous fluid. The patient left the hospital on the 25th

Fig. 182.—Condition of patient's legs after operation (Case 210).

Fig. 183.—Condition of patient's legs after operation (Case 210).

of May, 1912. In February, 1913, the patient writes that he is feeling very well, and that the elastic stockings which he is now wearing prevent any recurrence of the enlargement at the site of operation.

Case 211

A draughtsman of sixty-five entered the hospital May 11, 1912. The patient's wife died of tuberculosis thirty years ago. His family history is good. He has two children living and well. He remembers no previous illness, and says he has been well and strong. He has taken no tobacco or alcohol and denies venereal disease. He has been

accustomed to work twelve to eighteen hours a day, and has taken long bicycle rides on Sundays. He entered the hospital with a diagnosis of "chronic nephritis and chronic bronchitis," made by his family physician.

For three months he has been running down, losing weight, strength, and ambition. For two months he has had moderate swelling of the feet and a persistent dry cough. His appetite is poor, his digestion good. He has had no headache, no nausea, no dyspnea or nocturia. He sleeps well. Cramps in his hands and feet he has noticed for three or four years. He finished his contract as a draughtsman this morning, then immediately gave up and came to the hospital. Two months ago he weighed 136 pounds, with his clothes; at entrance he weighed 108 pounds, without clothes.

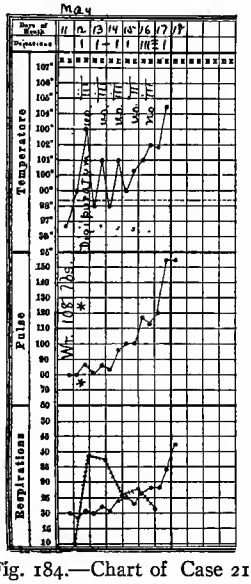

Fig. 184.—Chart of Case 211.

Physical examination showed obvious emaciation, but nothing abnormal was detected in the chest or abdomen except spasm and dulness in the right hypochondrium. The urine averaged 35 ounces in twenty-four hours; specific gravity, 1020; very slight tracè of albumin and a few granular casts. Blood normal. Blood-pressure, 125 mm. Hg., systolic; 75 mm. Hg., diastolic. My diagnosis was arteriosclerosis, myocardial weakness, vascular crises in the peripheral arteries. The course of the temperature is shown in Fig. 184. Wassermann reaction negative. He coughed up a good deal of mucopurulent sputum which contained no tubercle bacilli. His edema rapidly cleared up, his heart seemed to be well compensated, and his chief trouble seemed to be malnutrition. He slept most of his time and took food poorly. On the 17th râles were noted throughout both lungs, especially in the middle of the left back, where they were coarse and loud. At the same time he became incontinent of urine and feces. He was considered to have a terminal bronchopneumonia.

Discussion.—It seems to me altogether pathetic that a man of his age, with such obviously serious illness, should have worked up to the very day that he entered the hospital. His history is of three months' weakness, with two months of cough and edema of the

feet, and the loss of 20 pounds in this time. The cause of his edema and fever we were altogether unable to determine. We supposed his cough to be of nervous origin, though possibly due to cardiac weakness. There was nothing of any special significance in the lungs until the day before his death, and the conditions then found were taken as terminal rather than etiologic.

The case illustrates a total failure of our diagnostic resources.

Outcome.—He died on the 18th. Autopsy showed chronic tuberculosis of both lungs, general miliary tuberculosis, tuberculous peritonitis, tuberculosis of the ileum, slight arteriosclerotic degeneration of the kidneys.

Remarks.—In looking back upon the case in the light of the autopsy I do not see how we could have done much better. The edema was doubtless due to an infectious myocarditis with weakening of the heart's action.

Case 212

A shoemaker of eighteen, born in Turkey, entered the hospital June 22, 1912. He quit work two weeks ago because of swelling of his feet, headache, and nosebleed. He has never been sick before and has excellent habits. During the two weeks that have passed the swelling has extended up the legs and thighs, but has never been noticed in the face. Appetite and digestion are excellent, eyesight good, no dyspnea or nocturia.

Physical examination shows a respiration suggesting Cheyne-Stokes. The heart's impulse seen and felt in the fourth space, $\frac{1}{2}$ cm. outside the nipple line. No enlargement on the right. Pulmonic second greater than the aortic second. Apex second sound ringing. Radials and brachialis slightly roughened. The course of the blood-pressure is shown in Fig. 185. The urine averaged 25 ounces in twenty-four hours for the first week, with a very slight trace of albumin and a moderate number of hyaline casts, some with a few cells adherent, many red corpuscles. Blood negative. Wassermann reaction negative. After two days in the ward, with a nephritic diet, and 1 ounce of concentrated solution of magnesium sulphate every morning, the edema was gone. A week after entrance the urine rose to 70 ounces and the patient felt perfectly well. At times there was a suggestion of presystolic thrill and roll at the apex.

Discussion.—Edema of the legs in a man of eighteen, associated with headache and nosebleed, and later with Cheyne-Stokes' breathing and hypertension, compels us to make the diagnosis of nephritis,

whatever the urine shows. As a matter of fact, the urine would probably have inclined us strongly toward such a diagnosis even had the other symptoms been less clear.

The point of interest is to determine whether this is an acute nephritis, as the history suggests, or an exacerbation of a chronic process. At the time of entrance the blood-pressure of 215 mm. Hg. made me feel confident that we were dealing with a chronic case, and even when the pressure had declined so wonderfully (Fig. 185) I still felt that the case must be a chronic one.

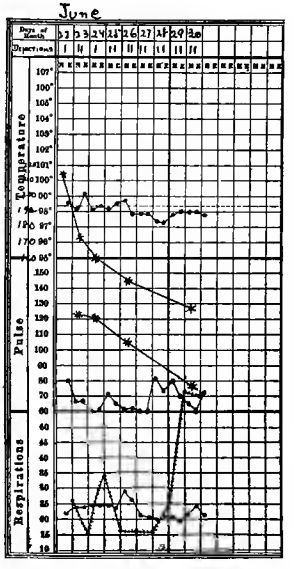

Fig. 185.—Showing course of systolic and diastolic blood-pressure (starred lines) in Case 212. Note the diuresis as blood-pressure falls.

Outcome.—The patient left the hospital July 1st. March 19, 1913, the patient's physician writes that he is feeling perfectly well and working daily. The doctor has recently examined his urine and finds it entirely normal.

Remarks.—In view of this outcome, it seems to me clear that I was wrong in calling the case chronic rather than acute nephritis. If so, it is a matter of some importance as proving that even a temporary and curable disease of the kidney may produce so marked a hypertension.

CHAPTER XI

FREQUENT MICTURITION AND POLYURIA

POLYURIA, or an abnormally large daily excretion of urine, is, of course, quite different from *frequency* of urination. Nevertheless, they are so often associated in cases of disease that it is convenient to consider them in the same chapter.

Persons vary a good deal in perfect health in the number of times that they pass urine during twenty-four hours. The great majority of healthy persons do not have to rise during the night to pass urine, but in a small majority this is *habitual* and does not seem to depend upon any unusual amount of water ingested during the evening. Of course, it is obvious and familiar that anyone who takes a large amount of *liquid, especially of beer, during the evening,* is likely to have to pass urine during the night; but aside from this cause, and from the rare cases of habitual nocturia, there are a good many people who suffer from nocturia whenever they are "nervous." Sometimes it appears as if both the *nervousness* and the increased frequency of micturition had a common cause in the nervous and vascular ataxia. If this is so, we cannot truly say that the nervousness is the cause of the urinary trouble, but is rather a concomitant effect of a deeper cause, perhaps low peripheral pressure and splanchnic congestion.

Aside from these temporary causes, any of which may, of course, act during the day as well as during the night, the commonest type of urinary frequency is that associated with *prostatic enlargement,* whether simple or carcinomatous. In elderly men this is by far the commonest cause of frequency.

In women the pressure of *uterine* or *ovarian tumors* and the irritation of pelvic exudates blend their effects with psychic influences in a way that makes it difficult to distinguish the two. Either or both sets of causes affect women all the more strongly because of the shortness of the female urethra.

Bladder irritation, whether from definite cystitis or from the presence of urine sent down from a tuberculous kidney, is perhaps the next most frequent cause of urinary frequency. Cystitis, of course, is also an accompaniment of many prostatic enlargements in men.

In children the irritation due to hyperacid urine, to balanitis, or to phimosis may be sufficient to produce frequency or even incontinence.

Among the rarer causes of frequency are stone in the bladder, cancer of the bladder, bilharzia disease, and appendicitis. All of these act, of course, through the local irritation of the disease present.

In diabetes and contracted kidney frequent micturition is the result of a large amount of urine which has to be discharged. It is noticed most at night.

Pregnancy is a common cause for urinary frequency.

Just why the local affections of the kidney and renal pelvis (nephrolithiasis, pyelitis, pyelonephritis, renal tumor) produce urinary frequency I do not clearly understand. To call the frequency reflex is merely to cover up our ignorance. Perhaps the urine itself is especially irritating to the bladder wall. But why?

Case 213

A butler of forty-three entered the hospital December 21, 1911. His family history was not important save that one sister had phthisis. He has had no serious illness in the past, but has been troubled with constipation, poor appetite, and sleeplessness. He has used considerable alcohol up to six months ago, but none since. He denies venereal disease, but has taken potassium iodid and mercury for two or three years. There has been pain of five years' duration in the abdomen and over the symphysis every month or less, accompanied by constipation. Diagnoses of constipation, then of lead-poisoning, and later of chronic appendicitis have been made. About one and a half years ago a lump appeared on the scalp, was not painful, but broke, discharging yellow serum (?). A few months later another appeared and also broke. Both healed very slowly after discharging a couple of months.

Eight weeks ago, after a movement of bowels, he urinated; at end of urination gas came out of the penis. Since then he has had burning and painful micturition, frequency and cloudy urine, at times very foul and of a peculiar muddy color. There has been considerable loss of weight during the past two months (20 pounds ?). Frequency is not so marked of late, but he continues to pass gas, which is preceded by a peculiar pain. There has been no cough, dyspnea, or night-sweats, but he has had an occasional chill. He has taken some morphin, but not recently. He has never noticed blood in the urine, but there has always been a thick sediment. At times he has had pain in the left sacro-iliac region.

Frequent Micturition

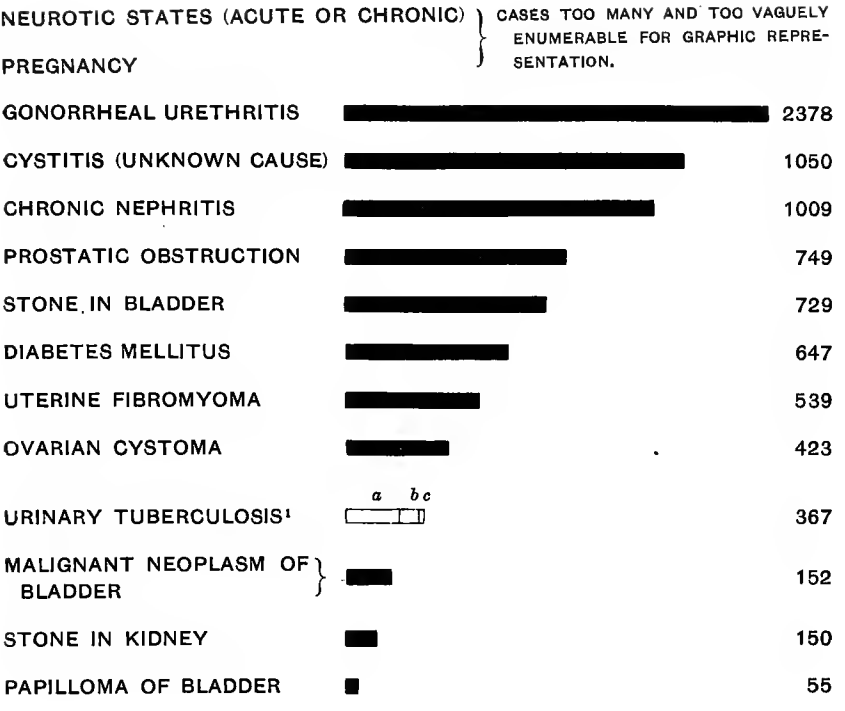

[1] Urinary tuberculosis—*i. e.*,

(*a*) Tuberculosis of the kidney 248
(*b*) Tuberculosis of the bladder 94
(*c*) Tuberculosis of the kidney and bladder..... 25

On examination, he is rather thin and pale; ears waxy. The right pupil is larger than the left and both react normally. There are two scars of abscesses in the scalp. The throat is red; breath foul. There are no glands and the heart is negative. In the lungs the right apex is duller than the left, with breath sounds exaggerated, fremitus increased, and an occasional musical râle. The abdomen is negative save for a burn-scar. The genitals are normal; knee-jerks present.

The patient passed 4 ounces of cloudy urine, the last ounce of which was thick, white, and caused some burning. There was no blood seen, no "gas." Temperature, 99.6° F.; pulse, 108; respiration, 32. The white cells were 8600. The urine was normal, acid; specific gravity, 1012; albumin, slightest possible trace, no sugar. The sediment contained leukocytes, bacteria, a few red corpuscles, and many pus clumps. Wassermann reaction was slightly positive. Cystoscopy was done and the bladder washed clean. In upper left quadrant was what appears to be the opening of a sinus from which a plug of pus protruded. No discharge of pus seen.

0.6 gm. of "606" was given; considerable discomfort and vomiting followed. During the next three weeks the patient showed little change, and was given a second dose of "606," with some discomfort. A second cystoscopy shows the same ulcer previously seen, from which a ribbon of pus can be squeezed out by pressure on left lower quadrant of abdomen. The specific gravity of the urine at this time is 1012, with a slight trace of albumin, much pus, and red cells. No fecal matter can be found.

Discussion.—Pneumaturia, or the passage of gas with the urine, may be due to infection of the urinary tract by bacilli-producing gas or to a communication between the bladder and the intestinal canal. Among the micro-organisms which produce gas in the urine the commonest are the yeasts, which in diabetes often fill the urine with air-bubbles. Apparently the colon bacillus is also capable of splitting up sugar in the urine so as to produce pneumaturia. In the present case the extreme foulness of the urine and its peculiar muddy color suggest a communication between the bladder and the rectum.

Some features in the case suggest syphilis, notably the lumps upon the scalp, the history of antisyphilitic treatment, and the Wassermann reaction. If the patient is syphilitic, it may well be that a gummatous process of the lower bowel has perforated the bladder, so that the intestinal contents are discharged with the urine.

Another possibility is of a diverticulitis connecting with the bladder.

The results of cystoscopy leave little doubt that such a communication exists.

Outcome.—On the 18th of January the abdomen was opened and a mass the size of the fist was found, involving the sigmoid flexure and its appendices. There was also an abscess near the rectum. After the drainage of this abscess the patient improved, had normal bowel movements, together with a profuse foul purulent discharge from the wound. Rectal examination, February 8th, showed considerable thickening and moderate tenderness, but no fluctuation high up upon the left. The temperature was from one to two degrees above normal.

The urine was now pale, cloudy, 1008 in specific gravity, free from albumin and sugar, free from gas, and showing nothing of importance in the sediment. On the morning of June 20th the patient complained of shortness of breath, became excited, and rather hysterical. The temperature was then 99° F.; pulse, 110; respiration, 20. During the afternoon the pulse was of poor quality, heart sounds regular but weak, and there was distention and pain in the abdomen. Next day he died, rather suddenly. The autopsy showed a retroperitoneal pelvic abscess, presumably arising from diverticulitis of the intestine. The lesion upon the scalp was regarded as probably a gumma.

Case 214

A tailoress of thirty-eight, born in Russia, entered the hospital June 24, 1908. The patient's mother died of cancer of the stomach at sixty-three; otherwise her family history is excellent. She had typhoid fever fifteen years ago. Four years ago she had an illness of six months' duration similar to the present.

For three months her urine has been thick and red and for eight days bloody, and passed, as she says, about forty times a day, with great pain. She has no other symptoms.

Physical examination was negative, save for a slight systolic murmur at the apex of the heart and tenderness over the pubes. The urine showed considerable sediment of pus and blood, otherwise nothing abnormal. The blood was negative. There was no fever in two weeks' observation. A catheter specimen of urine, drawn under aseptic precautions, showed, on bacteriologic examination, atypical streptococci. It was then injected into a guinea-pig, July 1st. August 29th, autopsy of this animal showed nothing.

Cystoscopy, June 25th, by Dr. Fred T. Murphy, showed no stone and nothing abnormal about the ureters. The base of the bladder was

generally injected. The patient showed no reaction after the injection of 10 mg. of old tuberculin. A vaccine was made from the streptococci isolated from the urine and administered.

Discussion.—The history of typhoid fever fifteen years ago brings to our mind the possibility of typhoid cystitis, since we know that typhoid fever is prone to settle down into the bladder after the patient is otherwise well.

But this is apparently an acute cystitis, lasting only three months and beginning suddenly. It is hard to connect such an illness with the typhoid fever of fifteen years ago. The whole question is as to the nature of the cystitis. We have no reason to believe that it is due to any disease either above or below the bladder, although in the vast majority of cases cystitis is to be thus explained and is not an independent entity. The fact that streptococci are the only organisms discoverable does not in any way prove that the lesion is not tuberculous, for tubercle bacilli may easily be overgrown by organisms of more rapid development. Much more important is the negative result of animal inoculation, which may be taken as practically excluding tuberculosis.

The cause of cystitis remains somewhat of a mystery. The time at which the disease originated is the time when streptococcic infections, especially those showing themselves in the throat, are most common. Is it not possible that a streptococcic infection was arrested in its way out of the body and took root in the bladder?

Outcome.—By the 5th of July she was much better, and was allowed to continue her treatment in the Out-patient Department. July 18, 1908, she reported that she was still urinating every half-hour. The urine was normal.

December 26, 1908, the patient was complaining chiefly of precordial distress with occasional dyspnea. The heart and abdomen showed nothing abnormal. She was evidently worrying a good deal.

As the urine continued to contain streptococci, on May 11, 1909, cystoscopy was advised, but refused. A guinea-pig test, made with the sediment of the urine, showed no evidence of tuberculosis.

June 24, 1910, she reported that she was passing water every fifteen minutes. The urine at that time contained considerable pus. She was given an injection of 10 per cent. argyrol, and a week later the urine was considerably improved.

February 21st the urine was in all respects normal, except that the specific gravity was 1006.

July 12, 1911, she reported that she no longer was troubled about

her urine. She came then for pain in the back, thought to be due to a strain from falling down stairs.

December 16, 1913, she came to the hospital for coldness and pain in the little and ring fingers of the left hand. Hydrotherapy was advised and produced much improvement.

Case 215

A housekeeper of thirty-four entered the hospital August 5, 1908. The patient's mother died of cancer; one brother of "blood-poisoning"; her father of "asthma"; one brother in infancy. Another brother was murdered. The patient had rheumatic fever twelve years ago and typhoid fever ten years ago. She has taken a good deal of wine, ale, and brandy.

As long as she can remember she has been troubled with frequent and somewhat painful micturition. At the time of menstruation this trouble is increased and is associated with headache and backache. For the past two years her symptoms have been much worse, and the desire to pass urine is almost constant, though, in fact, she passes it about seven times during the day and not at all at night. She has worn a pessary without relief. Her urine has been normal in appearance. She has been able to do no work in the past two years on account of backache.

On physical examination, the patient was well nourished and showed no abnormalities except a blowing, systolic murmur at the base of the heart and an antiflexed uterus. The urine was normal. The blood showed hemoglobin, 65 per cent.; red cells, 4,860,000; white cells, 5700. The stained smear showed achromia, but was otherwise negative. While in bed she had no trouble with frequency.

Discussion.—The rheumatism of twelve years ago, the typhoid fever two years after that, and the alcoholic history are probably of no special significance in this case. A point of great importance is the presence of *frequency only in the daytime* and worse at the time of the menstrual period. This would seem to connect the symptom with the pelvic organs, and the fact that the urine looks normal strengthens the plausibility of this theory. Any type of cystitis is likely not merely to produce abnormalities in the urine which the patient herself notices, but to distress her as much at night as in the daytime.

The idea of those who saw this patient in the hospital was that local irritation from the anteflexed and deformed uterus was the cause of this patient's frequency, but I think the conclusion may be

doubted. One sees so large a number of people who have exactly the same pelvic condition without any frequency at all that I am inclined to believe that another factor is the important one—the factor, namely, of individual hypersensitiveness, which would probably have resulted in frequency even had the uterus been wholly normal. The common tradition which attributes urinary frequency to anteflexion of the uterus rests, I think, upon insecure foundation, for the reason suggested in the last sentence.

I believe that the patient's anemia and general debility, as shown in her headaches and backaches, have rendered her oversensitive on the physical side, and are the chief factors in accounting for her frequent micturition.

Outcome.—An examination under ether, August 14th, showed that the uterus was drawn to the right by what seemed to be a tubo-ovarian mass. Operation showed a fibroid, the size of a hen's egg, on the right side of the uterus, near the fundus, and another posteriorly. These were both shelled out and removed; a ventrosuspension was done. The patient convalesced normally and left the hospital on the 2d of September, 1908. September 17, 1909, she reported, in answer to a letter, that she was still troubled by pain at the time of urination. No cause for this pain was found. I believe it due to a nervous hypersensitiveness.

Case 216

A housewife of thirty-four, born in Austria, entered the hospital April 12, 1909. For the past four months she has passed urine very frequently, sometimes as often as every half-hour, with pain and burning after it. Sometimes the urine looks normal, sometimes like coffee. Three weeks ago she gave birth to a child, and for a week after that time her symptoms were relieved, then they recurred, and were as severe as before. Two years ago she weighed 120 pounds, with clothes; now, 78¼ pounds, without clothes. She has no appetite and occasionally vomits. She remembers no previous illness and has had five living children.

Her mother died of "a cold"; otherwise the family history is good. The patient was poorly nourished and pale. The chest was negative. In the left upper quadrant of the abdomen was a rounded mass, the size of an orange, transmitting an impulse to the flank and back when grasped bimanually (Fig. 186), descending slightly with respiration; slightly tender. After inflation of the colon, tympany appeared over the mass. There was tenderness in the left costovertebral triangle,

none in the right. There was slight edema of the ankles. Physical examination was otherwise negative. The blood was normal. The urine averaged 20 ounces in twenty-four hours; specific gravity, 1026; albumin, a trace; sediment, much pus, a few red corpuscles, no casts. The patient had no fever above 99.5° F. during her week's stay in the medical wards. The temperature always fell to normal in the morning.

Cystoscopy, by Dr. Lincoln Davis, showed a sluggish stream of thick pus issuing from the left ureter. Indigocarmin was excreted normally from the right ureter and none at all from the left. The bladder was somewhat inflamed and sensitive, but showed no ulceration.

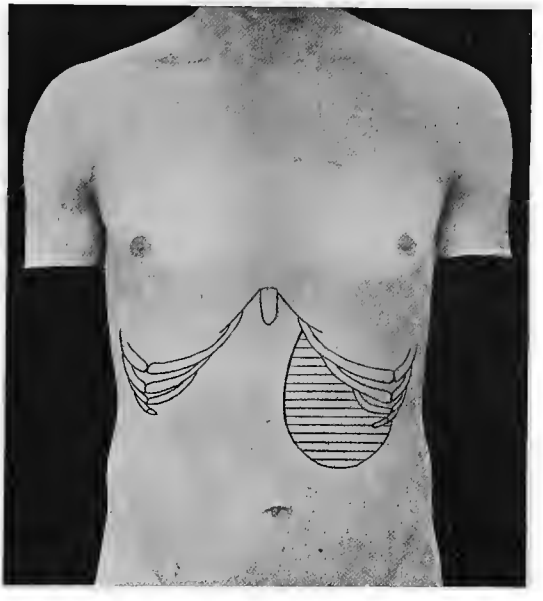

Fig. 186.—Mass felt in Case 216.

Discussion.—When the urine is said to look like coffee we must remember that the presence of precipitated urates or phosphates is the commonest cause of such an appearance, and renders it, in the great majority of cases, medically insignificant. Provided, however, that the urinary turbidity is due to pus and micro-organisms, there is something in the intermittence of its turbidity which suggests pus of renal origin. When pus comes from the kidney rather than the bladder it is discharged intermittently into the urine, so that some specimens are clear and others turbid. In cystitis, on the other hand, every specimen is turbid.

The emaciation, the family history, the mass in the region of the left kidney, and the abnormal urine shown on examination to contain pus, make it clear, even in advance of cystoscopy, that we are dealing with a purulent affection of the kidney, that is, either with pyonephrosis, pyelonephritis, or tuberculous kidney. The absence of ulceration in the bladder favors a non-tuberculous renal lesion.

Outcome.—Operation, April 21st, showed a kidney increased in size transformed into a sacculated tumor, 15 cm. in diameter and filled with pus. The ureter was much thickened. No definite evidence of tuberculosis was found. The kidney and 7 cm. of ureter were removed without difficulty. The patient made an excellent recovery and left the hospital May 24th, apparently well.

Case 217

A housewife of forty-nine entered the hospital December 11, 1911. The patient's mother died of cancer in the neck; otherwise her family history is good.

Thirteen years ago she began to have marked frequency of urination, passing water every fifteen minutes in order to relieve her pain in the region of the bladder. At times the stream was checked suddenly, causing great pain. Twelve years ago she was in the Massachusetts Homeopathic Hospital, but did not improve. The above symptoms continued until ten years ago, when she began to have incontinence of urine, which has continued ever since, *except for some periods of eight to ten hours, during which she has severe pain.*

Physical examination shows a stout woman, good color, negative chest and abdomen, lacerated peritoneum, exquisite tenderness over the urethra. On the 12th the patient was anesthetized, the urethra dilated, a searcher introduced, and a stone felt, apparently incrusted in the tissues at the neck of the bladder. It was crushed and washed out. The fragments examined by Dr. W. F. Whitney were shown to be portions of phosphatic calculus.

Discussion.—So long a history of frequency and incontinence, without any lesion of the central nervous system, makes us suspect an organic lesion of the bladder, benign in type—in other words, a stone. Subsequent results of sounding, and the position of the stone in the neck of the bladder, make it probable that sphincteric efficiency cannot be restored, and that when this stone is removed another is quite likely to re-form in the old ulcer left by the first.

Outcome.—After operation the patient was more comfortable, but still incontinent of urine, and continued so at the time of discharge,

December 21st. On December 3, 1912, the patient writes, "I am no better than when I left the hospital, in some ways not as well, as I suffer more pain now than I did then. I am not having any doctor now, as they don't seem to do me any good. Sometimes I think I will see a doctor and perhaps he can give me something for the pain, but I have no faith in any of them. This is rather a hard way to talk to a doctor."

Case 218

A housewife of thirty-one, born in Russia, entered the hospital March 5, 1901, for the first time, for pelvic pain, which had been present for a year since the birth of her last child. Operation by Dr. Maurice H. Richardson showed double pyosalpinx. One tube was removed, and on the other a plastic operation was done so as to make possible the passage of the ovum. The patient convalesced rapidly and left the hospital on the 8th of April, after which she was perfectly well until a few weeks before her next entrance to the hospital, December 15, 1909, when she began to be bothered very much by frequent micturition, constipation, hemorrhoids, and pain in the lumbar region. She is also much troubled by her heart. She says that her urine is small in amount, but never bloody.

Physical examination shows excellent nutrition, and is negative in all respects except for very slight edema over the shins. The blood and urine show nothing abnormal. She is very apprehensive about her heart.

Discussion.—It all comes to this, that the patient's physical examination is negative, that she has many complaints affecting all parts of her body, and especially, as I see it, that she is afraid of heart trouble. This point is of importance, and it may well be that by psychotherapy addressed to cure *this* fear, her urinary frequency may, without any direct attack, be conquered. It is in just this type of case that we must hunt for psychic and social causes if we are to make treatment effective. We ought to know everything we can about this patient's environment, physical and psychic, in order to aid her state of mind if we are to help her bladder symptoms.

In any such psychotherapy the first and most important step is a thorough physical examination and the elimination of doubt, first from our own mind and then from the patient's mind, regarding organic disease. In the first instance, it does not seem to me that cystoscopy is called for in a case of this kind. If our other efforts fail, we must come back to that. First, we should try the effect of telling

the patient that she can and must control her frequent micturition. Patients are apt to think that dreadful consequences will follow any such attempt to control. When they are assured to the contrary, they may, within a day or two, convince themselves of their power to check the symptom unassisted.

Outcome.—When reassured about her heart and given a week's rest she was able to control the frequency of micturition, and was finally convinced that it was a matter of habit. She left the hospital on the 20th.

Case 219

A milliner of forty entered the hospital April 2, 1910. Her mother died of consumption at forty-six. Her family history is otherwise good. The patient herself had "typhoid fever" fifteen years ago.

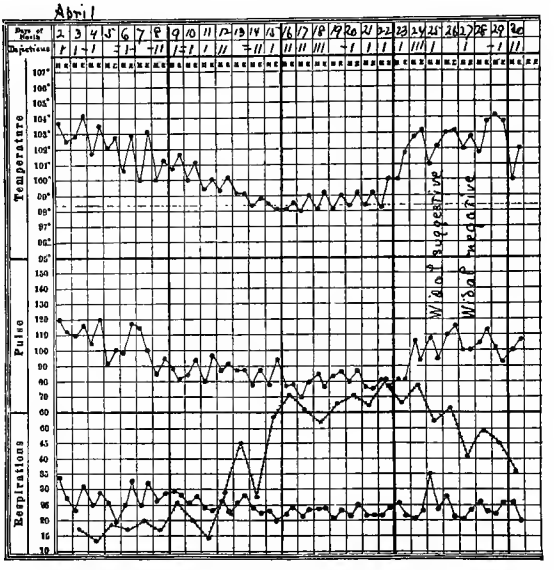

Fig. 187.—Chart of Case 219 (first entrance).

Twelve years ago, and again eight years ago, she raised blood in small amounts. On the second occasion she was awakened from sleep by the bleeding. She has had "bladder trouble" ever since she was a child; *i. e.*, intermittent attacks of frequency and burning micturition. She has always been subject to severe "colds." Since she got stout, four years ago, she has had some shortness of breath.

Ever since her typhoid she has noticed that her legs are swollen at night. A year ago she had no menstruation for three months, but since then she has been regular.

Ten days ago she "took cold," and began to have bladder trouble as before. The next day she had chills, headache, and pain over the pubes. Last night she vomited.

On physical examination she was well nourished. Her chest was negative, except for a soft systolic murmur at the apex, transmitted to the axilla. Abdomen negative. At entrance the diagnosis was of acute infection of unknown cause. Next day the patient's scleræ were slightly yellow. The urine for the first ten days averaged 20 ounces in twenty-four hours, then rising to 60 ounces (Fig. 187). The specific gravity varied from 1013 to 1021. Pus was always present in the sediment in large amounts, even when the urine was drawn by catheter. At entrance the blood contained 28,000 leukocytes per centimeter, with a polynuclear leukocytosis. The counts thereafter were—April 4, 22,000; April 7, 14,500; April 13, 8000; April 27, 10,000. Wassermann reaction was negative. Her vomitus, April 4th, contained brownish material and showed positive test for guaiac. On the 10th of April diminished breathing was noticed in the right back and diminished excursion of the lower right lung border.

Cystoscopy, April 11th, by Dr. Hugh Cabot, showed chronic cystitis. The ureters looked normal. The right kidney excreted indigocarmin in normal time and amount. The left kidney excreted nothing but thick yellow pus. Culture from the urine, which was always acid, showed only a slight growth of cocci, probably due to contamination. Blood-cultures were negative; 1 cm. of urine from the left ureter was injected into a guinea-pig, April 6th. Autopsy, May 23d, showed nothing.

Discussion.—There is a good deal of evidence pointing to tuberculosis in this case, but the very long duration of her symptoms, thirty years or more, makes it very improbable that they are due to tuberculosis.

The fifteen years of edema affecting the legs is probably due to phlebitis after typhoid, and has no connection, I take it, with the present trouble.

She now comes to a physician by reason of an acute upset, apparently infectious in type, and associated with jaundice and pyuria in a urine always acid. The latter fact strongly suggests tuberculosis as the underlying disease.

Note, in the first temperature charts (Fig. 187), how the temperature goes up when the amount of urine excreted is small and falls as the urine increases. This might be due either to retention of urine

during a period of infection in the urinary tract or possibly to a concentration of urine due to the infection itself.

Cystoscopy leaves no doubt that there is pus in the kidney. Since animal inoculation shows no tuberculosis, and no sac of any size is to be felt in the region of the kidney, we may exclude tuberculosis and pyonephrosis and conclude that a pyelonephritis of septic origin is the diagnosis.

Outcome.—May 3d the left kidney was cut down upon, but while being stripped of its fat was ruptured and pus spilled into the wound. Externally the kidney was soft and somewhat enlarged. Nephrectomy was done. Examination by Dr. W. F. Whitney showed the following: Kidney, 13 by 4 by $4\frac{1}{2}$ cm., sacculated. On section, the cortex was thin and the lining of the calices and pelves thickened and reddened. Microscopic examination showed entire destruction of the cortical substance, all of the glomeruli being sclerosed and the tubes being entirely destroyed. The tissue was everywhere infiltrated with round cells, many of them leukocytes. After operation the temperature ranged high for a long time (Fig. 188), with a positive Widal reaction. On the 23d of June some pus pockets were opened up. July 19th the wound was better, the temperature was lower, and the patient was allowed to go home.

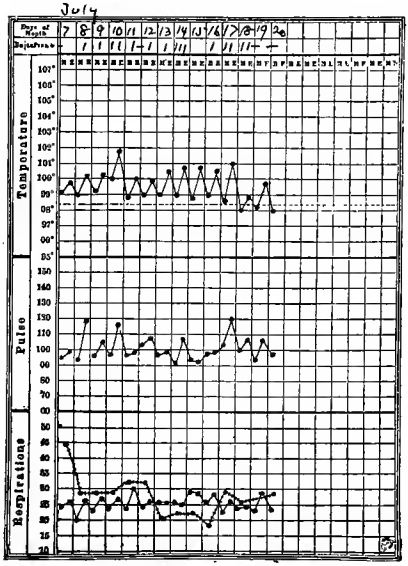

Fig. 188.—Temperature at the end of the patient's second hospital stay (Case 219).

In April, 1913, the patient reported that she weighed 167 pounds, the most that she has ever weighed, and had no trouble any longer with her urine except the frequency, which still continued. She passes urine four times in the night and four times in the day. If she is prevented from emptying the bladder she gets fits of shivering. She says that she is very nervous and has no strength. Nevertheless, she is pursuing her trade as a milliner.

Remarks.—How should we interpret the persistence of a positive Widal reaction? Probably, I think, as a result of typhoid infection remaining in the gall-bladder. There seems no evidence of typhoid

in the urinary tract, or of any generalization of the process such as results in what we call typhoid fever.

There are other cases on record in which typhoid infection has remained in the gall-bladder after typhoid fever for periods much longer than fifteen years.

Case 220

A housewife of thirty-eight entered the hospital April 5, 1910. Her family history was excellent. The patient had "pneumonia and pleurisy" two and a half years ago, otherwise has been well, and has had nine healthy children and three miscarriages. Last fall she felt run down, but picked up until five weeks ago, when she began again to feel weak and tired. Of late there has been occasional incontinence of urine with some frequency. Incontinence and weakness are now her chief symptoms.

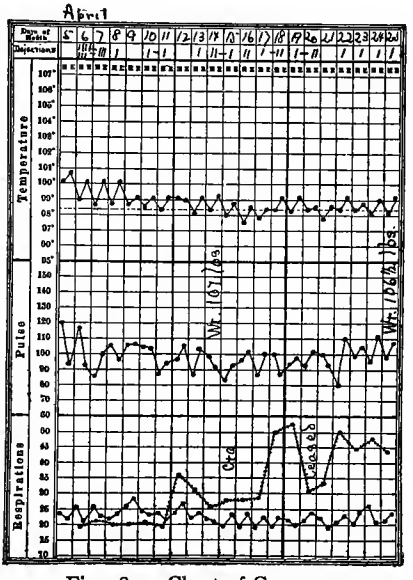

Fig. 189.—Chart of Case 220.

Physical examination showed poor nutrition, moderate fever (Fig. 189). The pupils were unequal in size, slightly irregular, and react slowly. Lymph-nodes, the size of beans, were felt in the right axilla. Chest negative. Reflexes and urine normal. Abdomen as in Fig. 190. The patient remained a month in the wards without any gain in weight, but with considerable gain in strength. The skin tuberculin reaction was slightly positive. Bowels rather costive.

Discussion.—The diagnosis seems to be tuberculous peritonitis. Just what is the relation of this to the urinary frequency I do not know. With a perfectly normal urine we have no good reason to suspect tuberculosis of the bladder or kidney. If tuberculous peritonitis is a correct diagnosis, it may well be that there are glandular masses around the bladder which interfere, possibly, with its action. Possibly her general weakness affects the sphincteric control and contributes to or causes her frequency. The case is an unusual one and not altogether explained.

Outcome.—She went home on the 20th, much relieved. The patient died in September, 1910. Her daughter writes that she got along nicely after leaving the Massachusetts General Hospital until a nurse came to the house and told her that it had been reported that

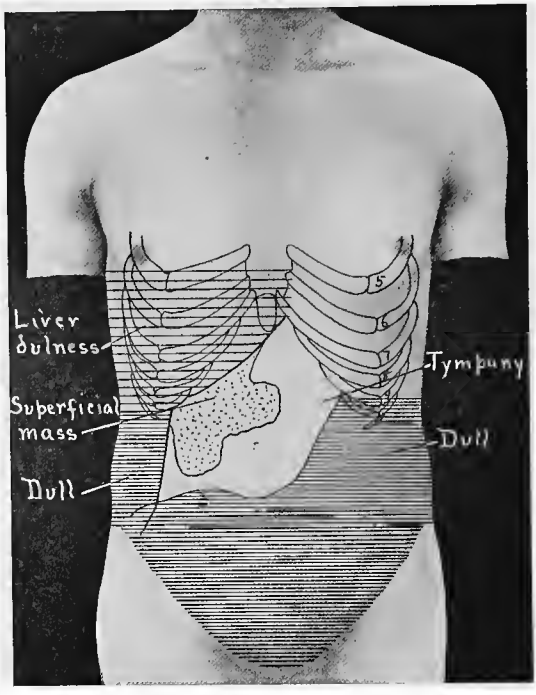

Fig. 190.—Condition of the abdomen in Case 220.

she was a consumptive. "After that she worried and pined herself away." Her physician, Dr. W. P. Cross, of South Boston, writes that she died of pulmonary tuberculosis.

Case 221

An Armenian tailor of twenty-five entered the hospital March 9, 1910. His family history and habits are good. Ten years ago he had some trouble with his left hip, lasting three months. A year ago he began to have slight pain in the region of the right costovertebral angle, troubling him both by day and by night, and radiating down his back and to the groin. This was accompanied by frequency of micturition, at first every five to twenty minutes. The urine was bloody and painful in passage. For three months he has been having similar pain in the left side. During the past fifteen days he has passed a

number of times what he calls "pieces of meat." For three weeks his appetite has been poor, bowels have been irregular, and his sleep poor. A year ago he weighed 135 pounds; now, 141 pounds. He has done no work in the past year and "feels tired."

Physical examinations, including *x*-ray and the blood, were negative, except that the left leg was slightly atrophied and the hip motions limited. The urine averaged 40 ounces in twenty-four hours; specific gravity, 1016; albumin, 0.2 per cent. The sediment contained much pus and blood. There were no tubercle bacilli and no casts. Temperature was as shown in Fig. 191. On the 11th of April a few acid-fast bacilli were found in the sediment of the urine obtained under aseptic precautions. March 14th cystoscopy by Dr. Hugh Cabot showed that the bladder was much contracted and ulcerated. Indigocarmin excretion was very poor, and not enough coming from either kidney in half an hour to make clear the position of the ureter. The condition was believed to be an advanced bilateral tuberculosis, but another cystoscopy, April 18th, showed that the right kidney now excreted indigocarmin promptly and in full amount, while none at all came from the left side in thirty-five minutes. A cubic centimeter of urine from the left kidney was injected into a guinea-pig April 14th. Autopsy, May 23d, showed tuberculosis of the spleen and liver.

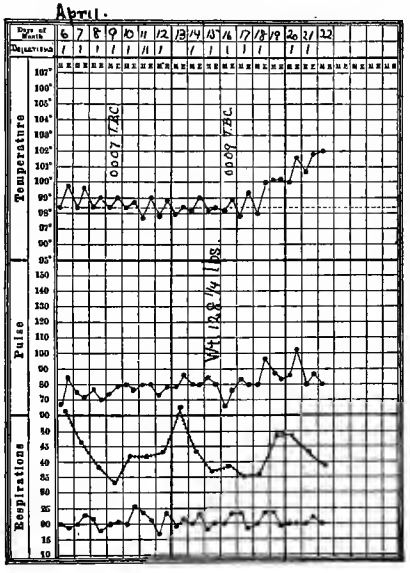

Fig. 191.—Chart of Case 221 up to the day of operation.

The urine was always acid during the patient's hospital stay. He complained of considerable pain in the right flank at times. The bladder held only 3 ounces. He gained 4 pounds during his stay in the medical wards, where the treatment consisted of sandalwood oil, 10 minims, three times a day, and an occasional dose of aspirin or phenacetin, with a maximum of fresh air and food.

Discussion.—A point of interest is that the pain was mostly on the right side, though the disease was mostly on the left. This not infrequently happens in tuberculous disease of the kidney. One

side becomes diseased, the other kidney hypertrophies, and in connection with this hypertrophy there may be pain. This leads to an examination of the kidney region. We feel the hypertrophied kidney and decide that it is diseased. The sick organ on the other side meantime keeps quiet.

Note that the urine contains blood, which is somewhat unusual in renal tuberculosis.

Note further that there is actual tuberculosis of the bladder. In many cases of renal tuberculosis the bladder is normal, despite the very marked urinary frequency and pain. This case is one of the exceptions.

Outcome.—On the 23d the left kidney was cut down upon. The kidney seemed small, but otherwise not abnormal, as was the left ureter. The right kidney was hypertrophied and was considered tuberculous, while the left was merely somewhat atrophied. It was deemed unwise to remove the left kidney on the ground that the other was also diseased. It was thought that the condition of the left kidney was not such as to account for the urine. The patient did well after operation, except for an attack of scarlet fever, but a letter from his son tells us that he died three months after leaving the hospital.

Case 222

A Scotch motorman of forty-three entered the hospital May 18, 1910. The patient's father died of "inflammation of the bowels"; otherwise nothing of importance was contained in the family history. The patient had "rheumatism" in his back and hip seven or eight years ago, and was confined to bed two months at that time. Otherwise his past history and habits are good.

For seven or eight years he has noticed that in certain positions he had twinges of pain and a sense of something moving in the right flank. During the same period he has had to pass urine about every three hours, night and day. He thinks the total amount is not increased. Several times during the last six years he has passed small clots of blood, and in the last month this has happened two or three times a week. During the past winter he often felt lame in the right lower quadrant after a day's work, and on lying down sometimes felt soreness beneath the left ribs. His discomforts are always worse on exertion and always relieved by passing urine.

All winter he has had slight cough and some expectoration, and on his car has noticed shortness of breath and some fatigue. For

the past month these symptoms have been accompanied by dizzy spells and frequent nausea when getting off his car at the end of his run. His appetite during the past month has been poor and he has had some headache. He weighed himself four weeks ago and found he had lost 12 pounds. Since that time he has lost about 12 pounds more. He quit work eleven days ago.

Physical examination showed good nutrition and slight pallor. The heart's apex extended 2 cm. outside the nipple line. The pulmonic second sound was accentuated. There were no murmurs or other abnormalities. There was slightly diminished breathing at the right base behind. Otherwise the lungs are normal. The ab-

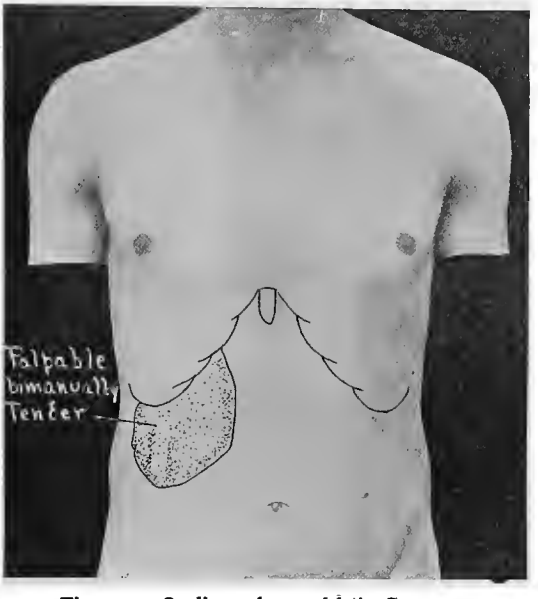

Fig. 192.—Outlines of mass felt in Case 222.

domen showed a mass, the outlines of which are shown in Fig. 192; otherwise nothing abnormal.

During his two weeks' stay in the hospital his temperature occasionally rose to 99.5° or 100° F., but was usually normal. He lost 4 pounds in weight in this period. The urine averaged 40 ounces in twenty-four hours; specific gravity, 1020; albumin, $\frac{1}{10}$ per cent. or less. The sediment consisted chiefly of pus, which made up about one-tenth of the specimen. No tubercle bacilli were present in it. The blood contained from 15,000 to 18,000 leukocytes per cubic millimeter, with a polynuclear leukocytosis. Hemoglobin, 85 per cent.; blood-pressure, 150 mm. Hg.

Cystoscopy by Dr. Hugh Cabot showed that the bladder held 6 ounces. There was marked ulceration of the right lateral wall and about the right ureter, from which a "worm" of thick yellow pus issued. No excretion of color or urine from it. The left side and ureter appeared normal and secreted indigocarmin eight and one-half minutes after injection and in normal amount. After the cystoscopy he had to be catheterized during the ten days preceding his transfer to the surgical ward. The diagnosis was right pyonephrosis, probably tuberculous. Twenty minims, drawn by catheter from the right ureter, were injected May 19th into a guinea-pig. Autopsy, June 29th, showed tuberculous lesions of the glands and spleen. The patient was entirely comfortable in the ward. A skin tuberculin reaction was strongly positive. The urine was always acid.

Discussion.—The duration of the patient's symptoms is of interest. Apparently he has had something the matter with his kidneys for eight years, yet he has got along fairly well and done his work until eleven days ago. In view of the diagnosis, to be mentioned in a moment, this is of much interest. The fact that his pain was always relieved by micturition connects it very certainly with the urinary tract.

It is important to note that he has had cough and loss of weight for six months, with other symptoms, such as vertigo, headache, and nausea, pointing to some infectious disease.

In advance of the cystoscopic examination we can conclude, in the presence of fever, leukocytosis, pyuria, and a mass in the region of the right kidney, that he has pus in or about that organ. The presence of cough and emaciation gives us ground to conjecture that his kidney may be tuberculous.

Cystoscopy increases the probability of this hypothesis, and the results of animal inoculation prove it.

Outcome.—June 3d the kidney was cut down upon and found very adherent, greatly enlarged, and fluctuant. The kidney was removed. No attempt was made to resect the ureter. Pathologic examination by Dr. W. F. Whitney was as follows: Kidney, 13 by 5 cm., sacculated and filled with pultaceous material, consistency very soft and putty-like. Cortex thin. Microscopic examination showed the cortex extremely infiltrated with round cells, and here and there small foci of rounded and epithelioid cells with giant cells and cheesy degeneration. Tuberculosis.

The patient did well after operation, and was discharged June 22d in excellent condition.

In the spring of 1913 the patient reported himself to be in perfect health, stouter than ever, and working steadily since September, 1910. Such perfect results in renal tuberculosis are among the most satisfactory in medicine and, fortunately, they are not very rare.

Case 223

An Armenian butcher of thirty-eight entered the hospital June 3, 1910. In 1903 the patient began to have trouble with frequency of micturition. This continued to trouble him, but was unaccompanied by any other symptoms until one year ago, when he noticed slight swelling of his legs with shortness of breath and fatigue on exertion. During the last four weeks his eyesight has been growing poor, and for two weeks he has had orthopnea and been unable to sleep in bed. Cough and night-sweats have also been troublesome. He thinks he has lost weight. In former years he has had a great deal of generalized headache; for the past three months, none. He has rather frequent nosebleeds. Seven months ago he weighed 145 pounds; now, 128 pounds. He has had no previous illness except "stomach trouble," in 1893, for which he was treated in the Out-patient Department. Diarrhea and pain after eating, with occasional vomiting, were his symptoms at that time. He was sick three months, but has ever since been well and strong until the present illness. His family history is good. His wife has had three healthy children, one child still-born, one miscarriage.

The patient was well nourished, and breathed easily but rapidly as he sat propped up in bed. On his left cheek was the scar of an Aleppo boil (Leishmaniasis). Pupils, glands, and reflexes were normal. The heart's area of dulness extended 5 cm. outside the nipple, in the sixth interspace, and $2\frac{1}{2}$ cm. to the right of the median line. There were no murmurs. Its action was regular, slightly rapid. The pulmonic second was louder than the aortic second. The artery walls were thickened. The brachials show lateral excursion. The systolic blood-pressure was 210 mm. Hg. in the right arm, 180 in the left, and the right radial pulse was markedly greater than the left. The blood-pressure was measured sixteen times during his three weeks and a half in the hospital. It remained at about the same level, and also showed approximately the same discrepancy between the two arms.

At the base of the right axilla and below the angle of the scapula, on the right side, posteriorly, there was dulness, absent breath sounds, and voice sounds. The abdomen was negative, except that the edge

of the liver could be vaguely felt 1 inch below the ribs. He had moderate edema of the legs and sacrum. The blood showed nothing abnormal. The urine averaged 30 ounces in twenty-four hours; specific gravity, 1009 to 1012; albumin, 0.25 to 0.50 per cent.; sediment, hyaline and granular casts, with cells and fat adherent. Wassermann reaction was negative.

During his stay in the hospital the patient was quite comfortable during the day, and his lungs at that time were usually clear, except in the area above noted. But at night he had a terrible time of it, wheezed alarmingly, and had to sit leaning forward in a chair in order to breathe. The attacks were not at all relieved by inhalation of stramonium, cubebs, or potassium nitrite, and even morphin did not give him relief. Hot-air baths seemed more efficient.

By the 9th he was distinctly better, and was able to sleep through the night, except for one slight attack. Theocin, 5 gr. three times a day, had no special effect. Digipuratum was equally ineffective. By the 14th the lungs were entirely clear, and there was no edema of the legs, except after being up all day, but as soon as he began to be up and about the ward he got worse again and the night attacks recurred. He was then put back upon his daily hot-air baths and marked relief followed. By the 24th he was again sleeping all night, and was thereafter able to be up and about all day, free from all evidence of decompensation, except slight edema of the legs.

He left the hospital on the 28th of June, and returned on the 5th of July, 1910, having been much worse since he left the hospital. At this time the systolic blood-pressure was 230 mm. Hg. in the right arm, 200 in the left. His blood showed 20,000 leukocytes, with 81 per cent. polynuclear cells, although fever and all evidences of inflammation were absent. His urine was practically as before. At entrance he was fighting for breath, sweating profusely, and looked very pale, although his hemoglobin was 80 per cent. There was some ascites and occasional vomiting. All these symptoms continued for about forty-eight hours, during which time morphin was the chief aid given. After that hot-air baths were started, and with these and 10 minims of digitalis, three times a day, he showed a wonderful improvement.

In five days his edema was gone and he had changed from a fat to a thin man. The cardiac and pulmonary signs were practically as before described; during the attacks of dyspnea his expiration was always prolonged, intensified, and accompanied with wheezing râles ("renal asthma"). At times his dyspnea was very great, and was

relieved only by standing up and leaning upon the back of a chair. On the 22d of July his right chest was tapped and 1900 c.c. of slightly cloudy, yellow fluid removed. Its specific gravity was 1006; albumin, 0.5 per cent.; sediment, mostly endothelial cells, with a few polynuclears and lymphocytes. After this tapping there was a loud, dry, painful friction rub, audible over the entire right back. Ice-pack and morphin were required for its relief. The blood at this time showed 14,000 white cells, 81 per cent. of polynuclears.

After the pleural pain had subsided the patient was much more comfortable, but early in August he became very drowsy and his dyspnea gradually increased. The fluid re-accumulated in his right chest, and on the 4th of August 1350 c.c., with a specific gravity of 1009, were removed. Things seemed to be going on from bad to worse, and on the 5th of August the patient was given 15 gr. of diuretin at 2, 3, and 4 P. M. His digitalis was increased to 25 minims, three times a day, his liquids limited to 1000 c.c. After that his condition markedly improved for a time. His urine output increased to 60 ounces, his hydrothorax and edema diminished, and he was able to sleep for several nights without sedatives. A week later he began to lose ground steadily. His chest was tapped again on the 23d of August; 1000 c.c. were removed; again, on the 27th, 850 c.c. were withdrawn. The characteristics of the fluid were as before. On the 12th of September he died.

Discussion.—Here the frequency is associated with headache, and lately with dyspnea, edema, and poor sight. This differentiates the case sharply from those previously discussed. With the appearance of orthopnea and cough in the last two weeks, we have every reason to expect the hypertension and urinary abnormalities which physical examination reveal.

The leukocytosis at the time of his second entrance to the hospital may have been of the uremic type or may have been connected with a terminal septicemia. The dyspnea at this time was of the type often known as renal asthma.

The point of special interest in the whole case is that the first of all his symptoms was urinary frequency. In the form of nocturia this symptom is often the earliest manifestation of renal disease, but, unfortunately, it is often overlooked by physicians as they take their patients' histories. In my own routine I never omit to ask about nocturia in connection with the other routine questions regarding appetite, bowels, sleep, and weight.

Outcome.—Autopsy, No. 2676, showed chronic glomerulonephritis;

arteriosclerosis of the aorta and coronary arteries; myomalacia of the left ventricular wall near the apex, with mural thrombi on the corresponding area of endocardium; hypertrophy and dilatation of the heart, acute terminal pericarditis, general passive congestion, dropsical effusion in the serous cavities; obsolete tuberculosis of a tracheal lymphatic gland. The cause of the difference in blood-pressure in the two arms was not explained.

Case 224

A housewife of forty-three entered the hospital November 10, 1910. The patient has had eight healthy children and seven miscarriages. During her last pregnancy, three and one-half years ago, she spent three weeks, at the fourth month, in the Maternity Hospital on West Newton Street, where she was said to have albuminuria and "acute diabetes." Carbohydrates were restricted, she was delivered of a healthy child at term, and remained well until the present illness.

Since early summer she has gradually become more and more tired and irritable. She thinks the amount of urine has been increasing, and is quite sure she passes it more frequently than is normal. Two days ago she vomited, and this symptom has continued night and day since that time. Yesterday she began to have some headache.

Visceral examination is entirely negative. The urine averages 30 ounces in twenty-four hours, specific gravity usually about 1012; it contained a few hyaline casts, but nothing else abnormal in the sediment. After the 17th of November albumin was absent. On the 11th and 12th of November no sugar was present in the urine. On the 13th, 15th, and 17th traces were found, the amount being from 0.4 to 0.6 per cent. Blood-pressure, 135 mm. Hg. The blood at entrance showed hemoglobin, 90 per cent.; leukocytes, 19,000, falling in two days to 12,000. Vomiting was easily controlled by starvation for twenty-four hours, during which time she was given cracked ice by mouth and 6 ounces of normal saline solution by rectum every four hours. November 11th she began to take milk and lime-water, 2 to 1, 2 ounces every two hours, and the amount of food was doubled next day. After the first twenty-four hours there was no vomiting and no other symptoms of importance, and on the 16th she felt fine and was out of bed.

Discussion.—The case is an obscure one. For six months the frequency has been associated with a psychic irritability, which may be its cause or its concomitant. The appearance of headache and vomiting within the last two days, and the slight albuminuria and

glycosuria, may also be either the cause or the result of the psychic disturbances. Frequency, as we know, may be associated not only with diabetes, but with the psychic type of glycosuria. The difficulty of such an explanation in the present case is that the amount of sugar is so small. Possibly when the symptoms began and the frequency was at its height, she may have had more glycosuria than she did under our observation. The point of greatest importance in the whole case is the total disappearance of all symptoms in the end. Possibly, when we know more about the action of the ductless glands a case like this may be explained by some temporary excess or deficiency in that function. For the present it remains rather mysterious.

Outcome.—November 13th she was given egg-nogs, toast, crackers, and on the 14th a normal diet. By November 22d she seemed perfectly well.

Case 225

A housewife of forty-seven entered the hospital December 28, 1910. The patient's mother died of phthisis at thirty-five and her father of kidney trouble at fifty. From girlhood she was always delicate and subject to sore throats and headaches, especially when nervous or excited. Often these headaches are accompanied by vomiting.

Three years ago she had pain in the left side of the abdomen, which was diagnosed as "fibroid of the uterus." Ever since that time she has had a little of the same pain, off and on.

For a year she has had constant dull epigastric pain, sometimes very severe, radiating to both breasts, both shoulders, and the small of the back, sometimes waking her at night, and temporarily relieved by taking a raw egg and brandy or by other food. Otherwise the pain seems to have no relation to meals. The patient's menstruation ceased seven years ago.

For a month her epigastric pain has been much more severe. It is constant with sharp exacerbations, perhaps a dozen times a day, and without known cause. The appetite is very variable, and she is afraid to eat. *She passes urine a dozen to fifteen times a day and once or twice in the night.* During the past month the urine has been very high colored. She thinks she has been losing weight for a year and a half, but worked until five weeks ago.

On physical examination the patient is pale and thin, shows a lymph-node the size of a filbert over the right clavicle, and several large nodes in the left groin. The other lymph-nodes are not abnormal. For the chest, see Fig. 193. The abdomen showed masses as de-

lineated in Fig. 193. The pelvis is filled with a hard, somewhat elastic, apparently cystic mass. The cervix is pushed close behind the pubic bone and the uterus to the right.

Discussion.—Presumably the family history of tuberculosis is not of importance, as there is nothing in the patient's present condition to suggest any form of that disease. The abdominal tumor is not likely to be produced by tuberculous peritonitis. The symptoms of the past year were such as at first to suggest gall-stones, but during the past month the pain has been much too constant to be explained

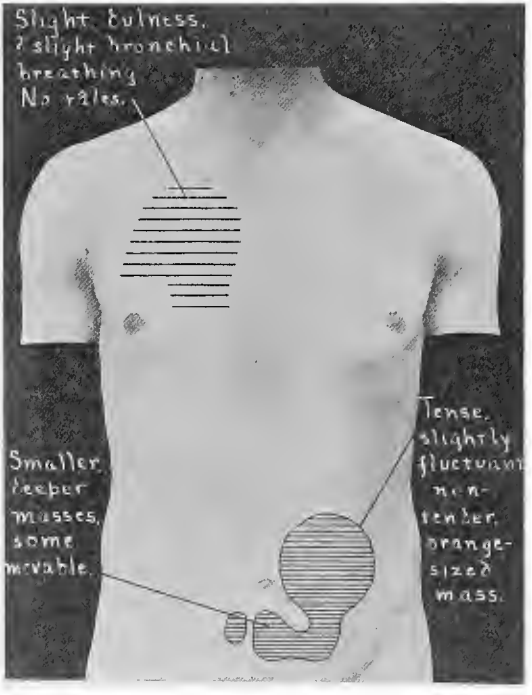

Fig. 193.—Chest and abdomen of Case 225.

in that way. Whether it is connected with the pelvic lesion associated with the frequency it is difficult to say.

What is the nature of the pelvic mass? The patient's emaciation and the nodule above the clavicle are ominous signs, unless we can explain the latter as a relic of the old tuberculous trouble—a rather far-fetched hypothesis. Our attempts to make the case out tuberculous are not successful, and if this is excluded we have every reason to fear malignant disease, perhaps originating in an ovary. The lung signs are much less significant than they would be if they had

occurred upon the other side. I am not at all sure that they are not physiologic.

Outcome.—Operation was advised, but refused. She went home January 5, 1911, and died within that month.

Case 226

A cook of fifty-eight entered the hospital March 2, 1911. The patient's family history is not important. Three years ago he vomited a large amount of blood, having four attacks of this trouble within two weeks and remaining in the hospital for that period. Two years ago he began to notice increasing frequency of micturition, and thinks this was due rather to an inability to hold his water than to an increase in amount passed. This troubled him intermittently, but has gradually grown worse, until now it prevents his working. He has never had pain or retention or seen any blood in the urine. He now passes water eight to ten times a day and six to eight times at night.

For six months he has noticed slight dyspnea on exertion, and has needed three pillows under his head at night. He has a voracious appetite. No headache, no loss of weight, no edema.

Physical examination showed good nutrition and no anemia. Heart's apex extends 1 cm. outside the nipple line and the retrosternal dulness seemed to be increased at the level of the second rib. At the apex and in the aortic area a systolic murmur was heard. Aortic second was sharp and ringing. Systolic blood-pressure at entrance, 300, and ranged above 250 during the first week of his stay. In the next two weeks it was usually in the vicinity of 230, with occasional spurts up to 280. After that it ranged between 220 and 250, until he left the hospital, April 15th. The lungs and abdomen showed nothing abnormal. The pupils were irregular, but reacted normally. Reflexes negative. The prostate was slightly enlarged by rectum, but cystoscopy showed no intravesical prostatic enlargement. The bladder was trabeculated, but not inflamed, and emptied itself rapidly and freely. Dr. Hugh Cabot believed the condition to be dependent upon the heart. Later, the pupils seemed to react somewhat sluggishly and the question of tabes and a tabetic bladder was seriously considered. The urine ranged from 50 to 80 ounces in twenty-four hours. Specific gravity, 1010 to 1012, usually near the lower figure. Many hyaline and granular casts with round cells and leukocytes adherent were found. The Wassermann reaction was negative.

Additional history obtained from the patient's wife showed that

the patient had been bothered for five years by attacks of weakness in his legs, occasionally accompanied by pain throughout his thighs and calves. After such attacks his legs remained sore. During the same period he has become much more irritable, and has sometimes awakened in the night somewhat dazed, not knowing where he is. His wife states, however, that he has had enough trouble in this period to change his disposition.

Discussion.—There seems no good sense in connecting the patient's hemoptysis of three years ago with his present symptoms. What was the cause of that hemoptysis we have no means of judging.

His frequency, which antedated all his other symptoms except the hemoptysis, begins to get its explanation as soon as we know that he has dyspnea and orthopnea, and becomes clearly recognized as a manifestation of chronic nephritis as soon as the blood-pressure measurements are known. The only remaining question is whether the slight prostatic enlargement felt by rectum has anything to do with his frequency. In view of the results of cystoscopy, I doubt it.

Tabes was seriously considered after the condition of the bladder and pupils had led us to question his wife more closely. The mental condition which she reports and the pains in the legs are significant, even though the knee-jerks are normal. The negative Wassermann reaction should not lead us to exclude tabes.

If he has had syphilis affecting his spinal cord, it is quite possible that his renal lesion has a similar origin.

Outcome.—During the earlier part of his stay in the hospital he occasionally had incontinence, but this was controlled by tincture of hyoscyamus, 10 minims, three times a day. Each time this drug was omitted the incontinence returned, disappearing again when the drug was resumed. April 10th the patient had a sudden attack of vomiting, without known cause. The attack did not recur. The renal functions were tested by an injection of phthalein; 8 per cent. were excreted the first hour, 9 per cent. in the second. He left the hospital April 15th, and died September 1, 1912.

Case 227

An engineer of forty entered the hospital May 25, 1911. There is nothing worthy of note about the patient's family history or about his past history until three weeks ago, when he had a shaking chill, accompanied by frequent and painful micturition, with a little blood at the end. These symptoms have continued since, micturition coming every half-hour and being very painful. The urine is cloudy, fairly

abundant. Nevertheless, the patient has worked until to-day, because he could not find a substitute as engineer at the Children's Hospital. He is always thirsty, because, he believes, of his work in the boiler-room. Has no abnormal appetite. During the past six months he thinks he has lost 10 pounds in weight and some strength.

Physical examination shows a well-nourished, powerful man, without visceral lesions. The reflexes and pupils are negative. Rectal examination shows a soft, enlarged, symmetric prostate. Good *x*-ray plates of both kidneys and bladder show nothing abnormal. Cystoscopy by Dr. Hugh Cabot shows a normal bladder capacity. The trigonum, the internal urethral orifice, and the fundus of the bladder show evidence of chronic cystitis, suggesting tuberculosis. The ureteral orifices apparently normal. Urine from the right side seems to be slightly turbid, that from the left normal. Cultures from the right ureter show moderate growth of colon-like bacilli; that from the left shows the same thing. Specimens injected into a guinea-pig yield no information of value. The sediment of the urine from the right ureter and from the left show essentially the same thing. Both contain hyaline and granular casts and leukocytes. A functional test of the kidneys with phthalein shows normal capacity.

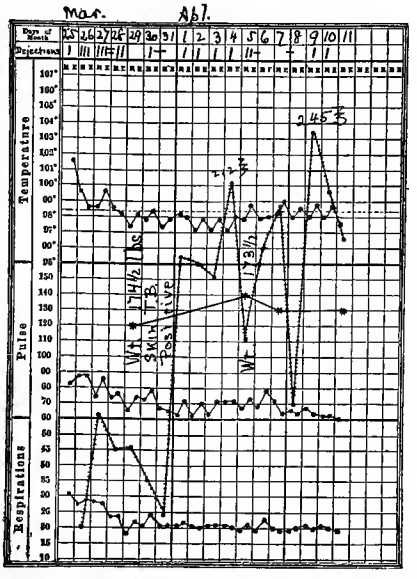

Fig. 194.—Chart of Case 227. The urinary output (cross-marked line) is recorded in ounces.

The dysuria following cystoscopy is relieved by 5 minims of sandalwood oil, three times a day. The amount of urine passed, under advice to "drink plenty of water," is shown in Fig. 194. Strangely enough, the specific gravity of the urine varies little from 1010; the sediment always shows considerable pus. The blood is normal. Blood-pressure, 130 mm. Hg.

Discussion.—Without cystoscopy we should be utterly at sea in a case of this kind. We should know that he had some sort of an infection, probably involving his urinary tract. Beyond that we

should be in the dark. With the cultivation of colon bacilli from the urine of each kidney we may conclude that operative interference is out of the question. Whatever infection he has in the kidney or bladder he must conquer by his own vital forces with whatever non-surgical help we can give him.

The negative results of animal inoculation are reassuring as to prognosis. If there were an extensive pyonephrosis or pyelonephritis, we should probably be able to feel one or the other kidney, and the patient would probably have been unable to work as he did up to the time of entering the hospital.

Outcome.—The patient left the hospital on April 11, 1911, in fair condition. November 25, 1912, the patient reported himself in excellent condition and at work. He is still taking the capsules of sandalwood oil. He drinks a great deal of water and sweats profusely. The urine at this time was 68 ounces in amount, showing no turbidity, no albumin, sugar, or pus. The specific gravity was 1008.

Case 228

A schoolboy of fourteen entered the hospital February 14, 1912. His family history is negative. Two and a half years ago the patient noticed a swelling in his left neck; it lasted three weeks, and went down without treatment. He believed it to be due to a bad tooth. Otherwise he has been well and strong, though he has worn glasses for seven years.

December 1, 1911, two and a half months ago, he developed "erysipelas" of the right foot, the part being painful, hot, and red. This lasted seven weeks before the foot was finally healed, the doctor having tried various liniments and plasters as well as internal medicine in the meantime. There was fever with this attack, but no chills.

After the foot was better, three weeks ago, he began to pass small amounts of urine every ten minutes. This frequency has gradually decreased, until now he passes urine about ten times in the day and four or five at night. He often has the desire, yet cannot pass urine without considerable forcing. At the onset of this frequency there was pain and burning as well, symptoms which now occur only at the end of micturition, when blood is also occasionally seen.

Physical examination shows large red ragged tonsils. Chest and abdomen negative. Systolic blood-pressure, 120. The right tarsus is slightly hot, red, and tender, and a little larger than the other side. The motions of the ankle and toes are free and painless. Reflexes are normal. Blood normal. The urine averages 25 ounces in twenty-

four hours, with a specific gravity of 1020 and a trace of albumin, probably accounted for by a considerable amount of pus and blood in the sediment. No casts. *X*-rays of the renal regions were negative for tuberculosis or stone anywhere in the urinary tract. The bones of the right foot showed slight atrophy and a moderate periostitis of the os calcis. Cystoscopy by Dr. Hugh Cabot showed what he considered bladder tuberculosis; 20 minims of urinary sediment were injected into a guinea-pig February 15th. The pig was found dead March 21, 1912, but the autopsy was negative. A culture from the urine at the same date, February 15th, showed no growth.

The *x*-rays of the foot were not considered characteristic of tuberculosis, yet this disease could not be excluded. Hygenic treatment was thought to be the most important measure, hence the boy was discharged on the 24th of February.

Discussion.—The results of inoculation in this case are not conclusive. The pig may have died of some intercurrent infection before the tuberculosis had time to develop. Only by a knowledge of the later course of this patient's symptoms can we be sure what the nature of the bladder trouble was. A "primary cystitis" is always a doubtful and unsatisfactory diagnosis, yet nothing much better than that is possible in this case. The disease in the foot and in the neck may have been tuberculous, but we have no proof of it. This is the sort of case in which only time can make good the deficiencies in our diagnosis.

Outcome.—A year later he reported that since March, 1912, he had been perfectly well, save for an attack of "malaria" in the summer.

Case 229

A housewife of forty entered the hospital April 15, 1912. Her family history and past history were not remarkable. For three months she has had frequent and burning micturition, and noticed a white sediment in her highly colored urine. She has grown pale and short of breath, but until ten days ago had no pain; then she began to suffer in both sides of her chest, high up, and in her shoulders, especially the right. The pain is not constant, but leaves a steady soreness and is worse when she breathes. It is sufficient to confine her to bed. There are no suggestive symptoms except poor appetite. Four months ago she weighed 115 pounds, with clothes; now, 96 pounds, without clothes.

Physical examination showed obvious loss of weight. Veins of the neck prominent. Skin pale yellow, but without jaundice in the scleræ. No substernal dulness. Physical examination was negative,

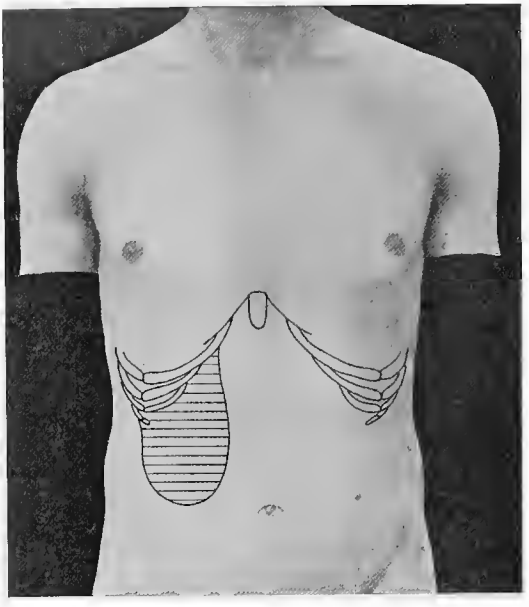

Fig. 195.—Abdominal mass found in Case 229.

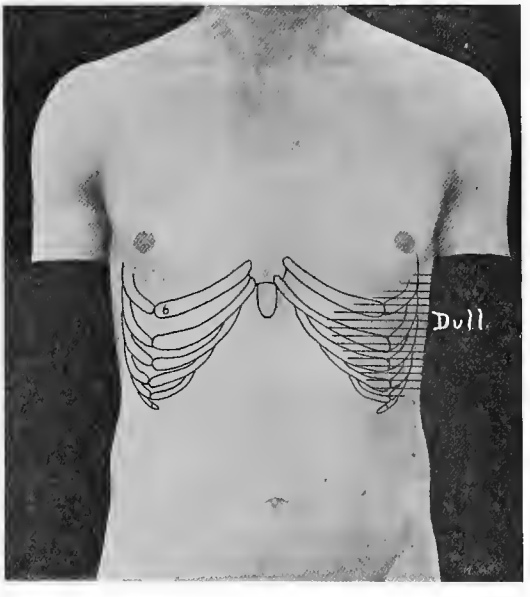

Fig. 196.—Chest signs in Case 229.

except as shown in Figs. 195, 196. The urine averaged 40 ounces in twenty-four hours, with a specific gravity from 1004 to 1006.

Pus was always present in large amounts, and there were also a good many red blood cells. Cystoscopy by Dr. Hugh Cabot, April 17th, showed a normal bladder and ureteral orifices. Both ureters were catheterized and both contained cloudy, foul urine. Bilateral infection of the kidney, probably not tuberculous and not demanding operation, was the diagnosis. On the 19th of April the same consultant found the urine from both kidneys looking better and washed the renal pelvis on each side. Cultures from each kidney showed nothing distinctive, and a blood-culture was also negative. The course of the anemia is shown in Fig. 197. The stained smear showed always a marked secondary anemia with a moderate leukocytosis.

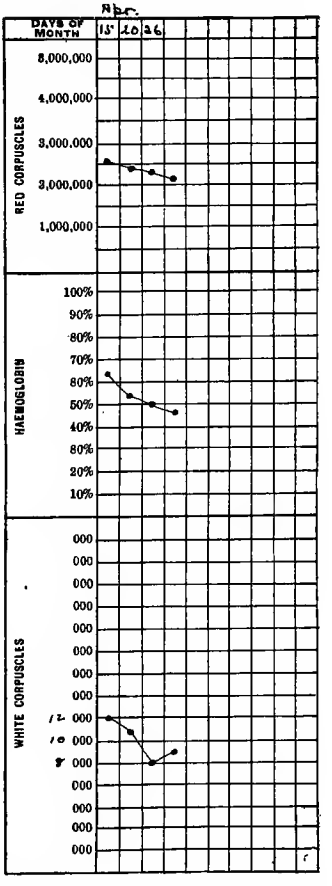

Fig. 197.—Blood chart in Case 229.

On the 25th the patient was examined in a hot bath and showed a large nontender tumor, palpable bimanually, in the position shown in Fig. 195. May 3d the patient was up and felt much better. The precordial pain, which was the most distressing symptom at entrance, had entirely disappeared. The urine was reported improved, but the anemia was worse, and she was discharged on the 3d of May.

Discussion.—From the history of whitish urine, with pallor and the loss of 20 pounds' weight during the first three months of pregnancy, a septic or tuberculous process in the kidney comes at once to mind as the most probable explanation of the patient's frequency. The condition of the blood is puzzling, and, taken by itself, would strongly suggest pernicious anemia, though the slight increase of leukocytes would be atypical under such a diagnosis. I looked at the blood myself on the 16th of April and called it a secondary anemia, on account of the notable leukocytosis, although I could find no achromia. There were moderate variations in the size and shape of the red cells, no stippling, no blasts. Such an anemia is more often seen

in septicemia than in tuberculosis. As a result of cystoscopy there was a demonstration of infection in both kidneys. Operation was, of course, impossible. It is to be regretted that no animal inoculation was made.

At the time she left the hospital we expected a steady progress of the disease to a fatal termination.

Outcome.—November 23, 1912, her husband reported that she "got along fine after leaving the hospital" until the last week in August, when diarrhea and vomiting began (after a vacation trip) and lasted until her death, September 6, 1912.

Case 230

A teamster of forty-one entered the hospital April 22, 1912. The patient is moderately alcoholic, but otherwise shows nothing of importance in past history or family history. Eight weeks ago micturition became frequent and caused burning pain, especially in the latter portion. Seven weeks ago he noticed that the urine at the end of micturition was bloody. At the same time the left ankle, hip, and knee became so sore and painful on motion that he stayed in bed for a week. Six weeks ago he had severe colicky pain in the right lumbar region and flank, radiating down the ureter. This pain lasted half an hour and has not recurred. There was no change in the urine at the time. Since then he has been fairly well save for the local urinary symptoms, but he has noticed that his urine is cloudy and has a white sediment.

Two days ago his right knee suddenly swelled and became red, hot, and tender, so that he walks on crutches. Despite these troubles his appetite has remained fair and he has kept his usual weight, 145 pounds.

Physical examination shows in the precordia a soft systolic murmur, present only during inspiration. The aortic second sound is more intense than the pulmonic second; otherwise visceral examination is negative. The right knee is swollen, hot, red, and tender. The patella floats and there is considerable thickening about the joint. On the dorsum of the right foot there is a tender spot. A smear of pus obtained from the prostate shows a few polynuclear leukocytes and a rare diplococcus, negative to Gram. By rectum the prostate is tender, uneven in consistency, and contained an excessive, slightly purulent secretion, believed to be due to gonorrheal prostatitis. The treatment advised is irrigation and massage of the prostate. The gonococcus fixation test is moderately positive; the Was-

sermann, negative; *x*-ray, No. 20,646, shows evidence only of an infectious arthritis in the right knee.

Gonococcus vaccines, 50,000,000 every four days, were given by Dr. Steele. During four weeks in the ward the patient ran a slight irregular fever, now and again, never exceeding 100° F. The urine averaged 60 ounces in twenty-four hours, with a specific gravity of 1010, and during the first few days a slight trace of albumin. The sediment always contained pus, though the amount became much less during the later weeks of treatment.

Discussion.—When the joints are effected simultaneously with bladder symptoms of this type a general infection is naturally our first thought. The fact that he has had a pain along the ureter leads us to imagine that the trouble may have extended up to the pelvis of the kidney, wherein a blocking with pus might cause pain. The condition of the right knee on physical examination is that most often seen in gonorrheal arthritis, and the blood-test goes to confirm this, likewise the rectal examination. Presumably he had a gonorrheal prostatitis and pyelitis as well.

Outcome.—By May 1st the right knee was almost normal, but the left knee was very large and showed practically the condition present in the right at entrance. This condition in the knees progressed and improved, from day to day, in an irregular way until the 15th, when both knees seemed to have cleared up and the patient was allowed to go home.

Case 231

A housewife of sixty-six entered the hospital July 18, 1912. Her family history was negative and past history not remarkable.

About a year ago she began to have frequent and burning micturition. The urine looked a little darker than usual, but was never bloody. The quantity was not increased and there was no incontinence, but at times the urine was passed every half hour, night and day. With slight periods of improvement this has persisted ever since, though she has kept about and worked until six weeks ago. At that time she began to have severe pain in the small of her back and in one or the other hip. The pain was increased by motion, and was similar to the attacks of "lumbago," which she has often had before. This pain, however, disappeared a month ago and has not recurred.

For six weeks she has been in bed most of the time and has lost her appetite. She is constipated and is much troubled with gas

in the bowels. For six months she has noticed shortness of breath on exertion, and for three months swelling of the feet and ankles, disappearing when she goes to bed. There has been no fever, cough, or jaundice. Her main complaints are of the urinary frequency and great weakness.

Physical examination shows the patient moderately emaciated. The heart is negative except for a soft systolic murmur at the base, and there is an accentuation of the pulmonic second sound. There is soft edema of the lower back from the twelfth rib to the sacrum and over the anterior abdominal wall. Some also in the thighs. Vaginal examination shows that the base of the bladder is thickened and firm, forming a rounded mass several centimeters thick, which bulges slightly in the anterior vaginal wall. The urine averages 35 ounces in twenty-four hours, with a specific gravity in the neighborhood of 1018. It contains much fresh blood and many masses of multinuclear epithelial cells; no casts and few leukocytes. Culture from the urine showed no growth. Blood showed red cells, 4,700,000; white cells, 10,500; hemoglobin, 60 per cent. Stained smear gave evidence of achromia.

Discussion.—At this patient's age such bladder symptoms are probably due to stone or malignant disease. Emaciation favors the latter alternative, and if her dyspnea and edema are not due to some separate cause they would round out the diagnosis of malignant disease, which the vaginal examination renders practically certain. Tuberculosis originating at her age is practically unknown.

Outcome.—Cystoscopy, July 19th, by Dr. Hugh Cabot, showed a new growth in the bladder, believed to be cancer on account of the suggestion of glandular involvement given by the edema. No operation was advised. Accordingly, the patient left the hospital July 20th and died three days later.

Case 232

An Irish laborer of seventy-nine entered the hospital July 18, 1911. The patient says he has had pain in the epigastrium for twenty years and that it has steadily been growing worse. He has no other gastric symptoms and has otherwise been well. He drinks whisky two or three times a day.

For a year he has noticed that his urination was frequent and caused burning. There has been no retention and no incontinence, but for the past two weeks he has passed urine about every hour

in the daytime and five or six times at night. The urine is foul and cloudy; sometimes only a teaspoonful at a time is passed.

Physical examination showed tortuous, hard, beaded arteries. The heart's apex was in the sixth space, 1 cm. outside the midclavicular line. Aortic second was accentuated. A soft systolic murmur was localized in the apex region. The chest was barrel shaped, hyperresonant throughout. The expiration was prolonged, accompanied by squeaks and crackles. The bladder was distended, reaching to within 2 inches of the umbilicus. There was right inguinal hernia. By rectum the prostate was moderately enlarged, not tender, fairly firm in consistency; 22 ounces of urine were drawn by catheter, alkaline in reaction, 1012 in gravity, containing much pus and blood. The twenty-four-hour amount thereafter averaged 50 ounces. The temperature as in Fig. 198. The patient was put on constant drainage and kept so for fourteen days. By the phenolsulphonephthalein test 6 per cent. was excreted in the first hour, the color first appearing in thirty-five minutes the first time, later in fifty-five minutes. On the 14th of August he developed acute epididymitis on the left; by the 17th that had begun to subside.

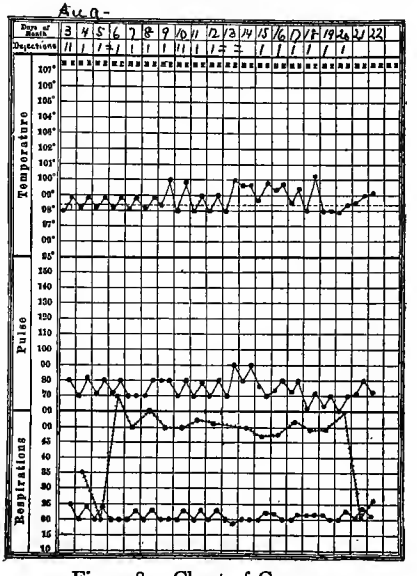

Fig. 198.—Chart of Case 232.

Discussion.—The patient clearly has arteriosclerosis and an enlarged heart with emphysema, but at present his trouble is a distended bladder, presumably due to prostatic enlargement. The only question of interest is whether or not he has cancer of the prostate. Of the latter condition, the rectal examination gives no evidence and there is nowhere else to look for any. We are dealing in this case purely with symptoms of obstruction, not with pain or hematuria, such as are associated with tuberculosis, cancer, or primary cystitis. The development of acute epididymitis is one of the unavoidable complications of constant drainage, in a certain percentage of prostatic cases, and does not complicate in any way the diagnosis, while it may darken the outlook.

Outcome.—By the 22d of August he was much better in his general condition, and was allowed to go home.

Case 233

A housewife of fifty-two entered the hospital May 12, 1908. For the past three or four months the patient has been troubled with thirst, polyuria, and increasing nocturia, now eight to ten times; also dyspnea, which in the past two weeks has amounted to orthopnea. She has had occasional attacks of vomiting, has lost considerable in weight, and her eyesight has rapidly been growing poor. Her headache has also been a troublesome symptom of late. Previously to this she has always been well, has had fifteen children, and three miscarriages.

Physical examination showed obesity, pale, dry skin; pupils, glands, and reflexes negative. The heart's apex was 1 inch outside the midclavicular line. Right border dulness $\frac{3}{4}$ inch to right of midsternum. The heart's action was irregular, with frequent premature contractions. The aortic second sound was markedly accentuated, no murmurs. The artery walls were thickened. Blood-pressure, 240 mm. Hg., systolic. Slight dulness and crackling râles at both bases behind. Abdomen negative. Considerable edema of the legs and back. Blood negative. Urine, 32 ounces in twenty-four hours; specific gravity, 1010; sediment negative. She did not improve during her week in the hospital, and was taken home by her friends on the 19th of May. She returned on the 20th of June. She has had attacks of vomiting four or five times a day since she left. She has been in bed; had no appetite and some dyspnea, but no orthopnea. The heart's apex was at this time in the anterior axillary line, right border of dulness $1\frac{1}{2}$ inches to right of midsternum. Blood-pressure, 235 mm. Hg. In the left lung there was dulness, absent breathing, and faint nasal voice sounds, with crackling râles below the lower angle of the left scapula. Abdomen negative. Slight edema of the legs. At this time she seemed a good deal better than when she left the hospital before, and improved still further during her ten days' stay, though she still vomited each morning. The condition of the urine was as before, although an occasional hyaline and granular cast was found. She went home on the 30th of June.

Discussion.—When a patient consults a physician primarily for thirst and polyuria, the diagnosis is usually saccharine diabetes. The unusual thing about this case is that the urine contained no sugar.

As soon as we go beyond the presenting symptom, we find dysp-

nea, headache, vomiting, poor eyesight, and, above all, an enormous degree of hypertension; in other words, the complete clinical picture of chronic nephritis, which in this patient has run probably its entire course up to this, its terminal stage of contracted kidney, without any symptoms at all. So it is with most cases of chronic nephritis. They are entirely symptomless until their later stages. This is especially true of the arteriosclerotic varieties and of all mixed cases in which the arteriosclerotic element predominates over the glomerular element. There is no reasonable doubt of the diagnosis and no need of discussion.

It is worth mentioning, however, that now and then a patient comes to us complaining of dry mouth and of nothing else, but presenting on careful study a picture similar to that of this case, though less in degree and intensity. A good many such "dry mouth" cases are associated with prostatic obstruction and are regarded by the genito-urinary surgeon as poor risks. The dry mouth is often, but not always, an ominous symptom. Curiously enough, it is now and then wholly relieved by chewing dry crackers.

Case 234

A schoolboy of seventeen entered the hospital August 18, 1909. Family history is negative. During the first months of his life he had convulsions, but since then has had nothing of the kind, though he has occasionally been troubled by "rushes of blood to the head and by choking sensations."

In June, 1909, eight weeks ago, he first noticed that he was passing a great deal of urine, getting up three or four times in the night to urinate, and drinking a great deal of water. Appetite very good until two weeks ago, since then poor. He has been constipated of late and has vomited once or twice. He has no headache and sleeps very well, but his mouth is always dry, and he thinks he has lost a little weight.

Physical examination shows good nutrition, a dry, harsh skin. Otherwise negative. The range in the amount of urine is shown in Fig. 199. Fundus oculi was normal. The patient was put on Folin's diet and the amount of urinary excretion, as compared with the salt ingestion, was studied. Later he was put on a diet of protein without salt, and the amount of urine, together with the thirst, rapidly decreased. As soon as salt was added to the diet the urine returned to nearly its former amount. September 13th a positive Wassermann reaction was obtained. September 16th he was given a salt-free diet

containing nitrogen and again the amount of urine diminished, though still remaining considerably above the normal. In view of the positive Wassermann reaction, the patient was given mercurial inunctions and iodid of potash in increasing doses. He decided to go home on the 30th, having lost no weight since the first week of entrance and having achieved no gain.

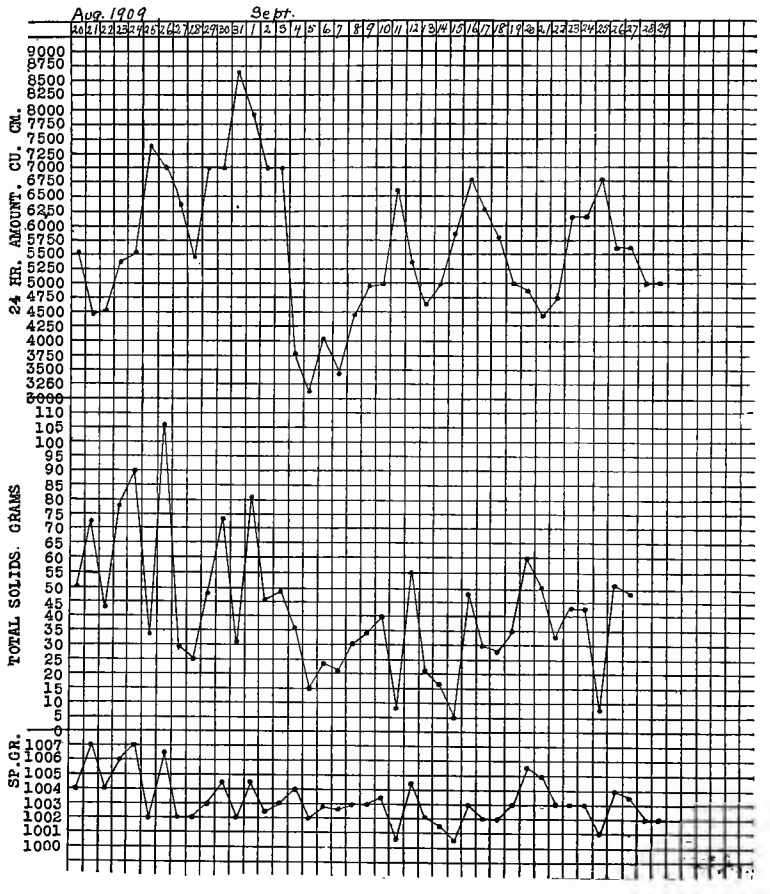

Fig. 199.—Urine chart in Case 234.

Discussion.—The enormous degree of frequency and polyuria which this boy exhibited, when associated with a poor appetite and known to be continuous, leaves only one probable diagnosis in the foreground, diabetes insipidus. The presence of a positive Wassermann reaction is no reason for changing this diagnosis, since we still use the term "diabetes insipidus" to cover cases with some organic brain

lesion as well as those with unknown pathology. In differential diagnosis the main thing is to exclude nephritis, which in this case was easy, and to determine that the frequency and polyuria are not of temporary nervous origin. The lapse of time and the careful study of the case exclude these possibilities beyond doubt.

We tried various experiments with this patient's diet and showed that a salt-free diet would for a time reduce his polyuria, but, as such a diet could not be kept up for any length of time without great danger, its temporary effects were of no benefit to the patient.

It is of some importance to note that antisyphilitic treatment produced no benefit. This is what we have learned that we must expect in many cases of diabetes insipidus, even when the Wassermann reaction leads us to hope that we may secure good therapeutic results.

Outcome.—The patient died February 27, 1910. During most of the latter months of his life he could eat scarcely anything. He drank an enormous amount of milk and water, but vomited most of it within half an hour. After Thanksgiving he was confined continuously to bed, and for three months before his death he took absolutely no solid food and lived wholly on orangeade and moxie. He suffered no pain, but during these bed-ridden months there were troublesome cramps in his arms and legs, and finally contractures developed in all four extremities. There was no fever or cough, no headache, no trouble with the movements of his bowels. Toward the end of life he was not drowsy, but emaciated to skin and bone, the enormous polyuria continuing up to the very end, although he was too weak to pass urine spontaneously and had to be catheterized. There was much itching of the skin.

Case 235

A schoolboy of fourteen entered the hospital February 14, 1910. He has always been well. Good family history. Eighteen days ago he ate a hearty dinner, with a good deal of ice-cream, and drank much water. During the next twenty-four hours he passed more urine than usual, and after that seemed to be all right, but a week later he had another attack of polyuria, and since then has passed over 2 quarts, sometimes 3 quarts, daily. Four days ago sugar was discovered in the urine. His appetite has been very good all winter, but not until the last two weeks did he notice any thirst or dryness in the mouth, and not until that time did he lose any weight.

On physical examination he is well developed, dry skin, viscera and reflexes normal. Urine, 40 gm. of sugar a day, quickly yielding

to strict diet. The boy stayed twenty days in the hospital, and during the last five days had no sugar in the urine. Acidosis was very slight, and the boy held his weight at 118 pounds without considerable change.

Discussion.—The sudden onset of symptoms is of some interest. The diagnosis could never have been in doubt, provided the urine were examined. It is notable that he never suffered from thirst or dry mouth and that for a considerable period he maintained his weight, although no changes were made in his diet. The prognosis for such a case is poor, even when response to treatment is excellent, as during his hospital stay. Very few such cases live more than a year or two.

Outcome.—He went home on the 2d of March, 1910, and died in coma, March 14, 1911.

Case 236

A carpenter of thirty-eight entered the hospital March 31, 1910. The patient's family history and past history are excellent. He used to drink heavily until two years ago.

About Christmas-time he began to notice that he passed large amounts of urine. He was much worried by the statement of his doctor that he had tuberculosis. Since last Christmas he has done no work, and for the past six weeks can scarcely go up stairs because of weakness and shortness of breath. His appetite is good and he has no cough, but there is some palpitation and some swelling of the legs. His legs seem much weaker than any other portion of his body. He has no pain anywhere.

Physical examination showed fair nutrition and marked pallor. About the knees and elbows were many small flattened red papules, covered with scales. His teeth were poor and many missing. Chest and abdomen were negative. Reflexes and pupils normal. Blood showed red cells 2,144,000; white, 9500; hemoglobin, 50 per cent. In the stained specimen were marked achromia, slight variations in size and shape of the red cells. Differential count normal. The yellowish tint of the skin was such as to suggest pernicious anemia, but the blood-picture was that of secondary anemia (Fig. 200). There was a positive guaiac reaction in the stools at entrance, but this was found to be due to piles, for which operation was advised by Dr. Mixter.

The urine contained sugar in amount varying between 40 and 60 gm. a day on a strict diabetic diet with 200 gm. of bread, and on all the subsequent reductions in the amount of bread no change

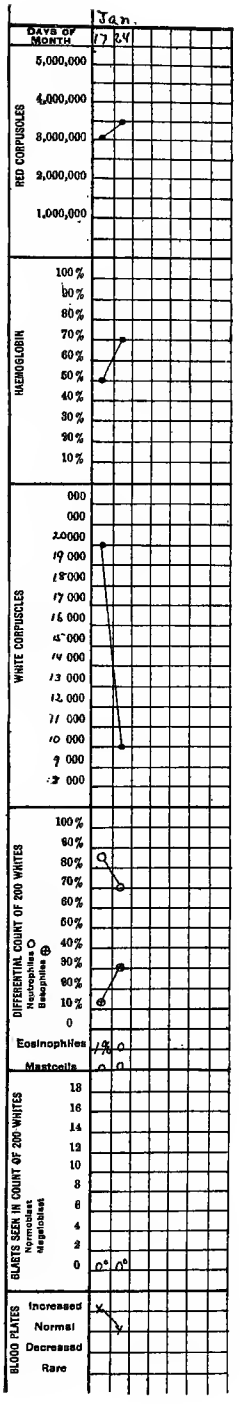

Fig. 200.—Blood chart in Case 236.

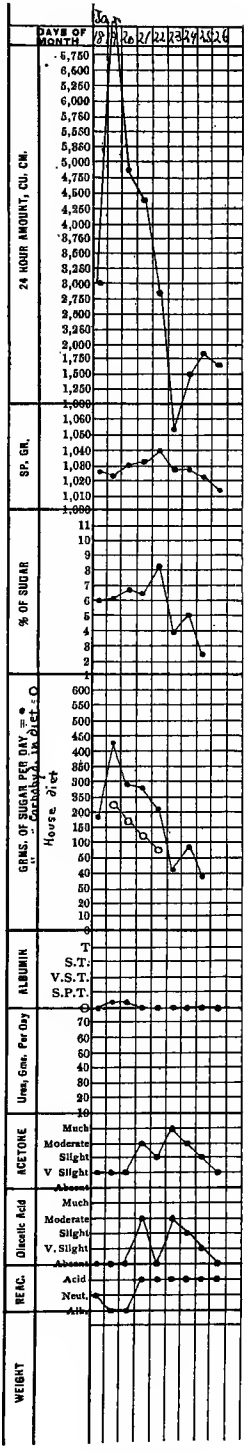

Fig. 201.—Urine chart of Case 236.

occurred, though during the last week of his stay in the hospital the diet contained no carbohydrates. He went home on the 11th.

The patient entered the second time on the 17th of January, 1911, stating that since his discharge he had been much the same, gaining weight when he loafed and losing it when he worked. He has not stuck to his diet (Fig. 201).

Three weeks ago he got what was called "pneumonia," beginning with a heavy cold, followed by chills and fever, with pain in the left lower chest and cough, with scanty whitish sputum. A little cough persists. At this time physical examination showed slight dulness and

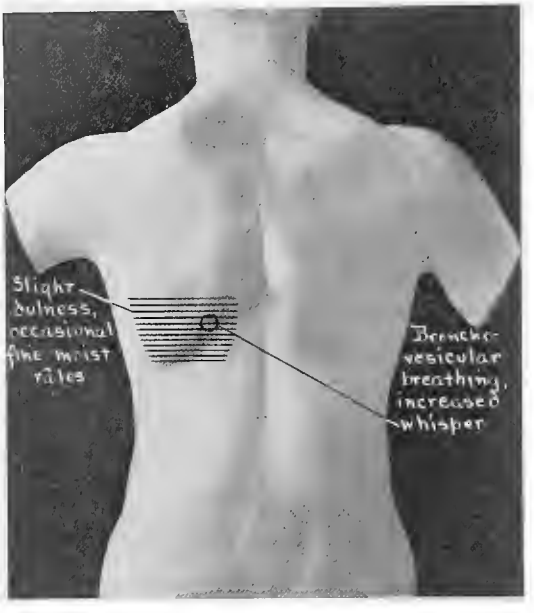

Fig. 202.—Chest signs in Case 236.

occasional moist râles at the left base (Fig. 202). Just inside the angle of the left scapula was a patch of bronchovesicular breathing and increased whisper. Otherwise physical examination was unchanged, except for his red cells, which had risen to 3,200,000; white cells, 19,000. Hemoglobin remained at 50 per cent. The stained smear still showed marked achromia with a polynuclear leukocytosis. The amount of sugar was considerably greater than on previous examination. Under strict diet it was gradually brought down to about 40 gm. a day. At this time, as on the previous occasion, he had considerable diarrhea.

After leaving the hospital the last time he adopted a diet of his own, containing as much milk and cereals as he liked and two slices of bread. On this diet he worked at carpentering two or three days a week and felt well and fairly strong until a week ago, though he has had several spells, lasting a week or two, when he would be "all done up" and feel very weak and drowsy.

A week ago he caught cold, felt tired and miserable. Four days ago he was feverish and chilly at night and felt sore all over. The next morning he began to cough and felt pain in the left lower chest. These symptoms have continued since, though his appetite has been good. His weight has gradually fallen since spring from 145 pounds at that time to 133 pounds now.

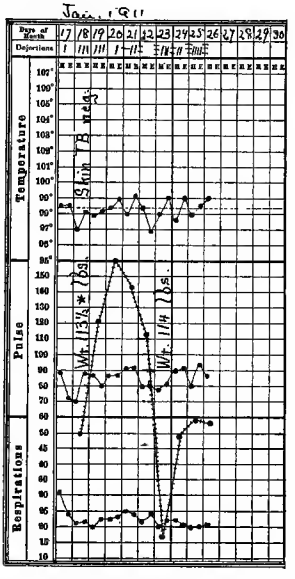

Fig. 203.—Chart of Case 236.

Physical examination showed essentially the signs given in Fig. 202. *X*-ray, according to Dr. Walter J. Dodd, showed a less local and more diffuse process than would be expected from tuberculosis. The diaphragm was found to move poorly on the left. September 27th the chest showed all the signs of solidification in the left middle back, with some crackles at both bases and an occasional friction sound.

Discussion.—The remarkable feature of this case is the anemia. Most diabetics have no considerable anemia, and the opposite condition, a concentration of the blood with polycythemia in the unit obtainable, is the rule. It does not seem to me that the patient's hemorrhoids are likely to be the explanation of his anemia, for under observation it was proved that he lost scarcely any blood, and the rise in his red count under treatment was not at all marked.

Another feature of interest is the cause of his dyspnea. Although his local physician told him three months before we saw him that he had tuberculosis, we could not find the evidence of it at the time of his first entrance to the hospital. Later, we found some dubious signs which might be interpreted as tuberculosis or as bronchopneumonia. At no time was there any considerable cough or sputa. Dyspnea was his only pulmonary symptom.

All this is quite in accord with the fact that at postmortem many

cases are proved to have a complicating tuberculosis unrecognized during life. We should learn to be prepared for the fact that tuberculosis complicating diabetes gives a very different and a much less distinctive clinical picture and physical signs when compared with the ordinary non-diabetic consumptive. Cough and sputum are often absent, even when the pulmonary lesions are extensive. Râles are less constant and less numerous. In several cases that I have watched there has been none of the usual march of the disease from the apices downward. The tuberculosis appeared in patches throughout a whole lung, as marked at the base as above.

Outcome.—The patient remained a week in the hospital at this time, gained no weight, and went home on the 27th at his own request (Fig. 203).

CHAPTER XII

FAINTING

APPARENTLY, fashions have changed since Walter Scott's time. Ladies do not faint as they used to, and I do not suppose we shall ever know exactly what was the pathologic condition of Scott's heroines and the other ladies of that time. At any rate, it must be clear that fainting is much rarer than we used to suppose it to be.

But beyond the narrowing scope of the term in its *popular* use, and its availability in difficult situations, there is certainly a *medical* narrowing of its use as well. Many attacks of unconsciousness which used to be called fainting would now receive some more significant and more serious name. The typical fainting attack, as we know it at the present time, is such as comes on in persons predisposed to such attacks when they are confined in a poorly ventilated room, or when they are compelled to witness some disaster involving bloodshed. Just what happens in these cases we do not know. It is customary to suppose that the individual loses consciousness because of cerebral anemia. The face is pale, the extremities cool, pulse feeble, and it seems as if the heart was doing very little work. But exactly why cerebral anemia, when produced in chronic diseases, such as pernicious anemia, so seldom leads to fainting is not at all clear. Perhaps chronic anemia with its slow onset gives the brain opportunity to accommodate itself in some way.

However this may be, it is certainly true that we are much more cautious than we used to be, when we decide to call a given attack of unconsciousness a fainting fit. Many such attacks turn out to be epilepsy in its minor form. Others manifest cerebral arteriosclerosis or a lesion of His' bundle. The diagnosis, then, is only to be made after every effort to find organic disease has failed.

It is important to realize that just before the end of a fainting fit the patient not infrequently has a brief, generalized convulsion. One need not give up the diagnosis of fainting or swing over to epilepsy merely because of such a convulsion. I have repeatedly observed it in attacks which deserved to be called fainting, if the term is ever to be used at all.

Another point not always realized in relation to genuine fainting fits is that the patient may altogether stop breathing for a period long enough to cause considerable alarm, even to the physician. Such a period of aphonia would doubtless end itself before any serious results occurred, but it may be brought to an end promptly by the use of artificial respiration.

In a general way, such attacks are unimportant in the young and serious in the old. The exception to this statement is found in the possibility that a *petit mal*—in other words, a minor epileptic attack—may be mistaken for a faint.

Hysteric coma differs from fainting in that it has less definite relation to bad air and sudden fright. It is more under the control of the will, and usually lasts much longer than a fainting fit. The latter is usually over in a minute or two, the former lasts for hours. Fainting fits have always marked circulatory phenomena suggesting cerebral anemia, while in hysteric attacks such evidence is wanting.

Aside from the tendency to bad air and mental shock to cause fainting, it is well recognized that such attacks are more prone to occur in certain predisposed individuals or families.

Many such individuals outgrow the tendency to faint as they advance in years. Beyond this, it may be stated that all diseases which weaken the patient profoundly make him more likely to faint.

Fainting and vertigo are symptoms often closely associated. Almost all of the causes of vertigo are also, on occasions, causes of fainting and *vice versâ*.

Case 237

A man of forty-two, occupied in making white lead, entered the hospital December 8, 1900. The patient had never been sick before, except for "brain fever," which he had eighteen years ago in St. John's Hospital, Newfoundland. He was in bed seven weeks and delirious seven days.

Ten years ago an empty water barrel fell 35 feet and struck him in the forehead. He was unconscious several minutes, in bed three days, out of work two weeks. Since that time he has had a sense of burning above the left eye whenever he thinks about it. He uses about ½ pint of whisky in five weeks and ten cents' worth of tobacco a week.

He now comes to the hospital on account of *fainting spells*, which began eight weeks ago with dizziness and nausea which three or four times have led to vomiting, brought on, apparently, by suddenly

lifting his head from the pillow or turning quickly. He never has trouble while lying down or standing quietly. Three weeks ago, as he started to turn over in bed, he grew so dizzy that he fell over the side of the bed on to the floor. He was unconscious a few minutes, vomited several times, and had some stomach trouble for the next week. He has had four similar attacks, each one milder than the last. For four years he has had occasional spells of abdominal pain, lasting an hour or two, attributed by him to constipation. Bowels move every day or two. He has had nosebleed almost every day for two weeks. For two months his head has felt heavy, as if it were an effort to hold it up and prevent its dropping on to his left shoulder.

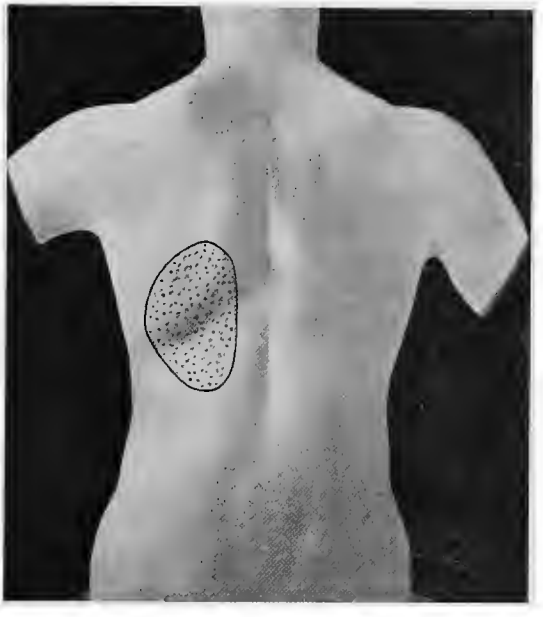

Fig. 204.—Area of partial anesthesia in Case 237.

Physical examination shows pallor, good nutrition, a spotted black line on the gums at the border of the incisors and bicuspids. No blue patches anywhere. In the left back there is an area of diminished sensation, as shown in Fig. 204. Otherwise the chest shows nothing abnormal. The radials are somewhat tortuous and thickened. All the reflexes are normal and there is no muscular weakness. The ears are negative, likewise the eye-grounds. Blood examination shows red cells, 5,000,000; whites, 9400; hemoglobin, 60 per cent. The urine is normal.

Discussion.—This patient is burdened by exposure to lead-poison-

ing and to alcohol. In view of his occupation we may imagine that the brain fever of eighteen years ago was very possibly a lead-encephalopathy.

Whether the traumatism of ten years ago has any special relation to his present symptoms I cannot say, but it seems to me very doubtful.

At the present time he is troubled not only by fainting, but by vertigo, vomiting, nosebleed, and abdominal pain. The last two of these symptoms are not ordinarily associated with fainting and suggest that some other malady is at work. Another bizarre symptom is his difficulty in holding up his head, which in a man of forty-two is more notable than during the first year of life.

The other points of note in this case are the patch of diminished sensation in the left back, the evidences of arteriosclerosis, and the anemia.

Out of this rather miscellaneous group of complaints and lesions, several draw attention strongly toward lead-poisoning as a possible diagnosis. This would explain the stomachache, the arterial changes, the anemia, the nosebleed, and very possibly the nervous lesions responsible for his patch of anesthesia and his difficulty in holding up his head. The condition of the gums strongly supports this hypothesis, but before committing ourselves absolutely, however, certain alternatives should be mentioned.

Brain tumor could cause many of his symptoms, but the negative eye-grounds, the absence of focal symptoms, and of any persistent headache are against any such idea. Arteriosclerosis might cause all his symptoms, except his anemia and the black spots upon his gums. Doubtless he has some arteriosclerosis, but in all probability plumbism is its cause.

Alcoholism would account for his vertigo, possibly his fainting, certainly his vomiting, but beyond that it cannot help us to straighten out the complicated symptomatology of the case.

Outcome.—The patient was given magnesium sulphate, ½ ounce before breakfast daily, and potassium iodid, 5 gr., twice a day. He improved steadily and had no more fainting attacks, but during the nights of the 9th and 10th had abdominal pain, keeping him awake about two hours, and relieved by pressure and hot-water bag. On the 12th of December he was so much better that he was allowed to go home. For the past seven years he has worked making white lead and his hands are constantly covered with it. He always washes them before eating, but some of the paint sticks about the finger-nails.

Case 238

An Irish butler of thirty-one entered the hospital May 16, 1907, complaining of aching in the region of the ensiform, relieved by food for several hours, also by hot drinks. Two weeks before this he began vomiting early in the morning, the vomitus being sour and relieving the pain. Lavage also relieved him. His appetite was good, bowels constipated. The previous year he had been operated upon; the gall-bladder was drained and some adhesions about it separated. The appendix was also removed at this time, though no disease was found in any of these viscera. Another operation was done February, 1907, and some more adhesions freed. After this he was well for two months. At the time of his first entrance to the Massachusetts Hospital he was very neurotic and had but little pain. Examination of his stomach, both fasting and after test-meal, showed normal contents and physical examination was otherwise negative, except that his stomach after inflation reached 2 inches below the navel. Operation was considered, but not advised.

January 29, 1908, he returned, stating that four days ago, while working as a waiter, he fainted away three times. During that night and the following day he passed four black stools. Since then he has had some epigastric pain, which last night kept him awake, and he has grown very pale and weak.

Physical examination was again negative, except that his hemoglobin was reduced to 75 per cent., and his stools were strongly positive to guaiac during the first few days. After that time they were negative. There was no fever. He had occasional night attacks of pain in the upper abdomen, but under a diet of milk and lime-water continued for two weeks, and then followed by carbohydrate and milk diet, he did very well, and left the hospital March 26th. Such pain as he had at the end of this time came about three hours after eating, and was relieved by soda. He was again in the hospital November 3 to December 9, 1908, having had pain off and on since his previous entrance. Meat-free diet and sodium bicarbonate relieved him as before.

Discussion.—Fainting associated with black stools leaves little doubt of its cause. In the majority of cases such an association is not noticed by the patient, but when he is aware of it and remembers to tell his doctor, the latter can hardly be excused for not putting two and two together and recognizing that the fainting is due to hemorrhage. Among the causes of gross bleeding from the bowel in

a man of this age, typhoid fever, cirrhosis of the liver, peptic ulcer are the only ones of any importance. Typhoid can easily be ruled out by the absence of fever and other evidences of infection. Cirrhosis is possible, but there is nothing to suggest it. On the other hand, the symptoms are all such as one expects with peptic ulcer, a diagnosis which doubtless would have been made long ago had we not been thrown off the track by the previous operation, at which the real cause of the trouble was not recognized, though it must have, in all probability, been present at that time.

Faintness from this cause is not unusual and is sometimes very sudden. I have known two patients to fall out of their chairs in such a fainting attack.

Outcome.—Soon after this Dr. E. A. Codman operated on him and found a duodenal ulcer with marked local peritonitis. Posterior gastro-enterostomy was done.

April 24, 1913, he was reported to be perfectly well and working regularly.

Case 239

A janitor of thirty-seven entered the hospital January 19, 1909, for the second time, largely on account of fainting spells which have troubled him, off and on, for the past ten months. At the time of his first entry, January 1, 1908, he stated that he had rheumatic fever at fifteen and again at twenty-five, and was told that he had severe heart trouble with his second attack, but completely recovered from it, so far as he knows. He denied venereal disease.

About fifteen years ago he did not feel well and went to a doctor, who found albumin in his urine. Under treatment this disappeared, and he was perfectly well until five years ago, when he again consulted a doctor, who found albumin once more and put him to bed for a month. The albumin then disappeared as before, and after a couple of months more of convalescence he went back to work.

In the spring of 1907 he again felt weak; he gave up his job as janitor in June and went to work on a farm, where he remained until the end of November. He worked hard all the time and felt perfectly well. He returned to Boston in December and worked at various jobs. In December, 1907, a week before the time of his first entrance to the hospital, he began to feel faint and saw spots before his eyes, but did not actually faint away. Four days later his face and his feet swelled, but he had no other symptoms at the time of entering the hospital on New Year's Day, 1908. At that time physical ex-

amination was negative, save for puffiness of the face and the following cardiac abnormalities: The heart's sounds were best heard and the left border of dulness found at a point $\frac{3}{4}$ inch outside the left nipple; the right border dulness $1\frac{1}{4}$ inch to the right of midsternum. A moderate systolic murmur was heard at the apex, transmitted to the axilla and all over the precordia. The pulmonic second sound was considerably louder than the aortic. Systolic blood-pressure was 175. Urine averaged 40 ounces in twenty-four hours, with a specific gravity of 1021 and a very large amount of albumin. Many hyaline and fine granular casts, some with red corpuscles and fat drops adherent. A few highly refractile casts. Occasionally an epithelial cast. Blood normal; fundus oculi also normal.

January 5th slight edema appeared in the legs and in the abdominal wall. There were occasional attacks of shortness of breath in the night. On the 19th ascites was made out, but by the 22d this had almost disappeared, and on the 29th he was allowed to go home.

Discussion.—This is the type of case to which Libman, of New York, has drawn attention in a recent series of interesting papers, the last of which was published in the Transactions of the Association of American Physicians, vol. xxviii, p. 307. Libman called attention specially to the fact that attacks of rheumatic—that is, streptococcic—endocarditis such as affected this patient in his early life are likely at the same time to produce renal lesions which appear much later in life, after a period of intervening good health, in the form of chronic nephritis. Whether the renal lesions are actually embolic in type, as Libman supposes, or whether they are produced by circulating toxins, need not at present be decided.

For the past fifteen years the patient has certainly had evidence of glomerulonephritis. At the present time the condition of the urine and blood-pressure leaves little room for doubt that his present cerebral symptoms are due to his kidney trouble and to the vascular cerebral crises associated with it.

Outcome.—He returned a year later, January 19, 1909, on account of the fainting spells above referred to. He has no headache, no dropsy, and no vomiting. Nocturia, four. He comes this time wholly for the fainting spells and for weakness.

Physical examination was essentially as before, but edema was absent. Systolic blood-pressure, 170; urine, 0.3 per cent. albumin; casts much fewer than before. He went home on the 23d.

Case 240

A Scotch housewife of fifty-seven entered the hospital January 9, 1911. Her family history was good. For about eleven years she has been troubled by "biliousness," coming about once a week and culminating in the vomiting of bitter green fluid, relieved by soda water and not accompanied by pain. Menopause occurred seven years ago. In August, 1910, she had swelling and pain in her knees, but was not in bed with it. Four weeks later, after the swelling had disappeared, there was much itching in both legs for a month, thought by her physician to be connected with varicose veins. This itching has occurred at times since.

For eight weeks she has had many chills and two periods of unconsciousness, the first eight weeks ago and the second six weeks ago, each accompanied by a chill, with cyanosis and unconsciousness lasting a few minutes only, though the chill lasted four hours. In the second attack she fell.

For four weeks she has vomited each night, following an attack of colic at about 2 A. M. The attacks are in the left side of the abdomen, later in the back. The pain is sharp, but does not radiate. During this time she has eaten but little, and feels very much as she usually did in the early months of her pregnancies. Her bowels are costive. There is no nocturia. The urine was examined a week ago and found normal. Two years ago she weighed 160 pounds, with clothes; now, 137 pounds, without clothes. She thinks she has lost a good deal of weight in the last few months.

Physical examination showed a patient well nourished. Normal pupils and reflexes. Chest and abdomen negative, except for slight tenderness on pressure on the left flank. On the front of the right thigh there was a white scar the size of a dime. Systolic blood-pressure, 170. Urine averaged 30 ounces in twenty-four hours; specific gravity, 1007 to 1010. Slight trace of albumin. There was a small amount of pus and red corpuscles in a catheter specimen. No casts. White cells, 12,000, with a slight polynuclear leukocytosis; hemoglobin, 85 per cent. Wassermann reaction negative. Fundi negative. The urine showed a pure culture of colon bacilli, but 20 minims injected into a guinea-pig produced no results. *X*-ray showed apparently two stones in the left kidney. The patient continued to vomit despite diet and purgation and took very little nourishment.

January 16th, soon after breakfast, she began to have peculiar spasmodic attacks, as follows: She lies quiet, the radial pulse disap-

pears, and the heart's sounds are reduced to a very slight ticking sound corresponding to first sound, and best heard just to the left of the sternum. The rate is 70 to 80 and the rhythm quite regular. No second sound is heard. In five or ten seconds the face becomes pale, then gray, the eyelids droop, and eyeballs roll up with widely dilated and non-reacting pupils. Then follow a few quick, deep respirations. Then twitching of both arms, with or without a strong backward extension of the neck. All of this lasts perhaps twenty to thirty seconds. Then there come a few violent irregular thumpings of the heart, the eyes and mouth become greatly puckered, then the face relaxes and becomes pink, the spasmodic movements of the arms cease, the pupils quickly contract to their normal size, and the patient looks up in mute astonishment as if waking from a bad dream. Within a moment another seizure may occur.

In the interims the pulse is regular, at about 40 per minute, and there seem to be two beats in the neck veins for every beat at the wrist. During the day of January 16th she had twenty-five attacks of this kind and ten to twenty in the following night. In one of these attacks, while the nurse had gone for a glass of water, she wriggled out of bed.

Discussion.—Bilious attacks are among the most mysterious and tantalizing of all the symptoms of which our patients tell us. They always seem to know so much about them and we so little. In the present case there is reason to suspect that these attacks have the same fundamental cause as the later periods of unconsciousness and chills.

The condition during the last four weeks seems to be somewhat different. The nightly attacks of abdominal pain and the marked loss of weight seem to point to something different from what is suggested in the earlier history. Presumably, she has two separate diseases.

The nocturnal attacks, when taken in connection with the physical signs in the left flank, the condition of the urine, and the *x*-ray picture, point pretty clearly to renal stone.

Quite separate from these are the attacks of January 16th and the following night. These evidently involve the brain, and our further consideration must be directed to an attempt to make out what brain trouble she has. First of all, we may note that there are no infectious symptoms, no persistent headache, and no optic neuritis; brain tumor is, therefore, improbable. Can we account for the attacks as uremia? Possibly, although one would expect a higher blood-pressure and more marked urinary abnormalities.

Vascular crises, associated with arteriosclerosis, give perhaps the most tempting explanation. The pulse is slow enough for a Stokes-Adams syndrome, and to some of those who saw the case this seemed obviously the diagnosis. No satisfactory tracings, however, were obtained from the neck veins, and I have long ago come to distrust any diagnosis of heart-block based on simple observation of neck pulsation. On the whole, then, the diagnosis seemed to rest between Stokes-Adams' disease and vascular crises. The cause of death is not obvious, but is presumably the same as that which produced the cerebral attacks. The loss of weight must be attributed to arteriosclerosis.

Outcome.—On the day following she died in an attack which began just like the rest. Autopsy showed arteriosclerotic nephritis with a stone in the pelvis of the left kidney and slight hydronephrosis, also some calcium oxalate stones in the tissue of both kidneys; slight hypertrophy and dilatation of the heart; chronic pleuritis, obsolete tuberculosis at the apices of both lungs, and cholelithiasis. The heart showed no lesion in the region of His' bundle and was not remarkable save as above noted. The brain was normal.

Case 241

A contractor of sixty-five entered the hospital November 30, 1910. His family history was excellent. He has been unable for some time to sleep on his left side. He cannot say why. He has been active and strong muscularly, but has had some sort of stomach trouble, the nature of which cannot be definitely described. For three months he has been losing weight.

Ten years ago he had an attack similar to the present one, and since that time he has had six or seven in all. In each of these attacks he suddenly faints, without the least warning; once in the middle of a sentence. After ten or fifteen minutes he begins to recover and in two or three hours is all right. During the attack he is chilly, but sweats profusely. There has been no convulsion, no foam at the mouth, no cry, and no loss of sphincteric control. A drink of whisky appears to shorten the attacks. Pallor and cyanosis accompany them. His last attack was three months ago and was longer than the others.

About 2.15 P. M. this afternoon he was picked up on the street unconscious. At 5.15 P. M. he recognized his son, but seemed still much dazed. Later in the day the patient showed slight aphasia, but answered questions fairly well, and stated that at the beginning of the attack he noticed that he could not use his hands and that they shook

a little. A window was opened, but he does not remember what happened next. He has never had dyspnea or precordial pain. He was examined after an attack in 1904 and told that his heart was all right and that his fainting was caused by indigestion and worry.

Physical examination showed well-developed pupillary reactions, somewhat sluggish on the left. Tongue came out straight. Heart's apex just outside the nipple line. Action slow, regular, no murmurs. Pulses showed increased tension. Systolic blood-pressure fell from 180 mm. Hg. at entrance to 105 a week later. Pulse-rate was in the neighborhood of 60 throughout his week's stay in the hospital. Lungs and abdomen negative. Reflexes, motion, and sensation negative. Blood and urine normal, except for an occasional hyaline and granular cast in the specimen of December 1st.

On the 2d of December it is noticed that the wrist reflex and the Achilles reflex are slightly increased on the right and the cremasteric diminished on the right. Thinking and talking are slow and unsatisfactory. He can scarcely read or spell, though he used to be proficient in these respects.

Discussion.—Fainting attacks beginning at the age of fifty-five are, of course, spurious. No one has true fainting attacks independent of organic disease at that age, and most attacks which receive that name, in people past middle life, turn out to be due to uremia or arteriosclerosis. Yet, when the mistaken diagnosis of fainting is avoided, the other commonest mistake is to refer such attacks to indigestion. This blunder also was committed in the present case. It is high time that we all came to realize that indigestion never causes marked cerebral symptoms, and that the indispositions of prominent elderly men at banquets and elsewhere, though ordinarily called indigestion, are usually of vascular origin and mean disease of the heart, brain, or kidney.

In the present case the aphasia, the paretic hands, the suggestion of hemiplegia contained in the physical examination, the high blood-pressure and mental changes, make a diagnosis of cerebral arteriosclerosis inevitable. Whether an actual hemorrhage has taken place, or whether, as is more probable, we are dealing with a vascular crisis, cannot be positively decided. Such attacks are sure to be repeated and become more severe.

Outcome.—By December 9th he could read and spell normally, walked strongly, and was allowed to go home.

Case 242

A pedler of sixty-five entered the hospital March 22, 1911. His family history was negative. He has always been well until six weeks ago, February 15, 1911, when he suddenly fainted in a store and fell, cutting his head. Within a minute he was conscious and clear-headed, but had a peculiar throbbing in the epigastrium and felt weak for a few minutes. He was taken to the hospital room within the store and his wound sewed up, but fainted again and was unconscious for thirty seconds. He was then sent to the Municipal Relief Station, where he fainted once more and stayed in bed twenty-four hours, after which he was sent home in an ambulance and has remained in bed since. During the past six weeks he has had many attacks almost exactly like the first, but for the last three days these attacks have ceased. There have never been any convulsive movements in the attacks, no dyspnea, cough, or cyanosis, no headache or vertigo, no urinary symptoms. He says he has eaten almost nothing. His time has apparently been consumed in taking many medicines, powders and pills, both day and night. He says he has bushels of empty bottles as a result.

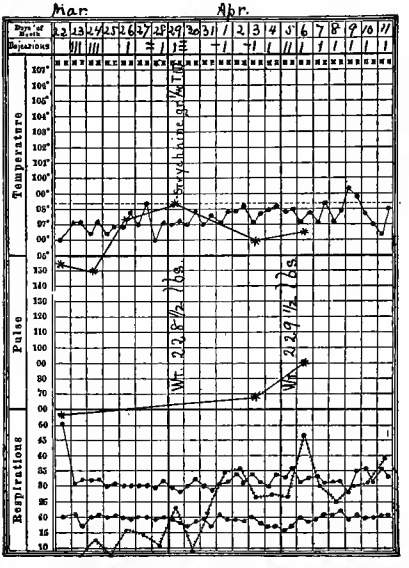

Fig. 205.—The systolic and diastolic blood-pressure (starred lines) in Case 242. Note also the slow pulse, subnormal temperature, and low urinary output (cross-dotted line) recorded in ounces.

Physical examination shows nothing remarkable except as concerns the circulatory system. The heart's dulness extends to the second rib above and 11 cm. to the left of the median line, 2 cm. inside the nipple. Right border behind the sternum at a point not clearly determined. The impulse is not seen or felt. The sounds are regular and forceful. A rough systolic murmur is heard all over the precordia, loudest just inside the apex. The neck veins are distended and pulsate twice between each of the radial beats, which occur, as a rule, from 30 to 35 times a minute. The urine is negative. The blood-pressure, systolic and diastolic, is recorded in Fig. 205. Fluoro-

scopic examination is negative. Atropin and strychnin subcutaneously have no special effect. Blood and urine show nothing of importance.

Discussion.—Of course, it was not a fainting fit which happened to this patient six weeks ago. There are many such tales about people of his age, tales of falling down stairs and striking the head, tales of stumbling and falling with a stunning blow. Many of such stories go hindside foremost. What has happened is that the person has become unconscious and therefore falls; not fallen and therefore becomes unconscious.

In the present case it might perfectly well have been a fainting fit had it occurred in a younger person, but at sixty-five we should be very skeptical of any diagnosis of fainting.

When we come to the positive side of the question, we must confess that without polygraphic tracing from the neck and wrist we cannot be certain whether the observation of two venous beats between each pair of radial beats is true or not. The attack seems like one of Stokes-Adams' disease, but there are many mistakes in this diagnosis unless the most accurate methods of observation are used. If the attack was not Stokes-Adams' disease it was, in all probability, a vascular crisis.

Outcome.—He left the hospital April 12th, having had no attack of syncope in the meantime.

Case 243

A chauffeur of thirty-six entered the hospital July 10, 1911. His family history and past history are excellent. Ten years ago the patient was very active and worked in a gymnasium. Since he gave up exercise, nine years ago, on account of business, he has been less athletic than before, but felt no other special change until a year ago, when he began to notice that he tired very easily and had to give up his work as chauffeur for a day or two at a time. Nevertheless, he worked, with slight intermissions, until two weeks ago. Ten days ago he fainted for the first time in his life, though he has felt faint several times in the last few months. Palpitation and dyspnea on exertion have been noticed for several months. The appetite has been excellent until ten days ago; since then, poor. His bowels are irregular, but usually constipated. For a week he has noticed that his mouth is sore. Nine years ago he weighed 170 pounds; now, 143 pounds.

Physical examination shows evidence of some loss of weight.

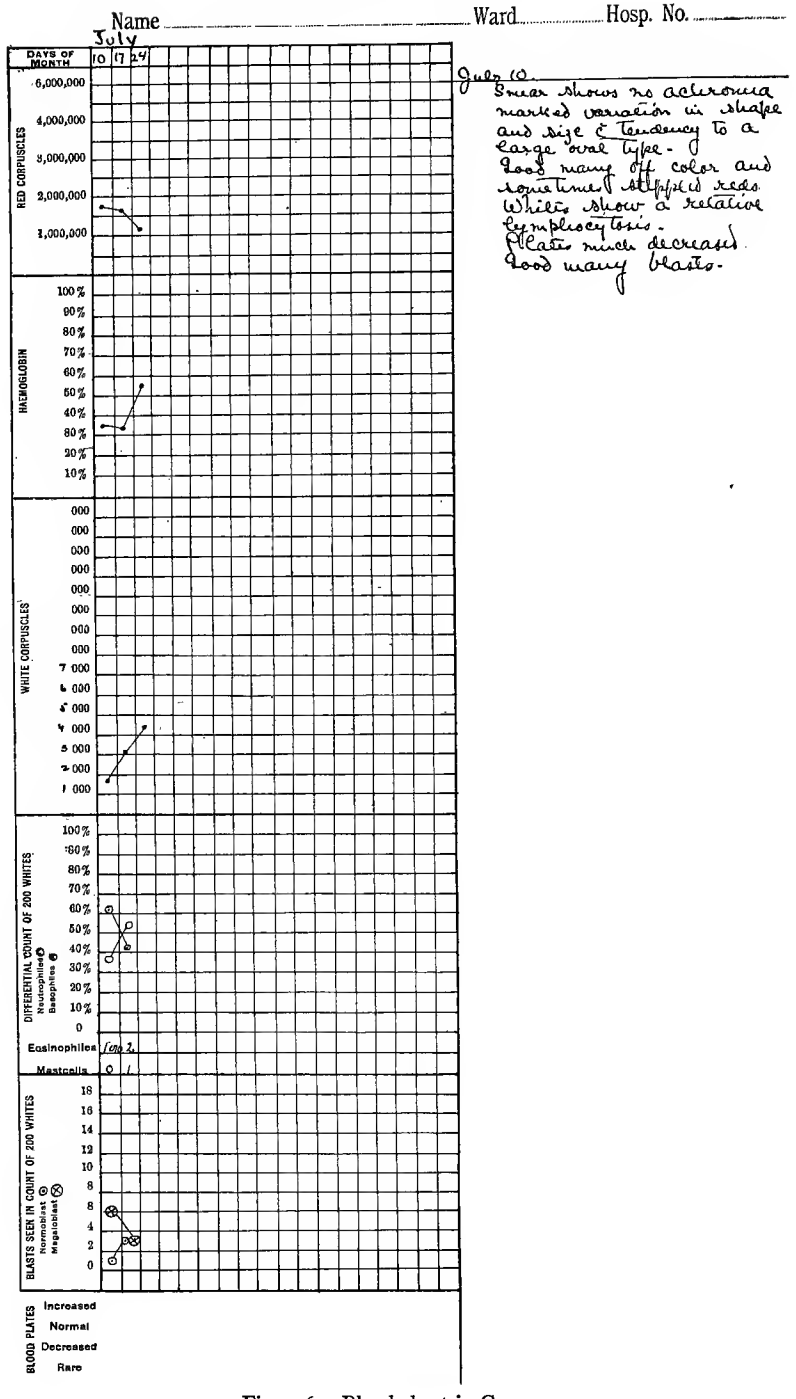

Fig. 206.—Blood chart in Case 243.

His scleræ slightly yellow; mucous membranes very pale. Pupils normal; knee-jerks reduced, but present. The heart area is normal, but the apex impulse is not seen or felt. A blowing systolic murmur over the whole precordia, loudest at the apex. Lungs and abdomen negative. Urine negative. Blood as in Fig. 206.

Discussion.—This appears to be a fainting fit due to general weakness, what might be called the cachectic type of fainting. From the history I do not see that any guess could be made as to the underlying cause of his weakness. The blood-picture leaves no doubt that the diagnosis is pernicious anemia. Fainting is relatively uncommon

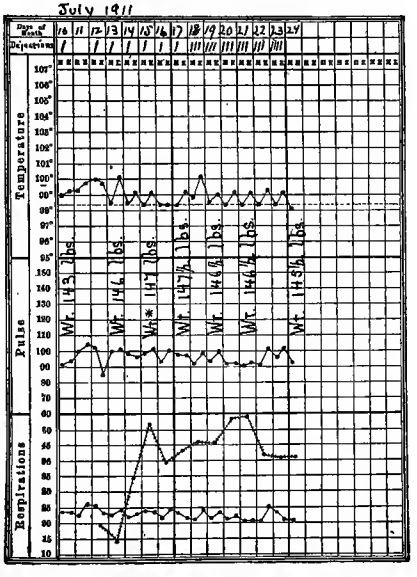

Fig. 207.—Temperature, weight, pulse, urine, and respiration in Case 243.

in that disease, surprisingly uncommon when we consider how great must be the degree of cerebral anemia.

Outcome.—The patient gained 4 pounds in his first week, but lost 2 pounds in his second. He ran a slight, irregular fever, as is shown in Fig. 207. He left on the 24th, feeling better than at entrance.

Case 244

An unoccupied woman, aged twenty-one, entered the hospital November 8, 1911. The patient's family history and past history are excellent. She has never been nervous. Six months ago, without known cause, she began to have fainting spells, coming at irregular

intervals, sometimes every day or several times daily, sometimes only once in a fortnight. In these attacks she loses consciousness and falls, sometimes to the floor, sometimes to a bed, but has never hurt herself. In the attacks her arms and legs become rigid and flexed, and when she is coming out of them her mouth "works." The attacks last fifteen to thirty minutes, and are followed by a period of weakness lasting about half an hour. They are more troublesome just before the menstrual period. In the interval she feels entirely well. She is occasionally nauseated after one of these fits, but never vomits. Her eyesight is good and she has no other symptoms of any kind.

Physical examination shows good nutrition; small white scars on the cornea of each eye; the right pupil larger than the left, both reacting normally. A soft-blowing systolic murmur is heard at the apex, not widely transmitted. Pulmonic second sound is greater than the aortic second, but not accentuated. The right pulse larger than the left. The lungs show nothing abnormal. There is a slight general tenderness in the lower abdomen, but nothing else of note. The hymen is normal, the labia not hypertrophied or pigmented. Reflexes normal. The left leg slightly smaller than the right. Systolic blood-pressure, 115. Wassermann reaction is recorded as suspicious, but not positive. Temperature, pulse, respiration, blood, and urine normal.

Discussion.—Are we dealing with organic or with functional disease? In favor of some organic lesion is the smallness of the left pulse, the left pupil, and the left leg, the suspicious Wassermann reaction, the scars upon the cornea. None of these data, however, is conclusive.

In favor of functional disease is the age and sex, the connection of the symptoms with the menstrual period, the negative physical examination, and, above all, the fact that the attacks are never nocturnal, never injurious to the patient, and never present any of the characteristic signs of epilepsy.

The attacks are obviously too long to deserve the term "fainting fit," and the rigidity during them is quite uncharacteristic. On the other hand, both of these features are what we expect in hysteria, and I see no good reason to doubt this diagnosis.

Outcome.—During her five days in the hospital the patient had no attack and refused treatment.

Case 245

A factory girl of eighteen entered the hospital March 14, 1912. Her family history and past history not remarkable, though the patient eats 15 cents' worth of candy every other day. Ten months ago, without known cause, the patient began to have fainting spells. In the first three weeks they came fifteen to twenty times a day. Since then they have grown more infrequent, until now they only come once a month. They are often preceded by lack of appetite, headache, and drowsiness. After the fainting fit she feels better.

In the attack she sometimes falls, bumping her head. Sometimes she is able to get a glass of water and recover without losing consciousness. She has no twitching or convulsions and no warning of the approach of an attack, except through the general symptoms above mentioned. The attacks may occur at any time of day, but never during the night. Except during the first three months of her trouble she has worked steadily.

She has no appetite at the present time and her food tastes queer to her. Her bowels are regular. She eats at a restaurant, where her food costs $3 a week. She sleeps well.

On physical examination the patient is pale and looks tired. Pupils and tendon reflexes normal. Viscera negative. Blood and urine negative. No fever in ten days' observation. Systolic blood-pressure, 120 mm. Hg.

Further investigation showed that she lived in a room with her sister and in the same house with a girl chum, whose brother is said to be engaged to the patient's sister. The chum's brother and father drink much and work little, and it is thought by some friends that the three girls support the two men. All three girls work in an ink factory.

A friend describes an attack which took place at a lecture. The patient's neck gradually stiffened, head drawn back, eyes closed. She then slipped unconscious between the seats and remained so for five or six minutes. The legs were stiff and straight. There was no cry and no convulsion, except that while slowly coming out of the attack there were slow spasms of the arms and legs. On the 24th she had an attack, beginning with a shuddering sort of tremor, with the legs stiff and the eyes tightly closed. She was then referred to the Social Service Department for more thorough investigation.

Discussion.—The poor hygienic and mental conditions surrounding the patient seem in all probability of importance, whether as aggravating or producing the attack. The most important diagnostic

fact is the negative physical examination, especially when considered in connection with the patient's age and sex. Clearly, we are not dealing with fainting spells, for these never occur fifteen or twenty times a day, nor does a person feel relieved after a fainting fit.

The description of the attack, beginning with spasm and rigidity, is strongly suggestive of hysteria, and in the absence of physical signs no other diagnosis is possible.

Outcome.—Worries and mental conflicts sufficient to produce her symptoms were found. November 29, 1912, she was better and having much fewer attacks.

CHAPTER XIII

HOARSENESS

CASES of hoarseness may be divided into those which are acute and usually of trifling importance, and those which are chronic and usually serious. Any one who shouts much at a college game or a political rally acquires, I take it, an acute laryngitis as the cause of his inevitable hoarseness. Just how this irritation is produced I do not know. If a person knows how to use his voice, he may make a great deal more noise than his neighbor who gets hoarse, and yet retain his voice quite clear. In some way it is the misuse, rather than the simple overuse, of the voice that produces such trouble.

After an ordinary acute laryngitis, such as occurs as part of a "common cold," men's voices behave quite differently from those of women. In men the vocal cords slacken down, the voice becomes a deep bass, but is seldom lost altogether. In women, on the other hand, we see no such marked lowering in the pitch of the voice, but it is far more common to see complete aphonia or voicelessness after slight laryngitis. This is of considerable importance in connection with the explanation of what is ordinarily called "hysteric aphonia." Such aphonia is usually preceded by an attack of ordinary acute laryngitis. It does not come on from purely psychic causes, as a rule, yet it is not independent of psychic factors. The connection between the cerebral innervation (what we call the will) and the vocal cords is temporarily lost as the result of the laryngitis.

This is the first step in the process. Now, if there is any congenital tendency to a pathologic forgetfulness or splitting up of the mind into mutually unconscious parts, if, in other words, there is any tendency to hysteria, there may be considerable difficulty in re-establishing the patient's memory of how to talk. When this difficulty occurs and prolongs the aphonia after the laryngitis has disappeared we call it, very naturally, hysteria, but we should bear in mind that such an attack may occur in a person who is not hysteric, in the sense of showing any other manifestation of that disease. In other words, there is probably enough tendency to hysteria in a great many of us to result in a hysteric aphonia, provided the connection

between the brain and the vocal cords were once broken up by the lesion of laryngitis. In men this break does not occur at all frequently; in all probability this is one of the reasons for the infrequency of hysteric aphonia in men.

Chronic hoarseness or aphonia is due almost exclusively to organic disease of the larynx or to a pressure paralysis produced by tumor or aneurysm of the mediastinum. Occasionally, the pressure of a dilated heart in mitral stenosis or other cardiac disease may produce the same effect. Enlargement of the left lobe of the thyroid gland, occasionally enlarged bronchial lymph-glands, may produce similar pressure. Tuberculosis at the apex of the lung may also involve the recurrent (laryngeal) nerve, producing paralysis of one vocal cord.

In the larynx itself tuberculosis, syphilis, and tumors, benign or malignant, are the commonest causes of hoarseness or aphonia. The diagnosis of these conditions depends, of course, upon an expert laryngologic examination.

Case 246

A housewife of fifty-two entered the hospital January 10, 1908. Two of patient's sisters died of cancer; one sister, of "nerves." Her

Fig. 208.—Shape of nose in Case 246.

husband died at twenty-nine of "heart disease and paralytic shocks." She has one child of twenty-four, well. Many years ago she had

Hoarseness and Aphonia



diphtheria, very severely. Four years ago she had a partial hysterectomy for uterine tumors at the Baptist Hospital, and a year later the left kidney was removed "on account of something which was cut at the previous operation." She passes water four to ten times in the night and has done so for years, the amount varying with the amount of water she takes.

For three weeks she has had a cold in her head and a sore throat. A week ago she became dizzy and almost lost consciousness upon the street. She staggered, but managed to get home. Since then she has had fever, sweating, cough, sore throat, headache, and increasing hoarseness. The cough has been dry until to-day, when she began to raise thick, purulent sputum. She has been unable to speak for three days.

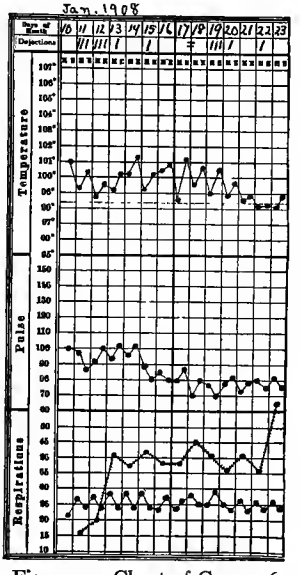

Fig. 209.—Chart of Case 246.

Physical examination showed obesity, normal pupils and reflexes, a hard, tender gland at the angle of the left jaw, herpes on the nose and upper lip. The lungs showed groaning râles throughout, but were otherwise negative, likewise the heart. The tension of the pulse seemed to be increased. The blood-pressure was not measured. Physical examination was otherwise negative. The shape of the nose is shown in Fig. 208. A laryngologist found marked chronic atrophic rhinitis, also acute pharyngitis, and laryngitis. The blood showed 11,000 white cells, 85 per cent. hemoglobin. The urine was normal. The temperature was as shown in Fig. 209. During the first few nights of her stay the patient had severe attacks of laryngeal dyspnea with croupy cough. An intubation outfit was kept at hand, but was not needed. By the 15th these attacks ceased, but the lungs were full of dry and moist râles. The palatal reflexes were at this time noticed to be absent, perhaps owing to her former attack of diphtheria.

Discussion.—At first sight of this patient there is every reason to think that we are dealing with an acute laryngitis. The three weeks' sore throat, cough, headache, and gradually increasing hoarseness are fairly typical of that lesion. The herpes and glandular enlargement in the neck are wholly in keeping with such a diagnosis.

On the other hand, the suggestion of syphilis in the husband, the patient's habit of nocturia, and the absence of palatal reflexes should make us pause for a moment to consider whether some more serious disease, or, in particular, whether syphilis may not be in the background.

In a case of this sort the services of a laryngologist are essential if diagnosis is to be prompt and sure. Without such help one may make a successful guess, but nothing more. In view of the laryngoscopic finding in the present case, there seems no reason to doubt that the acute infection of the upper air-passages is all that ails the patient.

Outcome.—On the 30th of January she was sitting up and her voice had returned. On the 5th of February she seemed to be entirely well and left the hospital. The treatment consisted of potassium iodid, 10 gr., three times a day, hot Dobell's solution as a gargle, twice a day, codein, 1 gr., every two hours when needed for cough, inhalation from steam, from water containing 1 dram of compound tincture of benzoin to the pint.

Case 247

A nurse of twenty-four, newly arrived at the Massachusetts General Hospital, and previously employed for two years in a hospital for the insane, entered the hospital April 8, 1901. She said she had felt perfectly well until three days ago; then, while on duty, she began to have headache, general muscular pains, chilliness, fever, sweating, nausea, and loss of appetite. Her voice from the first has been more and more hoarse, and yesterday she lost it altogether. At the beginning of her illness there was a little cough, without sputum, and a slight sore throat, with stiffness of the neck. She worked until yesterday, but took to bed in the evening.

Physical examination showed good nutrition, herpes of the lower lip, reddening of the tonsils and pharynx, tender glands in both sides of the neck. A soft systolic murmur at the apex of the heart, without any other abnormality. Lungs, abdomen, and nervous system normal. Blood and urine normal. While in the ward the patient was apathetic much of the time, waking from time to time with a start. She had no cough. Examination of the larynx, by Dr. Algernon Coolidge, showed no disease.

Discussion.—Clearly the case began with an acute infection. Everything in the history and physical signs points to this. An aphonia persisting after such an infection is usually of the type called hysteric, and discussed in the introductory paragraphs of this chapter.

Outcome.—Dr. Coolidge's diagnosis was hysteric aphonia. By the 14th her voice was normal. It appeared that she had had a previous hysteric attack in the winter before. On the 18th she left the ward well.

Case 248

A jeweler of forty-five, born in Turkey, entered the hospital October 5, 1906. The patient has a negative family history and has had no other illness. He denies venereal disease.

Three years ago he began to have a shooting pain in the right hand and forearm. Later a similar pain came in the other side, and

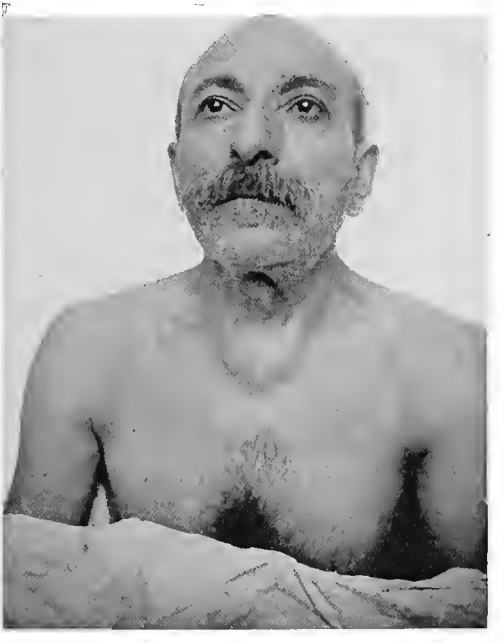

Fig. 210.—Shape of head and suprasternal bulge in Case 248.

later still the pain extended to the shoulders and neck, even to the head. This pain has continued and has grown steadily worse. It has been treated by many doctors for rheumatism, without relief, and has prevented work for the past three years. It has never extended below the level of the shoulders.

The patient had absolutely no other symptom until the fall of 1906, when there appeared hoarseness and a severe cough, often dry, sometimes with foamy sputa, which cough has continued up to the present time, except for a slight remission during the past summer.

With this cough there came dyspnea on exertion. Five months ago he began to have orthopnea at night.

Physical examination showed a remarkable flattening of the back of the head (Figs. 210, 211). The mucous membranes were cyanotic. Pupils normal. The voice was hoarse, and there was a frequent ringing cough. At the top of the sternum was a round, pulsating tumor, extending down to within 1 inch of the angle of Louis and as high as the larynx. It was $3\frac{3}{4}$ inches wide and 2 inches high. It was tender to touch. The heart's apex extended $\frac{3}{4}$ inch outside the

Fig. 211.—Shape of head and suprasternal bulge in Case 248.

nipple, in the fifth space; no enlargement to the right. At the apex there was a harsh systolic murmur, transmitted to the axilla. Over the tumor a harsh systolic was also heard. About the tumor there was an area of dulness, as shown in Fig. 212. The left pulse seemed a little larger than the right. The artery walls were easily felt. The lungs and abdomen were negative save for double inguinal hernia.

A laryngologic examination showed paralysis of the recurrent laryngeal nerve. Systolic blood-pressure at entrance was 155. It soon fell to 130 mm. Hg., and remained there during the nine months of his stay in the hospital. Blood and urine showed nothing abnormal.

There was no fever. The cough was controlled only by $\frac{1}{4}$-gr. doses of codein or morphin. *X*-ray showed a shadow corresponding with the ascending and transverse arch of the aorta. A diastolic murmur was audible from time to time, usually best heard at the apex, but also in the third and fourth left interspaces, near the sternum. Dr. R. H. Fitz considered it due to mitral stenosis. It could be heard indistinctly as far back as the posterior axillary line. It was a long, early diastolic sound and replaced the aortic second sound at the apex.

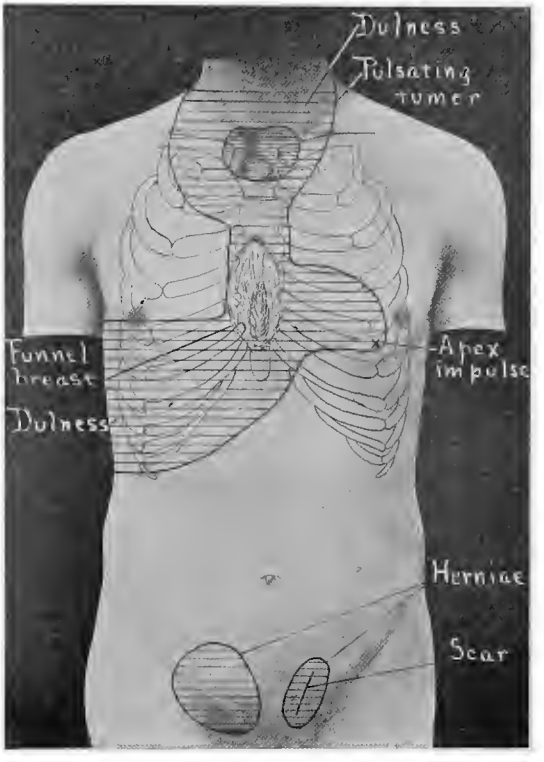

Fig. 212.—Physical signs in Case 248.

On the 30th of January 250 c.c. of a 1 per cent. solution of gelatin in 0.6 per cent. sodium chlorid solution were injected under the skin, on the left side of the abdomen. This caused severe pain and two hours later a chill, with rise of temperature to 102° F., subsiding in about thirty-six hours. An area of tenderness and redness surrounded the site of the injection and extended round to the back. This was still present February 5th. On that date the diastolic murmur in the left anterior axillary line was louder than the systolic.

By the 9th of February the local reaction about the site of the gelatin injection was gone, and on the 12th of February a second injection, similar to the first, was given. The reaction was like that after the previous injection, but somewhat milder. There was no effect perceived in the condition of the tumor.

Discussion.—When hoarseness and cough appear in a middle-aged man, without any evidence of acute infection and immediately following an attack of pain about the upper chest and shoulders or in the arms, one should always suspect that aneurysm is the cause. When a pulsating tumor appears at the root of the neck in front, we can have very little doubt of the diagnosis. Such a tumor might conceivably be a pulsating vascular thyroid, but such a lesion would certainly have been of much longer duration, and would, in all probability, be associated with other manifestations of thyrotoxicosis.

If the patient has aneurysm, as there is every reason to believe, the diastolic murmur is naturally to be explained as a result of widening in the aortic arch at the base of the aortic cusps. There seems no good sense in calling it mitral stenosis. The fact that the patient has been treated by many doctors for what was called rheumatism is no reason for supposing that he has ever had rheumatism, in view of the fact that pains often mistaken for that disease are especially common in aneurysm.

The *x*-ray, as is usual in such cases, showed a much more extensive growth within the thorax than would have been predicted from what we would discover on direct physical examination. The effects of gelatin injections in this case were similar to what I have seen in a good many others during the luckily short-lived vogue of that treatment. It causes a great deal of pain, but no good effect.

Outcome.—The patient's general condition had improved very much and he was active in helping about the ward. On the 24th of February he left the hospital.

Case 249

An Italian schoolboy of nine entered the hospital March 1, 1909. Since the 4th of July the boy has been hoarse. In January he choked on a peanut. Last month he had his tonsils removed. Except for hoarseness he is now all right. Family history and past history negative save that he has had scabies.

Physical examination showed a healthy boy with inspiratory and expiratory dyspnea, involving movements of the accessory muscles of

respiration. Physical examination was negative save as relates to the larynx and the fingers. His nails were somewhat incurved.

Discussion.—Probably the history of choking on a peanut and the tonsillectomy have nothing to do with this case, as six months have elapsed since the choking and a month since the tonsillectomy. Organic disease of the larynx is not common at this boy's age, but his clubbed fingers suggest that some congenital cause may have been at work. What this is only the laryngoscope can determine.

It is of some interest to note that although the cause of dyspnea is high up in the respiratory passages, the dyspnea is not exclusively of the inspiratory type, but involves expiration as well. We are usually taught that trouble of this sort should produce inspiratory, not mixed, dyspnea.

Outcome.—Laryngoscopic examination showed a papilloma of the larynx. On the 4th of March he was transferred to ward G for operation. On the 5th of March the papilloma was removed. By the 8th the child was out of bed, although there was a large piece of the growth still remaining. He left the hospital on the 11th.

Case 250

A salesman of fifty-six entered the hospital May 23, 1910. Family history not remarkable. The patient has always been well, but seven years ago he had to give up playing baseball because he could not run the bases. Five years ago he began to get somewhat more short of breath. Three years ago he was taken rather suddenly with hoarseness and a chill and pain in his right side and fever. The illness was called grip, but he has never recovered his strength and has never been able to work since that time. He lost 25 pounds in weight at the time of that illness and 25 pounds more since that time. Any attempt to work and exert himself in any way causes a choking sense of pressure beneath the sternum, a short dry cough, and difficulty in getting his breath. He has had no sputum and no pain, no wheeziness, and no paroxysms of dyspnea.

For three years he has had left trifacial neuralgia, the pain coming in quick flashes and going from the left temple to the corner of the mouth. *Throughout the three years he has continued to be hoarse.*

The patient is well nourished and lies comfortably without pillows. Pupils negative. Knee-jerks and Achilles' jerks not obtained. Babinski's reaction is present on the left. The right plantar is not satisfactorily obtained. There is no glandular enlargement. The heart is negative. Lungs as in Figs. 213, 214. The breathing seems to

be of diminished intensity over the whole left side. The right pulse is stronger than the left. Abdomen negative. The laryngoscope shows that the lower part of the trachea is pushed forward so that the tube is not straight. Blood and urine are normal, likewise Wassermann reaction.

Discussion.—Tuberculosis, syphilis, and tumor must be considered. The lung signs and the hoarseness are familiar tuberculous symptoms. Loss of weight would be a natural accompaniment. Against this idea, however, is the fact that his illness began with

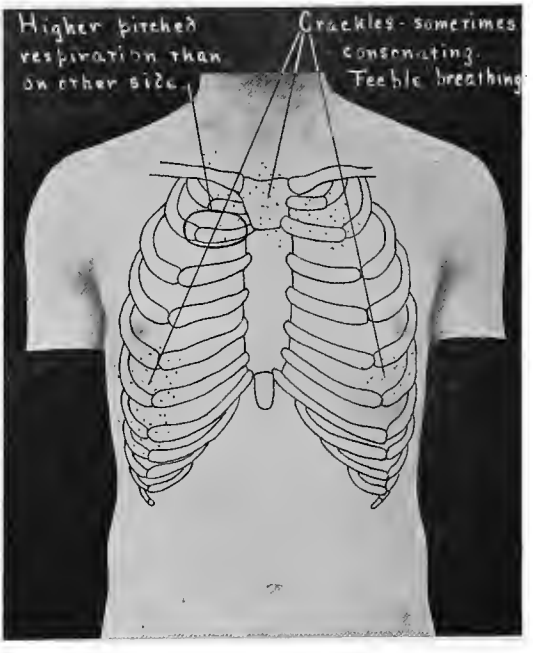

Fig. 213.—Chest signs in Case 250.

hoarseness and the cough developed considerably later and seems to be directly connected with exhaustion. Without the finding of bacilli or other very positive evidences of tuberculosis there would be no reason to consider this disease further, in view of the many symptoms pointing in another direction.

Syphilis, with resulting aneurysm, naturally occurs to us when we find that the knee-jerks are absent and recognize symptoms like those of mediastinal pressure, especially the displacement of the trachea. The negative Wassermann reaction does not disprove this theory. On the other hand, we have no positive evidence of syphilis,

and the pain which the patient has suffered is not like that generally seen in aneurysm. The diminution of the left pulse and the respiration in the left lung could be explained either by aneurysm or by some other cause of pressure. If the statement of a displacement from behind forward is correct, we must recognize that this is not the usual direction in which aneurysm exerts its pressure upon the trachea. Aneurysm generally presses upon the front or side of the windpipe.

Further evidence in the difficult distinction between mediastinal tumor and aneurysm must be sought in *x*-ray examination.

Outcome.—During a month's stay in the hospital the patient lost 10 pounds in weight, but had no fever. Systolic blood-pressure, 122.

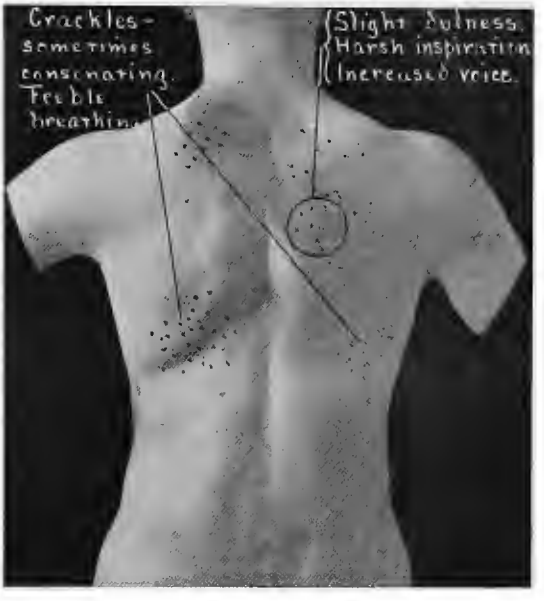

Fig. 214.—Chest signs in Case 250.

X-ray showed large indefinite shadow in the mediastinum, believed by Dr. Dodd to show definite evidence of mediastinal pressure, especially on the right of the sternum. Skin tuberculin test was negative, and subcutaneous tuberculin, gradually increased 1 to 10 mg., also gave no reaction. On the 11th of June the lung signs were less marked behind, but the crackles in the upper fronts persisted. He was given treatments by *x*-ray, and left the hospital on the 16th of June. He died October 9, 1912. The death certificate was signed "Heart trouble."

Case 251

A farmer of twenty entered the hospital August 8, 1910. The patient was born in Russia, and had been studied in the Out-patient Department previous to entrance. He spoke but little English, and all the history that could be obtained was that he had had pains in his ankles, shoulders, elbows, and wrists three months ago and that for the past month he had been very hoarse, but had been able to work.

Physical examination showed good nutrition, normal pupils and reflexes, no glandular enlargement. The heart's impulse, seen and

Fig. 215.—Position of *x*-ray shadows in Case 251.

felt in the sixth space, 3 cm. outside the nipple line, right border $4\frac{1}{2}$ cm. from midsternum. There was a palpable systolic thrill at the apex and a blowing systolic murmur transmitted to the axilla and base. A rough diastolic murmur was heard best in the axilla and at the apex, faintly along the left edge of the sternum, not at all on the right side. The aortic second was faint; pulmonic second, loud. The pulses had a marked Corrigan quality and there was a capillary pulse visible in the fingers. Duroziez's sign was present and all the peripheral arteries pulsated visibly. The abdomen was negative, save that the edge of the liver could be distinctly felt 2 cm. below the costal margin. The blood and urine showed nothing abnormal. Blood-pressure,

120 mm. Hg., systolic; 40 mm. Hg., diastolic. Wassermann reaction negative. Skin tuberculin reaction slightly positive.

Laryngoscopic examination showed the left vocal cord in the cadaveric position, both in respiration and phonation. By the 13th his bronchitis had practically cleared up. *X*-ray on the 18th showed a shadow about the roots of both lungs, especially on the right. Tuberculous glands and malignant disease were suggested (Fig. 215). The heart by *x*-ray was huge. The patient did not react to 10 mg. of old tuberculin, subcutaneously. On the 4th of September the right border extended 4 cm. beyond the right edge of the sternum, in the third space.

Discussion.—Everything points toward aneurysm here except the negative *x*-ray examination and the negative Wassermann. It is, however, possible that a rheumatic endocarditis may produce sufficient dilatation of the left auricle to compress or injure the recurrent laryngeal nerve.

The cardiac signs do not indicate anything of this sort, but these signs may well be wrongly observed or wrongly interpreted.

Despite the slightly positive skin reaction from tuberculin and the shadows about the roots of both lungs, there seems to me no good reason to imagine that tuberculosis is the cause of any symptoms in this case. The negative reaction to 10 minims of old tuberculin subcutaneously is important negative evidence in this connection. I do not see how a positive diagnosis can be made. On the whole, I am inclined to believe that syphilis is at the bottom of the whole trouble. So large a heart as the *x*-ray shows could hardly have been produced by a rheumatic endocarditis within three months and without more evidence of decompensation. It seems unreasonable to suppose that a dilated left auricle has produced the laryngeal paralysis. I believe that later evidence will be more conclusive in favor of the diagnosis of aneurysm.

Outcome.—Under mercurial inunction and iodid of potash the patient improved very much, and left the hospital on the 9th of September, having gained 4 pounds during his month's stay.

Case 252

An engineer of twenty-eight entered the hospital August 27, 1910. The patient's family history is negative. For two years he has had gaseous indigestion after eating, immediately relieved by soda or any simple remedy. During this period his bowels have been rather constipated. He denies venereal disease and has always considered himself well. He has been married twelve years. He has no children.

In January, 1908, he noticed that he was short of breath on exertion. This trouble has steadily and slowly increased since. Shortly after this he noticed a pain in the left axilla—sharp, stinging, continuous—often keeping him awake at night during the six months of its duration. It then passed off spontaneously and did not recur. For a year, however, he has had another pain, which he says is around his heart, passing from the left to the right side, sharp, steady, and often preventing sleep. For a month he has had dry cough and for two weeks orthopnea.

Six days ago he suddenly became hoarse, and has been unable to speak above a whisper ever since. He gave up work ten days ago and has lost much in weight and strength. His main complaints are dyspnea, pain, and hoarseness.

Physical examination showed good nutrition, pupils, glands, and reflexes normal. The whole chest, especially the left chest, heaved with each systole. The heart's apex reached $2\frac{1}{2}$ cm. outside the nipple line and its dulness $4\frac{1}{2}$ cm. to the right of midsternum. The quality of the impulse was forcible, and the first sound was followed by a blowing systolic murmur, loudest in the pulmonary area. The pulmonic second sound was palpable as a shock and very loud. There was no thrill. The pulses were normal. The entire left lung showed bronchovesicular breathing and increased whisper and was nearly flat on percussion. The right lung was normal, likewise the abdomen. Systolic blood-pressure was 100 mm. Hg. in the right arm, 90 in the left. The blood was normal. The Wassermann reaction was negative. Urine was normal. A laryngologist found the left vocal cord motionless in the cadaveric position. *X*-ray showed a diffuse shadow through the entire left chest, suggesting fluid or thickened pleura. No evidence of aneurysm. On the 1st of September the pupils were found to be unequal, and small, hard, epitrochlear glands were felt.

Discussion.—I am driven to a similar course of reasoning in this case as in the previous one. If the patient has no syphilis, why should his heart be so large? He has nothing else in his history or in his physical examination to produce a *cor bovinum* capable of lifting the whole chest at each beat. The negative *x*-ray does not disprove aneurysm, for the extensive shadow in the left chest might cover up the outline of the aorta. Just what is going on in the left chest it is difficult to say, but it is certainly possible that aneursymal pressure could produce such appearances and signs. Conceivably a chronic pleurisy might involve the recurrent laryngeal nerve and produce hoarseness; or syphilis of the lung might do the same thing, but

neither of these diseases can account for so large and forcible a heart, nor for two weeks of orthopnea, though either of them would explain the left axillary pain. The differences in the pulses and pupils and the small, hard epitrochlear gland furnish a certain amount of evidence confirmatory of the diagnosis of syphilis and, therefore, of aneurysm.

Outcome.—On September 1st the left chest was tapped, but no fluid obtained, the needle evidently entering the lung. Under rest in bed, with potassium iodid, 20 gr. after meals, and an occasional dose of morphin, the patient's pain practically disappeared and he had good nights. On the 7th he left the hospital.

Case 253

A housewife of thirty-seven entered the hospital January 9, 1912. The patient's family history was negative. She had a peritonsillar abscess seven years ago. Two years ago she was struck in the right breast and on the head in a street-car accident. After that she had nausea and fainting spells in the morning, at first three or four times a week, less frequently after that, but she still has them every month or two. In August, 1911, she became hoarse and this symptom has persisted ever since. Three months ago she caught cold, but both this and the hoarseness cleared up after a two weeks' vacation. Two and a half months ago the hoarseness returned, and she has had much treatment for her throat without relief. When asleep her breathing is noisy and often wakes her. She has no sore throat and no cough.

A month ago her breathing became labored on exertion, though she could still lie flat. A week ago she took to her bed from exhaustion. Three days ago she awoke at 3 o'clock in the morning with extreme dyspnea, which lasted several hours. Since that time she has never been free from dyspnea of some degree, and has had recurring attacks in which she had to fight for breath. These attacks come more frequently at night, and last from one-half to three hours. She has lost much sleep and much weight in the last week.

Physical examination showed good nutrition, marked expiratory dyspnea, and moderate inspiratory dyspnea. Pupils and reflexes negative. No enlarged glands, tongue clean. Wassermann reaction moderately positive. Larynx showed slight swelling of the glottis with reddening. On the inside of the larynx the tissues on both sides showed swelling, which ran up upon the two vocal cords. The cords were almost approximated, were motionless, and their edges showed ragged ulcers. On the 10th tracheotomy had to be done. The patient was given "606," mercury, and iodid of potash, but the mercury was

omitted after a few days because of stomatitis. The patient rapidly and steadily improved and by the 18th could speak aloud. On the 29th she got her second dose of "606," and on the 5th of February the tube was removed. The course of the temperature is shown in Fig. 216. The leukocytes at entrance were 14,500; on the 17th, 13,000; on the 24th, 10,000. The blood-pressure was 160 mm. Hg., systolic.

Discussion.—When hoarseness has lasted for six months, although with a slight intermission in the middle of that period, we may be sure that some serious organic disease is present. We have no evidence of a mediastinal pressure, and attention is, therefore, naturally concen-

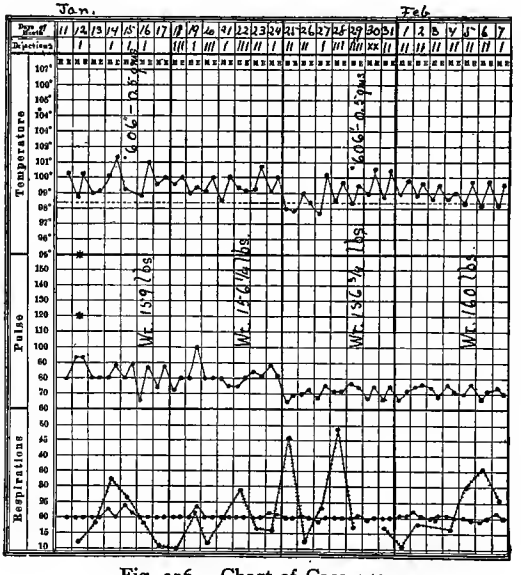

Fig. 216.—Chart of Case 253.

trated upon the local condition of the larynx itself. With a positive Wassermann reaction we may certainly expect that syphilitic changes will be found there, especially as acute suffocative attacks are particularly common in laryngeal syphilis. In this, as in one previous case, I am interested to note that the dyspnea was not of the inflammatory but of the mixed type, contrary to tradition.

The brilliant effects of salvarsan have seldom been more impressed upon me than in this case. A patient whose life was in serious danger was almost well in a week after its use.

Outcome.—February 6, 1912, she went home, apparently cured. In January, 1913, she reported herself as well, except for some dyspnea on exertion. No hoarseness.

CHAPTER XIV

PALLOR

As a rule, pallor is not due to anemia. Pale people are common; anemia is rare. The majority of cases of non-anemic pallor are due to living indoors, to continuous exposure to high temperatures, as in industry or in the tropics, or to congenital causes.

Tuberculous patients are usually pale, but seldom anemic. Even extreme and ghastly pallor in consumption may be accompanied by a normal blood.

What the Germans call the "cachexia of old age" is a state in which pallor as well as emaciation forms a part. It is reasonable to suppose that such pallor is due to changes in the cutaneous circulation. Presumably the same is true of the pallor resulting from exposure to heat or from living indoors.

Pallor of the lips is much more significant than pallor of the face, much more apt to mean anemia, yet even this site is by no means proof of anemia. Any one who is in the habit of basing his judgment upon the looks of the skin and mucous membrane has violent surprises awaiting him.

Edematous or myxedematous skin is usually pale, whether there is anemia behind it or not.

A yellow pallor is probably more common in pernicious anemia than in any other single disease, but it is especially the combination of such a tint with good nutrition that is properly suggestive of pernicious anemia. When accompanied by emaciation, precisely the same yellow tint results from secondary anemias, however produced. On the other hand, it must never be forgotten that pernicious anemia may cause no pallor at all.

Case 254

A housewife of fifty-one entered the hospital May 31, 1912. Her family history and past history are not of importance. The patient passed the menopause eleven years ago. For three years she has been troubled by gas in the stomach and slight discomfort when the organ is empty. She is always relieved by food. Her appetite and digestion seem to be good.

Except for this trouble she has called herself well until five months ago, when she began to notice pallor and loss of weight and strength. The hunger pain became worse, sharp and burning in character. The epigastrium was tender. The pain was aggravated by soda, relieved by food or by vomiting. The vomitus has never been bloody nor resembled coffee-grounds. She was in the Boston City Hospital from March 27th to April 18, 1912. She was fed on milk and lime-water and told that she had gastric ulcer. For several weeks previous to this time she was treated there as an out-patient. She was much relieved by this stay in the Boston City Hospital, and on discharge went back to work and resumed her ordinary diet, but continued to lose ground slowly, and for the last two weeks has been much worse, though she has kept at work. Last night she vomited many times, though she has not previously done so since leaving the Boston City Hospital. Her appetite is notably good; her bowels move three or four times a day. She has noticed slight swelling of her feet and under her eyes. She has no nocturia or jaundice. Any kind of food relieves the pain for a time, but it always returns, regardless of diet.

On physical examination, she is well nourished, does not look sick, except that her skin is very pale with a slightly yellowish tinge. Pupils, glands, and reflexes normal. Heart's impulse extends 2 cm. outside the nipple line, and is accompanied by a systolic murmur audible all over the precordia and transmitted to the axilla, but not replacing the first sound. Pulmonic second is accentuated. Blood-pressure, 115 mm. Hg., systolic; 60 mm. Hg., diastolic. Abdomen is negative. There is no edema. The urine is negative. Weight, 109½ pounds, without clothes. Stomach-tube examination shows small amount of food in the fasting stomach. After a test-meal HCl was absent. On the 5th of June slow rhythmic peristalsis, from left to right, corresponding in time to that of a normal stomach, was observed in the epigastrium. She complained of no pain and practically of no digestive disturbance. The guaiac test in the stools was positive June 4th, 6th, 7th, 13th, 18th, and 22d. The amount of blood in the feces seemed to be considerable. June 10th the left leg became swollen and tender, and a hard, cordy vein was felt in the region of the internal saphenous. On the 22d a hard, smooth lump, movable laterally and with respiration, not tender, was felt midway between the ensiform and the navel.

Up to the time of her discharge, July 8th, there was almost no change in her condition. The phlebitis subsided in the left leg and

was followed by a similar infection in the right. Loss of appetite and moderate distress after meals were not present after June 10th, when we began to give her a dilute hydrochloric acid, 10 drops after meals. The improvement was prompt and striking. On the other hand, the blood showed little improvement. Red cells at entrance, 2,500,000; July 5th they were still below 3,000,000, though the hemoglobin had risen from 40 per cent. June 7th to 50 per cent. July 5th. The leukocytes ranged from 6000 to 10,000. The differential count was normal. The stained smear showed always *very marked achromia*, great variations in size and shape, no stippling or nucleated red cells, a diminished number of blood-plates, and some macrocytosis. Bismuth *x*-ray of the stomach showed in all the plates a defect in the outline of greater curvature.

She re-entered September 4th, having been fairly comfortable and able to do her work since leaving in July. She has now a good appetite and has gained in weight and color. She has no pain, but constant eructations of gas and constant nausea. Diet makes no difference. When she lies on her right side she is troubled by a dragging sensation in the epigastrium. The past two weeks her wrists and some of the joints have been swollen and painful. The mass was made out as before in the abdomen.

She refused operation and left the hospital on the 7th of September, but entered for the third time, September 24th. This time the curved edge of a mass, firm, not fluctuant and not moving with respiration, was felt in the lower epigastric region, a little to the left of the median line. Last December she weighed 129 pounds. Between this and the following May she lost 21 pounds; since then she has held her weight.

Discussion.—Three years of stomach trouble of the type that is relieved by food, and accompanied by good appetite, strongly inclines us to make a snap diagnosis of peptic ulcer, gastric or duodenal. The present condition of good nutrition, despite some marked pallor, supports this idea.

On the other hand, the presence of stasis, achylia, and especially the visible peristalsis in the epigastrium, inclines us to interpret the lump which later appeared as cancer rather than as perigastric exudate surrounding an ulcer.

When the patient gained so markedly after leaving the hospital we were again in doubt, but the mass felt at the time of the second entrance was strongly like that produced by gastric cancer.

Pernicious anemia was at the time seriously considered, but this

was a blunder, for the very marked achromia should have prevented our wasting any time in the consideration of that disease.

Outcome.—On the 27th of September Dr. F. T. Lord thought the diagnosis to be carcinoma of the lesser curvature of the stomach, but thought there was a reasonable doubt in favor of gastric ulcer. Accordingly, on the 28th, Dr. Scudder opened the abdomen and found a hard mass, size of the fist, involving the greater curvature and anterior wall of the stomach. No metastases palpable. Nothing done. The patient recovered promptly from the operation and left the hospital on the 9th of October, 1912. She reported February 17, 1913, that she was losing ground steadily and could take only milk.

Case 255

A blacksmith of fifty-one entered the hospital October 8, 1907. For the past six months the patient has noticed pallor, dyspnea on exertion, gradual loss of weight and strength. He has lost 30 pounds in six months. For three months he has been unable to work. During the past two weeks he has had for the first time some vomiting spells, three in number, food only being rejected. There is some dull pain in the right hypochondrium, no jaundice, no cough or edema. His family history, previous history, and habits are excellent, except that he takes an excessive amount of tobacco. He denies venereal disease.

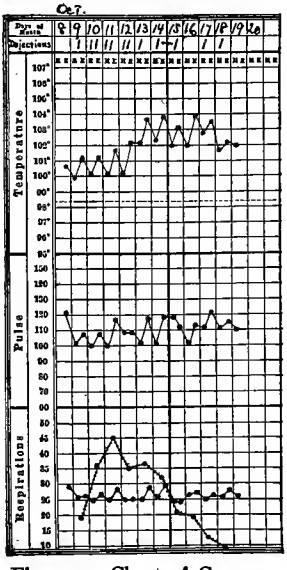

Fig. 217.—Chart of Case 255.

Physical examination shows poor nutrition, marked pallor. The heart's impulse is in the fourth interspace, $1\frac{1}{4}$ inch outside the left nipple, no enlargement to the right. Just inside the apex there is a rough presystolic murmur and thrill, ending in a short, sharp first sound; on the left border of the sternum a faint diastolic murmur; at that situation and at the apex a rough, loud systolic murmur. The pulse has a Corrigan quality. The lungs are normal save for a few crackles at the bases. Abdomen and extremities negative. Temperature as seen in Fig. 217. Urine negative. The blood shows red cells, 1,216,000; white cells, 7000; hemoglobin, 35 per cent. Stained specimen shows polynuclears, 58.5 per cent.; lymphocytes, 41.5 per

cent.; slight achromia and deformities, no abnormal staining, no blasts. Blood-plates diminished. Systolic blood-pressure, 128. On the 15th the blood showed red cells, 800,000; white, 12,900; polynuclears, 56 per cent.; lymphocytes, 44 per cent., many of them of the large type with azur granules. On the 17th the white cells were 29,000; polynuclears, 36 per cent.; large lymphocytes, 59 per cent.; small lymphocytes, 5 per cent.; 12 normoblasts and 3 megaloblasts were seen while counting 200 cells.

Discussion.—The history gives us no inkling of what the patient's pallor may be due to. His excess in tobacco has certainly no particular significance, and I may here confess that I have seldom if ever been convinced that excess in tobacco is in itself the cause of any serious symptom, whether cardiac, digestive, or nervous. Excess is as apt to be a *result* of nervous conditions as their *cause*. Doubtless it does some harm to some people, but I find it difficult to formulate any definite beliefs as to its injurious action on the majority of smokers, even of excessive smokers.

The present condition of the heart might be due either to syphilitic or to rheumatic disease of that organ. In the absence of any rheumatic history, syphilis is perhaps more probable, but, in view of the very grave anemia shown by the blood examination, it is our first business to determine, if possible, what can be inferred from the blood itself.

Could syphilis produce this condition? Very grave anemias have often been attributed to syphilis, doubtless rightly in some cases, but such anemias have been, so far as I know, invariably consequent upon long-standing, obvious, and virulent syphilitic lesions. We have nothing of the kind here. Moreover, we have a fever of a type not often seen in the later stages of syphilis when grave anemias may develop. A close study of the leukocytes leaves me entirely convinced that the patient suffered from an acute lymphoblastoma with lymphemia. The excess of white cells is not great, but I know of no disease other than that just mentioned which can produce such a differential count in connection with such a total leukocyte count. Moreover, the insidious development of anemia is especially characteristic of the lymphoblastomous lesions of this type. Pallor and the general symptoms of anemia are often the patient's first complaint. This means that the red cells and the red cell-forming tissue of the marrow have been crowded out by the overgrowth of marrow lymphocytes, and that the anemia is of the myelophthisic type.

Outcome.—The patient lost steadily in strength, and died on the 19th of October. No autopsy.

Case 256

A maid of twenty-three entered the hospital January 11, 1910. The patient's family history and past history are good, except that she had rheumatic fever at fourteen and a year ago "used to vomit blood." Her menstruation is not regular, a month or more being often omitted.

For two months she has been getting pale and weak. Two or three times a week she has severe headaches and is very nervous. For the last four days she has had a smothering sensation in her upper chest, and for two months has been short of breath on exertion. In all her attacks she has vomited but once and has had almost no pain. Appetite, bowels, and sleep are normal. She thinks she has lost a good deal of weight.

Physical examination shows good nutrition, pallor, and slight yellowness of the skin and mucous membranes. Chest negative, save for a slight systolic murmur, limited to the apex of the heart and the region of the left third costal cartilage. Abdomen and extremities negative. Two examinations of stools showed nothing abnormal. Red cells numbered 4,280,000 and continued near that point during her three weeks' stay in the hospital. Hemoglobin at entrance was 45 per cent.; it never rose above 50 per cent. during the period of observation. The leukocytes showed nothing abnormal. In the stained specimen there was marked achromia, slight variations in size and shape. No abnormal staining, no nucleated red cells. The patient had no fever and a negative urine during her three weeks' stay. She was given at first Blaud's pills, 10 gr., three times a day. Later, 15 minims of the green citrate of iron was given her subcutaneously every other day. She improved markedly in looks and feelings despite the absence of much change in the blood.

Discussion.—I have to drop out of account altogether, in the diagnosis of this case, the rheumatic fever and the statement that she "used to vomit blood." Both may be true, but I can make nothing of them and find no present results of them in the patient.

What we now see is that she has shown the general symptoms of anemia for two months, and has now a yellow pallor and a notably low hemoglobin. With a history of rheumatic fever one looks, of course, for evidence of endocarditis, for that infection often accompanies or causes anemia; but, with no fever and no more definite cardiac signs, I cannot believe that there is any active endocarditis in this case. Pretty much everybody has sooner or later a slight

systolic murmur like that here described. The more often one listens for it and the more carefully, the more frequently it appears upon our records. Its absence is surprising in careful bedside notes of any patient who is sick enough to call a doctor.

Insidious symptoms of this type in a girl of twenty-three always makes us look with special care for evidence of pulmonary tuberculosis. I cannot positively deny the possibility of tuberculosis in this case, but, despite painstaking search, no evidence of it could be found.

The remaining probability, chlorosis, has of late years become a rarity in our clinics, so that one hesitates much more than formerly to make such a diagnosis. Nevertheless, it will account for all the facts here presented and is the best working hypothesis in sight.

Outcome.—On the 30th of January, 1910, she left the hospital. May 1, 1913, she reported herself well and at work.

Case 257

A waist maker of forty, born in Russia, entered the hospital February 12, 1910. The patient was sent in from the Out-patient Department on account of excessive uterine flowing. Her father was killed in the Odessa massacre. Her family history is not otherwise remarkable. She has had no previous illness of note. Her menstruation has been regular, but always excessive. It has been no more so of late. Late in December, 1909, she got pale and lost her appetite; in consequence she ate very irregularly and meagerly. At this time she began to have pain in her chest and between her shoulders. For the past two weeks she has had palpitation. She stopped work five days ago on account of increasing weakness. Yesterday her menstruation began, a week ahead of time, accompanied by headache. She has constant pain in the middle and right side of her chest. In the last two years she has lost 17 pounds. Her bowels are regular and she sleeps well.

Physical examination showed good nutrition, marked pallor, normal pupils, glands, and reflexes. Chest was negative, save for a systolic murmur, heard best at the apex of the heart, but audible also over the whole precordia. Abdomen and extremities negative. Blood normal. Slight fever, ranging between 99° and 100° F. for the first three weeks of her stay in the hospital, after that usually below 99° F. There was no elevation of pulse or respiration. Menstruation ceased on the third day after her entrance to the hospital, but began again two weeks later and lasted four days. The blood examination showed the following: Red cells, 1,500,000, at which point they

remained with very little change during the five weeks of her stay in the hospital; hemoglobin, 50 per cent., gradually rising to 60 per cent.; white corpuscles, 7500, later rising to 10,000; polynuclear leukocytes, 72 per cent. at entrance, 80 per cent. five weeks later. The stained smear showed great variations in size and shape; no achromia. No stippling, marked abnormal staining. At the first examination no nucleated forms were seen; three weeks later, 4 normoblasts were found. Blood-plates, 280,000 at entrance; 490,000 five weeks later. The feces were negative to guaiac on three successive examinations. Pelvic examination showed no disease. The Wassermann examination was positive.

Discussion.—The chief impression made by the history is that we are dealing with a secondary anemia due to excessive uterine hemorrhage; yet it is almost unprecedented to meet with anemia of this degree in a patient who has had no very recent or colossal bleeding and who has been able to work until five days before her entrance.

Posthemorrhagic anemia disables a patient far more quickly and completely than the slowly developing primary or secondary type. In these the patient's system becomes accustomed to the bloodlessness. Some sort of compensation presumably takes place, and the patient gets along surprisingly well with half or a quarter, or even a fifth, of his normal quantity of red cells.

Since neither the history nor the general physical examination reveals any obvious cause for the anemia, we must scrutinize the blood-picture closely. Everything in it points toward pernicious anemia, and the presence of a positive Wassermann reaction should not, as it seems to me, weigh at all against this diagnosis. A person with syphilis is not thereby immune against the possibility of developing pernicious anemia, and surely patients with the latter disease may acquire syphilis. Grave anemias do occur as the result of syphilis, but not without more obvious lesions than have occurred in this case.

Outcome.—At the end of five weeks the patient showed considerable improvement in her blood and some in her general condition. She thought she would be as comfortable at home as in the hospital, and was accordingly discharged March 8th. The treatment throughout was Fowler's solution with tonics and laxatives.

Case 258

A painter of forty, born in Russia, entered the hospital November 23, 1910. For the past three months the patient has noticed pallor

and pain in the left flank, worse when he urinates. The twenty-four-hour amount is from 2 to 3 pints, reddish-brown in color, and contains a white sediment. Appetite, bowels, and sleep are normal. The patient has lost no weight and worked until entrance. His family history and past history are otherwise negative; habits excellent.

Physical examination showed fair nutrition, marked pallor. On the lower forearms, above the inner condyles, were two moderately tender, firm masses as large as walnuts. Pupils and reflexes were normal. The heart was negative save for a soft systolic murmur, replacing the first sound at the apex and audible all over the precordia. The aortic second sound was accentuated. The brachial

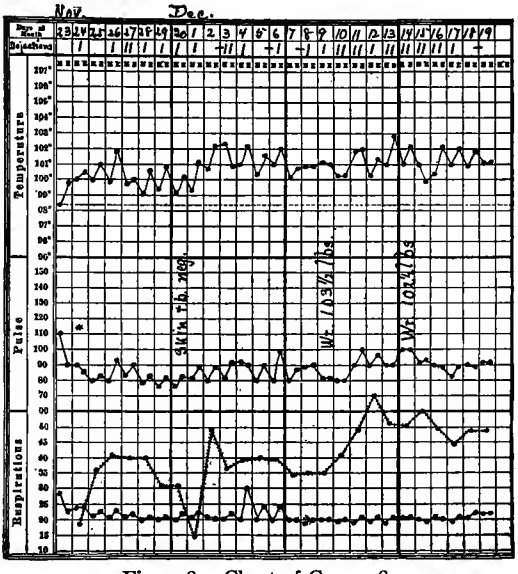

Fig. 218.—Chart of Case 258.

arteries pulsated visibly. The lungs showed, at the right apex behind, a few crackling râles and all the signs of slight solidification.

The patient entered the hospital with a diagnosis of "nephritis," but examination of the urine showed an average of 40 ounces in twenty-four hours, specific gravity 1015, no albumin, and no casts. On the 25th of November a sterile specimen showed a sediment consisting of pus in small clumps. This state of things continued thereafter, and the amount of sediment varied from 2 to 5 per cent. of pure pus. This was repeatedly stained for tubercle bacilli, with negative results. Four similar examinations of the sputum were also negative. The blood showed 3,600,000 red cells, and this anemia stayed without

much change during the four weeks of his stay in the medical wards. The white cells varied from 9000 to 13,000; hemoglobin, 60 to 70 per cent. The stained smear showed moderate polynuclear leukocytosis and slight achromia. The course of the temperature is seen in Fig. 218. Blood-pressure, 115 mm. Hg., systolic.

Cystoscopy, December 4th, showed a normal bladder, but, about the left ureteral orifice, marked ulceration. Practically no urine came from this ureter, but only thin pus. From the right ureter normal urine was obtained. Dr. Hugh Cabot stated that in his opinion the left kidney was largely destroyed, probably by tuberculosis. The right kidney competent.

November 28th 20 minims of the urinary sediment were injected into a guinea-pig. January 14th the pig was killed. Autopsy showed tuberculous lesions of the glands, spleen, and liver. Cultures from the urine always showed streptococci, but nothing else. Two negative *x*-rays were taken. The skin tuberculin test was negative.

Discussion.—The history points toward some disease in or near the kidney. The physical examination, with its evidence of pyuria, fever, and anemia, supports this conjecture and the cystoscopy confirms it. The only remaining question is as to the etiology of the renal suppuration. The signs at the apex of the right lung naturally lead us to assume tuberculosis, both there and in the kidney. The negative examination of the urinary sediment and of the sputa for tubercle bacilli incline us against tuberculosis, but do not rule it out. Our only decisive test in a case of this sort is animal inoculation. The anemia, of course, is secondary to renal infection, whatever its bacteriologic cause.

Outcome.—On the 20th of December incision was made over the left kidney, which was found everywhere adherent, as if plastered into its bed, and surrounded by a markedly thickened inflammatory capsule. At the lower pole an abscess outside the kidney was broken into and about 4 ounces of very foul-smelling pus evacuated. The kidney was removed; the ureter found greatly thickened, as large as the forefinger. It was removed, together with the kidney, microscopic examination of which showed that its substance was largely replaced by fibrous tissue, its pelvis and calyces dilated and full of pus. The patient did not rally well after the operation, and died on the 22d of December. Autopsy showed an evacuated subdiaphragmatic abscess in the retroperitoneal tissues about the kidney, with gangrene of these tissues extending up to the diaphragm, posteriorly;

abscess of the spleen, thrombosis of the left external iliac and femoral veins; obsolete tuberculosis at the apices of both lungs and in the bronchial lymphatic glands.

Case 259

A housekeeper of forty-four entered the hospital February 23, 1911. The patient's father died of cancer of the stomach at fifty-five; mother, of some chronic stomach and intestinal trouble at fifty-seven. One brother has nervous dyspepsia, one sister has the same trouble, and another sister has had stomach trouble for four years, but has recently recovered.

The patient's general health has always been poor. For years, she says, she has been as pale as she now is. At twenty-nine she had a nervous breakdown, with general tremor, weakness, and inability to use her eyes. She did nothing for six years, during which time she was several times in hospitals for operations on eye muscles, for curettage, and other troubles. Twelve years ago the right ovary was removed. Most of the time since she has been working as a governess and housekeeper, with only one breakdown, although she has had constant trouble with sour stomach, gaseous eructations, epigastric tenderness, and constipation. Her menstruation began at fourteen and was regular until June, 1910, since when she has had but one period, six weeks ago.

A year ago she began to be troubled by sore tongue, and at intervals it has been sore ever since. In September, 1910, she began to have what she calls "bilious attacks," *i. e.*, nausea and vomiting at irregular intervals, without relation to meals, associated with anorexia and constipation, but without pain or jaundice. For the past week she has vomited once or twice a day. Since January, 1911, she has noticed dyspnea on exertion, associated with some pain in the chest. She sleeps well with one pillow and has lost no weight. She knows of no fever.

Physical examination showed marked sallow pallor. Pupils, glands, and reflexes normal. Mouth and throat negative. Heart sounds somewhat irregular, distant, and of poor quality. Soft, blowing, systolic murmur, audible all over the precordia and in the left axilla, loudest at the apex. No evidence of cardiac enlargement, no accentuation of any sound. Lungs and abdomen negative, except that the liver dulness extended 3 cm. below the ribs, where the edge of the organ was doubtfully felt. There was intermittent coarse tremor of both hands, especially the right. The urine averaged 45

ounces in twenty-four hours; specific gravity, 1004 to 1010; albumin sometimes absent, sometimes present, slightest possible trace. Sediment negative. Five examinations of the stools were negative. Examination of the fundi showed patches of exudate and small hemorrhages in the left retina.

The condition of the blood is shown in Fig. 219. The red cells were mostly of the large type and well stained, though a few of them

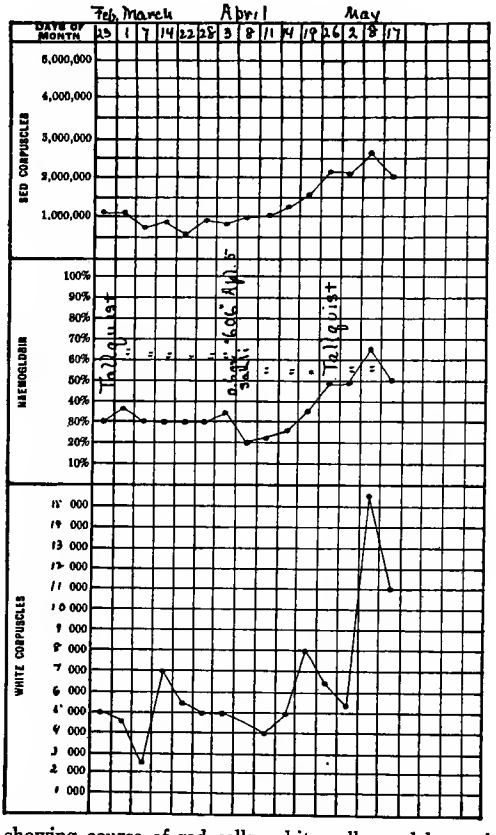

Fig. 219.—Chart showing course of red cells, white cells, and hemoglobin in Case 259.

were very achromic. Occasionally very large purplish or stippled cells were seen. Blood-plates seemed to be very much diminished and there was much deformity in the shape of the red cells. At entrance no nucleated forms were seen. On March 7th a few normoblasts appeared; on the 14th, 2 megaloblasts were seen while counting 200 white cells; on the 22d, 2 normoblasts and 2 megaloblasts; on March 28th, 2 megaloblasts only. On the 3d and 8th of April normo-

blasts became very abundant, 30, and 18 megaloblasts. After that the nucleated cells became rare and at times could not be found at all. The leukocytes at entrance numbered 5000, sagged in two weeks to 2500, then gradually rose with the increasing red cells to 15,000; the polynuclear varieties meantime rising from 60 to 83 per cent. Throughout the whole course the blood-plates were diminished.

April 5th 0.6 gm. of salvarsan was injected deep in the left gluteal region, and the improvement in the patient's blood dated from this time. Up to the 27th of April she seemed to be decidedly improving, though there was at times a little edema of the face. On the 5th of May she complained of headache and had slight coryza. This steadily increased, and at midnight on the 6th she became unconscious. Soon after she had a generalized clonic convulsion and bit her tongue. The radial pulse showed alternation. The face seemed more edematous than before. There were many crackling râles at the base of the right lung; otherwise physical examination was negative. On the 9th Dr. Brewster removed the area of fat and muscle about the site where "606" had been injected. The specimen examined microscopically showed necrosis of fat and muscle and a small amount of arsenic was detected on chemical examination.

Throughout the three months of her stay in the hospital she maintained her weight, but had most of the time a slight temperature in the evening, the highest point reached varying between 99.5° and 100.5° F.

Discussion.—This patient seems to be predisposed by inheritance to stomach trouble and possibly to cancer. She has also suffered many things from many physicians, as nervous sufferers are unfortunately so apt to do. The operations upon her eyes and her pelvic organs are of the type so often done, especially in the last decade, because of the utterly false surgical dogma that all nervous symptoms must have "a cause," by which they mean a cause open to surgical treatment.

The history of sore tongue accompanying a marked anemia makes it incumbent upon us to look with special care for evidence of pernicious anemia, since many cases of that disease begin each one of the successive waves of illness with a sore mouth. Such a suspicion is here strengthened by the finding of retinal hemorrhages, hepatic enlargement, and a high color index. Further study of the blood leaves no considerable doubt of the diagnosis.

A few words may here be said regarding the salvarsan treatment for pernicious anemia. Certainly a single dose is often devoid of any

good effect whatever. On the other hand, the recent cases reported from Dr. Mumford's clinic at Clifton Springs by Dr. Brotherhood arouse the hope that by giving small and repeated doses of salvarsan we may produce at any rate a longer and prompter remission of the symptoms than can be expected from the activities of nature unaided, or from the ordinary methods of treatment. That salvarsan can cure the disease I do not for a moment believe. It is a palliative, not an etiologic, treatment, for, although there are certain scraps of evidence pointing toward an infectious etiology for pernicious anemia,[1] these hints are by no means conclusive. What other infectious disease begins so regularly at the arteriosclerotic age?

Outcome.—On the 15th of May the clinical note is "still doing well," but on the 18th she died, rather suddenly. Autopsy No. 2854, May 19th, showed arteriosclerotic nephritis with foci of suppuration; hyperplasia of the bone-marrow; slight hypertrophy of the heart; streptococcic septicemia; chronic pleuritis; general anemia.

Remarks.—The fact that the kidneys were markedly diseased would lead some incautious observers to believe that this case supports the theory often advanced on similar equivocal evidence that nephritis can cause pernicious anemia. When two diseases occur so frequently without any known connection with one another, one needs a good deal more than the fact of their simultaneous occurrence within a single body to constitute evidence of an etiologic connection. Whether arsenic-poisoning played any part in this patient's demise I cannot definitely state. I see no good reason to believe so, though it is possible that the end may have been hurried by the unfortunate accident resulting from the way in which salvarsan was at that period not infrequently given.

Case 260

A schoolgirl of eight years entered the hospital March 13, 1911. The little girl's mother has had ten other children and four miscarriages. Eight children are living and well. The patient herself has had measles and whooping-cough, and when four years old was treated in the Neurologic Department and at the City Hospital for multiple joint pains, with tenderness, but no swelling. A diagnosis of multiple neuritis was made. She was in bed three weeks and could not walk for five weeks from the onset.

After that she was in vigorous health until December 10, 1910,

[1] Herbert C. Moffitt, Transactions of the Association of American Physicians, 1911, p. 288.

when she had a sore throat and an attack of pain in many joints, though without swelling. She was in bed a week, but has never been really well since. For an hour on the 15th of December she was said to have been temporarily blind, and for several months past she had now been troubled with frontal headache. Nevertheless, until four days ago the parents considered her fairly well.

Four days ago her mother noticed *pallor* and puffiness of the face. The child had a good appetite, but vomited most of her food soon after eating.

Physical examination showed marked pallor and edema of the face and extremities. Pupils, glands, and reflexes negative. The chest showed a slight rachitic rosary. The cardiac dulness reached 2 cm. to the right of midsternum and 7 cm. to the left of the nipple line. There were no murmurs or accentuations. In the lungs abundant bubbling râles were heard throughout both chests. There was soft edema of the extremities; otherwise physical examination was negative. Blood-pressure, 125 to 135 mm. Hg., systolic. Stained smear showed moderate achromia; hemoglobin, 80 per cent.; white cells, 14,000 to 16,000. The urine averaged 35 ounces in twenty-four hours, with a slight trace of albumin; specific gravity usually in the vicinity of 1010, occasionally rising to 1020. Granular, cellular, and bloody casts, with some pus, were present throughout most of her stay, though after the 1st of April the amount of blood rapidly diminished and soon disappeared. There was no fever during the five weeks of her stay in the hospital Under daily hot tub baths of fifteen minutes, at temperature of 100° F., gradually raised to 112° F., followed by wrapping in warm blankets, the child steadily improved. She was given a diet from which meat was omitted and salt limited. The bowels were moved by 2 drams of sodium sulphate every morning. The edema was gone by the 1st of April and the baths were then omitted.

Discussion.—Can this patient have had a multiple neuritis at the age of four? I never heard of any such diagnosis or read of any such cause. Does it not seem more probable that she had a rheumatic infection, similar to that which occurred in 1910? I am inclined to believe so. Blindness and frontal headache, following immediately upon an attack of tonsillitis and arthritis, make us confident that the urine will show clear evidence of nephritis, especially when pallor and puffiness of the face ensue. A systolic blood-pressure of 135 mm. Hg. constitute hypertension in a girl of eight years and further supports the diagnosis of nephritis.

The case is of interest as an example of posttonsillar or streptococcic nephritis. In my opinion, there is no other cause for acute nephritis so common as this. It is impossible to say that many cases of the so-called scarlatinalnephritis are not, in fact, streptococcic in origin. Those following tonsillitis are not so often discovered, because we have not yet become accustomed to expect nephritis as a complication of that disease.

Outcome.—By the 9th she seemed nearly well, and on the 15th was discharged. In April, 1913, she reported herself entirely well. The urine was not obtained.

Case 261

A farmer of sixty-two entered the hospital March 24, 1911. The patient has had stomach trouble for the past fifteen years, but it has never prevented his working. He has epigastric pain beneath the left costal margin occurring with great definiteness, two and a half hours after meals, especially after breakfast and lunch. He says the pain is like hungry kittens. It is immediately relieved by food, and for years he has carried crackers or doughnuts in his pocket to take when the pain comes. He also gets relief from pressure, and often throws himself across a bag of wool or bale of hay for comfort.

This condition has shown no marked change until five weeks ago. There have often been remissions, lasting several weeks or months. Five weeks ago he noticed that he was getting pale, and shortly after had an attack of diarrhea and vomiting, lasting three days. Since then he has felt weak, though he has been up and about the house. Two weeks ago he rose from a chair to get a drink of water and fell, without losing consciousness. There was no vertigo, and he got up without assistance. A week ago he had a similar experience. He thinks he may have lost weight. He is quite sure he has lost strength, though he feels able and willing to work to-day. His family history and habits are good. He denies venereal disease. His bowels moved daily until within a few weeks. He has always led the vigorous, out-of-door life of a farmer.

Physical examination showed marked pallor, good nutrition; pupils slightly irregular, otherwise normal. Glands and reflexes negative. Chest and abdomen negative. The course of the temperature is shown in Fig. 220. Urine was negative. The patient weighed 142 pounds, without clothes. The stools, examined six times, showed a marked reaction to guaiac, but no other abnormality. The blood showed red cells, 1,800,000; white cells, 14,000; hemoglobin,

35 per cent. There was no marked change from these figures in four examinations, at weekly intervals. The stained specimen showed almost no achromia, slight deformities, the red cells often oversized, and many of them off-color, even blue. There was a marked polynuclear leukocytosis. Altogether, an equivocal blood, but, when taken in connection with the history, probably due to secondary anemia. In the fasting stomach 70 c.c. of turbid, coffee-colored fluid was found, reacting strongly to guaiac. No further examination was made.

The first four days after his entrance to the hospital he had a persistent hiccup, which was checked, however, by a small dose of

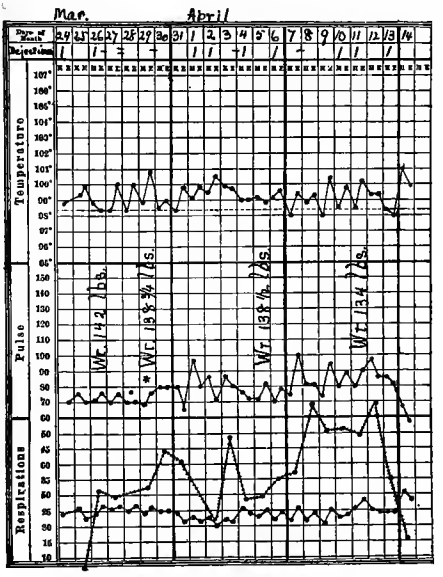

Fig. 220.—Chart of Case 261.

morphin and did not recur. Most of the time the patient lay in a semicomatose condition, occasionally irrational, but able to answer questions. An attempt was made to secure a donor of blood for transfusion, but unsuccessfully. April 11th and 13th he complained in the night of pain in the chest, but during most of the time lay as if asleep. The fundus oculi was normal.

Discussion.—The only organic disease of the stomach that lasts fifteen years is peptic ulcer and its results. If this patient has had but one trouble throughout the whole of his illness, it is inevitable for us to call it ulcer. His recent pallor and weakness are then explainable

as the result of hemorrhage, which may have passed out through the bowel without his knowing anything about it. Some features of the blood examination parallel those of pernicious anemia, but the well-marked polynuclear leukocytosis, taken in connection with the typical gastric history, should leave us no doubt that the anemia is, in reality, of the secondary type.

The latter symptoms in this case present an excellent type of those which are usually explained by saying that a peptic ulcer has become cancerous. Like many better men, I was misled into making such a diagnosis in this case.

Outcome.—On the 15th of April he died. Autopsy showed a perforated ulcer of the stomach with localized peritonitis. Cancer had been considered the most likely diagnosis before death.

Case 262

A housekeeper of thirty-six entered the hospital January 1, 1912. The patient's father died of Bright's disease; in other respects her family history is excellent. She has never been sick before, but for the past three months has had a great deal of flowing at irregular intervals. Three years ago, when walking home one cold evening, she left her coat unbuttoned and thinks she caught cold. For two weeks after this she had very frequent and painful micturition, which, however, got well without any further complications. Soon after this, without any known cause, she rapidly lost strength and became very pale. A vacation in Baltimore benefited her a good deal, and she went back to work on her return. She has worked for a greater part of the time since then up to last Thanksgiving, six weeks ago, though she has remained pale all this time and has never felt very strong. Since Thanksgiving she has been in bed, though she complains of nothing whatever except weakness. It is hard work for her now even to think. She absolutely denies any shortness of breath, any edema, vomiting, headache, or diarrhea. She has an occasional slight hacking cough, without sputum. She has had no fever, chills, or sweats, no fainting or vertigo, and no pain in any part of the body. Her weight, she believes, has remained about the same.

Physical examination shows fair nutrition and considerable pallor. No jaundice. The pupils are small, slightly irregular in shape, react normally to light and well to distance. Knee-jerks are present and equal. All the other reflexes are normal. There are many small, firm, non-tender, discrete glands in the neck, axillæ, and groins. The tongue shows a thick, brown coat. The mouth and throat are nega-

tive. The heart's apex is seen and felt in the fifth interspace, 7 cm. outside the nipple. Its dulness extends 4 cm. beyond the midsternal line. At the apex is a harsh, long, systolic murmur, transmitted to the axilla. The pulmonic second sound is moderately accentuated. The lungs are negative. The liver dulness extends $7\frac{1}{2}$ cm. below the ribs and as high as the fifth interspace in the nipple line. A rounded, slightly tender edge is felt. The spleen is enlarged by percussion and its edge is felt just above the level of the navel. It is not tender. The extremities are negative. Systolic blood-pressure, 140. The urine 20 to 40 ounces in twenty-four hours, 1012 to 1019 in specific gravity, slight trace of albumin, rare granular and hyaline casts with cells adherent. The blood shows red cells 2,600,000; white, 21,000 to 23,000; hemoglobin, 65 per cent.; polynuclear cells, 75 per cent. Stained smear shows slight variations in size and shape, but no achromia or abnormal staining; 1 normoblast. The Wassermann reaction is negative.

The patient's family physician later told us that on examination three weeks ago he found a large dilated heart with a mitral murmur and a weak, rapid pulse. Under digitalis and rest she improved very much. After her return from Baltimore, although she worked as a milliner, she was treated twice for attacks of broken compensation. Her physician also states that since Thanksgiving she has had several chills followed by fever, and has complained of pain along the lines of the ureters.

On the 2d of January a diastolic murmur was heard in the second right interspace and along the right sternal margin. Corrigan pulse, capillary pulse, and other vascular phenomena therewith associated were detected at the same time. The same afternoon she had a chill, followed by a sharp rise in temperature; the next day another chill, with slight spasm and moderate tenderness in the region of the spleen; also crops of petechiæ on each arm. Blood-culture gave a Gram-positive diplococcus, interpreted as a contamination. The patient's condition was very poor. On the 4th crops of petechiæ spread over the entire body. The heart became very rapid, and there were several attacks of marked cyanosis and pectoral oppression, lasting ten to twenty minutes.

Discussion.—So much weakness, unexplained and associated with extreme pallor, cannot but alarm us with its likeness to the onset of many a case of pernicious anemia, but the condition of the blood reassures us.

The heart lesions lead us to look in that direction for an explana-

tion of the patient's anemia and other symptoms. Here we have a "causeless" cardiac weakness, with marked enlargement and normal blood-pressure. We have also an enlargement of the spleen and liver. Cardiac disease does not enlarge the spleen, hence we must look elsewhere for an explanation. The general glandular enlargement prepares our mind for the appearance, late in the case, of a diastolic murmur which points very directly to syphilis, and gives us a diagnosis which can explain the "causeless" cardiac weakness and the splenic tumor, as well as the anemia.

On the other hand, the crops of purpuric spots which marked the latter days of the patient's life are such as one most often sees in connection with the rheumatic or streptococcic type of heart disease. Except for this, however, everything points in the other direction, that is, everything except the negative Wassermann, which cannot be ignored, but which need not upset the diagnosis otherwise well supported.

Outcome.—On the 5th of January the patient died. Autopsy showed syphilitic aortitis; aneurysm of the celiac axis; fibrous degeneration of the aortic valve and a slight degree of the same condition of the mitral valve; hypertrophy and dilatation of the heart; acute glomerulonephritis; slight chronic perihepatitis and perisplenitis; chronic salpingitis; chronic tuberculous pleuritis. No evidence of emboli.

Remarks.—I was wholly unprepared to find the acute glomerulonephritis shown at autopsy. Possibly it may have been due to a terminal infection which no one could predict. Certainly the urinary examination made at the time of the patient's entrance would not warrant any such diagnosis, though the conditions found were not those of health.

The frequency of chronic perihepatitis and perisplenitis at autopsy in cases of syphilis tempts one to regard such lesions as of syphilitic origin, even in cases where the latter disease is by no means clearly shown.

Case 263

The patient was a Finlander, thirty years old, and has worked in a stone quarry. He entered the hospital June 19, 1912, complaining that for a month he has been getting yellow. He has worked until nine days ago, though for two months he has noticed that his legs are somewhat weak. His family history, past history, and habits are excellent. Since he stopped work he has noticed vertigo, headache,

and tinnitus, with slight shortness of breath. As he lies in bed he feels perfectly well, has a good appetite, and no pain. He has lost a few pounds in weight, but thinks he is now regaining them.

Physical examination shows good nutrition and marked yellowish pallor, normal pupils, glands, and reflexes. The chest is negative, save for a few moist râles heard below the angle of the left scapula and at the bottom of the left axilla, not associated with any other physical signs of disease. The abdomen and extremities are negative. Urine negative. Systolic blood-pressure, 115. The temperature occasionally rose to 99.5° F. in the afternoon during the first week of his stay; after that normal or subnormal. The blood showed red cells 1,000,000; white cells, 6000; hemoglobin, 40 per cent. The stained smear showed no achromia, many large, deeply staining red cells. Marked variations in size and shape and many abnormally stained cells, but no stippling. Blood-plates decreased. Three normoblasts and 4 megaloblasts were seen while counting 200 white cells.

Discussion.—Pernicious anemia was the house officer's diagnosis in this case, and there was certainly much to justify it, for the blood was absolutely typical and the ordinary physical examination showed no cause for the anemia. But the patient's youth should lead one to scrutinize such a diagnosis carefully and to look for every other possible explanation. Certainly not more than once in a hundred times does true pernicious anemia occur in a man of this age. In a young woman it is not so rare.

Still more significant, however, is the patient's nationality, for we know that of all places in the world Finland is the one most notoriously associated with fish tapeworm anemia, whose striking resemblance to pernicious anemia was first made clear by Schaumann's classical monograph.[1]

This is one of the very few cases in which I have been able to believe that I have saved a patient's life. Had not the eggs of fish tapeworm been looked for under my direction, and the appropriate treatment for the expulsion of the worm given, this patient might have been allowed to die with the diagnosis of pernicious anemia.

Outcome.—The patient's youth and his race at once suggested the possibility of a fish tapeworm as the cause of his anemia. Examination of the stools showed the eggs of that tapeworm. The patient was accordingly given a milk diet for twenty-four hours with very free purgation; after that pelletierin tannate, 1 gr., together

[1] Berlin, 1904, Hirschwald.

with oleoresin of aspidium, 15 gr. in capsule, one every two minutes for eight doses. The next day the patient passed practically the whole of a full-grown fish tapeworm. The head was not found. During the ten days following the expulsion of the tapeworm his hemoglobin rose 10 per cent. and his blood improved proportionately in other respects. Thereafter he rapidly improved, and went home on the 1st of July to finish his convalescence.

CHAPTER XV

SWELLING OF THE ARM

THE symptom is rare, if we except the cases whose diagnosis is obvious. Swelling of an arm as the result of septic processes in the hand or higher up is, of course, not uncommon, but needs no discussion or comment. It is the cases without any such obvious explanation that I have called rare. They occur, now and then, in the course of cardiac disease, apparently because the dropsical patient has lain persistently upon one side so that the edematous fluid has settled there by gravitation.

Aside from this, a *phlebitis* may occur in the course of heart disease as well as in other conditions, but in the arm a phlebitis often presents no obvious tender cord, such as we can palpate on the inside of a leg similarly affected. Hence, the diagnosis of phlebitis in the arm has often to be made wholly by exclusion of other causes for the swelling that we find. One settles down upon that diagnosis in cases when they find no evidence of cervical or mediastinal pressure (*cervical rib*, glandular swellings, malignant disease, *aneurysm*).

Among the *mediastinal tumors* which cause an arm to swell, lymphoblastoma (Hodgkin's disease) is by far the most common.

Cancerous metastases in the axillary glands after tumor of the breast usually leave us in no doubt of the cause of the resulting edema in the arm. On the other hand, *axillary abscess* may obstruct the venous circulation and produce a swollen arm without giving us any clear evidence of its presence, for such an abscess often arises very deep in the tissues. The presence of slight unexplained fever and leukocytosis in connection with what is supposed to be a glandular tumor of the axilla gives us ground for suspecting an abscess behind it.

Case 264

A housewife of thirty-eight entered the hospital July 15, 1906. For the past three years she has had dyspnea and palpitation on exertion, with swelling of the feet at times. For eight months she has been in bed a good deal of the time with partial orthopnea. Nocturia, 2. She has had headaches all her life, but less of late. Appetite and bowels normal.

Four days ago the right arm swelled and the edema disappeared from other parts of the body. The whole arm was at first much enlarged and purple in color. It is now slightly smaller.

Physical examination shows fair nutrition, nervous, quick, and tremulous movements, prominent eyeballs, no goiter. The heart's impulse extends to the anterior axillary line, in the fifth and sixth spaces. Its action is rapid and irregular. The sounds are faint but clear. The aortic second is accentuated. No murmur. The lungs show coarse crackles at the bases, otherwise normal. There is dulness in the flanks, not shifting with change of position. Abdomen otherwise negative. The right knee-jerk not obtained, the other normal. The right arm is greatly swollen throughout and pits on pressure. The right leg is also very edematous, and there is considerable edema of the right side of the trunk, front and back. There is also slight edema of the left side of the body, especially the left leg. The white cells number 33,200; hemoglobin, 95 per cent. The temperature is as seen in Fig. 221. The urine is negative save for a slight trace of albumin. Under poulticing, purgatives, digitalis, and rest the edema rapidly diminished. The day after entrance an apex systolic murmur appeared, and the first sound was noticed to be sharp and short.

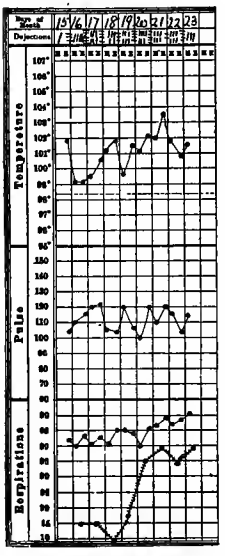

Fig. 221.—Chart of Case 264.

Discussion.—A history of three years' dyspnea on exertion and eight months' orthopnea makes us naturally prone to believe that a swollen right arm like that here described is connected with heart disease. The heart lesion from which this patient suffers seems to me most like mitral stenosis. In favor of this we have the marked lateral enlargement of the heart, its rapid, irregular action, and the sharp, short first sound at the apex. Even without a rheumatic history, a presystolic murmur, or an accentuated pulmonic second sound, such physical signs make mitral stenosis the best diagnosis in sight, especially as there are some points in the case suggesting a left-sided hemiplegia, for the combination of valvular heart disease with hemiplegia occurs most often in mitral stenosis. On this hypothesis, the leukocytosis will be explained as the result of one of those recrudescences of fresh infections to which the heart of mitral stenosis is strikingly subject.

Swollen Arm


CELLULITIS
218
CANCER OF THE BREAST
72
LYMPHANGITIS
39
THROMBOSIS AND PHLEBITIS
26
MEDIASTINAL NEOPLASM
4

That no arterial embolism of the arm has taken place seems clear from the course of the case. The obstruction, if there be any, seems to be in the venous trunks. Since no mediastinal pressure has made itself manifest, a phlebitis of the arm confronts is; on the whole, our best explanation of the fact.

Outcome.—On the 21st the white cells were 36,500. The arm was nearly normal in size and the tenderness was very slight. The general edema persisted after the arm had cleared up.

Case 265

A master mariner of thirty-eight entered the hospital May 1, 1900. About three years before entrance the patient noticed a lump on the outer side of the right arm near the shoulder. After a few weeks it began to discharge pus and two or three months later healed up. A year ago the discharge again appeared, and the bunch was operated upon by Dr. Maurice H. Richardson. The wound healed very quickly this time, but had to be opened again in three weeks and has never completely healed since that time. The last operation was three months ago. Just before it two lumps appeared upon the left leg, one on the outer side of it, above the knee, and one in the popliteal space. These lumps were opened, but the latter has never healed and is very tender.

Physical examination showed fine development and nutrition. There was a small discharging sinus in the region of the right deltoid, at the bottom of which, 2 inches from the surface, no sequestrum could be discovered. The function of the arm was apparently excellent. The left leg was considerably swollen. The patient says that at times it has been 3 inches larger in circumference than the other, just above the knee. There was a small scar on the outer side of the leg, just above the knee, where the patient says the bunch was opened, and several old white circular scars about the knee and on the lower leg. There was marked edema below the knee, and on the inner side of it a brawny tender swelling connecting with the popliteal space, where a shallow, unhealthy looking ulcer, very sensitive to touch, was discovered. The motion of the knee was good.

The leg was raised on pillows and the swelling gradually declined. No operation was done either on the leg or on the arm. The patient left the hospital on the 18th of May and re-entered October 26, 1911, stating that he had been operated upon in this hospital thirteen years ago, but had been well and strong, with no discomfort, up to the time of the present illness, two weeks ago, when he began to have

pain in the outside of the upper right arm, near the seat of the old operation. It all came in one night and now causes much discomfort. Three days ago the whole arm became much swollen and tender and the patient took to bed.

Physical examination shows in the upper part of the right humerus a dense tumor, red and very tender, the size of half an orange; otherwise the examination was negative.

Discussion.—Everything here points toward a local rather than a circulatory or mediastinal cause for the edema. In all probability the lump and purulent discharge of three years ago was due to an osteomyelitis of the humerus. The relapse and discouraging course of the lesion is characteristic of osteomyelitis. The edema which occurred in the leg at the same time was doubtless connected with the scar formation and the ulcer in the popliteal space.

When eleven years later we have a swelling of the arm and a local tumor over the humerus, we have every reason to connect the two facts with the old history. Surely we must be dealing with an osteomyelitis and a septic edema of the arm.

Outcome.—The tumor was opened and 4 ounces of pus evacuated. The cavity was found to lead to the bone, which was cureted. Four days later the patient was discharged to the Out-patient Department. The pus contained numerous colonies of streptococci and staphylococci.

Case 266

A candy maker of fifty-five entered the hospital January 31, 1911. The patient's father died of gastric cancer at seventy-two. His wife now has consumption, otherwise family history is good. General health excellent. He had typhoid fever twenty years ago. Denies venereal disease. Eight weeks ago his left wrist swelled. This continued for about forty days. Then he gave up work and the symptoms disappeared. Three days ago his wrist again became swollen, and later in the same day the entire arm became blue and considerably enlarged, with itching at the shoulder. He has no fever symptoms and feels well in all respects.

The patient did not look sick and was well nourished. In the left front there were soft, high-pitched, interrupted squeaks and twittering sounds, otherwise the chest was negative; likewise the abdomen. The left arm and adjacent pectoral region were moderately swollen and the veins over the shoulder dilated. *X*-ray showed nothing abnormal. Wassermann reaction negative. Blood and urine negative. Systolic blood-pressure, 135. No fever in four days' observation. He felt so

well that at the end of this period he left the hospital, though his arm was as much swollen as at entrance.

Discussion.—There has been no great pain and no local lesion suggesting sepsis. The general condition is excellent. Careful search for mediastinal growths and sources of local sepsis is negative. Nothing is left but phlebitis, and, although we have no idea why this should occur, we need not expect to have any such idea, for many cases of phlebitis decline to furnish us with any explanation of their cause. It may be that some deeper-lying malady may show itself in the later course of the disease, but at the present time we have no reason to suspect such nor to connect the patient's symptoms with his old typhoid fever. The pulmonary signs would make it seem that the lung, as well as the arm, is congested, and point to a deep-seated cause such as we have been searching for unsuccessfully in the mediastinum. Until these lung signs clear up there must be some anxiety regarding a mediastinal growth or aneurysm.

Outcome.—On February 11, 1911, the left upper arm was still 2 inches larger in circumference than the right, the forearm 1 inch larger than the right. March 23, 1911, he felt perfectly well. The arm was unchanged.

Case 267

A housewife of fifty entered the hospital June 23, 1911. The patient's father died of heart trouble at sixty-nine. Her mother is now living, but has heart trouble, otherwise the family history is good. The patient has never had rheumatic fever and for thirty years has had no tonsillitis. Thirteen years ago, after the delivery of her second child, she was told by Dr. Edward Reynolds that she had heart trouble, but suffered only occasional dyspnea on exertion until three years ago, when the dyspnea became more marked and she began to have precordial pain on exertion or emotional strain. She was told at that time that her heart was very irregular, and she remembers swelling of the ankles at night for at least three years.

Four weeks ago she noticed swelling of the left forearm, which began suddenly without other symptoms. This was coincident with the stopping of medicine for her heart, which she had been taking for three years. On account of the arm she consulted Dr. Maurice H. Richardson, who advised *x*-ray and sent her to a medical man. Her best weight, twenty years ago, was 192 pounds. Her usual weight now is 180 pounds. For three years she has been losing weight, and now weighs 143 pounds, without clothes.

Physical examination showed on the hard palate a ridge 5 cm. long, $1\frac{1}{2}$ cm. wide, and $\frac{3}{4}$ cm. high in the median line, apparently bony. She says her father had the same thing. Heart's apex was in the sixth space, anterior axillary line, where a systolic and presystolic murmur could be heard. At the base there was a high-pitched systolic and a long diastolic. The aortic second was not audible. The pulse was of the plateau type. There was no thrill. The vessels of the neck pulsated strongly and the pulse could be felt even in the finger-tips, where capillary pulsation was visible under the nails. There was marked edema of the left upper arm and hard edema of the forearm. Both legs were also much swollen. The *x*-ray, diagram of which is here reproduced (Fig. 222), showed dilatation of the aorta along its left border. Wassermann reaction was negative. Blood negative. Blood-pressure, 220 mm. Hg., systolic; 110 mm. Hg., diastolic. Urine, 30 ounces in twenty-four hours, with a specific gravity of 1014, a very slight trace of albumin, no casts.

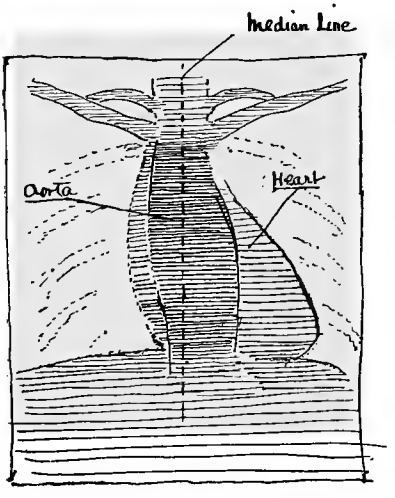

Fig. 222.—Sketch of *x*-ray plate showing dilated aorta in Case 267.

Discussion. — The history sounds rheumatic, despite the patient's statement to the contrary. By this I mean that it is unusual for a patient to have a recognized cardiac lesion for thirteen years unless that lesion is of rheumatic origin. Nevertheless, there is much in the examination of the heart and aorta pointing toward syphilitic disease. Aortic regurgitation and enlarged aortic arch may, it is true, result merely from rheumatic trouble, but in the vast majority of cases they are syphilitic in origin.

Granting that the aorta is dilated and capable of exerting pressure upon the venous trunk, we have a good reason for phlebitis and swollen arm. On the other hand, the phlebitis may have originated simply by infection within a stagnating venous current and without any local pressure. Nothing in the case tells how to decide this question. The prognosis is, in all probability, good.

Outcome.—The cause of the edema was not discovered, and on July 6th was still present, though much less. She left the hospital July 10th.

Case 268

A laborer of thirty-seven entered the hospital May 23, 1912. Family history negative. Two years ago he had left-sided pneumonia followed by dry pleurisy. He was sick ten days, and thinks he has not regained his strength since. He had bronchitis six months ago, but did not stop work. He has had no cough this winter. Takes one to three whiskies a day. Denies venereal disease. Seven weeks ago, while at work, he was seized suddenly with dyspnea, vertigo, and weakness. After a drink of whisky and an hour's rest he managed to finish the day's work, but gave up next day. The next few weeks

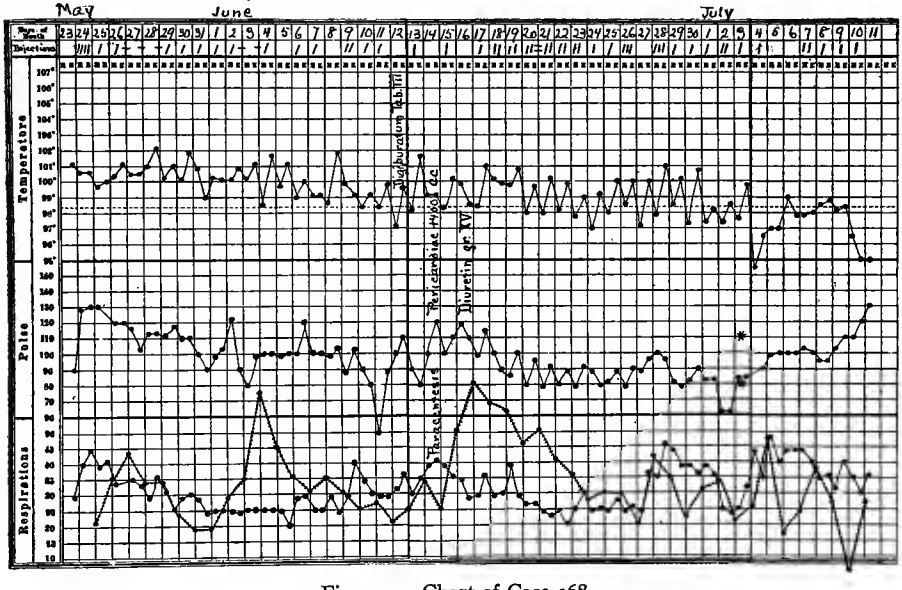

Fig. 223.—Chart of Case 268.

he was up and about the house, but felt poorly and did no work. He thinks he had fever at this time, but noticed no shortness of breath.

Three weeks ago he took to bed with pain in both axillæ, so severe that he could only lie upon the "broad of his back." This pain has been less severe of late, but has been followed by shortness of breath and orthopnea, with constant cough, but very little sputa. There have been no digestive symptoms except poor appetite. He thinks he has lost considerably in weight and strength.

Physical examination showed good nutrition, deep rapid breathing, severe paroxysms of coughing. He lay only on his left side. Moderate cyanosis and marked sweating. No glandular enlargement. Pupils

and reflexes normal. Abdomen negative. The heart-rate was between 120 and 130 for the first three days in the hospital (Fig. 223). The heart sounds were feeble, and during inspiration many beats were nearly or completely obliterated at the wrist. The whole left side was dull, especially in the upper half, and there were many coarse râles over it and over the precordia as well. Fremitus was generally diminished in the lower half, increased in the upper half. There was amphoric breathing under the left clavicle. The right border of cardiac dulness extended 7 cm. beyond the median line. White cells were 11,500 at entrance and remained in that vicinity for the next month. The urine showed nothing abnormal except at

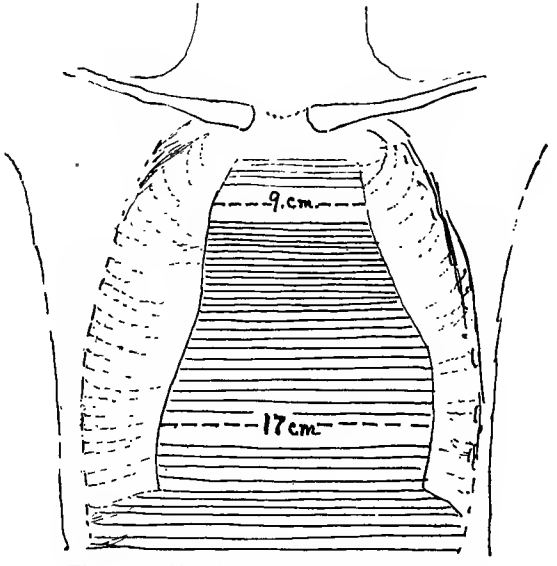

Fig. 224.—Sketch from *x*-ray plate June 4th.

times a slight trace of albumin. The sputa was examined repeatedly for tubercle bacilli, but they were never found. Among the various organisms seen pneumococci predominated. Dr. F. T. Lord considered the case one of mediastinal new growth, but later inclined toward pericardial effusion. Dr. W. H. Smith considered it mediastinal tumor. Within a couple of days of entrance a very marked edema appeared on both sides of the neck, also a massive soft edema of the tissues in the region of the left breast. The right arm was enormously swollen, and there was a network of dilated veins over the front of the right shoulder. The arm was also tender and red, so that a lymphangitis was suspected, but this swelling gradually went down

without interference. On the 28th I noted that the dulness in the left chest was nowhere extreme, but moderate, with a shade of tympany. The breathing was bronchovesicular, not bronchial. Râles innumerable, sharply crackling. The patient seemed at that time better. June 1st, the heart sounds were clear but feeble, the arm much less swollen; he was stronger and could turn in bed better. The cardiohepatic angle was still markedly obtuse. In the left back, near the angle of the scapula, and in the lower left axilla there was bronchovesicular breathing with diminished fremitus. Above that point the breathing was nearly normal. June 2d, additional history was ob-

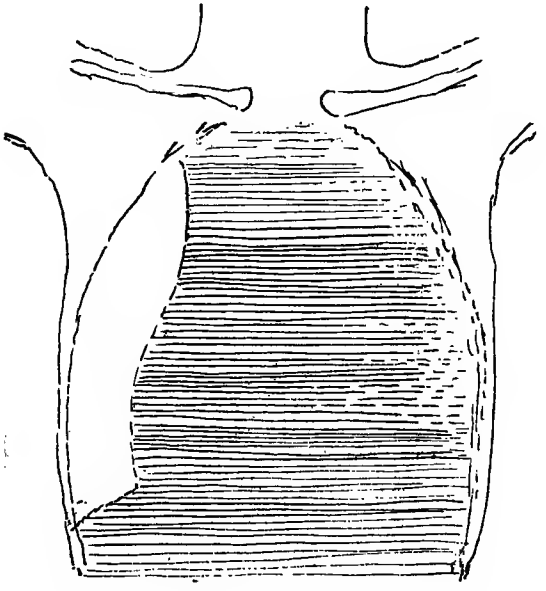

Fig. 225.—Sketch from *x*-ray plate June 5th.

tained from the patient's physician, who stated that the patient had been drinking heavily before the onset of his illness and that there was marked precordial pain at that time; that three weeks ago his present dyspneic condition came on, together with pain in the lower thorax. At that time signs of solidification were found at the left base, together with a mitral systolic murmur. Under the physician's observation the heart sounds changed from loud and strong to distant, rapid, and weak in the course of seven days. *X*-ray (Figs. 224, 225) showed an immense shadow filling the mediastinum, much wider at the bottom than at the top. The right border of this shadow was believed to be due to the heart and great vessels. The cardiohepatic angle was

obliterated. The left border of shadow was less distinct, but suggested a cardiac outline more than anything else. Diagnosis, probably pericardial effusion, possibly dilated heart. June 12th the heart showed no murmur and had a feeble tick-tack quality. Sounds loudest near the ensiform. The edema of the neck had then disappeared, but was still very marked in the tissues about the left nipple and axilla and in the abdominal wall. June 14th the precordial dulness extended 18 cm. to the left of the median line and 8 cm. to the right (Fig. 226). The diagnosis at this time lay between pericardial effusion and a dilated heart, with intracardiac thrombosis. I inclined to the latter,

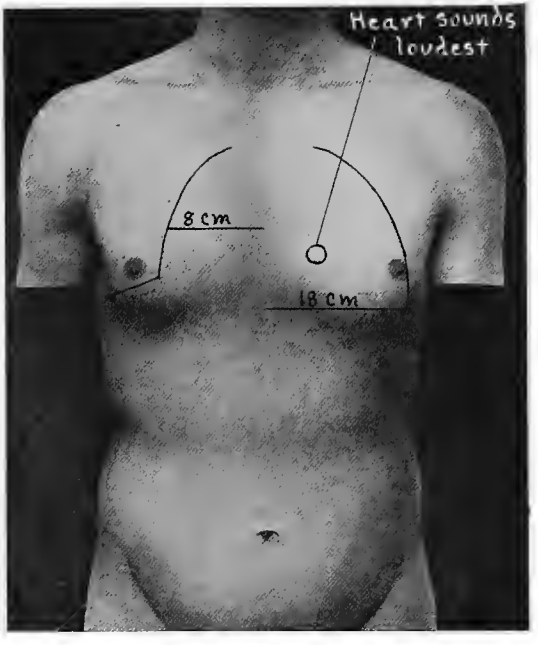

Fig. 226.—Percussion outlines in Case 268.

but as the man was getting worse, and we desired to exclude the possibility that his decline was due to a removable pressure about the heart, a needle was injected in the fifth left interspace, 1 cm. inside the nipple line at right angles to the chest wall. No fluid was obtained until the needle had passed $4\frac{3}{4}$ cm. and had traversed a firm, resistant tissue. Then 1400 c.c. were withdrawn before the flow stopped. Toward the end there was a marked improvement in the patient's pulse and a faint impulse palpable upon the cannula with each heartbeat. The last 500 c.c. of the fluid showed a slightly reddish tinge, the rest of the fluid dark straw color. The specific gravity was 1020;

albumin, $3\frac{1}{2}$ per cent.; sediment: polynuclears, 54 per cent; lymphocytes, 46 per cent. Culture showed no growth. Twenty minims of the sediment injected into a guinea-pig June 14th. July 19th the pig was killed. Autopsy showed tuberculous lesions of the glands, liver, and spleen. In reaching this fluid the needle entered at a point 15 cm. from the median line, though it was inside the much displaced left nipple. The needle-point was directed toward the median line, and entered first an inch of solid tissue, then went more easily, then penetrated a resisting wall and reached the fluid. During the tapping the

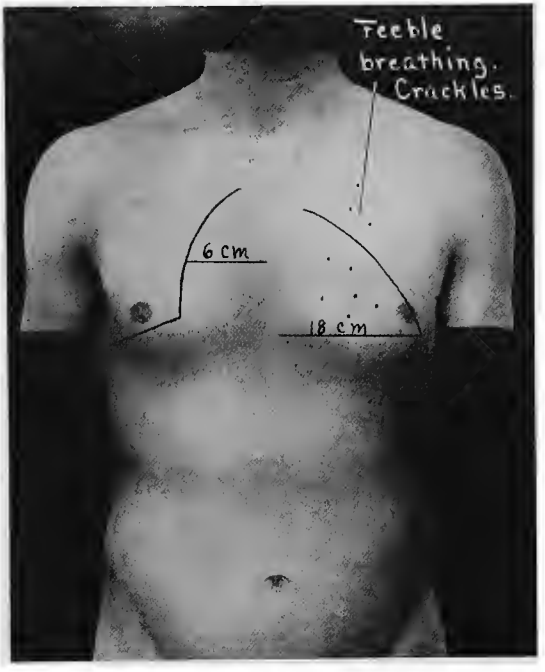

Fig. 227.—Percussion outlines and other signs in Case 268.

right border of cardiac dulness moved considerably toward the median line and the paradoxic pulse disappeared. Next day the right border of dulness was 3 cm. nearer the middle line than before tapping. The paradoxic pulse returned soon afterward and the patient was much distressed by cough. On June 22d the bronchial element had disappeared from the left chest and the edema was gone. He moved strongly in bed, his pulse was slower and no longer paradoxic, he slept without drugs, had a nearly normal temperature, a pulse of 80, and was anxious to get up. On June 29th the pericardium seemed to be refilling. The outline of dulness is shown in Fig. 227. July 3d there

was a sharp pain in the right chest and a friction rub was heard over the upper part of the liver dulness. The liver now reached to the level of the umbilicus. The heart sounds were again distant. *X*-ray was interpreted as pericardial effusion. On the 3d of July he had a sudden attack of collapse, with cold extremities and almost imperceptible pulse. The next day his pericardium was tapped at the same part as before and a cavity reached, but only a few cubic centimeters of bloody fluid obtained. There was no flow of air through the cannula with respiration. The needle was believed to be in the pericardium. On the 7th he began to have bloody sputa, increasing weakness, and mental confusion, and on the 11th he died.

Discussion.—Although we were long in doubt as to the correct diagnosis in this case, we finally settled down upon the belief that pericardial effusion was the most important element in it, and the results of paracentesis confirmed this. Animal inoculation showed that the pericarditis was of tuberculous origin. Although he had been so desperately ill throughout the whole of June, it seemed toward the end of that month as if he were going to get well. At that time we did not know the result of the animal inoculation. Presumably he had tuberculosis, not only in his pericardium, but elsewhere, and his death was due not only to cardiac weakness, but to infection.

Edema of an arm in connection with large pericardial effusions has been repeatedly observed. Presumably in this case it was due to thrombosis with a large venous trunk. I will call attention to the enormous amount of fluid withdrawn from his pericardium, which certainly must have been gradually distended for a long period in order to contain so much.

Case 269

An Italian housewife of fifty-three entered the hospital April 25, 1912. The patient has six healthy children and has had no miscarriages. For a long time she has noticed dyspnea on exertion and cannot climb stairs. Otherwise she has been well. She takes a little wine, but not every day, and no hard liquor. For the past month, since she has been in this country, she has been in bed with increased dyspnea, swelling of the feet, of the left arm, and of the abdomen. Her appetite remains good and she feels well in other respects.

Physical examination showed emaciation and enormous enlargement of the abdomen. Pupils and reflexes normal. Heart's impulse in the fifth space in the nipple line. Sounds rapid and irregular; no murmur. Pulmonic second accentuated. Artery walls palpable.

Lungs show coarse râles throughout. Abdomen showed shifting dulness in the flanks and the suggestion of a mass in the right upper quadrant. Very marked edema of the legs. Urine, 25 ounces in twenty-four hours, with a specific gravity of 1020 and occasional hyaline casts. Blood normal. Blood-pressure was essentially normal. Wassermann reaction negative. The feces contained an 8-inch round worm, otherwise not remarkable. The abdomen was tapped and 46 ounces of pale yellow fluid obtained, with a specific gravity of 1009, and the sediment containing 46 per cent. endothelial cells and the remainder lymphocytes. On account of the low gravity of the fluid, without evidence of cardiac or renal disease, a diagnosis of cirrhosis of the liver was made, but within four days the liver edge could be easily felt. After tapping, it receded rapidly and the heart continued to be irregular in force and rhythm. Mitral stenosis was, therefore, suggested. May 5th the arhythmia continued absolute. The pulmonic second accentuated, the first sound sharp. The disproportionate ascites, in comparison with the edema elsewhere, suggested adherent pericardium. Calomel, 3 gr. every four hours, was given May 8th, after digipuratum, diuretin and purgation, and salt-free diet had failed to increase the output of urine. After the calomel had been continued for three days it was omitted. On the next day 40 ounces of urine were passed and the dropsy rapidly subsided. May 27th there was no ascites or edema. The heart was slow and regular, the first sound doubled, and a slight presystolic murmur was heard at the apex. The edge of the liver was still palpable, but smooth, and even at the time of discharge, June 3d, the organ extended to the level of the umbilicus, but its dulness began at the costal margin. She left the hospital June 3d, but re-entered June 12th, with a return of all the symptoms. The day after this second entry she was exceedingly nauseated. Every other beat of the heart was strong, the intermediary beat not reaching the wrist and being followed by a compensatory pause.

Discussion.—No one could be blamed for making, as we did, a diagnosis of cirrhosis during the early stage of this patient's illness, although we were quite aware that some cardiac disease existed in addition to the liver trouble. With the prompt recession of the liver edge, this diagnosis began to seem very improbable.

What causes for ascites remain? The tap-fluid was obviously a transudate or dropsical effusion. It could not be explained by tuberculous peritonitis or neoplasm of the peritoneum. The kidneys showed too little disease to explain it. We must fall back, therefore, upon the heart as the cause of ascites. Now, the one cardiac lesion which we

have grown to recognize as a cause of ascites without any proportionate degree of edema in the legs is adherent pericardium. This disease ultimately becomes associated with a capsular liver cirrhosis and leads to many a mistaken diagnosis in interstitial hepatitis.

The presystolic murmur and cardiac irregularity may well have been due, as we supposed, to mitral stenosis, a lesion not infrequently combined with pericardial adhesions.

So far I have said nothing whatever regarding the swollen arm. Presumably, it is due to phlebitis.

Outcome.—The patient began to be much disturbed mentally, refused medicines with violence, and could not be quieted. She left the hospital on the 16th.

Case 270

With an uneventful history and inheritance a clerk of forty-six entered the hospital June 10, 1912, complaining that about two months ago both hands became rather suddenly swollen, the skin red, rough, and covered with cracks and scales. There was only slight itching and no known exposure to local irritants. He felt otherwise well, but had to stop work because of the appearance of his hands, and since that has been steadily losing weight and strength. His appetite is gone, and he lives on eggs, milk, and bread. He has a constant dull pain in the upper abdomen, without relation to food. His bowels are slightly loose, moving twice a day. His flow of saliva is increased, especially at night, and he has a bad taste in his mouth. On exertion he is short of breath and his feet swell during the day. His head feels dizzy and his eyesight is poor. He passes urine once or twice in the night.

Physical examination shows poor nutrition, swelling of both hands and wrists, with a patchy deep red coloration and some small whitish areas where the epidermis has come off, leaving a clear surface beneath. Small exfoliating areas are seen near the nasal fold on each side. The abdomen shows slight tenderness and spasm, especially in the epigastrium. Physical examination, including blood and urine, otherwise normal. Systolic blood-pressure, 110. No fever in two weeks' observation. Stomach-tube shows no contents in the fasting stomach and no free HCl after a test-meal. The patient states that for several years he has had attacks of indigestion in the springtime, lasting a day or two, but never severe enough to be remembered without cross-questioning. With the onset of his present skin lesions there was loss of appetite, soreness of the mouth, and a mild diarrhea. He has also had tingling sensations in his legs and feet, relieved by rubbing.

When seen in the Out-patient Department there seemed to be a noticeable disturbance in mentality: excitement, emotionalism, and weakness. The skin lesion consists of a dry, cool eczema of the hands and wrists, 1 to 4 cm. above the wrist-joint. Underneath a ring, removed by the patient July 13th, the skin is fresh and soft.

Discussion.—Although both arms were involved in this case, I have included it because of its unusual diagnostic interest. Clearly the edema is to be attributed not to intravascular or mediastinal causes, but to the local lesion. The association of this with diarrhea, indigestion, and mental symptoms strongly suggests pellagra. Indeed, I know of no other diagnosis which can be called upon to explain such a clinical picture. If any other diagnosis is made, we have to suppose that there are two or more separate diseases, such as eczema and dementia paralytica. We have no evidence of this, and should endeavor, if possible, to bring all the facts under a single explanation.

Outcome.—The patient was seen by Dr. C. P. Ward, of Atlanta, who found no doubt of the diagnosis of pellagra. Investigation of the patient's home conditions showed that he was peculiar, and could not get along with his neighbors or employers. He says that he is always trying to spit poison out of his mouth. There was nothing peculiar about his diet, and no reason to believe that he had partaken of any spoiled cereals. He was discharged on the 24th of July.

CHAPTER XVI

DELIRIUM

It is hard to define delirium. Ordinarily, we are content to say that it is the sort of rambling, incoherent talk which patients have during the height of pneumonia or in acute alcoholism; but we also recognize that in insanity the same phenomena occur without any infection or fever. We distinguish delirium from the irrational, incoherent talk of the psychoneurotic or the hysteric. The latter patients put more of will and intention into what they say. The truly delirious patient is thought of as entirely unaware of what he is saying. Whether these distinctions can be strictly maintained or not, the foregoing is probably as definite a statement of our present usage of the word delirium as can easily be made.

Using the word in this sense, we must note, first of all, that *children* become delirious on very slight provocation, as the result of a cold or even a digestive upset. In them the phenomenon is doubtless in some way connected with their greater liability to sleep walking and to talking in their sleep. Their mental stability and balance is more easily disturbed than that of the adult.

Next to the transitory deliria of the slight childhood illnesses, *alcoholic delirium*, or delirium tremens, is probably the most common. This is often characterized by hallucinations of sight. Animals, and especially black animals, are more frequently seen than other objects.

Among infectious diseases, *pneumonia* is most often associated with delirium of an active type. In *typhoid* the delirium is quieter and the patient is easily roused from it.

Of special interest are the *postinfectious* deliria and psychoses, which are to be differentiated from most other acute psychoses by their better prognosis. Doubtless these are closely akin to the psychoses of the *exhaustion type* seen after surgical operations, and often called postoperative psychoses.

In *uremic states* and in *cerebral arteriosclerosis* one sees various types of mental disturbance, and in the acuter and more serious forms typical delirium may be present.

During the treatment of a case of acute rheumatism, and in any other disease which involves the free exhibition of *salicylates*, one must remember that these salts are capable of exciting an active delirium, the source of which is often not recognized. Next to salicylates, *belladonna* is the commonest source of a drug delirium.

In *acute anemia*, after hemorrhage and shock, periods of delirium are often seen, not only in fatal cases, but in many that recover.

All of the above types of delirium are to be distinguished from those which occur in the course of those chronic psychoses to which we give collectively the name of "insanity" and of which I shall not attempt to speak. For practical purposes, it seems to me that it is especially important that the physician should be able to distinguish true delirium from the manifestations of hysteria. This distinction is aided by every observation which helps us to recognize the other features of hysteria: the cause and mode of onset, the previously recognized characteristics of the patient, the association with convulsive or pseudocomatose states, the presence of hemianesthesia, and other stigmata of hysteria. So far as the delirium itself is concerned, it is distinguished from the incoherence of the hysteric in that the latter has usually a predominance of emotion, and especially of rapidly shifting emotion. The hysteric can usually be aroused, that is, made to talk with comparative rationality if the appropriate stimulus can be applied. The older and more brutal way of applying this stimulus was to throw a bucket of water over the sufferer. Often, however, the right appeal to the patient's central or true personality can be found and used by one intimate with the patient. In true delirium this is impossible, and nothing that we say makes any special difference.

Case 271

An Italian laborer of twenty-one entered the hospital November 16, 1912, in delirium; no history was obtained. The patient was poorly nourished, and had a curious contraction of his facial muscles, suggesting *risus sardonicus*. The left pupil was much larger than the right. Both were circular, but reacted only slightly to light. Accommodation could not be tried. The tongue was not seen on account of trismus, possibly voluntary. The epitrochlear glands were felt, but there was no demonstrable enlargement of any gland. The heart was negative, the pulse not dicrotic. The lungs negative. The abdomen level, tympanitic, held somewhat rigidly; no other abnormality. The spleen was definitely enlarged to percussion, but

its edge not felt, perhaps on account of muscular spasm. The lower end of the right kidney was palpable, but not tender. There was no costovertebral tenderness. Knee-jerks were not obtained. There was no ankle-clonus or Babinski. Kernig's sign was questionable on both sides; the neck was not stiff. There was no bone or muscle tenderness.

The Widal reaction was suggestive, but not positive. Blood-culture negative. Wassermann reaction negative. Leukocytes, 6900; polynuclears, 88 per cent.; lymphocytes, 12 per cent. Temperature as in Fig. 228. The amount of urine could not be determined, as it was passed involuntarily. The specific gravity was 1024; albumin, slight trace. A few granular casts and red blood-corpuscles were found in the sediment. The spinal cord was tapped and 10 c.c. of blood-tinged fluid withdrawn under slight pressure. On account of the admixture of blood, examination of the sediment was unsatisfactory. Fundus oculi was normal, the cornea coated with a film of mucous secretion. A slight amount of bloody and purulent sputum was obtained which, on examination, showed nothing significant. No diagnosis as yet.

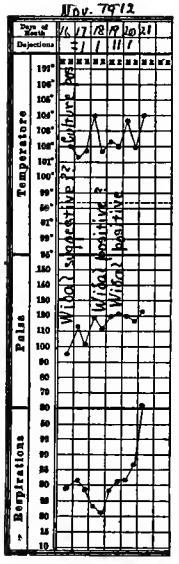

Fig. 228.—Chart of Case 271.

November 18th a sister-in-law was communicated with, who stated that the onset of the dsease had been sudden, with pains all over the body, especially in the back of the neck, elbow-joints, and knee-joints. These symptoms began with a chill nine days ago. The patient is unmarried and has been in this country two years.

The cultures from the spinal fluid were negative. A second attempt at spinal puncture was unsuccessful. The needle seemed to be in the spinal canal, but no fluid was obtained.

Discussion.—Clearly, this is the delirium of an infectious disease. The only question is, what infection? The curious contraction of facial muscles made us fear tetanus, but as time went on this disappeared and nothing else appeared to suggest that disease. Had the Widal reaction been positive, one would have no hesitation in calling the case one of typhoid fever, although the increased percentage of polynuclear cells and the absence of any leukopenia are atypical for typhoid. Nothing in the examination of the nervous system supports the idea of meningitis.

The sudden onset with chill might have occurred in malaria, but we searched without success for any parasites. Up to the 19th of November our diagnosis was wholly uncertain.

Outcome.—On the 19th a number of red macules and papules, about 2 mm. in diameter, appeared upon the trunk and abdomen and the Widal reaction in the blood was positive. The patient was constantly delirious and noisy. On the 21st a third attempt was made at spinal puncture without success. The patient died the same night. Autopsy showed the lesions of typhoid fever with double otitis media and focal pneumonia of the left lung. In the pelvis of the left kidney was a stone occluding the ureter and producing hydronephrosis. The other kidney was normal. Chronic perihepatitis and perisplenitis.

Case 272

A merchant of fifty-five was seen in consultation December 11, 1912. He had always been well, although nervous, until ten days ago, when he had chill and fever, rusty sputum, and the ordinary signs of solidification at the right base. For five days he continued desperately ill, then his temperature dropped to normal, but, to the surprise of all concerned, he began then to be delirious, and has continued so ever since despite a persistent normal temperature. The pulse has ranged between 100 and 120, and has at times been very irregular. He has taken food well, but has had moderate abdominal distention throughout the illness.

At the onset of his delirium he had incontinence of feces. He has now regained control of the sphincter. The attending physicians are in doubt as to the condition present at the bottom of the right lung.

On examination the patient is drowsy and has respirations still, 40 per minute, formerly 48. He looks more than his age, but at the time of the examination was rational when aroused from his nap. He moves with difficulty and seems greatly prostrated. At the top of the right lung, as low as the level of the second rib, there is flatness on percussion, with distant bronchial breathing. In the back this is accompanied by coarse crackling râles, which are more numerous in the lower half of the lung. Below the level of the second rib in front the percussion note is short, but low pitched, with a shade of tympany. The left lung showed nothing but a few scattered râles; the pulse is 100 and regular. The heart is negative. The blood-pressure is not measured. Save for moderate abdominal distention the physical examination is otherwise negative.

Discussion.—Meningitis had been seriously considered by the attending physicians, but against this was the absence of any stiff neck, Kernig's sign, or ocular changes. The absence of headache and fever, at the time when cerebral symptoms were most marked, suffices, with the other data just mentioned, to exclude meningitis.

Were he an alcoholic, one might have interpreted the delirium as delirium tremens, even though no trembling was present to substantiate the title; but the history was reliable and excluded this possibility. The condition was clearly not a hysteric one. At his age such things do not arise *de novo*.

The ordinary psychoses are not apt to arise in such close connection with an infectious disease. Hence, the remaining possibility—postinfectious delirium—seemed the most reasonable diagnosis. This was explained to the family and a good prognosis was given.

Outcome.—February 25, 1913, the patient writes that he is perfectly well in essential respects, although he has been somewhat slow in recovering his strength. The attending physician tells me that the delirium cleared up about a week after I saw him.

Case 273

A farm laborer of advanced years consulted his dentist early in March for a supposed toothache on the left side of the upper jaw. The dentist pulled two teeth without relieving the pain, which later spread over the left side of the head and was specially severe at the vertex. At this time the patient had no other symptom except an increasing weakness and confusion, which did not prevent him, however, from continuing to do his work upon a farm, though many of his days were short ones. About six weeks after the onset of headache he returned one day from his work in a state of mind which alarmed his wife. He did not seem to recognize her and talked wildly and incoherently. He was removed to the nearest hospital the same night, where I saw him next day.

He was mumbling and rambling in his talk as I approached his bedside. As he was an old friend of mine, I spoke his name sharply, at which he roused, recognized me, and burst into tears, evidently affected by the contrast between his present condition and the ruddy health in which I had always met him before. The left pupil was much larger than the right; the tongue was protruded somewhat toward the right side of the mouth. The right knee-jerk was increased, and there was a Babinski reaction in the right foot. During a week's observation there was no fever or leukocytosis. Wassermann reac-

tion was not tried. His speech, as he responded to my questions, was slow and difficult to understand. Single words were repeated monotonously, and before I left him he drifted off again into incoherent talk. The systolic blood-pressure was 180. The heart was somewhat enlarged, but not otherwise remarkable. There were many crackling râles scattered in both backs. The fundus oculi, examined by an expert on the previous night, showed no important changes, though the arteries were markedly sclerosed, as were those in the arm and groin. He no longer complained of headache, but became more and more helpless and hemiplegic. Three days later his sphincters became relaxed, and on the fourth day he died. There was no autopsy.

Discussion.—At this patient's advanced age it is natural to attribute almost any cerebral symptoms to arteriosclerosis. Brain tumor is almost the only plausible alternative. The absence of more distinct focal changes and of optic neuritis and the presence of hemiplegia are more characteristic of arteriosclerotic brain trouble than of tumor.

The chief point of interest in the case is the onset with delirium, rather than with aphasia or coma. Just what went on within his brain we never shall know. It seems to me probable that thrombosis and softening were the cause both of his initial headache and of his subsequent delirium.

Case 274

On the 18th of February, 1913, I saw in consultation a married woman of thirty, who had always been perfectly well except for an attack of typhoid fever twelve years before.

For the past two months she has been somewhat run down. February 12th she was taken with sore throat and pain in the left side of the chest, a temperature of 103.5° F., pulse 160. The tonsils showed the ordinary appearance of follicular tonsillitis, but the amount of pain was unusual. By the 15th the throat was much better, temperature 101° F., but the doctor noticed at this time a peculiar odor, suggesting that of the postmortem room.

Next morning, February 16th, she woke in active delirium, with religious delusions, with bad pulse, a scanty urine, yet with a temperature of only 99.5° F. During the next twelve hours only 10 ounces of urine were passed, although she was taking food very fairly and complaining of no headache or other form of distress. No atropin or belladonna had been given her. She had received aspirin, 5 gr., three times

a day, and infusions of digitalis, ½ ounce, every four hours for the past three days, with strychnin, $\frac{1}{30}$ gr., four times a day.

On examination she showed good color and nutrition. Teeth and chin like those of a rabbit. She lay upon her back with closed eyes, twitching eyelids, and hands tightly clasped across her chest. Her breathing was slow and regular, her heart-beats 60 to the minute, with a slight irregularity apparently of the sinus type. Save for a systolic murmur at the apex the heart was otherwise negative, likewise the lungs and abdomen. The neck was not stiff. The reflexes were excellent. The pupils were large, equal, and reacted normally.

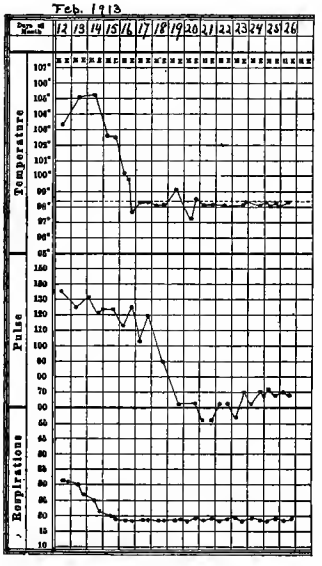

Fig. 229.—Chart of Case 274.

When I saw her the patient was conscious and would put out her tongue and answer simple questions, but showed no initiative. Her temperature and pulse ranged as in Fig. 229. Subsequent conversation with her husband elicited the fact that in the previous summer, while away from home and her two children, she had become acutely homesick, and after her return remained still morbid and not as bright as before. Just before the present illness there had been some question of her going away from home a second time. About this time she had been greatly upset.

Discussion.—Meningitis can be easily excluded by the absence of physical signs ordinarily associated with it. Uremia had been seriously considered by the attending physician, but when I saw her the urine was normal in quality though diminished in amount, and warranted no such diagnosis. There was a good deal in the physical state when I first saw her to suggest hysteria. The character of her previous delirium, and the immediate sequence of her mental symptoms upon the fall of temperature during an acute infection, seemed to me to warrant the diagnosis of a postfebrile psychosis.

Suspicion of more serious mental derangement, based upon her previous attack of homesickness and morbidity, did not seem to me well founded.

Outcome.—On February 27th her physician reported that she had steadily improved since the 18th and was now in excellent condition.

Case 275

On the 27th of February, 1913, a girl of nineteen was seen in consultation with her attending physician. Although always anemic and irregular in her menstruation, she had been considered a healthy, bright girl until two weeks ago. Her family history was excellent.

Two weeks ago she had a normal appendix removed. The convalescence seemed, for the first ten days, perfect. There was no fever or other untoward symptom. Then appeared what the doctor called "insanity" and headache. Her motions were largely resistive and stereotyped, a favorite action being to start up with the remark, "I've got to go and meet the doctor." She was disoriented and recognized no one. At times she seemed to be living over again the experiences of the etherization. Thus she would say, "They make you lie still and tell you to breathe deep," etc. At other times she would say, "Sh-sh-sh," with a semistammering articulation, as if trying to form words. Again she was tearful and anxious, grasping the doctor's hand and asking, "Are you mad with me? You are not mad with me, are you?" The words and motions just referred to had been repeated again and again, day and night, for the past five days.

Physical examination showed pallor; hemoglobin, 65 per cent.; a negative chest and abdomen, save for some tympany in the latter. The legs were spastic, and showed at times a coarse tremor approaching clonus. The eyes and neck seemed normal and there was no paralysis. The fundus examination had previously been made and was negative. The chart showed absolutely no fever and the leukocytes were not elevated. Her only complaint was the pounding sensation at the base of her skull on the left side, and it was remembered that she had had trouble with her ear for a long time, and had complained at times of deafness, although at other times this was wholly absent, and she said only that she felt as if something were growing in her ear.

During the five days that have passed since the abnormal mental condition first showed itself she has slept hardly at all and eaten but little, refusing food for the most part. The systematization of her delusions, as above described, has been most marked in the last two days; off and on she seems quite normal, but if she chances to sleep a little she always wakes "insane." To speak sharply to her often rouses her and makes her for the time being quite normal.

From time to time throughout these five days she has breathed with great rapidity, but has had no cough or true dyspnea. She moves easily and strongly in bed and has had no incontinence of urine or feces. The urine is normal.

Discussion.—Meningitis can be ruled out by the absence of fever and leukocytosis. The tendency to resistance and stereotypy makes it necessary to consider dementia præcox, but no such diagnosis is warranted until a longer time has elapsed. This is something to fear, and not yet to exclude. The onset of the symptoms immediately after the operation gives ground for doubting whether anything so serious is present.

The tendency to live over again the experiences of etherization is what one might expect in hysteria, and the physical condition is quite consistent with that idea; but, if it is true that she has previously been a perfectly normal girl and these symptoms never appeared until after the operation, it seems to me more reasonable to make some diagnosis which can be connected directly or indirectly with the operation itself. Two possibilities suggest themselves: since she is a chlorotic she is more than ordinarily liable to cerebral thrombosis (sinus-thrombosis), and since any type of thrombosis is more apt to happen after an operation, such a lesion might conceivably have occurred. Against this, however, are the absence of all focal symptoms, unless the sense of pounding in the back of the head is taken as such, which would be, I think, a mistake.

On the whole, the most reasonable diagnosis seems to me that of an exhaustion psychosis or postoperative psychosis, such as is the terror of all surgeons who remember its possibility. Nevertheless, the majority of such psychoses entirely clear up, and a good prognosis may, therefore, be given in such cases.

Outcome.—A letter received from her doctor states that "on the 10th of March, at 11 P. M., she said she felt something wind up in her head and then break, and immediately her reason came back and she recognized every one who came into the room. After that she complained of headache, especially at the back of the head, and would often throw her head back with a jerk and arch her back. I gave her a good talking to, told her she must stop it, which she did, although her neck was quite lame for some time after that. She is now perfectly well mentally. She gets up each day and practices walking, although her legs are so weak that she can scarcely use them. She looks finely and has no temperature."

Remarks.—This outcome seems to suggest that hysteria was the correct diagnosis—hysteria of the postoperative type—but I should still be doubtful of it unless some history of previous attacks or manifestations can be obtained.

Case 276

In the spring of 1893 a patient was brought in a cab to the Massachusetts General Hospital, fighting maniacally with his companion. This was about 5 P. M. His companion stated that the patient had been apparently perfectly well and at work as a day laborer that same day at noon, when, without rhyme or reason, he suddenly went crazy, and after some delay was conveyed to the hospital. After being put to bed he soon became manageable, and slept a good deal of the evening as well as the night. His temperature was 103.5° F. at entrance. His pulse was not elevated, respiration normal. His leukocytes were not increased. The only abnormal feature of the physical examination was a palpable spleen. A preliminary diagnosis of typhoid fever was made. No Widal reaction was done, because in 1893 Widal had not as yet done his epoch-making work. The next morning the temperature was normal and the patient seemed dazed, otherwise almost well. This sudden transition set us to hunting for malarial organisms in the blood, and after an hour's search I was able to find a pigmented parasite in violent motion. Quinin was at once administered in large doses, and the patient was able to leave the hospital twenty-four hours later.

Discussion.—The case illustrates the clinical manifestations of that overcrowding of the cerebral capillaries with malarial parasites which is so familiar to students of tropical medicine who see autopsies in the pernicious forms of the disease. Almost any type of cerebral or mental disease, such as meningitis, apoplexy, or insanity, may thus be simulated by a malarial infection, and whenever the temperature is high and the leukocytes low in such a case one should do one's best to find a malarial parasite.

CHAPTER XVII

PALPITATION AND ARHYTHMIA

A NORMAL man is unconscious of his heart-beat except after violent exertion or in periods of emotional strain. If he becomes oppressively conscious of it at other times he has *palpitation*. The heart's action may be *irregular* or simply *forcible and rapid*.

Usually palpitation and arhythmia go together, that is to say, the heart-beat is especially noticed by the patient when it becomes irregular. Mere force in the heart-beat, especially if it has been worked up to gradually during the development of cardiac hypertrophy, is not often noticed by the patient. What is distressing is a sudden change in force or in rhythm, which is forced upon the patient's attention and in greater or less degree alarms him. When a patient comes to us for palpitation he usually has one of the following diseases:

(1) *Thyrotoxicosis*, in which the violence as well as the rapidity of the heart's action attracts the patient's attention and causes alarm. There is probably no disease in which we see such violent, noisy, and spectacular heart action as in the thyroid intoxications with which Graves' name is ordinarily associated.

I recently saw a patient who, in answer to my preliminary questions as to what ailed her, simply pointed to her violently jumping carotids and said, "Don't you see?" That was her malady, so far as she knew. Examination showed the ordinary signs of a thyroid intoxication.

(2) *Hypertension*, due to arteriosclerosis or to chronic nephritis. Sooner or later in this condition the patient is aware of violent beating and throbbing, especially at night, when his attention is not otherwise occupied, or when he stoops and then rapidly recovers his balance, or after meals.

(3) *Valvular heart disease*, without hypertension, but with arhythmia.

(4) *Arhythmia*, with or without gross cardiac disease.

Of the *irregularities* seen clinically in patients *with obvious cardiac failure, 60 per cent. are due to auricular fibrillation*, and have the characteristics ordinarily described as absolute or perpetual arhyth-

mia (Thomas Lewis). Taking all varieties of irregular heart, *with or without cardiac failure*, Lewis gives the following figures:

Auricular fibrillation	40 per cent.
Premature contractions	35 "
Paroxysmal tachycardia, sinus arhythmia, heart-block, flutter, and alternation	15 "

The most serious types of arhythmia are due to *auricular fibrillation*. The premature contractions are much less often of ominous significance. The latter type corresponds to the occasional skipping of a beat, either at regular intervals or as an isolated phenomenon. It may continue through life and give little or no trouble. The arhythmia caused by auricular fibrillation produces a pulse in which no two successive beats are alike. When it once begins it usually continues during the rest of the patient's life, though that is not always the case.

Sinus arhythmia means ordinarily the physiologic variation of the heart's rate in connection with the act of breathing. The heart goes more slowly during inspiration and more rapidly during expiration. In adolescence and in the nervous, this psychologic variation may be exaggerated, but it does not usually trouble the patient or lead him to consult a physician.

Most *premature contractions* can be recognized clinically by the fact that they are followed by a pause of such a length that the premature contraction plus the pause is almost exactly equal in time to two normal contractions.

Heart-block is to be suspected clinically in cases of very slow pulse—25 to 30 or thereabouts—whether or not this is associated with apoplectic seizures. A certain diagnosis cannot be made without tracings from the jugular bulb and from the radial simultaneously.

Paroxysmal tachycardia can usually be recognized by the extremely rapid rate of the heart—200 or thereabouts—without any disturbances of rhythm and without any serious interference with circulation. When the rate is much above 200 the name of "auricular flutter" is given to it.

Alternation means the interposition of a small wave between each two larger ones, with or without a disturbance of rhythm. It is to be distinguished from coupling of the heart-beats, in which there is a pause between each pair of cardiac contractions. Alternation can rarely be recognized without a radial pulse tracing.

ETIOLOGY

Among the *causes of arhythmia* we may mention: (*a*) A failing heart of any type, rheumatic, syphilitic, arteriosclerotic, or nephritic; (*b*) the presence of any of the above diseases in the heart, without cardiac failure; (*c*) drugs, especially tobacco; (*d*) nervous influences.

Of the four well-recognized types of arhythmia, only two are often noticed by the patient—namely, the premature contraction or extra systole and the absolute or perpetual type of arhythmia. The sinus irregularities of adolescence are seldom noticed unless they are greatly exaggerated by some neurotic condition or by bad hygiene. The most marked cases of this kind are usually in those who have subjected themselves to *sexual excesses* without venereal disease. Tobacco and alcohol and coffee play a much smaller part in rendering the heart and the patient so irritable that sinus irregularities—that is, the variations in rate which are associated with respiration—become troublesome. Heart-block is so rare an affection that it need not be further mentioned here.

SUMMARY

For practical purposes, then, we may say that a person who complains of palpitation suffers in the vast majority of cases either from thyrotoxicosis, from hypertension, chronic valvular disease, from an absolute arhythmia, however produced, or from frequent premature contractions of the heart.

The pause following the latter type of irregularity is usually the thing which most alarms the patient. It often awakens him from sleep with a sense of falling or of great apprehension, sometimes of suffocation, although the circulation is perfectly well performed in the vast majority of such cases.

In the types of palpitation associated with valvular disease this particular symptom is usually overshadowed by dyspnea, insomnia, and other manifestations of the same lesions; hence, there are really but three conditions in which the patient often consults us for palpitation: thyrotoxicosis, hypertension, and nervous states.

Case 277

A Russian housewife of fifty-two entered the hospital April 21, 1906. Last winter the patient began to notice attacks of palpitation of short duration, occurring every week or two. Lately the attacks have been more frequent; otherwise she has always been well and has an excellent family history.

Types of Cardiac Disease

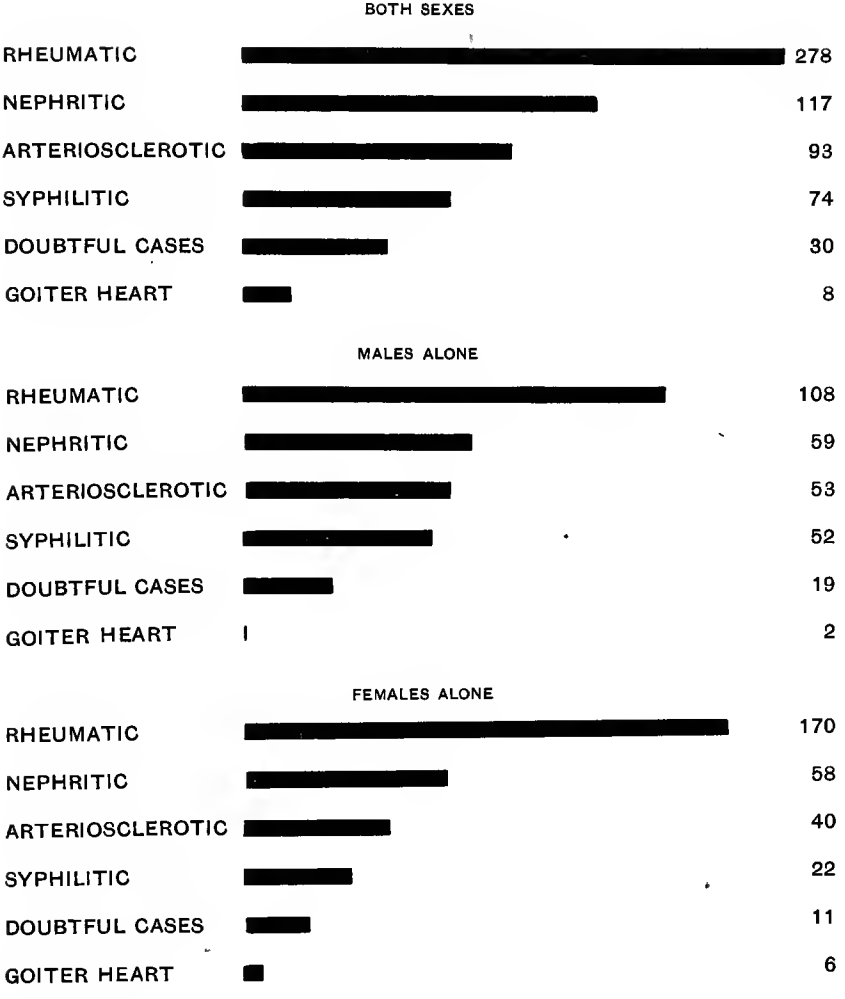

Physical examination, save as relates to the heart, was negative. The heart's dulness extended ½ inch outside the nipple line in the fifth space. Its action was irregular and intermittent. A soft systolic murmur was occasionally heard at the apex. Blood and urine negative. It was later learned that she had been taking six to ten cups of tea a day. After a week's observation, the pulse ranging most of the time between 80 and 90, she was allowed to leave the ward, although the heart was still slightly irregular.

Discussion.—I have searched the best I can through hospital records and private records for a case illustrating a cardiac neurosis with palpitation as a result of excessive tea-drinking. This is the best case that I can find, yet it does not seem to me that it will bear criticism. It is notable that no blood-pressure measurement is recorded, but my impression is that it would have been found to be elevated. The persistence of the irregularity after a week's separation between the patient and her tea seems to me to make it improbable that the tea was really the cause of her heart trouble. It is not at all likely that she has but recently begun to drink an excess of tea, yet at the age of fifty-two she is able to say that her troubles have lasted less than a year. A cardiac trouble, showing itself for the first time at the age of fifty-two and associated with enlargement, intermittance, and irregularity, seems to me, in all probability, due to some organic disease, of which, in the present instance, arteriosclerosis or nephritis seem the most probable causes. The Wassermann reaction should, of course, be done.

Case 278

A Swedish musician of twenty-one entered the hospital June 10, 1911. The patient's family history is excellent, previous history also good, save for an occasional attack of tonsillitis, the last one February, 1911. Once or twice in the past summer she spat up a mouthful of pink sputa; no cough before or after. She now comes to the hospital on account of rapid heart which she has noticed for two months, at first only on exertion, but now even when she is quiet. She also feels weak and cannot walk as she did. She has to lie down in the afternoon. Her appetite, bowels, and sleep are normal and she has lost no weight. Her eyes have not become more prominent, and her collars have grown too large rather than too small. She is very fond of music, but because of expense has not been able to continue her studies on the violin for the past year, and this has been a source of worry and anxiety.

Physical examination showed good nutrition, no tremor of the hands, thyroid normal, systolic blood-pressure 110, heart negative, except for a rapid rate, 130 per minute, lungs and abdomen negative. Reflexes normal. Blood and urine normal. No fever in three weeks' observation. With rest and reassurance, an occasional hypnotic or laxative, the patient gradually improved. Subcutaneous injections of tuberculin, in doses increased 1 to 5 mg., were not followed by any characteristic reaction. The pulse gradually diminished in rate (Fig. 230). On the 26th she was allowed to go home.

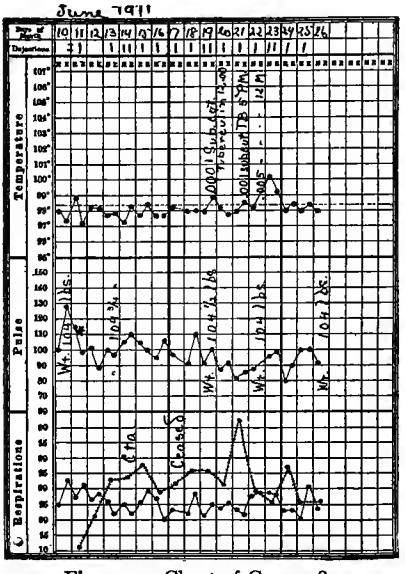

Fig. 230.—Chart of Case 278.

Discussion.—Save for the rapid gain under treatment and the rapid diminution in the rate of the pulse, one might easily believe this woman to be suffering from Graves' disease, which sometimes begins with tachycardia and no other symptoms except nervousness. But it does not seem to me at all probable that any such trouble would quiet down within a week. As a rule, months of rest are necessary before much change is to be seen.

Since the heart at present shows nothing abnormal except its rate, and since it settles down with rest, one cannot well assume that any of the four types of cardiac disease—rheumatic, syphilitic, arteriosclerotic, or nephritic—is present. The tonsillitis of February, 1911, and the pink sputa of the past summer may indicate some more serious trouble, but at the present time I do not see that we have any proof of it.

In all probability, therefore, we must attribute the heart-hurry to nervous or moral causes, and continue in this belief until more convincing evidence of organic disease appears.

Case 279

A maid of twenty-five entered the hospital October 30, 1911. The patient has always been well except for acute indigestion, which troubled her three years ago for a short time. During the past summer she was again nauseated in the hot nights and vomited a few

times. She has always been strong and cheerful and has liked her work. Her menstruation has been normal, her habits good.

A week ago she felt a queer sensation of pressure over the heart during the afternoon. At one o'clock the next morning she awoke with slight nausea and heaviness in the precordia. She vomited almost at once, and was immediately relieved "of a load of sickness around the heart," but at the same time noticed that the heart began to beat with great rapidity, and this continued the rest of the night and all the next day, the pumping distressing her very much. During this time she had brief spells of nausea, relieved by vomiting, about every hour. The next night she slept and did not notice the rapid heart action. The day after that she felt weak but comfortable, and on the third day was up and felt well. That night (two nights ago) the heart began to pound again, and has continued at top speed ever since. She has remained in bed, feeling weak, sleeping little, but otherwise not uncomfortable. If she sits up she feels faint and dizzy. Apparently there was no emotional stress of any kind at the time of the onset of these symptoms.

Physical examination showed a healthy, well-nourished girl, in profuse perspiration, with slight general tremor. Pupils and reflexes negative, except the left knee-jerk was more lively than the right. The rate of the heart when counted at the apex was about 200. At the wrist it could not be accurately counted. The apex impulse was in the fifth space, 1 cm. inside the nipple line. The sounds were very slightly irregular in force and rhythm. There were no murmurs. Physical examination, including the urine, was otherwise negative. Blood at entrance showed 15,500 white cells, 60 per cent. of which were lymphocytes. Systolic blood-pressure, 105 mm. Hg.

Discussion.—There is nothing distinctive or definite about the case until we come to recognize the degree of tachycardia. A pulse-rate of 200, without considerable arhythmia or signs of decompensation, rarely means anything else than paroxysmal tachycardia. A heart seriously weakened by any of the ordinary causes of heart disease or by the toxins of infection never goes at such a rate in an adult. Its rapidity, therefore, is really an encouraging sign. The diagnosis can be clinched beyond reasonable doubt only in case the tachycardia ceases as suddenly as it began and leaves the patient in fairly good health.

A case of thyrotoxicosis with a heart of anything like this rapidity would be *in extremis*. This patient is far too comfortable. The nervous and organic types of cardiac malady practically never send the heart-rate beyond 160. Paroxysmal tachycardia may come on in full

health as the result of some trifling, often quite unrecognizable, cause; thus, I have seen it in a young girl at the time of menstruation without any important consequences beyond a few hours' discomfort.

It may also appear in a heart previously weakened by disease, but only under these conditions has it any grave significance. Even then the patient never dies during such an attack, and often enjoys many years of good health thereafter.

Outcome.—Two hours after entrance the pulse was found to be 90, and continued slow during the four days of her stay in the hospital. Most of the time its rate was between 65 and 75. She was entirely free from symptoms; her blood was normal, and she was accordingly allowed to go home.

Case 280

A bookkeeper of twenty-three entered the hospital October 10, 1911. For two years he has been troubled with attacks of palpitation and nervousness. He has never been sick before. His habits are excellent. His family history is good. At first the palpitation came after meals or during excitement, but the attacks have grown steadily more frequent and longer. During his worst attacks he feels weak and unsteady upon his legs, but has no dyspnea. A year ago an attack took him just as he was starting for a quarter-mile race, but he ran the quarter in fifty-four seconds. He has a constant vague sense of uneasiness and restlessness. Small incidents often cause much emotional reaction, and when alone in a crowd he has a curious sense of fear. Before the present illness he is quite sure that he was a matter-of-fact person, never nervous or self-conscious. He has had several long vacations without benefit, but usually feels better on Mondays. His appetite, bowels, and sleep are normal. He has no fatigue and does his work as well as ever, although for the past year there have been brief sensations of hotness followed by chilliness and he has noticed a trembling of his fingers.

Physical examination showed a slight symmetric enlargement of the thyroid, coarse tremor of the fingers, normal viscera, no exophthalmos. Normal blood and urine. Weight, 140 pounds. Pulse at entrance 110, but after that it ranged between 70 and 90, although he was not kept in bed.

Discussion.—Evidently there is a strong nervous element in this case, but the presence of enlarged thyroid and tremor of the fingers makes it clear that the nervousness is of thyroid origin and the palpitation from the same source. Presumably, there was a time in the progress of this case when rapid heart action and nervousness were its

only symptoms, *i. e.*, when no tremor or goiter were visible. At such a time one could only make the diagnosis by the exclusion of all other possibilities. In nervous people this is sometimes impossible.

Outcome.—Operation was considered, but decided against. He left the hospital October 14th. In the spring of 1913 the patient reported that he was a little better, but still unable to do his regular work. Nervous tension, especially in cities or crowds, bothers him so much he says he would walk a mile to avoid it. In the country he is practically all right unless upset by some unusual excitement. When at rest he feels fine, but during periods of heart-hurry may get into a panicky state, especially if alone at night. His pulse is now 84, hands warm and moist. His weight is 140 pounds, as it has been for the past four years.

Case 281

An Italian housewife of thirty-one entered the hospital October 21, 1911. The patient's illness dates from four months previously. She has never been sick before this and has an excellent family history. Four months ago she began to be troubled with *palpitation* and weakness, and these symptoms have persisted since. Shortness of breath is scarcely, if at all, present, but during the first three months of this period she had much headache and almost daily vomiting, immediately after meals. She had no edema at any time. A month ago she was delivered of a 9½-pound baby by an easy labor, but immediately after it had urgent dyspnea and much aggravated palpitation. The baby died a week later. The patient remained in bed ten days, then was up until the past week, when she has again remained in bed, still vomiting occasionally, but nearly free from headache. A week ago, and again last night, she had an attack of violent palpitation and could not get her breath. She has had no dizziness or fainting, no cough or edema.

Physical examination showed poor nutrition, rapid breathing, slight cyanosis, normal pupils and reflexes, slight glandular enlargement in the neck, axillæ, and groins.

The heart's impulse was forcible and diffuse, extending 4 cm. outside the nipple, in the fifth space. There was no demonstrable enlargement to the right and no thrill palpable. A rough, loud, systolic murmur was heard over the whole precordia, loudest at the apex, transmitted to the axilla and back. A faint diastolic whiff was also occasionally heard along the left border of the sternum. The pulmonic second sound was moderately accentuated. Systolic blood-pressure varied between 105 and 125 mm. Hg; diastolic between 80 and 95 mm. Hg. Blood and urine were normal. Lungs and abdomen negative.

No temperature during a week's observation. At times a low-pitched presystolic murmur was heard at the apex and there was an occasional complaint of precordial pain, but in most respects compensation seemed to be excellent. No digitalis was given, and the patient went home on the 27th. No Wassermann test was made.

Discussion.—Physical signs point strongly toward valvular disease, and probably toward mitral stenosis. The patient is too young for arteriosclerosis, shows no signs of nephritis or thyrotoxicosis, and has never had a heart sufficiently rapid to be called paroxysmal tachycardia. The unusual feature about the case is that she should have been troubled first and chiefly by palpitation instead of by dyspnea. The prognosis in such a case is good, as she has got by the dangerous years for rheumatic heart. With moderately good care she ought to live for many years, provided her heart trouble is, as I have assumed, rheumatic and not syphilitic. A Wassermann test would help to determine the prognosis.

Case 282

A woman of fifty-five entered the hospital January 16, 1912. The patient's mother died of shock, one sister at sixty of apoplexy, and another sister at forty of shock. Two brothers died of consumption. The patient's husband had a tuberculous throat, and died of a combination of this and what was called typhoid fever. She has three children living and well and has had one miscarriage. Twenty years ago she had sciatica, which was obstinate and painful for two years, but entirely left her after that time.

For the past six years she has had occasional pains in her knees and hands, accompanied in the latter site by swelling and redness. For the past two years there have been no acute symptoms in the fingers, but stiffness and bony enlargement have been noticed. She had nervous prostration twenty years ago. She passed the menopause thirteen years ago without incident. One year ago she had a bad cough, lasting six weeks, but without hemoptysis, night-sweats, or loss of weight.

For the past eight months she has been troubled by palpitation and oppression in the chest, accompanying sensations of dyspnea. Swelling of the legs and puffiness of the eyes have been present off and on for four months. Her appetite has been increasingly poor and her bowels obstinately constipated. She has become weak and indifferent. She sleeps well with one pillow. Eight months ago she weighed 172 pounds, with clothes; now, 166 pounds, without clothes.

Physical examination showed good nutrition, flushed cheeks, puffy

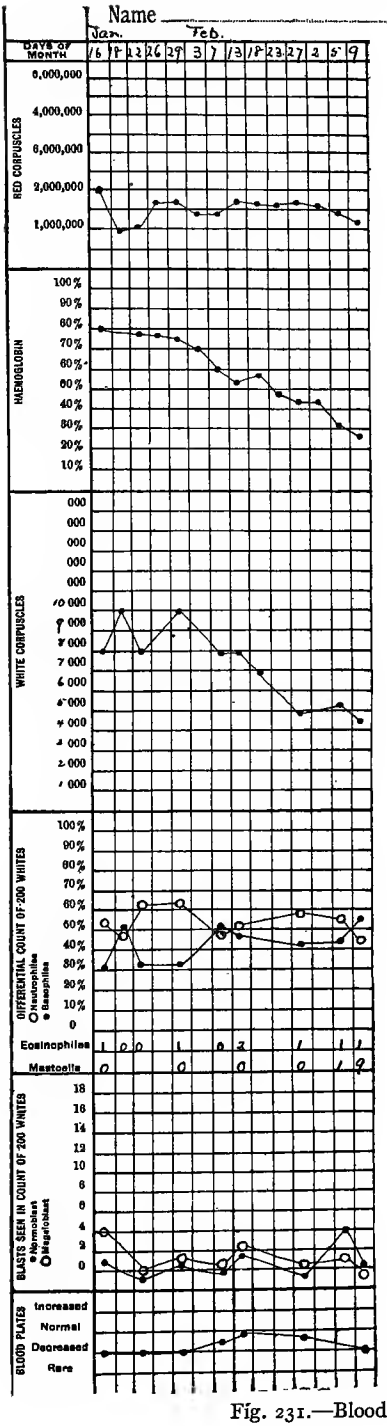

Fig. 231.—Blood chart of Case 282.

eyelids, a few urticarial wheals in the left upper chest. Pupils slightly irregular, equal, and reacting normally. Heart's apex extends 1 cm. outside the nipple. There was a soft systolic murmur over the entire precordia, transmitted to the axilla. The pulmonic second sound was accentuated. Systolic blood-pressure, 140 mm. Hg. at entrance, declining after a week to 120, where it stayed. Lungs were negative, except for a few fine râles at the right base behind. Liver dulness extended from the fifth space to a point 3 cm. below the costal margin in the mammary line, where a smooth non-tender edge was felt; otherwise the abdomen was negative. There was edema of ankles and over the sacrum. Knee-jerks present and equal. Heberden's nodes were well marked. Temperature, pulse, and respiration were practically normal during the eight weeks of her stay in the hospital, except for a flare-up in the last of February following injections of cacodylate of iron. The data concerning the blood are shown in Fig. 231. In the stained smear the red cells always showed a large amount of hemoglobin and large size, with an occasional stippled or off-color cell. Glycosuria was present for the first month of her stay, the output of sugar averaging 10 gm. per day. There was no acidosis or polyuria. A slight trace of albumin was usually present, with a few hyaline and granular casts.

Discussion.—The family history shows strong tendencies to arteriosclerosis and to tuberculosis, but neither of these diseases can be predicted in view of the facts indicated. To make a diagnosis of mitral regurgitation would be the ordinary procedure in such a case, but such a diagnosis would never be justified. There must be something behind it—the "something" of which the regurgitation, if it exists, is symptomatic. The same is true of myocarditis, the traditional term on which we often fall back for the lack of any better. I cannot see that the case fits into any of the known types of heart disease; neither am I content to call it merely functional. Probably the state of the blood is enough to account for everything. The diagnosis is clearly pernicious anemia. Without a blood examination I should be utterly at sea in such a case, and could only speculate and investigate regarding the possibility of alcoholism, cocaine habit, or some psychosis in the background. The patient's flushed, flabby cheeks and the absence of any obvious anemia might easily mislead one in a case of this kind, unless a blood examination were a matter of cast-iron routine in every case.

Outcome.—The patient felt stronger and happier in the middle of February, walked about a little each day, and ate fairly well. On the 10th of March she was sent to the Samaritan Hospital.

Case 283

A Scotch mill-worker of forty-two entered the hospital August 15, 1912. About a year ago the patient noticed that her heart was beating hard. She also had spells, when she felt as if "something comes over my head, darkness across my eyes, and I can't go out into the open air quick enough." These symptoms have progressed and been accompanied by shortness of breath on exertion, resulting finally in weakness so marked that nine months ago she took to bed for six months. Three months ago she felt better and has been about since. Has noticed no increased sweating, but has been growing very nervous for nearly a year.

On physical examination the heart's dulness extended 9 cm. to the left of midsternum and 4 cm. to the right. Apex impulse felt in the fourth space corresponding with the dulness. The sounds were rapid, irregular, and nearly one-third of the beats do not reach the wrist. There were no murmurs. Blood-pressure, 120 mm. Hg., systolic; 72 mm. Hg., diastolic. There was no exophthalmos and no goiter, but the fingers showed a fine tremor when extended. Pupils and reflexes were negative and there was no edema. Abdomen and lungs negative. The urine averaged 60 ounces in twenty-four hours, with a specific gravity of 1010, no albumin or casts. White corpuscles, 8000, with 47 per cent. polynuclears, and the remainder lymphocytes. Her past history and family history showed nothing of importance.

Under rest and neutral bromid of quinin, 5 gr., three times a day, the pulse rapidly improved, and by the 21st all the beats reached the wrist. The rhythm at that time suggested the fetal type. It later appeared that she had been given a good deal of thyroid extract and it was suspected that her symptoms might be due to that cause. Her husband deserted her several years ago, and she has been much tired and worried since. She left the hospital much improved on the 4th of September.

Discussion.—Here is a middle-aged woman with absolute arhythmia and tachycardia, with fine tremor of the fingers, but no other evidences of Graves' disease. Obviously, worry and fatigue have something to do with her condition, but it is not likely that they account for the whole of it. The condition of the heart does not suggest a rheumatic, syphilitic, arteriosclerotic, or renal type of heart disease. Probably the administration of thyroid extract may have contributed to produce her symptoms. But it does not seem to me likely that this is sufficient explanation. In a normal person the

amount of thyroid extract which she could have taken without entirely prostrating herself would not be apt to produce such marked symptoms. I believe there is something else in the background—namely, thyrotoxicosis.

Outcome.—September 24th she reported at the Out-patient Department feeling pretty well, weighing 123½ pounds, but with a pulse of 128. After she had sat still for half an hour the pulse was 90. She is less nervous, but still trembles at times. The largest circumference of the neck was 35½ cm. The heart's apex was in the fifth space, just outside the nipple line. Its action was rapid and the sounds of tick-tack quality. October 8th the neck measured 34 cm.; there was considerable tremor of the hands; the pulse was 96. November 29th she weighed 131 pounds, the neck was 34½ cm., and the pulse 114.

A letter received from the patient December 11, 1912, says there is now a lump in the front of her neck above the breast-bone. In other respects she is improving in health.

Case 284

A Russian rag-picker of twenty-nine entered the hospital March 21, 1910, for palpitation, with indefinite pain in the region of the left nipple and in the lower back. His family history and past history were not remarkable. He smokes from 25 to 60 cigarettes a day. He has no dyspnea, cough, or palpitation, but feels weak and tight across his chest. These sensations are not increased by exertion or by food, but are worse when he has headaches or when doctors are about him. They are sometimes associated with dizzy spells. He has worked steadily and has lost no weight.

Physical examination shows a marked tremor of the eyelids and an old puckered white scar under the ramus of the left jaw. The cardiac apex extends 2 cm. outside the nipple, as estimated by sight and touch. The right border extends 5 cm. from the midsternal line. Between the first and the second sound of every alternate cardiac cycle two faint short sounds are interposed. In this cycle there is no murmur, but in the normal alternate cycle a systolic murmur is heard about the region of the apex-beat. Blood-pressure normal. The pulses are equal, and the extra beat heard at the apex rarely reaches the wrist, so that the rhythm is usually regular there. In other respects physical examination, including the urine, is negative. Venous tracings showed this beat to be an auricular extrasystole. The patient's cardiac condition causes him actually no symptoms,

and the close observation seemed to be tending to make him neurasthenic. He was, accordingly, sent home on the 24th.

Discussion.—This case represents the best that I have been able to do to find a marked heart trouble attributed to tobacco, and I do not feel at all sure that the tobacco is the main cause of his troubles, for when the drug was taken away from him his cardiac condition was not much different from that which troubled him at the beginning. Presumably, the heart has been treated by the administration of digitalis. The alternation of strong and weak beats is what we expect to see under these conditions. We have no evidence of organic disease in the heart beyond a certain amount of enlargement; possibly a neurasthenia accounts for the whole thing. The lack of any increase in his symptoms after exertion, and their aggravation by close observation, seem to indicate that nervous causes are the most important part of his trouble. Such a patient should be told to keep clear of doctors and go about his business; if he has any organic disease, he is not likely to mind the advice long. If he has not, it will do him good, more good than anything else that we can do.

Case 285

A clerk of nineteen entered the hospital April 11, 1910. The patient's family history was excellent. With ordinary colds he has often had asthmatic attacks, and, although he has played football without difficulty, he believes that his heart has always been weak. He uses no tobacco or alcohol, and takes only one cup of tea and one cup of coffee daily. About the 1st of February, 1910, he began to have attacks of palpitation with sharp, needle-like pains in the precordia, coming fifteen to twenty times a day and lasting ten to twelve minutes, not influenced by food or by exertion. There has been no dyspnea, palpitation, cough, or other symptoms, except loss of strength, which has been noticed for about four months.

Physical examination showed good nutrition, negative pupils and reflexes. The heart's apex seen and felt in the fifth space, 11½ cm. from midsternum, 2 cm. outside the nipple line, the right border 1½ cm. from midsternum. The heart's action was irregular. During five minutes of auscultation the heart would be regular for thirty to forty beats, then would follow a succession of rapid strokes, irregular, both in force and frequency, the first sound apparently reduplicated at times. No murmurs were heard. Pulmonic second sound seemed to be accentuated. The pulses and radials were not abnormal, and visceral examination, including urine, was otherwise negative. Blood-

pressure normal. The blood showed a slight achromia and a polynuclear leukocytosis of 15,000. Venous tracings showed no defect in conduction. After exercise the heart was always much more regular than when he was sitting still. The Wassermann reaction was negative, and nothing further of interest was observed during ten days of his stay in the hospital. At times the radial pulse and the aortic second sound would be quite regular, even when the apex sounds seemed to be decidedly mixed up, owing to doubling of the first or the second. The precordial pain, of which he complained at entrance, was not relieved.

Discussion.—All the signs in this case seem to me to point toward a neurotic type of prostration. Of special importance is the fact that his heart is more regular after exercise than on sitting still. This is a test of great value and should always be applied in doubtful cases.

Although he states that his heart has always been weak, he seems to have had no functional difficulties, and one can place but little importance upon his statement, since he has played football without difficulty.

The needle-like precordial pains accompanying his palpitation are such as we have all frequently seen in cardiac neuroses; often they seem to be connected with gastric flatulency. The doubling of heart sounds which the record shows is probably of no importance in an otherwise healthy boy of this age.

Perhaps it is incorrect to call him sound, since his heart's apex is somewhat outside the nipple line. Without any *x*-ray control of this, however, I should not consider it of much significance. The type of arhythmia is probably respiratory, a so-called sinus arhythmia.

Outcome.—December 22, 1912, the patient's physician writes that he has been at work steadily except for the first month after he left the hospital, that he has not lost a single day since then, and appears to be in very good health.

Case 286

An engineer of thirty-three entered the hospital February 5, 1912. The patient's family history is excellent and past history not remarkable. Eight years ago, while working in a chair factory, he noticed very profuse sweating on slight provocation, and at the same time he lost much weight. After two months he saw a doctor, who said that he had "enlargement of the heart and trouble in the gland." After a vacation he felt much better and returned to work, where he

felt well enough for five years. Three years ago he began again to lose weight and his neck became swollen. The local physician at that time thought his condition serious and made him give up work. He then stayed upon a farm for a year and a half, during which time he improved much and noted considerable reduction in the size of his neck. For the past year and a half he has been working hard as an engineer and has felt fairly well until six months ago, when his neck again began to swell intermittently. Profuse sweating also returned, and his pulse has been very rapid. He has noticed no prominence of the eyes.

On physical examination the heart's apex extended 1½ cm. to the left of the nipple, in the fifth space. The sounds were clear, between

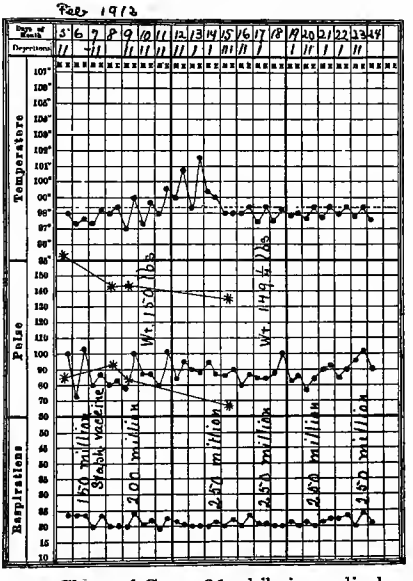

Fig. 232.—Chart of Case 286 while in medical wards.

100 and 110, but there was a systolic murmur and presystolic thrill at the apex. The thyroid gland was moderately enlarged on each side, and there was slight exophthalmos, slight tremor, and considerable moisture of the hands. Physical examination, including the urine, was otherwise negative. The patient was seen in consultation by Dr. F. C. Shattuck, who diagnosed a long-standing, well-compensated mitral stenosis, and was doubtful as to whether hyperthyroidism played any part. He thought the heart needed no treatment, but advised regulation of hygiene. As the patient had a hernia, a radical operation for this lesion and an appendectomy were done.

The appendix showed scar tissue with obliteration of the lumen. It was adherent to the hernial sac and formed a part of it. The whole operation was done under local anesthesia and caused at the time no considerable shock. About six hours later the patient vomited and the pulse began to rise, so that next day it reached 140. No cause for temperature was found, but the amount of exophthalmos was slightly increased for about a week after the operation. On the 5th of February he was transferred to the medical service, where his systolic blood-pressure was found to be 160 mm. Hg.; diastolic, 85 mm. Hg. (Fig. 232).

Despite careful questioning, no evidence of any cause for endocarditis could be found, and it was learned that palpitation on exertion and emotion had been noticed for at least twelve years. The palpitation has at times been so great as to shake his bed at night, and was accompanied by great nervousness and sweating. At no time has he had any edema or cough. An occasional short presystolic roll was at this time heard. The apex was 2 cm. outside the nipple line, in the fifth space. The aortic second greater than the pulmonic second. Pulse tracings showed an absolute arhythmia, but no evidence of tricuspid insufficiency. This arhythmia persisted after atropin, subcutaneously, $\frac{1}{100}$ gr., repeated in six hours. He had occasional spells of tachycardia, in which the heart's rate would rise to 130 to 160.

Discussion.—I should not have inserted this case but for the fact that a distinguished clinician differed strongly from the diagnosis of goiter heart or thyrotoxicosis, which seemed to me clearly warranted by the facts. I have never seen a case of pure mitral stenosis in a man of thirty-three which produced a systolic blood-pressure of 160 mm. Hg. The presence of goiter tumor, unusual sweating, and slight exophthalmos seem to me to leave no considerable doubt as to the diagnosis. Whether or not he had mitral stenosis in addition to thyrotoxicosis I do not know. I am convinced that a presystolic murmur may exist in any type of enlarged heart, and not merely with aortic regurgitation, as described by Flint. That the murmur disappeared when the heart was slow does not furnish evidence either for or against mitral stenosis. Neither does the existence of absolute arhythmia exclude thyroid disease.

Outcome.—When the heart was slow no presystolic roll could be heard, and on the 24th of February he was discharged. A year later the patient reported that he still had tachycardia, but had been working steadily and holding his weight since June 1, 1912.

CHAPTER XVIII

TREMOR

TREMORS are classified as coarse and fine, the latter particularly characteristic of thyrotoxicosis. Coarse tremors are common to a great many states presently to be mentioned.

The commonest of all causes for tremor are *cold*, *nervousness*, and *fatigue*. After hard muscular work the hand shakes. In difficult situations the knees knock together. The only importance of such types is that we should take sufficient pains to exclude them when considering diseases in which tremor forms an essential element. One does not want to condemn a person as alcoholic or burdened with thyroid disease merely because the hand shakes from apprehension or tire. One must be sure that the psychic conditions are understood and that we are getting a fair sample of the patient's muscular condition.

In *old age* there is a tremor, especially of the head, which does not connect itself with any known pathology and must be distinguished from the much more serious conditions of the nervous system to be mentioned below. The diagnosis of senile tremor depends on the exclusion of all causes except senility and the absence of the associated symptoms of paralysis agitans. It is often seen in arteriosclerosis, but there is no proof of an etiologic connection.

The tremor of *alcoholism* is coarse and irregular. It appears especially in the morning hours, when alcohol is suddenly taken away or when the person is sobering up; in other words, under the same conditions which produce alcoholic delirium or the trembling delirium (delirium tremens). It sometimes has the characteristics of an intention tremor, but can be controlled to some extent by the will.

In *Graves' disease* (*thyrotoxicosis*) the tremor is more rapid and of shorter excursion than in any other condition that I know. It is often to be recognized only when the fingers are extended and spread apart. It is present constantly, although it may be accentuated by temporary causes of nervousness. It is seldom bad enough to interfere with the ordinary use of the hands. It may be an early or a late symptom of the disease, but should always be looked for in doubtful cases.

Parkinson's disease, or *paralysis agitans*, is the next most common cause of tremor. It usually appears first in the hands and produces peculiar movements of the thumb and first two fingers, which have been compared to pill rolling or bread crumbling. It is a relatively slow and coarse tremor, and although it begins in the hand, may spread upward, in the course of time, to involve the arms, head, and even the legs. It is increased by excitement, but can generally be lessened by voluntary effort. Its diagnosis depends upon the presence of the associated symptoms of the disease, especially the muscular rigidity, the bent and rigid carriage, the mask-like, expressionless face, and general muscular weakness.

Lead-poisoning occasionally produces tremor, in connection with other evidences of neuritis. The same is true of mercurial-poisoning and of most of the drug habits, such as morphinism, cocainism, etc.

In *multiple sclerosis* and other cerebral, as well as spinal, lesions we have an intention tremor, that is, one which is more marked when the patient tries to use the muscles or is made worse by voluntary effort. In multiple sclerosis such a tremor is often associated with nystagmus and disturbances of speech, which render it slow, segmented, or staccato; also a spastic type of paralysis. The disease presents a great variety of types depending on the varying distribution of the lesions.

Case 287

A choreman of fifty-three entered the hospital February 22, 1910. The patient's family history is negative. He had "pleurisy and pneumonia" on the left side eight years ago. He takes "two glasses of beer a day and an occasional whisky." Four weeks ago a freight elevator fell on him, striking his head, but not injuring him in any other way. The scalp wound healed in ten days, but since the injury he has had a dull pain running from the nape of the neck along the shoulders, intensified by any sudden movement of the head. The appetite has been poor for a long time and he has not worked since the accident. His sleep has been very poor.

Physical examination showed good nutrition, subnormal temperature (Fig. 233), *and a marked coarse tremor of the hands.* The heart's apex extended 1 cm. outside the nipple. The pulmonic second sound was accentuated. There were no murmurs. The brachial arteries were tortuous and pulsated visibly. Systolic blood-pressure, 165. Urine negative. White cells, 20,000, with a polynuclear leukocytosis; hemoglobin, 90 per cent. There was slight dulness and decreased breathing at the left apex, posteriorly. Abdomen showed

Tremor

SENILITY
COLD
NERVOUSNESS
EXHAUSTION
} CASES TOO MANY AND TOO VAGUELY ENUMERABLE FOR GRAPHIC REPRESENTATION

nothing abnormal. The night after entrance he became belligerent and thought he had been wronged by another patient.

Discussion.—The fact that the patient has not worked since his accident and has not been able to sleep well should make us very suspicious of alcoholism, no matter what the patient himself says on the subject. Workingmen of fifty-three do not suddenly acquire insomnia from the ordinary causes affecting nervous and highly civilized people.

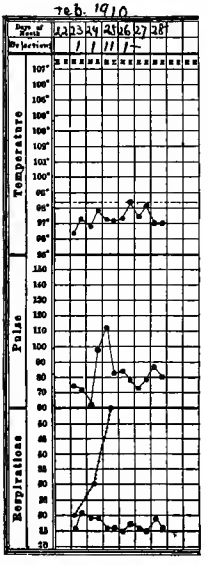

Fig. 233.—Chart of Case 287.

The behavior of the patient in the hospital, the appearance of cerebral symptoms in the evening, gives the support to the suspicion of alcoholism, and makes us pretty certain that he has taken a good deal more than two glasses of beer a day and an occasional whisky.

There may be a certain element of traumatic neurosis in the case. In such conditions tremor is frequent, but it is more probable that the alcoholism is the dominant factor.

Obviously, the patient has some arteriosclerosis, but this has probably no relation to the tremor.

Outcome.—The next morning he was apparently rational. *X*-ray examination of his neck was negative. He left the hospital on the 28th, after a negative examination by an alienist.

Case 288

A housewife of fifty-one entered the hospital July 23, 1910. The patient was recommended from the Out-patient Department for tremor, edema of the legs, and slight chronic arthritis. Ten years ago she was in bed four weeks with intense jaundice, but no pain. During the two years following this she suffered from frequent attacks of epigastric pain, lasting several hours. Five years ago she had typhoid fever and was in bed four months. She passed the menopause seven years ago.

Sixteen months ago she woke too weak to get up, and remained ten weeks in bed with what the doctor called "nervous prostration." Since that time she has been about the house daily, but has suffered much pain in both hips. During the last few months her hands have trembled.

The pain has prevented good sleep, and she has taken always $\frac{1}{4}$

gr. codein, which produces about two hours' sleep. The appetite is fair. The bowels move every other day. She has lost no weight.

On physical examination, the patient is very poorly nourished and sallow. Pupils normal. Internal viscera normal. Knee-jerks and plantars normal. Achilles reflexes not obtained. Marked Kernig's sign bilateral. The neck is held stiffly, bent markedly forward and to the right. All the muscles are spastic. The hip-joints are sore on motion, the knees slightly so. There is well-marked intention tremor of the hands and considerable tremor of the legs when attention is directed to them. The back is stiff and shows a lateral curvature, most marked in the lower thoracic region, with a convexity to the left. The range of the temperature is shown in Fig. 234. The urine averaged 35 ounces in twenty-four hours. It was always turbid and acid, with a specific gravity of 1023. Negative sediment. The blood was normal. Systolic blood-pressure, 105. The patient went home on the 28th.

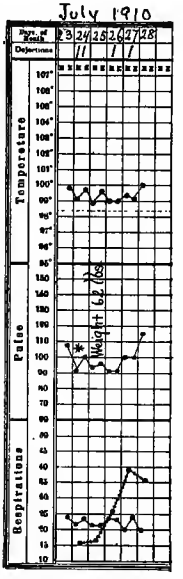

Fig. 234.—Chart of Case 288.

Discussion.—The case is obviously one of Parkinson's disease, and is here introduced to call attention to the fact that pain and other joint symptoms may be very prominent in the clinical picture of paralysis agitans. At the time of this patient's examination in the hospital there was actually no tremor at all, and one must be prepared to recognize the disease in the absence of this symptom, paying especial attention to the expression of the face, the stiffness of the neck and back, and the peculiarities of the gait.

Note that the doctor made a diagnosis of nervous prostration only sixteen months ago, a diagnosis which, of course, is never correct when its symptoms originate in a person of forty-nine.

Case 289

A foreman in a hay and grain house, forty-four years old, entered the hospital July 28, 1910. The patient's family history is negative. Nineteen years ago he had "sciatic rheumatism" for three weeks; otherwise was well and strong until the present illness. March 1, 1909, he had a severe sore throat with a peritonsillar abscess. Just after this he ate some well-done pork at a restaurant. Seven hours later he felt dopy. Twenty hours later he noticed a rash all over his body.

This rash lasted ten days and was accompanied by a tough swelling of the skin, suggesting myxedema to his physician. He desquamated in large pieces, but did not feel sick, and March 15th went back to work. April 20th he began to feel pain and tenderness in his elbows and his groins, and his doctor found tenderness along the ulnar side of each arm. April 24th *his hands began to shake*; so that on the 27th he had to quit work and has not been able to resume it since.

Gradually numbness crept up his arms until they were paralyzed. Then the legs became powerless. There was much paresthesia, but no anesthesia and no involvement of sphincters, speech, or swallowing. The power has gradually returned in his arms and partially in his legs, but he cannot straighten his knees.

In other respects his health is good, but he has lost about 20 pounds. He knows of no exposure to lead.

Physical examination showed a rather obese patient, with normal pupils, and nothing remarkable about his internal viscera. Knee-jerks, ankle-jerks, and plantars were absent. Cremasterics present on both sides. Abdominal reflexes not obtained. There was practically no motion below the knees and a moderate contraction of the hamstring muscle. No toe-drop. Motions of the left hand were fair, but rather weak. The little finger moderately contracted. The right hand was moderately abducted from the forearm and the fingers were in the position of a typical claw-hand. The grasp was weak, and there was considerable atrophy in this and in the other hand, especially at the base of the thumb. Sensation of touch was delayed and inaccurate in the feet, fair in the legs and hands, good in the rest of the body. The extensor muscles of the arms and hands reacted to galvanism, but a strong faradic current was necessary to produce any reaction. All electric reactions were absent in the perineal muscles. The Wassermann reaction was positive.

The patient was given Zander exercises, electric-light baths, and massage, and by August 6th could stand on his feet. August 13th he could take a few steps with help. An orthopedic consultant advised tenotomy of the hamstrings, but under Zander treatment his legs were considerably straightened by the 30th. By September 7th the patient had shown very marked improvement and was transferred to the neurologic wards, where a slight edema, duskiness, and coolness of the feet were found.

Discussion.—In view of the positive Wassermann reaction in this case, it seems to me that the diagnosis of peripheral neuritis, made at the time of his stay in the hospital, is a very doubtful one. It must be

admitted that the physical signs and condition of the reflexes support the diagnosis of a neuritis, but, in the absence of any of the known causes of such a lesion and the presence of a Wassermann reaction, it seems to me doubtful whether the disease is confined to the peripheral nerves.

At the beginning of the illness there were some etiologic suggestions which deserve a moment's comment. Peritonsillar abscess is a cause of many other manifestations of infection and toxemia, but I know of no good evidence for connecting it with nervous symptoms of this type. The same may be said of his initial rash and dull mental state following the eating of pork. What this illness was I have no idea. It surely cannot have been beriberi or myxedema.

On the whole, I must admit that the condition is by no means a clear one, though I incline to the opinion that syphilis is at the bottom of it.

Outcome.—September 26th he was able to walk alone and had moderate strength in his left hand. December 2, 1912, the patient's physician writes that he can now walk without cane or crutches, though he still has toe-drop and some deformity and weakness in the hands.

Case 290

A chair-caner of seventeen entered the hospital December 6, 1910. The patient came in because of a twitching of the left arm. While waiting in the anteroom for examination she was heard screaming and was brought in in the arms of the nurse, apparently comatose, with face bluish, foam on the lips, and irregular jerking motions of the arms and legs. The pupils and knee-jerks responded normally.

She remained unconscious about fifteen minutes, though opening her eyes occasionally without looking round. The subcutaneous injection of $\frac{1}{20}$-gr. apomorphin caused slight nausea and a renewal of consciousness.

The patient says that she has had similar attacks at irregular intervals for the last four years, though sometimes she has gone a year without any, and again she would have them every week or two. They last fifteen or twenty minutes, begin with vertigo, then headache, then loss of consciousness. After such an attack she has to lie down for an hour or more and feels very weak. A year ago last November she had an attack on an electric car, and stayed a week in the City Hospital thereafter.

Two weeks ago blood was taken from her left arm for examination. The next morning the arm was twitching when she awakened, and ever

since then, as she sits in a chair, the left arm and shoulder are agitated by a constant tremor, which slightly shakes the whole body, while the left shoulder is drawn down. There is a slight limp in the left foot.

Physical examination shows well-marked left hemianesthesia. The tremor involves chiefly the latissimus dorsi. The anesthesia is not marked upon the trunk or face, but is most striking in the foot and arm. The grip of the left hand is very feeble. Both knee-jerks are exaggerated, the left more than the right. No plantar reflexes obtained upon the left. The left ankle-jerk is exaggerated.

No notes of treatment were made during the five weeks of the patient's stay in the hospital, during which she passed through an attack of acute tonsillitis and two menstrual periods. The bowels were decidedly constipated, several days often passing without any movement.

Discussion.—The initial attack, as described, might be either hysteric or epileptic, although the fact that she opened her eyes occasionally and that apomorphin brought her to consciousness are items strongly in favor of hysteria.

It is easier to interpret the attack when we study the later phases of her trouble and the physical examination. Hemianesthesia with exaggeration of both knee-jerks and a tremor of the arm following immediately upon the extraction of blood for examination makes a clinical picture strongly confirming the previous suspicion of hysteria. Weir Mitchell has described similar cases, especially one classical and spectacular instance in which later a careful autopsy showed absolutely no lesion—macroscopic or microscopic.[1]

Case 291

A man with no occupation, thirty-three years of age, entered the hospital June 29, 1912. The patient's family history is excellent. He had the ordinary children's diseases, and beginning at seven years old had five severe attacks of rheumatic fever, the last one four years ago. Since that time he has noticed palpitation on exertion or excitement, and occasionally slight dyspnea. He denies venereal disease and alcohol.

Four years ago, after being in bed three months with rheumatic fever, he noticed that his hands trembled and made uncertain irregular motions when he used them, though there was no paralysis or disturbance of sensation. He also finds himself weak and unsteady on his feet and can get about only with crutches. Four years ago his

[1] Transactions of the Association of American Physicians, 1904, p. 433.

speech was very thick and unintelligible. He knew what he wanted to say, but could not pronounce the words correctly. For the last two years he has been training himself in speech, with considerable improvement as a result. He can now also write, paint, and do basket-work, and has no trouble in dressing himself. He still has to use crutches. He has no pain, no vertigo, and no ocular disturbance. For a short time, three years ago, he had slight incontinence of urine, but that soon passed off and has not recurred.

Physical examination showed good nutrition, slight cyanosis, normal pupils, knee-jerks equal and lively, plantars and cremasterics normal. Superficial abdominal reflexes not obtained. All motions of the trunk and arms are awkward and uncertain and accompanied by a coarse, irregular tremor, not fibrillary in character. No wasting. Grips strong and equal. Head held to the left, mouth slightly drawn to the right. Tongue protruded slightly to the right. Speech slightly thick, but not scanning. No nystagmus. The fundus oculi normal. A neurologic consultant was in doubt between hysteria and multiple sclerosis. Wassermann reaction negative. Blood and urine negative. No fever in ten days' observation. Systolic blood-pressure, 180 mm. Hg.; diastolic, 60 mm. Hg. By lumbar puncture a few cubic centimeters of clear fluid were obtained, not under pressure.

The cell-count was 3 per centimeter.

The heart's apex was seen and felt in the sixth space, 5 cm. outside the nipple line. There is a slight presystolic thrill at this point and a faint presystolic murmur, ending in a loud first sound and a loud systolic murmur. At the aortic area and along the left sternal border a diastolic murmur is heard. The pulmonic second is greater than the aortic second, which is very faint.

Pulses markedly Corrigan in quality. Capillary pulse present. Lungs, abdomen, and extremities normal. The patient remained in the hospital ten days and left without any considerable change in his condition.

Discussion.—The patient has all the evidences of rheumatic or streptococcic endocarditis, with mitral stenosis and probably aortic regurgitation and stenosis. It is not probable, however, that the present condition of the hands has any direct connection with the rheumatic infection. We note that the ataxia and tremor of the hands is associated with disturbances of speech and of gait. The spasticity often seen in multiple sclerosis is not present.

As in many cases, the diagnosis is in doubt between hysteria and

multiple sclerosis. Some of the most classical and disastrous diagnostic mistakes that I have known have been those in which the physician called the case hysteria and treated it accordingly, when the march of time demonstrated the presence of an incurable organic disease, multiple sclerosis. In this case the nature and duration of the trouble with speech, the transitory attack of urinary incontinence, the muscular abnormalities in the head, face, and tongue, incline us to believe that organic disease is present. It is very improbable that a man would begin to be hysteric at twenty-nine.

Paresis and other postsyphilitic diseases of the nervous system may be excluded by the negative Wassermann reaction and the low cell-count in the spinal fluid.

We have no grounds for suspecting multiple neuritis. Under these conditions the diagnosis of multiple sclerosis seems to be the most defensible

CHAPTER XIX

ASCITES AND ABDOMINAL ENLARGEMENT

I RECENTLY made a series of wrong diagnoses in cases of ascites. These failures, which were shared by some of the best diagnosticians in the country, suggested to me a study of the causes of this symptom. Until recently I had supposed that the diagnosis of the causes of ascites was one of the easiest in medicine. I was amazed to hear Dr. Rolleston say, in 1909, that he considered the diagnosis of cirrhosis a very difficult one; but in the light of recent events I have come to agree with him. To minimize the number of future mistakes, I have in this chapter endeavored:

1. To tabulate from the autopsy records of the Massachusetts General Hospital the actual causes of ascites as found postmortem in 2217 autopsies (Chart I).

2. To tabulate the clinical diagnoses of ascites made at this hospital in the last forty years. Some of these diagnoses have been verified by operation or autopsy. A larger number rest on clinical evidence alone, but in most of the more dubious and more interesting cases we have operative or postmortem knowledge of the actual condition (Chart II).

3. To tabulate the *rates* at which ascites accumulates in different diseases. Possibly these latter facts may be of some assistance in identifying through its more or less characteristic *tempo* of accumulation the ascites of tuberculous peritonitis (Chart V).

4. To relate some of my failures and discuss the possibilities of better success in the future.

Chart I shows the causes of fluid as found in the peritoneum in 2217 cases *at autopsy*. A quart or more of fluid was present in all these cases. Cases of septic peritonitis and hemoperitoneum are omitted; 88 per cent. of the remaining cases are due, as was anticipated, to one of five causes: *Cardiac weakness*, *nephritis*, *abdominal neoplasms*, *cirrhotic liver*, and *tuberculous peritonitis*.

I am uncertain whether the cases of adherent pericardium (all of which were associated with extensive peritoneal thickening) should be classed with the cases of cardiac weakness or with those of chronic

Causes of Ascites as Found Postmortem in 2217 Autopsies

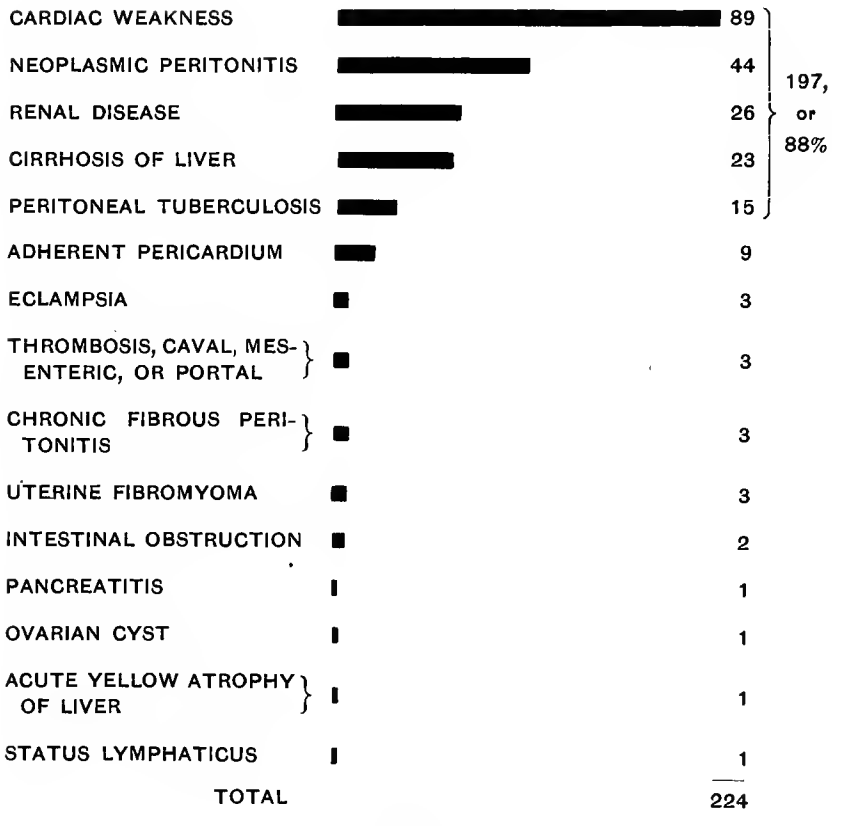

Chart I.

Relative Frequency of the Common Causes of Ascites

From the Clinical Records of the Massachusetts General Hospital, 1870–1910

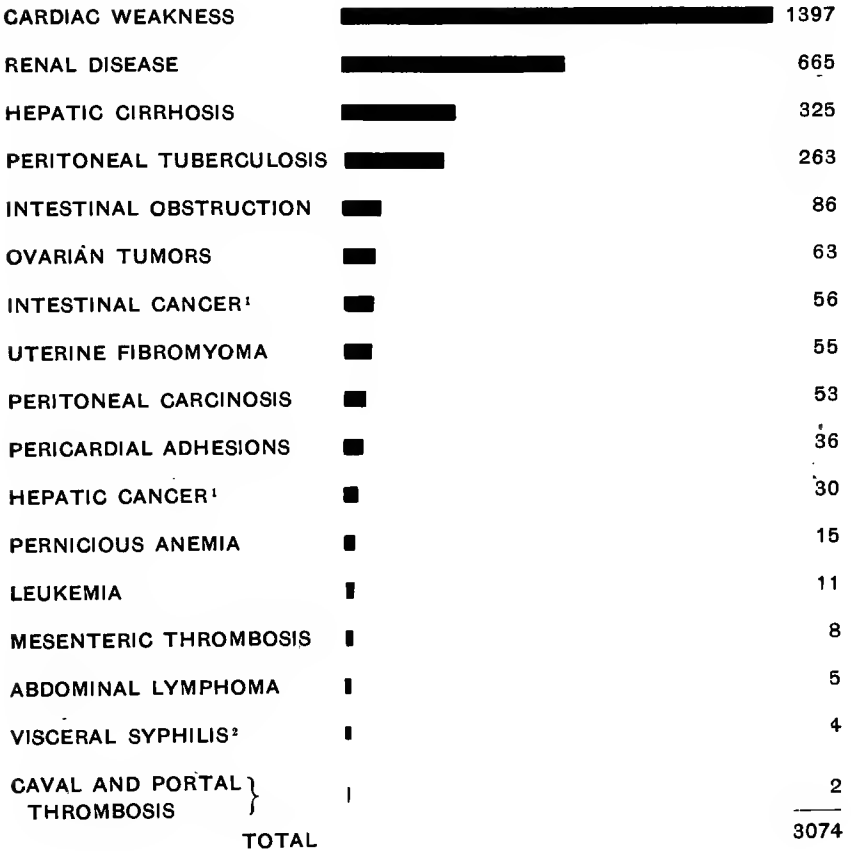

[1] With glandular metastases.
[2] Hepatic, splenic, etc.

Chart II.

Percentage of Cases of Ascites Found in 5001 Cardiac Cases Observed Clinically

MASSACHUSETTS GENERAL HOSPITAL, 1870–1910

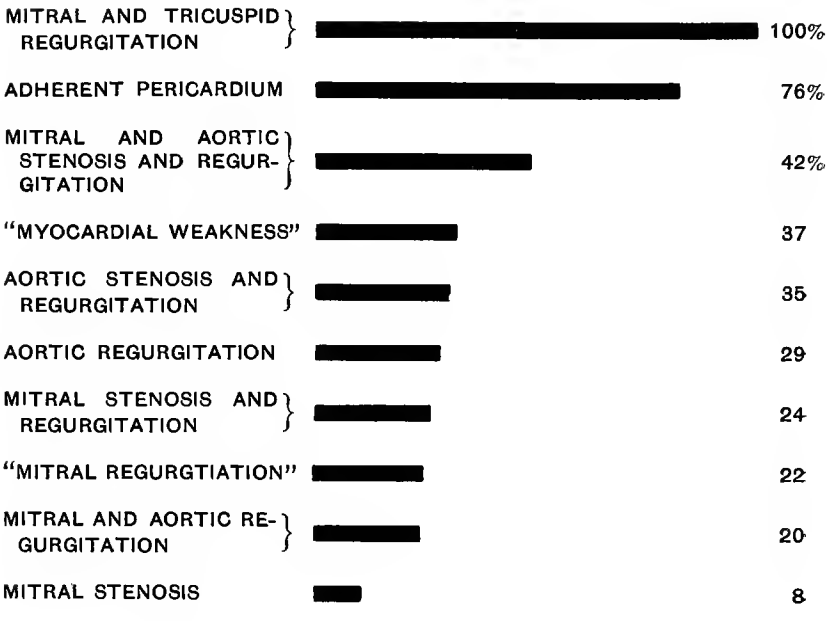

Chart III.

Percentage of Ascites Found Among 10,195 Cases of the Diseases Which Produce This Symptom

MASSACHUSETTS GENERAL HOSPITAL, 1870–1910

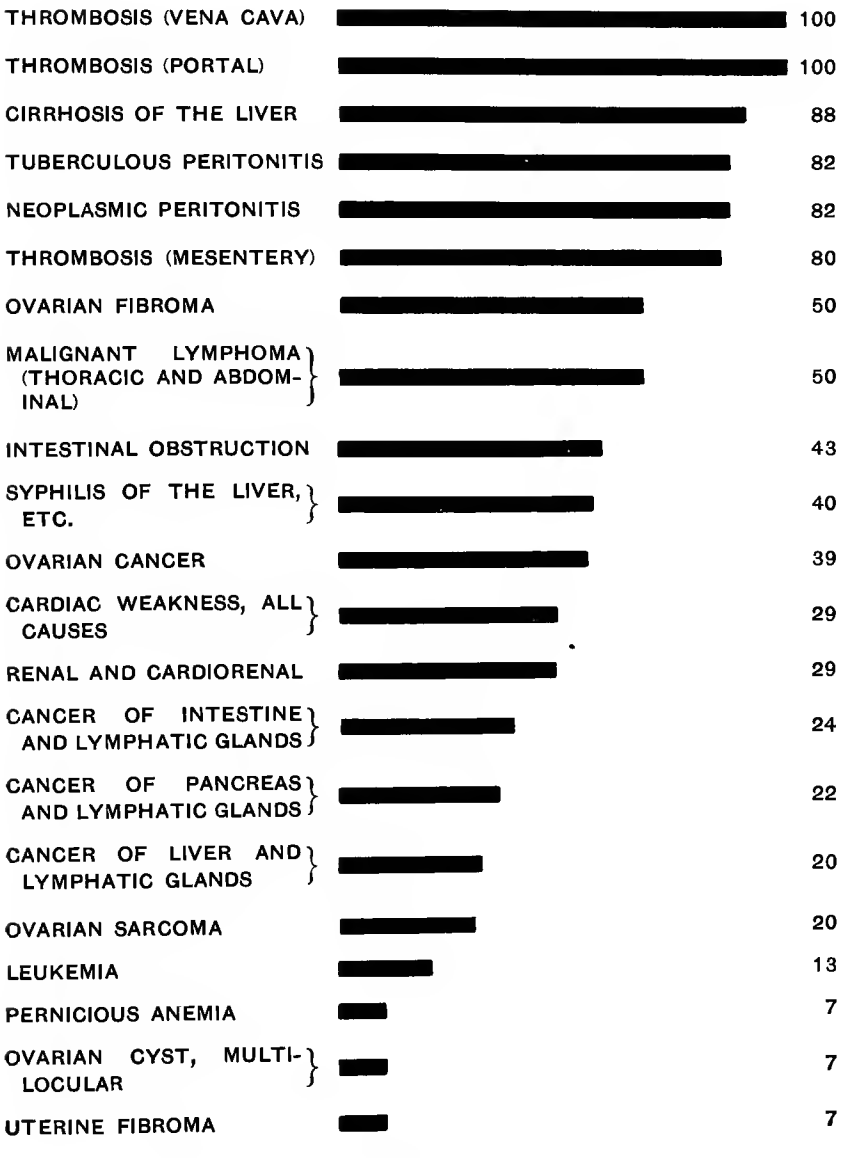
THROMBOSIS (VENA CAVA) 100
THROMBOSIS (PORTAL) 100
CIRRHOSIS OF THE LIVER 88
TUBERCULOUS PERITONITIS 82
NEOPLASMIC PERITONITIS 82
THROMBOSIS (MESENTERY) 80
OVARIAN FIBROMA 50
MALIGNANT LYMPHOMA (THORACIC AND ABDOMINAL) 50
INTESTINAL OBSTRUCTION 43
SYPHILIS OF THE LIVER, ETC. 40
OVARIAN CANCER 39
CARDIAC WEAKNESS, ALL CAUSES 29
RENAL AND CARDIORENAL 29
CANCER OF INTESTINE AND LYMPHATIC GLANDS 24
CANCER OF PANCREAS AND LYMPHATIC GLANDS 22
CANCER OF LIVER AND LYMPHATIC GLANDS 20
OVARIAN SARCOMA 20
LEUKEMIA 13
PERNICIOUS ANEMIA 7
OVARIAN CYST, MULTILOCULAR 7
UTERINE FIBROMA 7

Chart IV.

peritonitis. Of the other items in the list, the one most surprising to me is puerperal eclampsia.

CLINICAL STATISTICS OF ASCITES

In some of the cases arranged in Chart II the diagnosis was verified by operation or autopsy. This was the case with all the neoplasms and thromboses, and with most of the cases of intestinal obstruction and tuberculous peritonitis; but in the cardiac, renal, and hepatic cases, and most of the blood diseases, the evidence is wholly clinical.

Points of interest in this column are: (*a*) The frequency of ascites with ovarian cysts and tumors (see below, Chart VI), and (*b*) the large figures obtained in intestinal obstruction. Probably in a considerable number of these cases the fluid may have been due to actual peritonitis associated with the obstruction.

In this chart all the unstarred items represent cases actually studied in the original clinical record. The items which are starred were calculated as follows:

Throughout an eight year period I determined, by study of the clinical records, the percentage of ascitic cases among all the cases of cardiac and renal disease. These positive percentages were then applied to the total number of cases of each disease, as shown by a count of the cards in the card catalogue (1870–1910). The starred items are, therefore, only approximately accurate.

CHART V

Disease.	No. of cases.	Rate of ascitic accumulation. Ounces per day.
1. Cardiac weakness	2	36–54
2. Cirrhosis of the liver	16	20
3. Chronic nephritis	5	13
4. Solid tumors of ovary	2	12
5. Neoplasms of the abdominal organs and glands	4	11
6. Adherent pericardium (before cardiolysis)	2	11
Adherent pericardium (after cardiolysis)	1	2
7. Uterine fibroid	2	8–11
8. Tuberculous peritonitis	15	5– 6

Chart V requires little explanation. The number of ounces of fluid between two exhaustive tappings is divided by the number of days intervening. There is a chance for error here, in that the tappings, which were supposed to empty the peritoneal cavity, may, in fact, have left some fluid behind; but I do not think that this error is sufficiently serious to interfere with my results.

ASCITES WITH SOLID TUMORS OF THE OVARY

1. *Cancer of the Ovary.*—Fifty-four cases are on record at the Massachusetts General Hospital between 1870 and 1910. In 6 of these there was no operation or autopsy. Of the remaining 48, there were 19 cases (40 per cent.) in which a considerable amount of ascites was found.

2. *Fibroma of the Ovary.*—Twenty well-recorded cases are to be found in our records. In 10 of these (50 per cent.) ascites was well marked at the time of operation.

3. *Sarcoma of the Ovary.*—Five cases, 1 with ascites.

ASCITES WITH CYSTIC TUMORS OF THE OVARY

There were 391 cases operated upon at the Massachusetts General Hospital (1870–1910) for multilocular ovarian cyst. In 31 of these (7.9 per cent.) ascites was well marked at the time of operation. In 8 of these 31 the fluid was bloody or chocolate colored. In 1 the amount of serum was measured at 17 quarts.

ASCITES WITH UTERINE FIBROMYOMA

Among 723 cases operated upon for fibroid of the uterus, 55 cases (7 per cent.) showed ascites. This was of small amount in 18 cases (2.4 per cent.); of large amount in the remaining 37 (4.6 per cent.).

In 10 of the 55 cases the fluid was bloody, in 2 others it was purulent.

In Chart VI the relation of ascites to the different varieties of ovarian tumor is demonstrated. All these cases were operated on. I think many persons will be surprised, as I was, to learn how frequent is the association of ascites with benign ovarian growths such as fibroma and multilocular cyst. I have no idea why a small ovarian fibroma without metastases should produce extensive ascites so frequently.

Why should a small percentage (7.9 per cent.) of cystic tumors produce ascites? One would expect to find it in all cases or in none.

CHART VI.—*Percentage of Ascites Occurring in the Different Varieties of Ovarian Tumor.*

Diagnosis.	No. of cases.	Ascites found at operation in—
Ovarian fibroma	20	50 per cent.
Ovarian cancer	54	40 "
Ovarian sarcoma	5	20 "
Ovarian cystoma	391	7.9 "

Among 14 cases operated upon for *parovarian cyst* no ascites was found in any.

Case 292

A housekeeper of forty-eight entered the hospital July 17, 1909. She entered with a diagnosis from the Out-patient Department of "ascites, cause unknown." Nephritis, malignant disease, tuberculosis, and adherent pericardium were suggested. Family history negative. The patient has always been delicate, and when six years old was pronounced tuberculous and sent to the country, with great benefit. Fifteen years ago she had a bad cough, with "ulcer in her throat" and loss of weight. She went to Vermont for two months, improved very much, and has been better ever since, though eight years ago she had a "nervous breakdown," and six years ago the glands in her neck became large and inflamed. They were opened and drained at the Homeopathic Hospital. Following this operation the left arm became stiff and paralyzed, though the power gradually returned afterward. She has never been strong since then.

When first married she had two miscarriages, no children. Fourteen months ago she passed the menopause without incident. *A year ago her face began to be swollen, and soon after that a swelling was noticed in the abdomen.* Four months ago the legs became swollen, but the feet did not swell until two months ago. Five weeks ago she had to take to bed. She has had no pain, save an occasional "catch" in the lower right chest, which she has had on and off for years. She is gaining in weight, but thinks she has lost flesh. She has had no cough.

Physical examination showed poor nutrition, pupils slightly irregular, otherwise normal. Heart negative, impulse shifting 1 cm. with change of position. All the evidences of fluid in the abdomen. Normal reflexes. On the 18th the abdomen was tapped. Five pints of fluid were obtained, pale, opalescent, 1008 in specific gravity, with a sediment containing 85 per cent. small lymphocytes. After tapping the edge of the liver could be plainly felt, sharp, hard, and apparently not irregular. The blood, urine, and blood-pressure were all normal. The patient had no fever in two weeks' observation. The Wassermann reaction was negative. The fluid rapidly re-accumulated. Examination of the stomach with a stomach-tube showed nothing abnormal.

Discussion.—On the 25th of July I summed up the evidence as follows: "Neoplasm seems the most probable diagnosis, although there are no masses or pressure symptoms nor any organ markedly depressed in function. The urine is not characteristic of any type of nephritis,

and the absence of cardiac enlargement, high blood-pressure, and uremic symptoms make nephritis unlikely as a cause of the ascites.

Tuberculous peritonitis seems unlikely, since there is no fever, no local tenderness or spasm, and since the fluid has re-accumulated so rapidly. Cirrhosis is possible, but improbable, on account of the absence of alcoholic history, the rapidity of the re-accumulation, and absence of toxemia. The patient certainly looks cancerous."

On the 27th the patient was transferred to the surgical service and the abdomen opened. A large amount of ascitic fluid was evacuated, but the exploration showed nothing abnormal in any part of the abdomen except a few hard white nodules, the size of peas, in the liver. One of these was excised and examined by Dr. Maurice H. Richardson, who made a diagnosis of "cirrhosis of the liver." There were contracted places in the liver, suggesting scars. The diagnosis recorded on the surgical history is "syphilis of the liver." The patient was transferred to the medical side and was given mercurial inunctions and iodid of potash. Nevertheless the abdomen rapidly refilled; 6 quarts were removed on the 19th and 5 quarts on the 23d. The character of the fluid was essentially that previously reported.

Outcome.—She left the hospital September 1st and died September 4th. Hepatic cirrhosis of syphilitic origin seems, on the whole, the most reasonable diagnosis.

Case 293

A housewife of twenty-seven entered the hospital November 15, 1909. Five months ago the patient began to notice soreness in the lower abdomen, which soon after swelled, and has since grown steadily and rapidly in size. Except for this she has had practically no symptoms, though occasionally she vomits. Her appetite is good and her bowels regular. Her menstruation is normal, but she has lost considerably in weight and strength. Five months ago she weighed 158 pounds; now, 132 pounds. Nevertheless, she is not emaciated even now. Her family history and past history are excellent.

Physical examination was negative except as relates to the abdomen, which showed shifting dulness in the flanks. Blood showed 75 per cent. hemoglobin and slight achromia in the smear. Urine negative. No fever. On the 17th $9\frac{1}{2}$ quarts were removed from the abdomen, and after this tapping a mass the size of an orange could be felt low down on the right side of the abdomen. It was not tender, and suggested the feel of a closely packed bunch of grapes. A similar but smaller mass was felt on the left. The mass was easily felt bimanually

on each side of the uterus, which itself seemed normal. The tap fluid was greenish yellow, opalescent, alkaline, 1019 in specific gravity, 4.4 per cent. albumin, with 63 per cent. endothelial cells, 33 per cent. lymphocytes, and 4 per cent. polynuclears in the sediment.

Discussion.—The clinical picture is of slight anemia and ascites in a woman of twenty-seven. Nothing definite could be said until after tapping, which showed a high gravity fluid such as we should expect in neoplastic peritonitis or tuberculosis of the peritoneum. Between these two diseases the mass felt low down near the pelvis should make us strongly favor neoplasm. It is true that tuberculous peritonitis may produce abdominal masses, but they are rarely in this situation. Moreover, we have no fever and nothing in the family history or previous history to suggest tuberculosis. The diagnosis, therefore, should be of a pelvic neoplasm, which in this situation is almost certainly of ovarian origin. Whether it is benign or malignant only histologic examination can decide.

Outcome.—At operation, November 20th, the uterus and appendages were found bound up in one large mass of tissue, resembling that of a papillary cyst adenoma. The whole mass, including the uterus, was removed. Examination showed both ovaries cystic, with numerous papillary outgrowths, some of which are growing freely from the peritoneal surfaces. Microscopic examination showed a fibrous structure in papillary form, the surface of which was covered by a single layer of rather long cylindric epithelial cells. Diagnosis, papillary cyst adenoma. The patient did well after operation, left the hospital December 9th, and a year later, December 13, 1910, seemed to be entirely well.

Case 294

A barber of forty-nine entered the hospital April 18, 1910. The patient's father died of paresis at forty-seven, after an illness of three years. His mother died of cancer of the breast. His wife has had tuberculosis and has been in a sanitarium fifteen months for it.

The patient himself has never had a sick day until February 5, 1910, when he had a chill, followed by severe pains in his neck and breast-bone, with slight cough and fever. He was in bed four weeks, and after he had been up a few days his feet and legs began to swell and he began to be short of breath. Both these symptoms have steadily increased since, and he has had to sleep in a steamer chair for more than a month. For two weeks he has had a slight cough, but he no longer

has any pain. Three weeks ago he began to notice enlargement of his abdomen.

On physical examination, the patient was obese, skin pale and cyanotic. Heart's impulse felt in the fifth space, 3 cm. outside the nipple line, the right border dulness 4 cm. from midsternum. Sounds feeble, rapid, regular, no murmurs or accentuations. Systolic blood-pressure, 155 to 180 during the week of his stay in the hospital. The lungs and abdomen as shown in Figs. 235, 236. Spleen never felt. The whole body is more or less edematous, the legs especially showing a

Fig. 235.—Physical signs in Case 294.

hard, brawny swelling. The abdomen was tapped on the 18th and 1600 c.c. of canary-yellow turbid fluid obtained. Specific gravity was 1017; albumin, 1 per cent. Sediment contained 90 per cent. of small mononuclears, 2 per cent. polynuclears, the remainder of the endothelial type. On the 20th there was intense bronchial breathing in the left back, suggesting a pressure area as in pericarditis or hydropericardium. The whispered voice was much increased and there was egophony.

The patient remained afebrile and fairly comfortable during the day,

but was very dyspneic and a little delirious at night, especially when he slipped down off his bed-rest. The urine examined at entrance showed about 6 per cent. of sugar and 0.1 per cent. of albumin. The amount was not increased and averaged 35 to 45 ounces, and the sediment showed only an occasional hyaline or granular cast. The blood showed 13,500 leukocytes. The sugar output per day varied between 30 and 50 gm. The Wassermann reaction was positive. A culture from the ascitic fluid was negative.

On the 23d he had a fairly comfortable day, though he dozed a good deal. On the night of the 24th he suddenly became cyanotic and pulseless, and within an hour was dead. There was no autopsy.

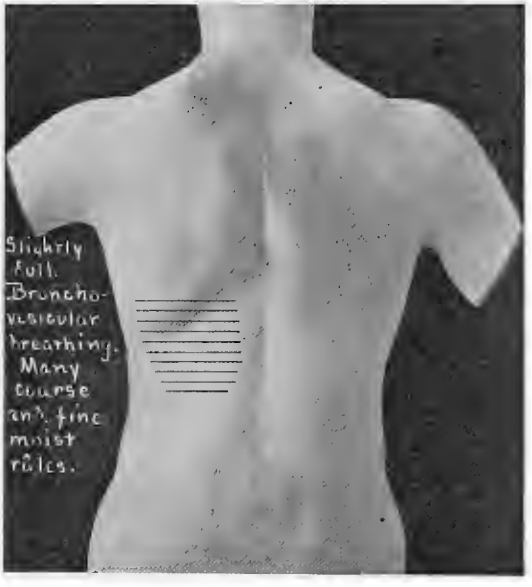

Fig. 236.—Physical signs in Case 294.

Discussion.—The family history is variegated and interesting, but not of special significance, so far as I see, in connection with the present symptoms of the patient, which point to a postinfectious cardiac trouble associated with hypertension.

The specific gravity of the tap-fluid is not like that of an ordinary dropsy. On the other hand, the amount of albumin is smaller than that which we expect in fluid of any other kind. With a positive Wassermann reaction any such cardiac weakness should be regarded as very possibly syphilitic, especially as we have no conclusive evidence of any other type of heart trouble.

The condition of the urine is perfectly consistent with this hypothesis. We may suppose, then, that he has a syphilitic nephritis and myocarditis; possibly also a syphilitic hepatitis. A similar affection of the pancreas might be conjectured as a reason for the glycosuria. Yet surely he did not die of diabetes. The glycosuria was only a minor item in his trouble.

I am also quite sure that he did not die of tuberculosis. The course of the illness is far too short and afebrile.

Malignant disease, too, may be clearly excluded. Just how far the lesions of the heart, kidney, and liver may have separately contributed to the accumulation of ascites it is impossible to say.

Case 295

A bricklayer of twenty-three entered the hospital November 30, 1910. Three of the patient's brothers died of Bright's disease, one sister of congenital heart trouble; otherwise the family history is good. The patient had a hard chancre last February, and was treated by inunctions of mercury, mercurial pills, and iodid of potash from April to October of the present year. In April he had a sore throat, loss of hair, swelling and tenderness of the cervical lymph-glands, and severe lumbar pains, the latter lasting two weeks and disabling him for that period from work.

Five weeks ago he noticed that his trousers were getting tight and his legs beginning to swell. In a week he could hardly walk because of the swelling. He gave up work and went to bed for a week, after which the swelling was reduced on a milk diet. He got up and the swelling then reappeared within a few days. Since then he has been in bed, off and on, without any permanent benefit. He never passes urine at night and, aside from the edema, has no symptoms, except three slight headaches within the past month and some dimness of vision in the last two days.

Physical examination showed normal pupils and reflexes, notable enlargement of the cervical, axillary, and epitrochlear lymph-nodes, which were hard, the smallest the size of a pea. The heart was negative and the lungs as in Fig. 237. Abdomen showed dulness in the flanks, shifting with change of position. The fundus oculi was normal. Urine during his eight weeks' stay in the hospital averaged 50 ounces in twenty-four hours, with a specific gravity of 1022. The amount of albumin varied between a large trace and 0.6 per cent. The sediment showed very large granular casts and a few hyalines. Systolic blood-pressure was never above 125 mm. Hg., usually 120 mm. Hg. or lower; at en-

trance, 110 mm. Hg. Blood was normal. Toward the latter part of his stay the number of casts in his urine decreased somewhat, but the albumin ranged between 0.4 and 0.7 per cent. Wassermann reaction was negative on the 7th and 12th of January. Daily hot-air baths and purgation with magnesium sulphate had, for the first ten days, no considerable effect upon the edema and ascites. No cardiac hypertrophy could be made out. By the 12th of December, 1910, the edema and ascites began to go down. The girth at the navel was then 87 cm.; on the 24th of December, girth 84 cm.; January 5th, 1911, girth 81 cm.

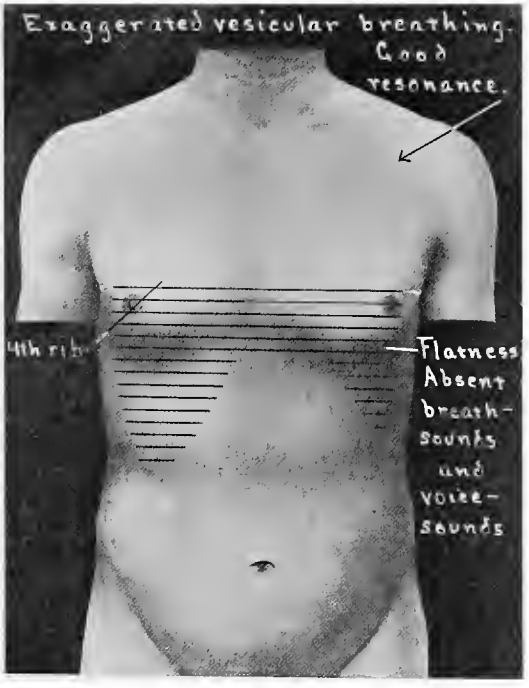

Fig. 237.—Physical signs in Case 295.

January 8th no demonstrable fluid in the abdomen. He noticed that he passed more urine whenever he stayed in bed.

Discussion.—When I studied this patient in the hospital I was amazed at the combination of low blood-pressure with obvious urinary evidence of nephritis. I did not at that time realize that the degenerative tubular lesions often associated with syphilis may produce just this combination of symptoms, the type of lesion classified by Volhard[1] as a *nephrosis*. As in the previous case, we may be in some doubt how

[1] Die Brightische Nierenkrankheit, von F. Volhard und Th. Fahr, von Julius Springer, Berlin, 1914.

much was contributed by the kidney and how much by the liver to the accumulation of ascites in this case.

Outcome.—January 17, 1910, girth 78 cm. January 22d, practically no edema, even when he is up and about. Is feeling considerably better and wants to go home. Accordingly he is discharged.

Two years later, January 2, 1913, he writes: "I have been steadily improving since I left the hospital. Last August when I took neosalvarsan I had my urine tested and there was a faint trace of albumin. Last week I had it tested again and there wasn't any albumin. I have taken salvarsan four times and seem to feel better after taking it."

The nephrosis may have cleared up or it may have reached the stage of "contracted kidney," which (according to Volhard) follows in some cases of this type, as well as in the glomerular and vascular types of disease.

Case 296

A woman of twenty-one entered the hospital June 15, 1911. The patient's father died of cancer of the stomach at sixty-two, otherwise the family history is excellent. She has had no previous illnesses until May, 1903, when she was much pulled down by an attack of mumps and whooping-cough, her cough lasting until July. Then she was well until September, when she noticed a painless enlargement of the abdomen, and three weeks later was tapped, 8 quarts being withdrawn. She was tapped three times more before March, 1904, when she went to the Boston City Hospital and had two operations, preceded by measles. The second operation was said to have been on the liver. The nature of the first one was not known. After that time she was tapped only about once a year, 12 to 15 quarts of clear yellow fluid being withdrawn each time. She has had at no time any pain and her bowels have been regular. She has lost no weight and has felt strong and well most of the time, though just before each tapping she has had some dyspnea and edema of the legs.

Physical examination showed good nutrition, very dry skin, marked dulness in the flanks, shifting with change of position, soft edema of the legs, flatness below the angles of the scapulæ, with diminished breath sounds and voice sounds. The apex impulse of the heart not made out, apparently displaced to the left and upward. A blowing systolic murmur was heard at the apex and transmitted over the precordia. The pulmonic second was accentuated. Knee-jerks were not obtained. Pupils normal. Urine normal at entrance and most of the time thereafter, though occasionally it contained a very slight trace

of albumin. Blood normal. Systolic blood-pressure, 120. Weight at entrance, 155 pounds; at discharge, six weeks later, 156 pounds.

A letter received from the Boston City Hospital stated that she was admitted there June 28, 1904, with a diagnosis of tuberculous peritonitis and operated upon June 29th, when considerable ascites was found, with a normal liver and spleen. Tubercles were found on the sigmoid flexure. The second operation, August 4th, showed nothing but a considerable amount of ascites.

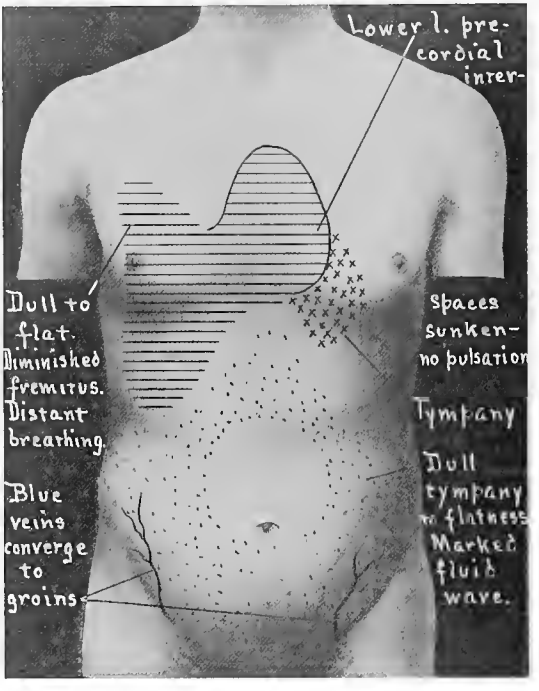

Fig. 238.—Signs in Case 296.

The abdomen was tapped at the Massachusetts General Hospital on the 21st of June and 17 quarts of fluid withdrawn. Specific gravity, 1007; albumin, 1 per cent.; sediment, endothelial cells; culture negative. After 1 mg. of tuberculin she had a typical temperature reaction, with considerable cyanosis. On the 26th she was given 100 gm. levulose in oatmeal, but the urine showed no sugar thereafter. *X*-ray of the shins, June 25th, showed nothing abnormal. Wassermann reaction was negative June 16th. Dr. F. G. Balch advised no surgical interference. At entrance, June 16th, I made the diagnosis of cirrhosis of the liver; later chronic fibrous peritonitis seemed more probable.

She was discharged the 27th of July and re-admitted February 29, 1912, after being tapped meantime every eight or nine weeks at first, later every four weeks, and, later still, every three weeks. For the past month she has complained of much gas in her stomach, with loss of appetite, vomiting and dyspnea, especially at night. For a month she has remained in bed and has lost weight. Two days ago, at 9 P. M., she had sudden intense pain in the left lower back and began to cough, raising bright blood.

Physical examination showed marked cyanosis, lungs and abdomen as in Figs. 238, 239. The abdomen obviously contained much fluid.

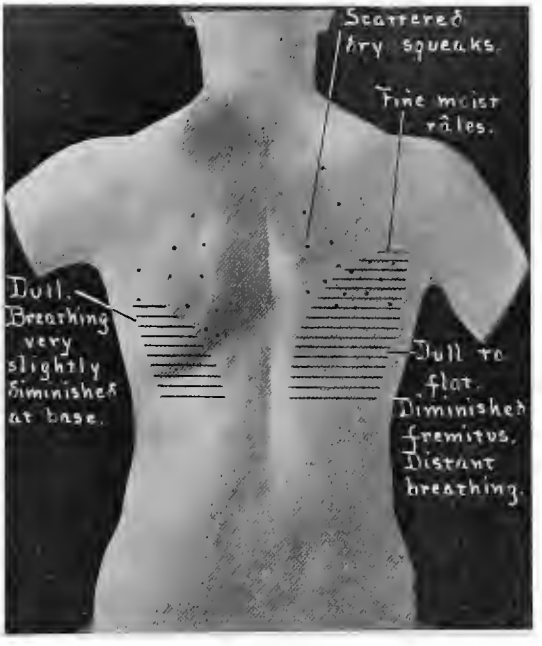
Scattered dry squeaks.
Fine moist râles.
Dull. Breathing very slightly diminished at base.
Dull to flat. Diminished fremitus. Distant breathing.

Fig. 239.—Signs in Case 296.

Knee-jerks were present and equal. There was marked systolic retraction of the lower precordial spaces, suggesting mediastinitis. There was also a paradoxic pulse.

Discussion.—The insidious onset of ascites in an afebrile patient of fourteen, and in quantity sufficient to require repeated tappings, without any marked impairment of the general health, is an unusual clinical picture. There is, however, one well-recognized cause to which it may be due—namely, adhesive pericarditis.

Although the records of the Boston City Hospital state that the patient had tuberculous peritonitis, the details of the record are not at

all convincing. One does not expect to find any such process confined to the sigmoid flexure or to any other one part of the intestine.

When at the Massachusetts General Hospital the characteristics of the tap-fluid were clearly those of a transudate, not of a peritonitis. The positive tuberculin reaction obtained at this time is not of importance in a patient of twenty-one. Mitral regurgitation would have been the diagnosis made by many, in view of the physical signs at this period. I wish, however, to insist strongly that such a diagnosis is never justified as the chief or main explanation of any set of symptoms whatever. Mitral regurgitation may often be a subordinate item in a pathologic state, an item like pulmonary congestion or ulcer of the leg, but it is never a sufficient or primary cause for other symptoms.

At the time of the second entrance the patient had evidently had a period of failing compensation and a recent lung infarct.

The evidence presented at the time would lead any unprejudiced observer straight to the diagnosis of adhesive pericarditis. The only missing link is the lack of any rheumatic history.

Outcome.—She did not improve at all, and died March 1st. Autopsy showed chronic adhesive pericarditis, chronic perihepatitis, perisplenitis, chronic peritonitis, hypertrophy and dilatation of the heart, infarct of the left lung, infarcts of the kidneys, chronic pleuritis.

Case 297

A married woman of forty entered the hospital August 26, 1911. Her family history is negative, and she remembers no serious illness since childhood. She has been married fifteen years and has one child living and well. Has had no miscarriages. Her habits are excellent. She has never taken alcohol.

One year ago she had what she calls "gastritis" for a week, and for four or five days afterward her skin was yellow, but there was no itching. She was not in bed, but since then has not felt quite so strong as before, and her abdomen has often been "bloated" for a day or two. The swelling has disappeared after a cathartic.

Two months ago the swelling in the abdomen became more marked than before and steadily increased until three weeks ago, when she began taking salts steadily. Since then it has decreased much, but a shortness of breath, which began two months ago, has meantime constantly increased. For the past month she has had a dry cough, and finds it distressing to lie upon the right side at night. There has been no pain in the chest, no chills or fever, no return of the jaundice, no edema. She does not think that she has lost any weight and says she

has always been thin. For years it has been her habit to pass urine four or five times in the night.

Physical examination showed poor nutrition, slight dyspnea, moderate pallor, and cyanosis. Pupils and reflexes normal. No enlarged glands. Chest and abdomen as shown in Figs. 240–243. Urine normal. Blood likewise normal. Wassermann reaction, September 14th, was slightly positive, and that done with the chest fluid moderately positive. The right chest was tapped August 26th, August 30th, September 1st, 9th, 14th, 18th, 23d, and 30th. It did not need to be tapped again until the 13th of October, and not after that until some months later. During most of her two months' stay in the hos-

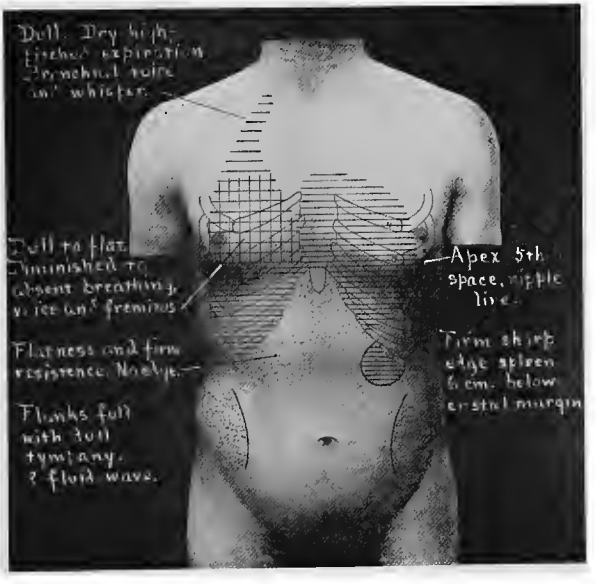

Fig. 240.—Physical signs in Case 297 at entrance.

pital her temperature reached 99.3° F., or slightly higher, each afternoon. The pulse ranged in the neighborhood of 110 for the first month, after that lower, and for the last two weeks of her stay it was about 80.

Her weight was 124 pounds at entrance, 104 pounds on the 15th of September and at the time of her discharge, October 20th. At all of these tappings of the chest, referred to above, the specific gravity of the fluid varied from 1004 to 1007. Amount of albumin was 1 per cent. or less; the sediment mostly of endothelial cells. The amount drawn at each tapping varied from 2 to 4 quarts. *X*-ray examination added no new evidence, but its results were strongly *against* the presence of any mediastinal tumor or any primary disease of the lungs.

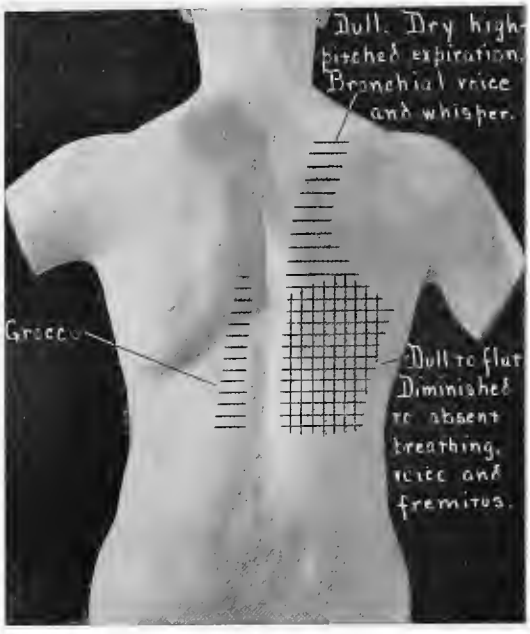
Dull. Dry high-pitched expiration. Bronchial voice and whisper.
Dull to flat. Diminished or absent breathing, voice and fremitus.

Fig. 241.—Physical signs in Case 297 at entrance.

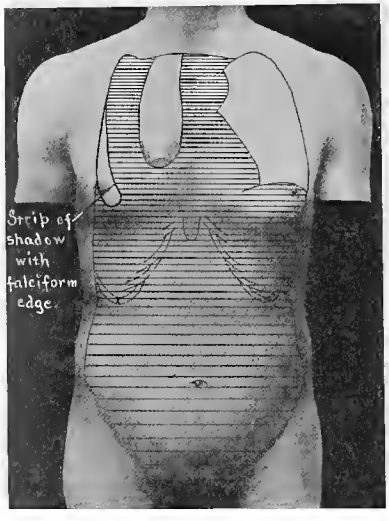

Fig. 242.—Diagram of *x*-ray shadows. Plate taken with patient prone.

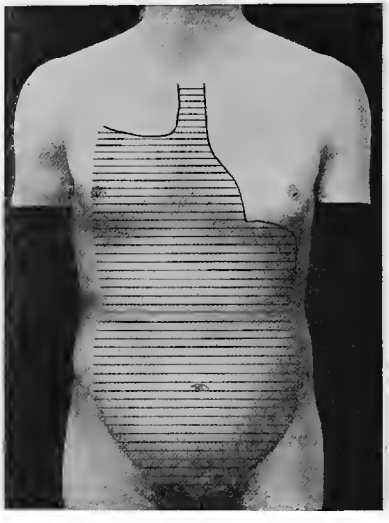

Fig. 243.—Diagram of *x*-ray plate taken with patient sitting up and immediately after the withdrawal of 2½ quarts of fluid from the right chest.

The spleen was always felt when the abdomen was moderately relaxed. In early September there was at one time a trifling suggestion of exoph-

thalmos, and the rapid unsatisfactory beat of the heart slightly suggested the action of a goiter heart.

On the 20th of September the abdomen was thought to contain a little fluid, although no absolute flatness could be obtained in the flanks. It was accordingly tapped, but only 40 c.c. of fluid obtained, the characteristics being practically the same as those of the chest fluid. Even after 21 quarts of fluid had been removed from her chest within four weeks—to September 23d—(Figs. 244, 245) her nutrition was extraordinarily well maintained.

About the first of October she was put upon a salt-free diet and began to improve at once. At the tapping, October 14th, only 2 quarts of

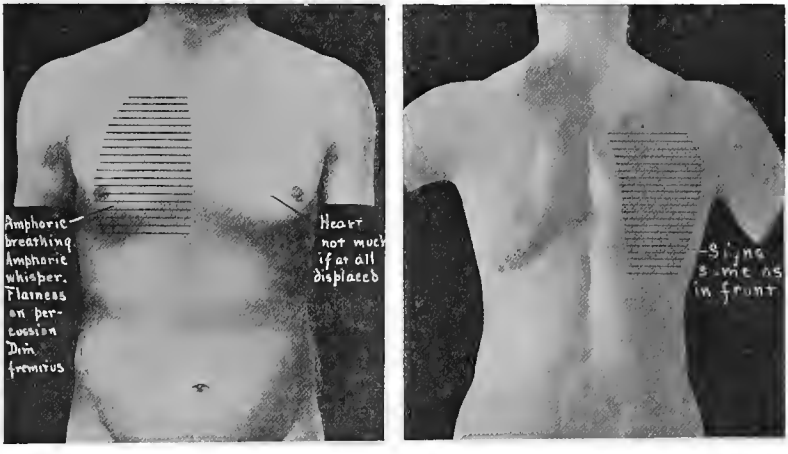

Figs. 244, 245.—Condition of chest September 23d in Case 297. Anterior and posterior views.

fluid were obtained. She left the hospital October 21, 1911, and reported regularly thereafter. January 13, 1912, three months after the last tapping, there was no evidence of any considerable amount of fluid in the right chest, but the abdomen contained a moderate amount of fluid. Her only complaint now was a moderate degree of prolapse of the vaginal wall. She notices that she is rapidly gaining weight and now weighs 111 pounds. She feels excellently well.

Dr. R. B. Greenough suggested the possibility of ovarian tumor, and thought this possibility would justify exploratory incision. Dr. W. H. Smith thought the fluid due to pressure of glands, either syphilitic or of the Hodgkin's type. As an alternate diagnosis, he suggested primary malignant disease of the abdomen, possibly of the ovary, with metas-

tases in the right lung. Dr. C. H. Lawrence suggested chronic adhesive peritonitis or pleuritis, syphilitic in origin, but could not rule out solid tumor of the ovary. Dr. G. C. Shattuck suggested mediastinal obstruction due to old polyserositis, perhaps syphilitic or tuberculous in origin. Dr. F. T. Lord suggested perihepatitis, with peritonitis and involvement of the gastrohepatic omentum and partial occlusion of the portal vein, and a similar process in the mediastinum and pleura with occlusion of the right azygos vein. Dr. James H. Wright thought the hydrothorax due to a lesion of the mitral valve, with the dilated right heart pressing on the right azygos vein. The ascites, he said, was due to cirrhosis of the liver.

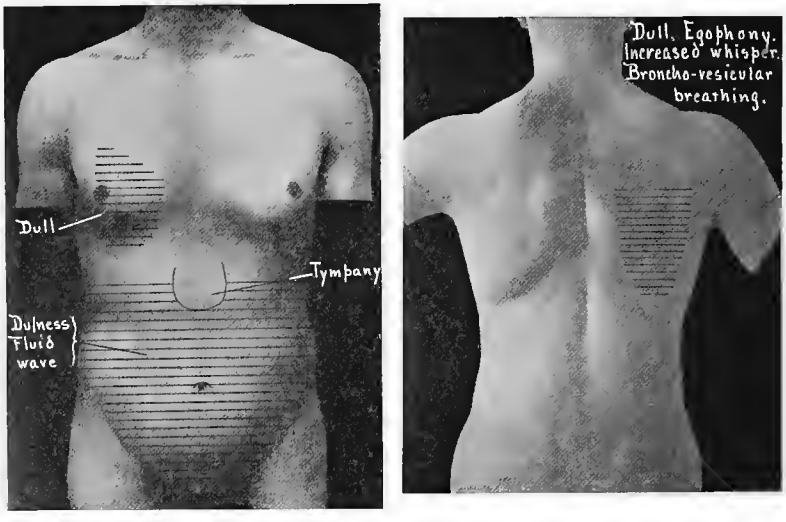

Figs. 246, 247.—Physical signs in Case 297 March 1, 1912. Anterior and posterior views.

The patient re-entered the hospital March 1, 1912, complaining chiefly of vaginal prolapse, with bloating of the abdomen. Three weeks ago her abdomen became especially swollen. She took an active purge, had severe watery catharsis, and the abdomen became flat, but she was much weakened. She was in bed a week thereafter and has not recovered strength since, although the abdomen has again become swollen. The condition of the chest and abdomen are shown in Figs. 246, 247. Three and a half quarts of fluid were withdrawn from the chest, the properties of the fluid being essentially as before; $1\frac{1}{2}$ quarts were also withdrawn from the abdomen on the 4th of March and $1\frac{3}{4}$ quarts three days after. The chest was tapped thereafter on the 12th, 20th, and 29th of March and on the 5th and 14th of April,

the amount drawn varying from 3 to 4 quarts. The abdomen was tapped on the 21st of March and 1 quart withdrawn; on the 28th 2 quarts were withdrawn.

On the 13th of March she had a well-marked temperature reaction following the subcutaneous injection of 1 mg. of tuberculin. Salt-free diet, which helped her so much before, had now no effect. On the 16th of April she developed an erysipelas around the last tap-hole in the back. Thereafter she lost her flesh rapidly, though the erysipelas cleared up. On the 24th of April, 1912, she died.

Discussion.—The multitude of conflicting diagnoses which I have recorded in this case shows that it was one of great interest and difficulty. Throughout the whole case our attention was concentrated upon the problem of explaining the rapid re-accumulation of dropsical fluid in the right chest. It was clearly not a pleuritic effusion, for its specific gravity was far too low. In the heart we could find no sufficient cause for it. The *x*-ray evidence was strongly against any neoplasm such as lymphoblastoma. No nephritis and no pelvic tumor could be found. (It will be remembered that some pelvic tumors are associated with hydrothorax as well as with ascites.)

Insufficient attention was paid to the history of jaundice and to the splenic enlargement. In view of the positive Wassermann reaction, my attention was thrown off the possibility of liver cirrhosis, though, in fact, that reaction should have acted rather to strengthen such a possibility. As a matter of fact, very little attention was paid to the abdomen, either by the patient or her physicians, for the thoracic symptoms were much more prominent.

When it seemed clear that we could exclude the heart, the kidney, tuberculous peritonitis, and any possible neoplastic source of pressure, I skipped over the fourth common cause of ascites, namely, hepatic cirrhosis, and alighted on a much more uncommon possibility, namely, multiple serositis. Looking back with the knowledge of hindsight, it is easy to see that this was foolish; yet, even after the autopsy, the mystery of recurrent hydrothorax was never cleared up.

Outcome.—Autopsy showed cirrhosis of the liver, enlargement of the spleen, right seropurulent pleuritis, obsolete tuberculosis of the bronchial lymphatic glands, streptococcic septicemia.

Case 298

An Italian barber of thirty-six entered the hospital October 27, 1911. The patient has lost one brother of tuberculosis, but was not, so far as he knows, exposed to infection; otherwise his family

history and past history are excellent. For fifteen years he has taken four or five whiskies and three or four beers a day. He had gonorrhea ten years ago, but no syphilis.

Until six weeks ago he has felt entirely well. Then he was seized in the night with vomiting and diarrhea. Next day he went to work and felt as well as usual for two weeks, when he had a second similar attack without known cause. He returned to work, but at the end of a week's work, three weeks ago, he noticed vague abdominal discomfort and an uncomfortable sense of fulness after eating or drinking, even in moderation. A few days later he noticed that his abdomen was enlarged, and he felt so weak and tired that he gave up work. The abdominal enlargement has steadily increased, and within a few days he has noticed some puffiness of the ankles.

His bowels have been constipated and have required cathartics. In each of the above vomiting spells he noticed black stools; at other times there has been nothing abnormal about them. He has never vomited blood and has had no stomach symptoms save after a drinking bout. His appetite is still fair.

Physical examination showed poor nutrition, normal pupils and reflexes, normal chest save for a few fine crackles at each base. Abdomen showed shifting dulness in the flanks with slight edema of the ankles. Over the shins were many large areas of brownish pigmentation. Blood-pressure, 130 mm. Hg., systolic; 85 mm. Hg., diastolic. Wassermann reaction was suspicious. Urine normal. White count at entrance, 11,000; November 1st, 19,000; November 2d, 20,000; November 3d, 25,000; November 6th, 22,000; November 7th, 18,000; November 9th, 15,000; November 11th, 13,000; November 14th, 10,500. Through the ascitic accumulation a hard, apparently smooth liver could be felt by "dipping" at the level of the umbilicus. Spleen not felt. In the fasting stomach there was a good deal of blood-stained material, with a positive reaction to guaiac.

The tap-fluid at entrance was 3800 c.c., amber color, with a specific gravity of 1012, albumin, 2.4 per cent., smear chiefly large endothelial cells, culture negative. Another tapping, November 3d, showed 3300 c.c.; specific gravity, 1010; albumin, 3 per cent.; sediment, 70 per cent. of small lymphocytes, 20 per cent. of polynuclears, 10 per cent. endothelial cells, no growth on culture-media. The results of blood-culture during the febrile attack are shown in Fig. 248. It was negative November 2d and November 9th. Weight, November 16th, 127 pounds; November 22d, after three tappings, the fluid seemed to be

accumulating more slowly. Operation was advised, but postponed. The patient left the hospital November 22d.

He came back again December 26th in about the same condition.

Discussion.—When an Italian of thirty-six admits alcoholism and gonorrhea, his denial of syphilis is of no special importance; and, joining this history to the attacks of vomiting and black stools and the four weeks of swollen abdomen, which examination shows to be full of fluid, we naturally think, first of all, of hepatic cirrhosis. The cardiac, renal, neoplastic, and tuberculous causes of ascites are less apt to be associated with black stools.

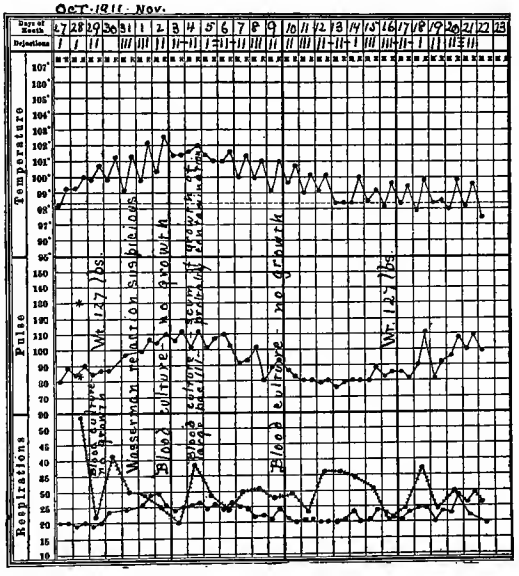

Fig. 248.—Record of temperature, pulse, urine (in ounces), respiration, and blood-cultures in Case 298.

The tap-fluid is of medium weight, but, on the whole, nearer to that of a transudate than that of an inflammatory fluid. The only discussable question relates to the origin of the cirrhosis. The suspicious Wassermann reaction and the brown scars upon the shin rather incline us to believe that the trouble is syphilitic. The fever points in the same direction. Alcoholic cirrhosis is less likely to produce such a pyrexia. None of the other causes of ascites, except tuberculous peritonitis, produce fever. Against the latter are the condition of the liver edge and the specific gravity of the fluid, as well as the negative past history and family history.

Outcome.—Operation on the 30th showed a small hob-nailed

liver. Its surface and that of the peritoneum near it was scraped until it bled and the two surfaces brought into apposition. January 4th the patient's temperature began to rise and continued elevated, as shown in Fig. 249. There were many râles in both chests and he raised a large amount of thick sputa, but showed no signs of lung consolidation. On the 11th he had to be tapped; 118 ounces were removed. On the 25th he was tapped again and 32 ounces removed. After that the abdomen did not refill and the patient felt much better. On the 6th of February, 1912, he left the hospital in good condition.

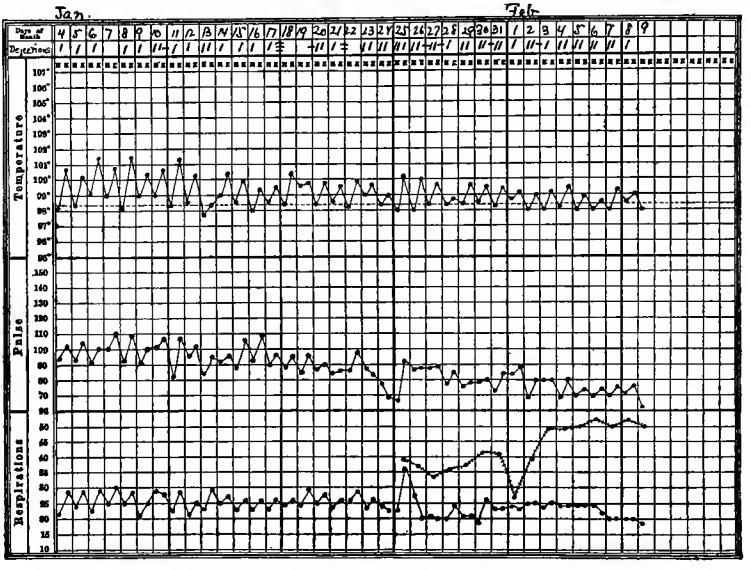

Fig. 249.—Chart of Case 298, after Talma's operation.

Remarks.—Apparently, after the operation he suffered a pulmonary thrombosis. His subsequent history was that of an alcoholic loafer. From a physical point of view the operation was a success; from a community standpoint we can hardly say so. On the 3d of May he still had moderate ascites, but was greatly improved in general appearance and had gained in flesh and strength. On the 31st of May the amount of fluid in the abdomen was small, but August 21st there was still shifting dulness in the flanks. October 14, 1913, he had not gone to work; he evidently enjoyed his leisurely life far too well.

Case 299

A clerk of twenty-four entered the hospital March 28, 1912. The patient's father died of Bright's disease. Family history otherwise

excellent. Three years ago she had a swelling on the right side of the neck which lasted for some weeks. Her menstruation has been rather profuse for the past year.

For five months she has been gradually getting weaker and losing appetite, but has had no more definite symptoms than these until two months ago, when she began to have a pain between her shoulders and down both arms. In the course of another month this gradually wore off. Four weeks ago she noticed swelling of the abdomen, which, especially in the last two weeks, has much increased, although for the same period she has had three or four watery stools a day and has been obliged to remain in bed. She has considerable pain about her heart after meals, relieved by belching; she is somewhat short of breath on exertion and when attempting to lie flat.

Physical examination showed considerable wasting, marked sweating, normal pupils and reflexes, normal chest, save for the evidences of a high diaphragm, shifting dulness in the flanks, blood-pressure 120 mm. Hg., blood and urine normal. On the 29th the abdomen was tapped and $5\frac{1}{2}$ quarts of fluid, greenish yellow in color, withdrawn. Specific gravity, 1018, albumin over 3 per cent. Smear of sediment showed 45 per cent. polynuclears, 55 per cent. large and small mononuclears, a few red blood-cells, no tubercle bacilli; 20 minims of this sediment were injected into a guinea-pig March 29th. On the 6th of May the animal was killed, and the autopsy showed tuberculous lesions of the glands, liver, and spleen. After tapping there was still slight general spasm of the abdomen and a moderate dull pain there. Throughout her three weeks in the medical wards the temperature continued much elevated. The cutaneous tuberculin test was positive. On the 17th of April she was transferred to the surgical wards.

Discussion.—Here we have a clinical picture of an ascites without any evidence of renal, cardiac, hepatic, or neoplastic origin. The fluid is of high specific gravity and produces tuberculosis in a guinea-pig. There are no further evidences needed. We may be as certain of tuberculous peritonitis as if an autopsy had been done.

Looking back from this standpoint of certainty, it is of interest that the patient had, three years before, a swelling in the neck, which we may reasonably interpret as a tuberculous gland. This followed five months of the sort of symptoms ordinarily known as general debility or attributed to stomach trouble. Diagnosis would probably have been impossible at that time, but the lesson to be learned is this: when people become debilitated without any good reason and without any

demonstrable physical sign, tuberculosis is always a plausible cause and should be watched for sedulously.

Outcome.—At operation the peritoneum was lusterless, but very few tubercles could be seen. There were a moderate number of adhesions and several pockets of fluid, which were not opened. Both Fallopian tubes were found to be tuberculous and were removed. In the surgical wards she continued to run a fever from April 17th to her discharge, May 9th. Microscopic examination of the excised tubes showed tuberculosis. Her general condition improved somewhat.

January 20, 1913, a letter from her sister states that she died June 30, 1912.

Case 300

A housepainter, aged fifty-six years, who had taken alcohol only occasionally and in moderate amounts, noticed edema of his ankles seven weeks ago. A week later his belly swelled up, and he needed three tappings in six weeks, 8 or 9 quarts being withdrawn each time. Has lost 30 pounds in four months.

Examination.—The right lower lid contained a small nodule showing all the characteristics of epithelioma. The heart was displaced so that its apex was in the anterior axillary line, while the right border of dulness was at the *left* sternal margin. There was a soft systolic murmur at the apex. The pulmonic second sound was not accentuated.

There was evidence of edema at the bases of the lungs. The belly contained a large amount of serous fluid, 250 ounces accumulating between two tappings sixteen days apart—an average of over 15 ounces a day. The fluids were 1006 and 1008 in gravity, and showed 80 and 90 per cent. of lymphocytes respectively in their sediments. Culture and animal inoculation negative. Fever was absent, and there was no reaction after the subcutaneous injection of 10 mg. of tuberculin.

There was some excess of neutral fat in the stools, suggesting to Dr. H. F. Hewes the stools of tuberculous peritonitis.

In diagnosis we considered cirrhosis of the liver, tuberculous peritonitis, and also the possibility that misplacement of the heart, owing to pleural adhesions, might have kinked some one of the great abdominal veins so as to produce stasis and ascites.

Against cirrhosis was the early appearance of swelling in the legs and the moderate amount of alcohol ingested. Against tuberculosis was the negative tuberculin reaction and the low gravity of the

fluid obtained by tapping. On the other hand, the cell-count in the fluid, the appearance of the stools, as well as the old history of pleurisy, made tuberculous peritonitis a possibility. On the whole, cirrhosis seemed the more probable, and on operation, September 18th, this was found.

Outcome.—The patient died September 29th, and autopsy showed the ordinary lesions of cirrhosis of the liver and, in addition, a thrombosis of the portal vein and a chronic peritonitis. There was also slight fibrous endocarditis of the aortic and mitral valves and slight hypertrophy and dilatation of the heart. There was obsolete tuberculosis of a tracheal lymph-gland, which is interesting in view of the negative tuberculin reaction.

Case 301

A married woman, aged thirty-eight years, entered the hospital October 9, 1908. She has previously been well except that she has had a cough since she was a girl, and had typhoid fever ten years ago. For two or three years she has felt something wrong in the pelvis, and a year ago her doctor found a uterine fibroid there. The patient thinks this tumor has been present for four years.

Seven months ago she consulted a physician for pain in her left chest. He found pleural effusion, and withdrew 2 quarts of fluid by tapping. The same amount was withdrawn four weeks later, but the fluid again recurred.

A month ago the abdomen was noticed to be swelling, and this has increased up to the present time. She has had dypsnea on exertion for many years, but this has been worse within the last seven months, and now she cannot lie down flat. For the last two days the feet and legs have been swelling. The bowels move five to eight times a day during the last few weeks. Several examinations of the urine and several of the sputa have been negative.

Physical examination verified the findings of fluid in the left chest and in the abdomen. October 10th the abdomen was tapped and 18 pints of serum withdrawn. The specific gravity was 1018, and the cell-count showed 63 per cent. of lymphocytes.

After tapping, a rounded solid tumor, hard and painless, could be felt in the median line, apparently connected with the uterus. The diagnosis was believed to be tuberculous peritonitis, and the experiment was tried of withdrawing 8 ounces of fluid from the chest every two or three days, in order to prevent recurrence such as was thought likely to follow if the whole amount was removed at once.

On November 21st the abdomen was again tapped and 18 pints again removed. This amount had accumulated in forty-two days, being at the rate of 7 ounces a day. After this tapping, pelvic examination showed a mass filling the pelvis, pushing the cervix up behind the pubes, very hard, irregular, non-elastic, and continuous with the suprapubic tumor. Dr. M. H. Richardson believed the condition to be one of tuberculous peritonitis with a concomitant uterine tumor, benign or malignant.

The association of fluid in the abdomen with fluid in the chest, and the history of a chronic cough, together with the high gravity of the fluid, made us confident of the diagnosis of tuberculous peritonitis, although in the two and one-half months of her stay in the medical wards there was never any fever. The blood and urine were throughout negative, as was the rest of the visceral examination.

Outcome.—Operation, December 12th, showed no peritonitis, but a fibroma of the ovary; after the removal of this the patient convalesced rapidly, and when I saw her a year later she was in perfect health, as she had been for the last eleven months since leaving the hospital.

Case 302

An unmarried Italian girl, aged seventeen years, entered the hospital October 17, 1908, for enlargement of the abdomen, with fever and general abdominal pain. These symptoms had been present for the last two weeks and had been accompanied by a dry cough.

On examination there were dulness and harsh breathing throughout the left lung except at the bottom of the axilla and the base posteriorly, where breathing was much diminished and resonance almost absent. Below the second left interspace were fine and medium crackling râles in front, and the same râles were heard below the angle of the scapula behind. The abdomen showed all the evidences of free fluid. Otherwise, physical examination was negative, and the blood and urine showed nothing abnormal.

After the first five days the patient had practically no fever throughout her two months' stay in the hospital. The abdomen showed general tenderness, but was otherwise negative, save for the evidences of free fluid above referred to. The abdomen was tapped on the 21st, but only a few ounces of clear serous fluid were obtained; 5 mg. tuberculin were injected subcutaneously on the 30th, after which the temperature rose from normal to 103.2° F. within six hours, returning to normal within twelve hours more. The cutaneous reaction for tuberculosis was also positive.

She gained weight, although there was no increase in the amount of fluid, and on November 12th was allowed to go home.

Outcome.—After this she slept out of doors and lived out of doors continuously, but by January the abdomen began to enlarge again, and January 16th she was operated on and diffuse tuberculosis of the peritoneum found. Diagnosis was verified by microscopic examination of an excised piece. The Fallopian tubes were also tuberculous and were removed. Convalescence was uneventful.

The resemblance between this case and that last described is striking. Indeed, but for the presence of the tumor in the first case, the abdominal tenderness and the scantiness of the ascites in the second, they are almost identical from a clinical standpoint, despite the entire difference of the actual pathologic condition present.

A relatively slow accumulation of fluid and a slight general rigidity and tenderness of the belly help to distinguish the ascites of tuberculous peritonitis from that produced by other diseases.

Case 303

A boy, aged, six years, entered the hospital October 19, 1908. His history was not of significance up to five months previously, when his abdomen began to swell; there was also some puffiness of the face, but no other symptoms, and within a few weeks he was able to be up and about. Later he relapsed, and two months ago the abdomen was tapped, 4 quarts of dark yellow, turbid fluid being withdrawn.

Since this there has been considerable vomiting, and at one time he had convulsions and was considered moribund. He was tapped again three weeks ago and 3 quarts of fluid withdrawn. Since then the abdomen has rapidly refilled.

On examination the cardiac impulse was in the nipple line, fourth space. The cardiac examination was otherwise not remarkable. Blood-pressure not measured. The lungs were negative, the abdomen very prominent, showing all the evidences of free fluid. Considerable soft edema of the legs and feet.

The urine averaged between 5 and 10 ounces in twenty-four hours during his stay in the hospital. The specific gravity was between 1020 and 1022; the amount of albumin from 0.5 to 0.9 per cent. In the sediment were many hyaline, granular, and fatty casts.

The abdomen was tapped on October 21st and 5 quarts 6 ounces of chylous fluid withdrawn; specific gravity, 1009. In the sediment, lymphocytes, 37 per cent.; epithelial cells, 63 per cent.

Outcome.—The boy left the hospital on November 2, 1908, in very poor condition, and remained so until February, 1909, when, after tapping, his abdomen did not refill, and this improved condition persisted for three months. Since then he has had to be tapped every two weeks, fifteen times in all, up to September 27th. (An average accumulation of about 12 ounces a day.)

His condition in September, 1909, was in all respects essentially the same as it had been a year before, except that the heart was 1.5 cm. farther to the left. He was tapped on the 28th and 5 quarts (5800 c.c.) of opalescent fluid removed; specific gravity, 1006. After this the fluid re-accumulated very slowly, and he was allowed to go home on October 9th.

Case 304

A dentist, aged thirty-nine years, entered the hospital October 20, 1908. He had been in the habit of taking a pint and a half of whisky a day for the last two years, and an unknown amount for eight years previously. Two and one-half months ago he noticed that his trousers were tight around the waist. This increased so rapidly that four weeks later the abdomen had to be tapped, and 5 quarts of serous fluid were withdrawn. Since then he has been tapped four times, the amount being about the same each time. This means an accumulation of about 16 ounces a day. His feet have never been swollen, his appetite has been good, there has been no pain or other symptoms of any kind. The last tapping was a week ago.

Physical examination was essentially negative except for the evidences of ascites. The blood and urine showed nothing abnormal. Temperature, pulse, and respiration were normal. October 27th, 14 pints 7 ounces of turbid yellow fluid were withdrawn. After tapping, the edge of the liver could not be felt below the ribs, but could be touched by reaching up behind the costal margin. The specific gravity of the fluid was 1008.

Outcome.—On October 28th the abdomen was opened, the liver found to be shrunken and irregularly nodular. Omentopexy was done, but by November 9th the patient had to be tapped again, and 9 pints of fluid were removed. (Rate of accumulation, 12 ounces a day.)

He left the hospital November 22, 1908. November 29, 1909, the patient was seen and seemed to be in excellent condition. There was no return of fluid in the abdomen. The abdomen was tapped within a few days after leaving the hospital in November, 1908, but tapping has not been required since. He now eats well, sleeps well, and looks well.

Case 305

A salesman, aged thirty-four years, entered the hospital November 13, 1908. His family history and past history not remarkable, habits good. For four or five years he has been gaining weight and has noticed that his trousers were tight about the waist. His usual weight is 150 pounds; now, 158 pounds. The increase of his girth has been especially marked in the last year, and has been accompanied by dyspnea on exertion. During the last ten months his appetite has also failed; he has had a good deal of vomiting soon after meals, also troublesome constipation. He worked until nine months ago. Eight months ago he was tapped and $6\frac{1}{2}$ quarts of clear fluid removed. After a month he began to refill. He has been treated during the last four months in the Out-patient Department.

Physical Examination.—The heart's impulse extended 2 cm. outside the nipple line in the fifth space. The heart sounds were clear and there was nothing else of interest in the cardiac condition. The position of the apex shifted outward 2.5 cm. when he lay on the left side. The peripheral arteries were normal and the lungs negative. The abdomen showed all the evidences of free fluid, and the edge of the liver could be felt 7 cm. below the costal margin in the mammary line.

He was tapped November 20th; 202 ounces of yellow turbid fluid removed; specific gravity, 1020. In the sediment 85 per cent. of small lymphocytes, 15 per cent. of large lymphocytes. Nothing more felt after tapping. After an injection of 0.005 tuberculin subcutaneously there was a positive temperature reaction. The *x*-rays showed no evidences of tuberculosis in the lungs. At this time the spleen was easily palpable when the patient lay upon his right side, and it was noticed that there was a systolic retraction of the apical and precordial region. Adherent pericardium, tuberculous peritonitis, and cirrhosis were considered, but laparotomy, December 5th, showed no tuberculosis and no evidence of disease in the liver so far as the surgeon's hand could discover. Dr. M. H. Richardson and Dr. Hugh Cabot considered the case to be probably one of pericarditis with adhesions and secondary ascites.

After that he got along until January 9, 1909, with two tappings, but was then operated on again, January 10th, for the relief of adherent pericardium. Parts of the third, fourth, and fifth ribs were resected from their sternal attachments to a point 4 inches to the left. This seemed to allow the free retraction of the heart, and was deemed sufficient.

He returned to the medical wards on January 26, 1909, and under calomel diuresis the urine rose to 68 ounces and the amount of ascites was considerably decreased. This calomel diuresis was repeated ten days later, with success as before. On March 4th he was tapped, but only 4 quarts removed. The liver edge was then felt 5 cm. below the ribs. The specific gravity of the ascitic fluid was 1017. March 10th he was tapped again, but only 6 pints found. A calomel diuresis was attempted on March 15th, but was unsuccessful. It was evident that after the operation for cardiolysis the accumulation of ascites was slower, though this may have been due to the persistent administration of diuretics and cathartics. He was last seen March 27, 1909.

Case 306

A Russian Jewish millgirl, aged eighteen years, entered the hospital December 2, 1908, with a diagnosis of "tuberculous peritonitis" made in the Out-patient Department by Dr. W. H. Smith (O. P. D., No. 118,422). Her family history and past history were uneventful. Menstruation began at twelve and has been regular until within the last year, when it has become more frequent, and lately has come every two weeks and lasted four days each time. For three months she has noticed enlargement of the abdomen, and thinks she has been losing weight. Within the last month she has had some abdominal pain, paroxysmal and griping. Her appetite has been good and there has been no cough or other symptoms. Pulse, temperature, and respiration were moderately and irregularly elevated. The urine showed nothing abnormal. In the blood were 17,900 leukocytes per cubic millimeter December 3d; 16,800 leukocytes December 7th.

Physical examination was negative except as relates to the abdomen, which was prominent, tense, flat on percussion throughout, symmetric, and gave a fluid wave. Girth at the umbilicus, 86.5 cm. The edge of the liver was not felt. No edema.

Tuberculous peritonitis was considered, but the leukocytosis and the extreme tightness of the belly made the diagnosis doubtful.

Outcome.—December 4th the abdomen was tapped above the pubes and 96 ounces of muddy, thick, viscid, ropy, alkaline fluid obtained; gravity, 1025. The fluid resembled very thick maple syrup and formed a jelly-like mass after heating. When diluted there was no precipitate or clot obtained by heat or by the addition of acetic acid. Biuret reaction negative. The addition of alcohol produced a heavy, ropy, tenacious precipitate (pseudomucin and paramucin).

This precipitate, when boiled with acid, broke up into two bodies, one of which reduced Fehling's, while the other gave the Biuret reaction. In the sediment there was nothing distinctive. The fluid was obviously characteristic of the contents of an ovarian cyst. By laparotomy a large multilocular cyst of the right ovary was removed without incident.

Case 307

A housewife, aged thirty-seven years, entered the hospital February 15, 1909. She had had a miscarriage seven and one-half years ago, purposely induced; one living child five years old. Two threatened miscarriages in the course of this pregnancy. The baby was anemic for the first three weeks, but otherwise has been well. The patient had diphtheria twelve years ago, and the throat was sore for six weeks at that time. Three years ago began to have pains in her lower legs, especially along the shins. The pains came at night, were very severe, and prevented sleep. There were no enlarged veins or other noticeable changes, but the bones were sore to the touch. A year later some ulcers appeared; the last one healed three months ago. Four months ago she had severe pain in the occiput, worse at night, and at this time three lumps appeared on her head about 1 inch in diameter, sore to the touch. One of them still remains.

Since her last pregnancy has had trouble with her nose, causing difficulty in breathing. At this time also, about five years ago, her hair came out profusely for a time. Two or three years ago she noticed a tumor in her left hypochondrium, which caused no symptoms, but bothered her in putting on her corsets. Last October she was operated on for hemorrhoids, and at that time the doctor said that her spleen was enlarged.

Two and one-half months ago the belly began to enlarge, and she has been tapped twice, six weeks ago and three weeks ago. On examination there were many pea-sized cervical glands. The chest was negative; systolic blood-pressure, 135. The upper border of the liver showed on percussion a median elevation just above the nipple line. The edge of the spleen was felt 12 cm. below the ribs. There was evidence of free fluid in the abdomen, and the girth at the umbilicus was 109 cm. Considerable soft edema of the ankles, and dark brown scars over the ankles and shins. On the forehead near the hair line was a straight periosteal thickening, and another higher up in the hair on the frontal bone. *X*-ray plates showed specific changes in the tibiæ.

Outcome.—Under antisyphilitic treatment and diuretin the patient improved rapidly. The fluid diminished in amount, but on March 2d 6 quarts were withdrawn, after which the edge of the liver could be easily felt 2 cm. below the ribs in the nipple line. The ascitic fluid was 1009 in specific gravity and showed 90 per cent. of mononuclear cells, about one-half of them large and one-half small. She left the hospital March 6, 1909, and up to date, May 1, 1914, has remained well.

Case 308

A shoemaker, aged fifty-three years, entered the hospital November 12, 1908. Family history and past history not remarkable. Eight years ago lumps appeared in the left side of his neck, and have not changed since then until a year ago, when additional and larger lumps made their appearance near those previously felt. Also similar lumps in the axillæ and groins. Nine months ago lumps were noticed in the abdomen. Three weeks ago the belly and legs began to swell, and a week ago he was tapped in the Out-patient Department and 2200 c.c. removed; specific gravity, 1011; sediment lymphocytic. Eighteen months ago he weighed 180 pounds; a month ago, 160 pounds. A gland was removed in the Out-patient Department, and a diagnosis of lymphosarcoma or lymphoblastoma (Mallory) made.

On physical examination there was a mass of glands, roughly 10 by 8 cm., in the left side of the neck, not adherent to the skin, and fairly movable. Elsewhere in the neck, axillæ, and groins there were glands from the size of a bean to that of a hickory nut. The right pupil slightly larger than the left. Heart's apex, 1.5 cm. outside the nipple line. Cardiac examination otherwise not significant; lungs negative. The abdomen showed evidences of free fluid and large irregular tumors. The spleen and liver not made out. On the posterior rectal wall a mass half the size of the fist, hard and nodular, was palpable.

He was tapped on November 25th and 82 ounces of brownish-red fluid obtained. On December 4th, 86 ounces more were removed. Specific gravity, 1015; sediment mostly epithelial cells. December 8th, 115 ounces more were withdrawn. December 20th, only 12 ounces. December 24th, 17 ounces more. December 28th, *x*-rays showed a shadow over the whole left side of the chest.

Outcome.—Under diuretin, started December 26th, urine rose on the 30th to 62 ounces, and several times subsequently 60 to 80 ounces were obtained as the result of diuretin. He was tapped December 28th

and 7 pints obtained. On January 3d, 50 ounces; January 9th, 6 pints; January 15th, 106 ounces; January 19th, 96 ounces. He left the hospital January 21st, and died soon after at home.

Case 309

A stage-manager of thirty-one entered the hospital June 29, 1907. The patient has been well, so far as he knows, until three and one-half weeks ago, when he began to feel rather poorly, and three weeks ago gave up work on account of spells of colicky pain in the abdomen, especially after a heavy meal. The pain always shifted from one point to another in the abdomen and was not accompanied by any tenderness. The attacks lasted two or three days, with intervals of entire comfort between times, during which intervals, however, he has felt weak, feverish, thirsty, and has been unable to take solid food.

Six days ago he felt fine and went on a visit to Lexington, where he ate ice-cream and cake and took two glasses of champagne. That night he had chills, fever, and nausea. The next morning he was weak and had headache, but went to work and kept at it through the day. That night he had epigastric pain and vomiting, and has since then remained in bed, feverish and sleepless. Three days ago the abdomen swelled and became generally sore. For twenty-four hours he has had much hiccup and belching of gas.

On physical examination the patient is mentally alert, but looks very sick. The head, chest, and extremities are negative. The abdomen is distended, the navel flushed, general tenderness throughout, marked in the epigastrium, but not in the right iliac region. Shifting dulness in the flanks. Spleen enlarged on percussion. One typical rose spot on the back. The white cells are 10,800; hemoglobin, 80 per cent.; Widal reaction negative. The temperature is 101° F.; pulse, 100. The urine is 35 ounces in twenty-four hours; specific gravity, 1030; slightest possible trace of albumin; rare granular cast. The vomitus consists of greenish fluid, mucus and undigested food. Guaiac always negative. HCl absent.

Discussion.—Three weeks' colic with fever in attacks lasting two or three days at a time, then three days of a sore and swollen belly, followed by twenty-four hours of hiccuping, leads us straight to the diagnosis of general peritonitis, dependent upon some focus of inflammation within the abdomen. The physical examination shows evidence of free fluid and of general tenderness, such as is produced by peritonitis. The amount of fever and leukocytosis is not great, and must be accounted for, if we stick to the theory of peritonitis, by saying

that the patient is overwhelmed by his infection and cannot react against it.

Is the spleen enlarged? I see no evidence of it. A spleen that we cannot feel should never be considered enlarged, no matter what the percussion outlines are. This is not to say that such enlargement cannot exist, but only that we cannot feel sure of it, and that an enlarged area of dulness in the splenic region frequently exists without any enlargement of the spleen or any other local cause of importance.

Among the diagnoses likely to be made in this case we will take first the inevitable ptomain-poisoning. Any abdominal pain which the patient connects with a supposedly poisonous material is very apt to be called ptomain-poisoning by the patient himself and by his doctor. Such a diagnosis has an impressive sound and pleases the patient, yet it is almost inevitably a blunder. True food-poisoning is rare, and, even if poisons from food are actually the cause of the patient's troubles, we have no reason to assume that these poisons are really ptomains. In the vast majority of cases, the term "ptomain-poisoning" is only a blind to cover up our ignorance of what the actual diagnosis is. Within the past year or two I have known the following diseases miscalled ptomain-poisoning: tabes dorsalis with gastric crisis, lead-poisoning, appendicitis, gall-stones, cancer of the colon, and uremia. Without much trouble the list might be greatly extended.

The commonest cause of an otherwise general peritonitis is inflammation of the appendix. I cannot rule out this diagnosis here, but there are no local physical signs to support it.

Some cases of tuberculous peritonitis remain entirely latent for a long time and then suddenly manifest themselves by acute symptoms, due to local peritonitis or obstruction by adhesions. The presence of shifting dulness in the flanks might be interpreted as supporting this conjecture. As a rule, however, the patient is not nearly as sick as this patient seems to be. In the acute complications of tuberculous peritonitis, the general condition of the patient remains surprisingly good. Such a feature as a twenty-four-hour hiccup would not be expected.

Acute intestinal obstruction of unknown origin might produce all the symptoms here described. At this patient's age, however, intestinal obstruction is rare, unless there has been a previous peritonitis or laparotomy.

Acute gall-bladder disease is certainly a possibility, although we have no jaundice, no demonstrable enlargement of the gall-bladder, and no local tenderness. Had the gall-bladder actually perforated, the patient's condition would be even more grave than it is. The

shifting of the colicky pain from point to point is not what one expects in gall-bladder disease.

Peptic ulcer usually shows a longer history of gastric symptoms and less shifting colic. Nevertheless, it is impossible to exclude a perforation of such an ulcer with general peritonitis as a result.

On the whole, then, I am unable to reach a definite diagnosis of the cause of this patient's general peritonitis. Intestinal obstruction seems as probable as anything, with appendicitis a close second.

Outcome.—Operation, July 2d, showed 2 quarts of clear fluid in the abdomen, the small intestine greatly distended, no cause for obstruction found. Incision was then enlarged downward and a coil of intestine, apparently from the upper ileum, found thickened, blue, and covered with a fibrous exudate. The mesentery corresponding with this loop was thick and porky. Above this point the intestine was distended; below it, contracted. The diseased loop was clamped and cut away. The patient died the next day. Autopsy showed chronic appendicitis with abscess formation; suppurative thrombosis of the portal vein, inferior and superior mesenteric veins and their radicles; general peritonitis.

Case 310

A rubber worker of forty-nine, born in Austria, entered the hospital January 26, 1910. The patient has noticed enlargement of the abdomen for five weeks; previously to that he has been well. His father died of lung trouble at fifty-four. He had three brothers and one sister who died of unknown cause. One living brother has stomach trouble. The patient's wife and nine children are well. He drinks half a pint of whisky a day. He has done this for thirty-five years, with a little beer and wine occasionally. He spends thirty-five cents a week for tobacco.

Abdominal swelling compelled him a month ago to give up work, though he has no considerable pain and rarely vomits. At the same time his skin became yellow, his stools light colored, his urine dark, his feet swelled, and a cough appeared, which has since become worse. Appetite and sleep are good, and, so far as he knows, he has lost no weight.

Physical examination showed fair nutrition and was generally negative, except as relates to the abdomen, the general yellow discolorations of skin and mucous membranes, and the absence of knee-jerks. The abdomen showed shifting dulness in the flanks and elsewhere, except for a small area of tympany about the navel. No tenderness or

masses could be detected. The knee-jerks were not obtained. Plantar reflexes normal. Save for the presence of bile the urine showed nothing remarkable and the blood was normal. The evening temperature ranged in the neighborhood of 100° F. during two weeks' observation. The temperature was usually normal in the morning. The stools were of normal color and contained bile. They were negative to guaiac and showed no special abnormalities.

Two and one-half quarts of fluid were removed from the abdomen on the 29th. After tapping the surface of the liver it seemed coarsely nodular. The abdominal fluid had a gravity of 1008, contained 1 per cent. albumin, and a sediment with 88 per cent. of small lymphocytes.

Discussion.—Lead-poisoning, which is brought to our attention by this patient's occupation (since litharge is used in the manufacture of rubber), does not ordinarily produce abdominal enlargement as the most noticeable symptom, and without pain. The abdominal enlargement which we sometimes see in lead-poisoning is due to gas and is associated with pain and constipation. If this patient has plumbism, his abdominal symptoms are not at all characteristic of it.

The family history of tuberculosis leads us to speculate on the possibility of tuberculous peritonitis, which might quite possibly come on in this way, though rarely in a patient of forty-nine. The presence of jaundice, absent knee-jerks, and swelled feet cannot be easily accounted for in this way, and the cough is much more likely to be due to a high diaphragm than to tuberculosis. On the other hand, tuberculosis would easily account for the condition of the abdomen and for the fever.

The alcoholic history leads straight to cirrhosis of the liver as a plausible explanation of his symptoms. I see nothing in the case to exclude this diagnosis, though fever is not the rule in cirrhosis, and we cannot thus account for the loss of knee-jerks. Moreover, the small nodules of the cirrhotic liver surface are rarely, if ever, palpable through the belly wall.

If, however, we suppose a cirrhosis of the syphilitic type, we can explain the loss of knee-jerks as manifestations of the same infection. The acetic fluid obtained by tapping has the characteristics usually seen in cirrhosis, whether of the alcoholic or syphilitic type, and its low specific gravity militates against a diagnosis of cancerous peritonitis or tuberculosis.

Syphilis is the best working hypothesis.

Outcome.—Vigorous antisyphiltic treatment caused no improve-

ment. On the 5th of February he had to be tapped again, and about the same amount of fluid of the same character was withdrawn. This had to be repeated once more on the 9th of February, when 3 quarts were withdrawn. The tube of the trocar, when moved about, seemed to encounter either adhesions or glands, and the fluid did not seem to be entirely free in the abdominal cavity. The patient went home on the 10th, and died March 17, 1910.

Case 311

A laborer of twenty-eight entered the hospital April 1, 1910. The patient comes to the hospital because, as he says, his stomach has been markedly enlarged for the past two weeks. This has been accompanied by considerable pain, which compelled him to give up work three weeks ago. Later, he remembered that fluid had been removed from his left chest five months previously. Nevertheless, he had been steadily at work since that time until the present illness. His family history, past history, and habits are excellent. He thinks he has lost some weight and strength, and his appetite has been poor. He has a slight cough, with yellowish sputum. He entered the hospital with a diagnosis of "cancer of the stomach."

Physical examination showed a sallow, pale skin, although the blood-smear showed only slight achromia; hemoglobin, 75 per cent. There was harsh breathing at the left apex, otherwise no pulmonary lesions, save such as could be explained by the abdominal enlargement. There was shifting dulness in the flanks, with tympany in the distended region about the navel. The spleen was not felt; the abdomen and extremities wholly negative. The blood and urine were negative, the temperature slightly elevated at night during the first ten days of his stay in the hospital, usually reaching 99.5° to 100° F. After that it did not go above 99° F. during a month's observation. The sputum, four times examined, showed nothing of interest. His abdomen remained always distended with gas, even when fluid could no longer be demonstrated there. Enemata had no considerable effect on this gas. The skin tuberculin test was slightly positive. There was always dulness and diminished respiration at the bases of the lungs, sometimes with fine crackles, but the high position of the diaphragm made it difficult to be sure that any independent disease existed in the pleural cavity.

Discussion.—When we know that fluid has been recently removed from the chest of a patient free from cardiac and renal disease, we can have little doubt that he has had pleurisy; that is, a tuberculosis. Any

other symptoms which may appear will, therefore, be naturally interpreted in the light of this earlier disease.

When a patient with such a history shows fluid in the abdomen, with anemia, slight fever, and questionable signs at the apex of the left lung, tuberculous peritonitis is by far the most probable diagnosis. The diagnosis could be further supported were the abdomen to be tapped and a high-gravity fluid obtained. This would help us to exclude cirrhosis and syphilis of the liver.

Malignant disease as a cause of ascites should always be remembered in a case of this kind, although we cannot take the idea very seriously in view of the patient's age, his lack of stomach or bowel symptoms, and the absence of any palpable tumor.

A point of interest in this case is the very marked gaseous distention which persisted after the evidences of fluid had disappeared. It should always be remembered that in cases of ascites, from any cause, gaseous distention of the intestinal coils is for some reason or other a very frequent concomitant. At times it is so extreme as to mask the existence of fluid beneath or behind it. Sometimes the obvious gaseous distention weighs far too strongly in our minds and leads us to suppose that if there is so much gas, no disease-producing ascites is likely to be present. But the truth is just the opposite. A belly which is chronically and obstinately distended with gas should be especially suspected of containing free fluid as well.

Outcome.—By the 27th he was up and about the ward and seemed quite strong, though his abdomen was still distended with gas and his bowels difficult to move. His weight had risen from 122 to 127½. pounds. He left the hospital April 30, 1910.

February 12, 1911, his physician reports that he has been at work and had a splendid appetite until February 11th, although for two weeks he has had a cough and night-sweats. The sputa showed many tubercle bacilli. The belly was tense, tympanitic, and showed no evidence of fluid. Weight, 125½ pounds. Both lungs showed coarse moist râles.

Case 312

A salesman of thirty-five entered the hospital May 9, 1910. His family history was unimportant. The patient had measles, whooping-cough, scarlet fever, and diphtheria when young, also several mild attacks of "inflammatory rheumatism," but has never been laid up. Eleven years ago he had typhoid fever and was sick four weeks. He has had occasional sore throats and one attack of influenza. He has

been said to have a weak spot in one lung, and two years ago was sent to Saranac Lake by Dr. E. G. Janeway. He was treated there for several months for tuberculosis. Since then he has worked each winter and rested each summer. He denies venereal disease and takes no alcohol, but until of late has smoked thirty to forty cigarettes daily.

He has been able to attend to business up to January, 1910, when his stomach began to trouble him, distress after eating, abdominal distention, gas, and abdominal pain being the principal troubles. His habitual cough has become more severe, though it is still dry. In connection with his gastric distress he has times of what he calls being "choked up," when he vomits and gets very short of breath. In February he was in a hospital in California for seven weeks, and was treated for stomach trouble without relief. For the past two months his feet have been swollen at night and his eyesight has been getting poor. In spite of all these troubles, his appetite has been good and his bowels have moved daily. His sleep has been disturbed by severe generalized headache. He passes urine twice or thrice at night. He has lost 24 pounds in two years and now weighs 110 pounds.

Physical examination showed a well-nourished man, pupils and reflexes normal, glands the size of beans in the neck, axillæ, and groins. Heart's impulse in the nipple line, fifth space, no enlargement to the right. The aortic second sound slightly accentuated. No murmur. Blood-pressure, 225 mm. Hg., systolic. Lungs hyperresonant with squeaks scattered throughout. At the right base, dulness with feeble breathing and distant voice sounds. Abdomen full, tympanitic throughout, and slightly tender. The liver dulness extended almost to the navel, but the edge of the organ was not felt and the abdomen was otherwise negative. The fundus oculi showed great indistinctness at the edges of the disk, but numerous large hemorrhages and patches of exudate throughout. Throughout most of the patient's six months' stay in the hospital the urine averaged 45 ounces in twenty-four hours, with a specific gravity from 1006 to 1014 and albumin from a slight trace to 0.7 per cent.; sediment a rare hyaline cast, sometimes with a few cells or fat drops adherent. Leukocytes 14,000, 87 per cent. of which were polynuclear; hemoglobin, 90 per cent.

At entrance the patient seemed perfectly comfortable, except for a respiration of 37 and considerable headache. About 7 P. M. he began to vomit, his respirations increased, and he became very nervous. A hot tub bath with a hot pack was given, but the exertion was too much for the patient and he had terrible dyspnea, though the sweating after the bath was satisfactorily profuse. With morphin he had a fair

night, but early the next morning he had an agonizing headache, persistent vomiting, and Cheyne-Stokes breathing, with slight generalized spasms during the period of apnea. Accordingly, 15 ounces of blood were withdrawn and 1 pint of salt solution given under the skin. The systolic blood-pressure fell 55 points, but soon regained its former high level. The patient was somewhat relieved, and thereafter improved under daily hot-air baths with pilocarpin. Although the headache persisted and he rejected almost all food, he had no real convulsion.

On the 12th dyspnea was still troublesome and he complained of faintness. There was marked reduplication of the second sound in the third left interspace and an occasional premature beat. Systolic blood-pressure, 215. There were no râles in the lungs and no edema. Twenty-four ounces of normal saline solution were given under the skin and no rise of blood-pressure followed. At this time the left border of cardiac dulness was 14 cm. from the median line. On the 14th, headache and vomiting continuing, 12 ounces of blood were withdrawn and 1 pint of saline solution injected. He was then given $\frac{1}{4}$ gr. of cocain by mouth and a little food. He retained this, fell asleep, and next morning seemed much better. Thereafter he steadily improved, and by the 21st his dyspnea was gone. He then took food regularly (though in small quantities) and slept fairly. His headache still persisted and he occasionally vomited. Various diuretics, such as sodium theocin acetate, were given without relief. Aspirin, 10 gr., every hour for three days, gave some relief to headache, but $\frac{1}{8}$ to $\frac{1}{6}$ gr. of morphin was needed almost daily to control headache.

On the 31st of May he was doing very well, at times quite free from headache. There had been no return of edema or convulsive movements. Hot-air baths without pilocarpin did not seem to act favorably. Blood-pressure gradually declined to the neighborhood of 150, where it persisted until the second week in June; then it ranged at 170 for two weeks. Any attempts to sit up straight, to stop the hot-air baths, or to bear any excitement produced vomiting and headache at once. June 9th he could read a postal card, though at entrance he could scarcely see people about his bed. It was found an advantage to add lactose to his liquid food in order to increase its value. After the 20th of June his blood-pressure ranged for a month in the neighborhood of 200, but despite this he improved steadily and by the middle of July was in better condition than at any time. He was able to sit up in bed, to read to himself, and he hardly seemed like the same patient. The eye fundus, however, showed no notable change.

On the 18th of July he was able to sit up in a chair without headache

or any other ill effects and was eating ordinary meals without distress. The blood-pressure meantime was ranging higher than at any time, 230 to 250. July 19th he could stand alone, though he could not walk. His abdomen was always markedly prominent, but showed no evident fluid, and his lungs were clear. Shortly after this he became more uncomfortable. During the early part of August all his bad symptoms returned, and on the 12th of August the slightest noise caused twitching. Thereafter his blood-pressure ranged a little lower, in the neighborhood of 200 for the next month, but the urinary output increased and the pulse somewhat improved. About the 16th of August a harsh systolic murmur developed, loudest in the pulmonary area, but audible over the whole precordia. The pulmonic second sound was now greater than the aortic second, the latter sharp but distant. Râles appeared in the lungs and edema over the sacrum. One-eighth grain of morphin with $\frac{1}{20}$ gr. of cocain gave him good nights, but he began at this time to be incontinent. His headaches were more or less relieved by the doses of aspirin, previously mentioned.

On the 24th of August he was almost unconscious. His temperature remained elevated for several days without obvious cause. On the 26th the left border of cardiac dulness was 15 cm. from the median line; the second sound to the left of the sternum was very loud, and a systolic murmur replaced the first sound all over the precordia. Sloughing hemorrhoids were discovered at this time and may have accounted for the temperature. At this time the blood-pressure came down to 160 for a few days, but soon rose again, and on the 14th of September was 220. He lost flesh steadily at this time, though he was able to eat fairly well, and his heart remained strong. Mentally he was very dull. After the 7th of September he had a good deal of mild delirium, chiefly of a happy type.

On the 20th he was a living skeleton, with a large heart beating tirelessly and no evidence of cardiac failure. Two small bed-sores developed at this time. He still ate and slept well. September 22d he became worse and passed almost no urine for forty-eight hours. The blood-pressure was now 150, having been dropping steadily since the 14th; pulse very slow, 45 to 60, regular. There was no marked edema of the legs. The steady decline of temperature, pulse, and blood-pressure during the last two weeks of his life is shown in Fig. 250. He died on the 27th.

Discussion.—A very important group of symptoms points straight toward the diagnosis of tuberculosis in this case; we have, first of all, the dictum of an almost infallible diagnostician, then the habitual

dry cough, the dyspeptic symptoms, and the slight glandular enlargement. There is another point favoring tuberculosis, viz., that the patient has many symptoms in many places, so that we must look for some disease capable of attacking many organs simultaneously. Such diseases are especially tuberculosis, syphilis, streptococcic sepsis, and the malignant neoplasms.

But there is a second group of symptoms not easily explained as part of a tuberculous process. The dyspneic attacks, the swollen feet, the headaches with poor sight, and, above all, the high blood-pressure, retinitis, Cheyne-Stokes' breathing, and convulsions, make it almost certain that we are dealing with a chronic nephritis, and at this patient's age, in all probability, a chronic glomerular nephritis. Amyloid disease of the kidney, such as might be secondary to tuberculosis, would not be at all likely to give us such a group of symptoms as this. The striking thing about amyloid disease, as a rule, is its latency, its colorless, often symptomless, course.

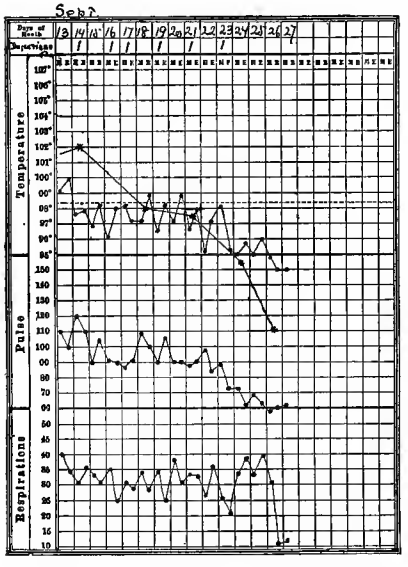

Fig. 250.—Blood-pressure (starred line), temperature, pulse, and respiration during the last two weeks of life in Case 312.

Is there anything in the case not to be explained by glomerular nephritis? I see nothing. Syphilis and malignant disease, which I mentioned in former paragraphs, cannot of themselves produce any such clinical picture, although it is, of course, possible that the nephritis may have been of syphilitic origin.

Outcome.—Autopsy showed chronic glomerulonephritis, arteriosclerosis, hypertrophy and dilatation of the heart, myomalacia of the heart's wall near the apex, with mural thrombi in this region and each side of the septum. Also thrombi in the right and left auricular appendages. There were infarcts in the lower lobes of the lungs and thromboses of small branches of pulmonary arteries; acute terminal pericarditis and pleuritis; obsolete tuberculosis of a tracheal lymphatic gland; small papillary adenoma of the kidney. The absence of any considerable evidence of tuberculosis is striking; also the absence of any infection of the circulating blood.

Case 313

A housewife of forty-seven entered the hospital January 6, 1911. The patient has noticed enlargement of the abdomen for about eight years. At first it was larger than it now is. The present size has been maintained for about five years. Otherwise she has always been well, though formerly subject to tonsillitis and troubled for a few days, eight years ago, by an attack of "malaria," in Nashua, N. H. She was in bed four days with chills and fever. Family history and habits are excellent. Menstrual flow has been excessive for seven years, and she

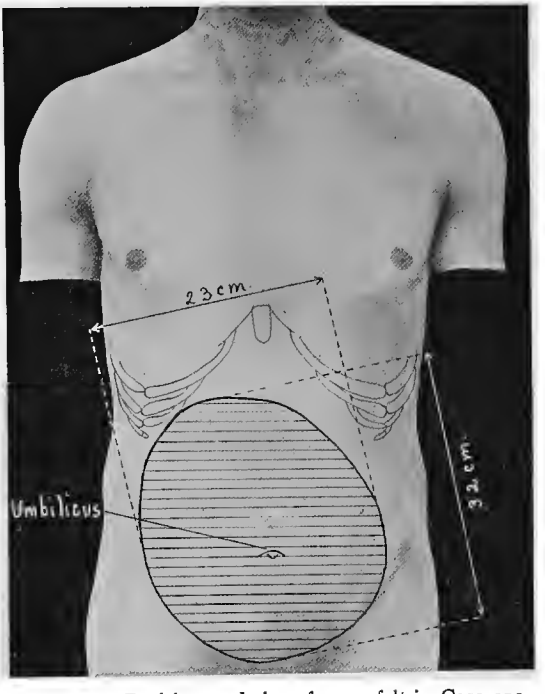

Fig. 251.—Position and size of mass felt in Case 313.

has grown increasingly pale and weak during this period. She worked until to-day, taking care of her house and doing all the cooking and sewing for her husband and six children, but not washing. Five months ago she weighed 190 pounds; a week ago, 176 pounds. Her appetite is good, bowels costive, urination not remarkable. She suffers no pain whatever.

Physical examination showed good nutrition, ivory-colored skin, marked pallor of the mucous membranes. No glandular enlargement, pupils and reflexes normal. Chest negative. Abdomen was generally

enlarged; also a mass as in Fig. 251. The mass there shown filled two-thirds of the abdomen, was firm, freely movable, elastic, and not tender. Otherwise the abdomen was not remarkable. There was considerable edema of both legs and marked varicose veins in the same area. At entrance red cells numbered 1,900,000; white cells, 5000; hemoglobin, 25 per cent. The stained smear showed marked achromia, with considerable variations in size and shape, no abnormal staining reaction or nucleated cells. Blood-platelets, 160,000. In twenty days the red cells rose to 4,500,000, hemoglobin to 70 per cent., white corpuscles to 8000. The urine averaged 45 ounces in twenty-four hours, with a specific gravity of 1015, a trace of albumin, and no casts. Systolic blood-pressure, 125. Feces normal. During this time she took Blaud's mass, 20 gr., three times a day. After the first two days there was no flowing. Vaginal examination showed her cervix high in the median line behind the pubes, but continuous with the abdominal tumor. The diagnosis in the medical wards was in doubt as between ovarian cyst and uterine fibroid. Dr. W. J. Mayo saw the patient and considered it fibroid. Dr. Farrar Cobb made the same diagnosis.

Discussion.—There are not many causes for an abdominal enlargement lasting eight years in a woman of forty-seven. Aside from obesity and gaseous distention, there is hardly anything but uterine fibroid and ovarian tumor. The fact that she has been steadily and vigorously at work, and that she is still well-nourished, makes any malignant type of disease improbable. Between fibroid and ovarian cyst, the amenorrhea and the uterine hemorrhages strongly favor the diagnosis of fibroid. The elasticity and free mobility of the mass is slightly in favor of cyst, though I have learned to distrust all inferences based chiefly upon such characteristics of a pelvic tumor. The position of the cervix uteri is a further point in favor of fibroid.

Outcome.—On the 2d of February the abdomen was opened, showing a small amount of free fluid and a tumor of soft gelatinous consistency, rather tense, but showing no large firm parts anywhere. Hysterectomy was done. Examination of the growth by Dr. W. F. Whitney showed the uterus greatly enlarged by a single growth weighing 4450 gm. The uterine cavity was enlarged, measuring 14 cm. On section the growth was fasciculated, its meshes being filled with serous fluid. These meshes were shown under the microscope to be formed of interlacing bunches of fibrous and muscular tissue. Diagnosis, fibromyoma with lymphatic dilatation, so-called cystic fibroid. The patient made an excellent recovery. On November 1, 1912, she seemed entirely well and had gained 60 pounds.

Remarks.—That a patient who has but 1,900,000 red cells should patiently continue to do the whole work for her husband and six children is a type of familiar heroism to which, despite its familiarity, I cannot forbear to allude.

Case 314

An unoccupied woman of thirty-five entered the hospital May 13, 1911. The patient has always been well, though she had scarlet fever and measles as a child. As the oldest of twelve children she did all sorts of work until ten years ago. Then she had a sudden swelling of the abdomen, accompanied by severe general abdominal pain, which confined her to bed for several weeks. She had no vomiting, but has never felt really well since that time. Any excitement or strain produces severe headaches and general aching all over the body. She passes at times large quantities of very pale urine, often getting up five to ten times at night, but she is able to pass it only when she is calm. Her bowels always move with difficulty, and there is a dull ache in that region most of the time. Distention of the abdomen is present off and on in varying amounts. It is always greater at night and her sleep is very poor. For a year she has had a slight cough without any sputa. Moderate exertion makes her tired and short of breath, but she has never had orthopnea or edema. She is now at her maximum weight, 110 pounds. Appetite is fair, but she has little ambition for food. Menstruation is regular, but scanty.

Physical examination shows good nutrition, normal pupils and reflexes, no glandular enlargement, chest negative. Abdomen full and very prominent, tympanitic everywhere, no tenderness. Slight general rigidity. Liver and spleen apparently not enlarged. Navel not flushed. A slight degree of ankle-clonus on each side, perhaps voluntary. Rectal examination negative. Blood, urine, and blood-pressure normal. No temperature in one week's observation. Calomel and sodium sulphate produced fourteen movements in two days, but the size of the abdomen did not change. It was unaffected by turpentine stupes or by the rectal tube. On the 19th she went home.

Discussion.—The long duration of this case is its most interesting feature. It has lasted ten years. The abdominal enlargement which she now complains of was her first symptom and she has it still. She also has symptoms in various other parts of her body and one group of urinary symptoms suggesting the vasomotor instability of the neurotic. The anorexia, insomnia, and headaches from any strain point in the same direction.

There is, however, a small group of symptoms pointing in another direction; that is, her year of slight cough with dyspnea and distention of the abdomen, which might mean tuberculous peritonitis, especially as physical examination shows slight general rigidity, the precise characteristic of the tuberculous abdomen.

Yet the other and larger group of symptoms is, on the whole, the more important, for she has had the abdominal trouble throughout, and it is exceedingly improbable that tuberculous peritonitis should last ten years without producing any loss of weight. The fact that she is now at her maximum weight is almost sufficient to exclude organic disease.

If, then, we exclude organic disease, can a neurosis account for her abdominal enlargement? It is well known that gaseous distention often accompanies and sometimes conceals ascites. It is, therefore, conceivable that there may be some organic trouble in the background, but we can only say that we have done our best to find such and failed.

Outcome.—July 25, 1914, a friend of the patient writes that since leaving the hospital she has been quite well when quiet, but under any mental strain or worry her bowels almost immediately become distended to an enormous size, causing great distress and pain and stopping the action of the bladder and bowels. Rest and sleep dispel these symptoms, but anything that happens out of the ordinary, causes the abdomen to swell up almost immediately. She is physically well and contented.

Case 315

An unoccupied woman of fifty-eight entered the hospital October 31, 1911. A year ago the patient began to have sharp attacks of pain in the lower abdominal region, rather more to the right. The pain was not definitely related to the taking of food. At the same time the abdomen became somewhat enlarged, and after a week she began to vomit frequently, so that for the next ten days she kept almost no food in her stomach. After that she was better, but her symptoms have recurred every few weeks, lasting from three to seven days. For six months she has vomited once or twice almost daily. Her pain has become more frequent, but less sharp. The abdominal enlargement has steadily increased during the last six months, but the rest of her body, she thinks, has emaciated. Her legs are swollen somewhat in the daytime, but not more than they have always been, as she has always had varicose veins. She has tried to keep at work during the year, but has often had to give up for days or weeks and for the last fortnight has done nothing. Her bowels often do not move for three or four days. She has no jaundice.

Physical examination shows marked emaciation, good color, pupils and reflexes normal, no glandular enlargement. Chest negative. Abdomen dome shaped, much distended, with an elastic feel, and a marked fluid wave transmitted to the top as well as to the sides of the abdomen. The abdomen does not sag into the flanks; it is everywhere dull and nowhere tender. Liver and spleen are not felt. The legs show slight edema and marked varicosity of the veins. The cervix uteri is high, not otherwise remarkable. There is no drag upon the cervix when the abdomen is manipulated. The fundus not made out. In the median line, just below the navel, is a hard, smooth, almost immovable mass, the size of an egg. Blood and urine normal. No temperature in two weeks' observation. Systolic blood-pressure, 156 mm. Hg.; diastolic, 80 mm. Hg.; weight, 91 pounds.

Discussion.—A year of abdominal symptoms in a woman of fifty-eight, previously well, are always ominous symptoms. One always fears malignant disease, especially when, as in this patient, there has been vomiting and swelling of the legs. The latter symptom, however, need not alarm us, as it is, in all probability, due to her varicose veins and is by no means a new symptom.

Much more serious is the marked emaciation, as shown on physical examination, and the apparent presence of an ascites. We cannot attribute such an ascites to the heart or to the kidney. It is not likely to be of liver origin at her age and with her history. It does not present the picture of tuberculous peritonitis. The only common cause for ascites that remains is tumor, usually a malignant tumor in some part of the abdomen. The hard, smooth mass below the umbilicus is, in all probability, part of such a tumor. It is possible that the ascites may be associated with a benign tumor, such as an ovarian fibroma, ovarian cystoma, or a fibroid uterus, but no one of these is a frequent cause of ascites. On the whole, we have reason to fear malignant disease. In any case the abdomen must be opened.

Outcome.—On the 7th of November, 1911, an ovarian cyst about 15 inches in diameter was removed. It contained about 6 quarts of fluid and was not adherent. It apparently originated from the left ovary. The patient did well after operation, and December 3, 1912, reported at the hospital in perfect condition.

Remarks.—This case was sent to the hospital as one of ascites, but this diagnosis was never seriously considered. The shape of the abdominal enlargement was wholly unlike ascites, and the ordinary causes of ascites could with reasonable probability be excluded.

Case 316

A housewife of forty-eight, born in Russia, entered the hospital January 19, 1912. Ten years ago the patient fell, striking her right side. Since then she has noticed pain in the right flank and back, gradually growing more severe. For five weeks she has noticed abdominal enlargement, and her sleep has been disturbed at night by the pain above described. For a month her urine has been scanty and painful in passing. She has no appetite and food causes discomfort or nausea. At the onset of her troubles she vomited occasionally,

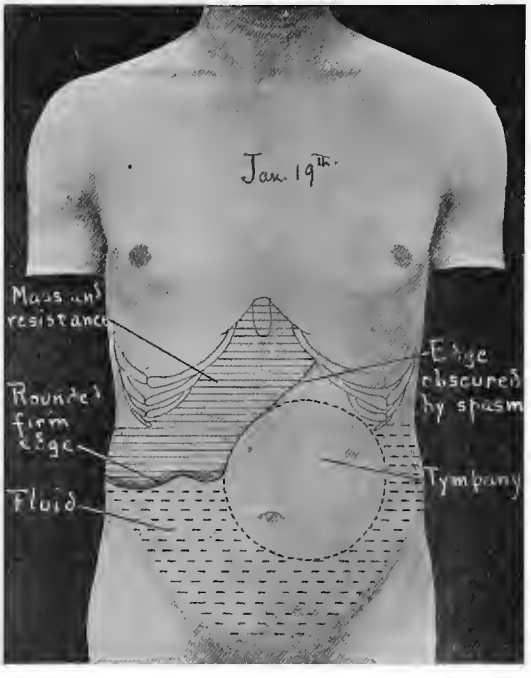

Fig. 252.—Condition of abdomen in Case 316 on January 19, 1912.

but has not done so now for some weeks. She has been in bed for the past month on account of pain and weakness. She thinks she has lost flesh. Three days ago her feet became swollen.

Physical examination shows much emaciation. Slight general brownish pigmentation of the skin. Pupils, glands, and reflexes normal. Chest negative save for moist râles at the right base behind. The abdomen was greatly enlarged and tense, the right side in the region of the liver especially prominent. In the right flank and epigastrium a mass can easily be felt, as shown in Figs. 252–254. Impulse

exerted upon the mass in front is plainly transmitted to the costovertebral angle. There is shifting dulness in the dependent portions of the abdomen and tympany about the navel. Liver dulness reaches up to the sixth rib, mammary line. Spleen not felt. There is moderate soft edema of the feet and legs. Wassermann reaction is negative. Urine negative. Blood showed a leukocytosis varying from 22,000 to 24,500, with polynuclear cells greatly in excess. No temperature in a week's observation. Blood-pressure normal. By tapping the abdomen 4700 c.c. of fluid were withdrawn. It was clear, yellowish, with a specific gravity of 1016, sediment mostly lymphocytes.

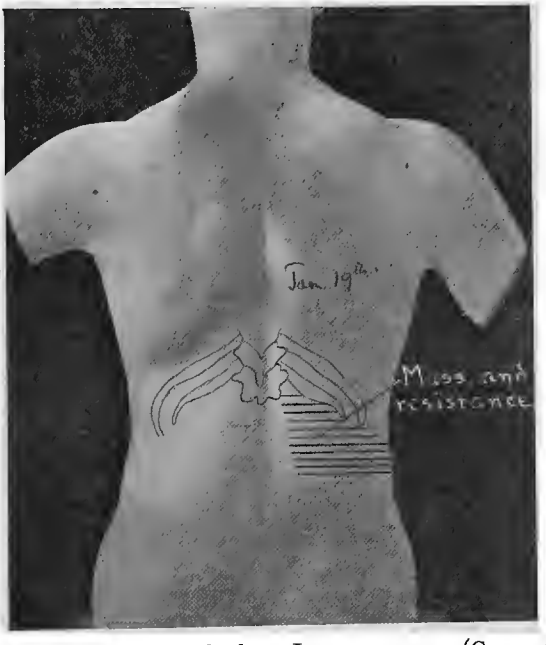

Fig. 253.—Signs in the back on January 19, 1912 (Case 316).

Discussion.—In all probability the patient's pain in the right flank and back, the pain which she has had for ten years, has no connection with her present troubles, and may very possibly represent the results of some traumatic strain or sprain.

We may reasonably suppose that the problem now to be solved is the cause of the five weeks of painful abdominal enlargement, with dyspepsia, vomiting, loss of flesh and strength. At her age this is an alarming group of symptoms, as physical examination shows a mass occupying the usual site of the kidney or liver. Its possible connection with the kidney is further hinted at by the painful urination. On the

other hand, the negative condition of the urine points against this, and the outline of the mass, as seen in Figs. 253 and 254, certainly suggests liver rather than kidney.

The fluid obtained by tapping has the specific gravity generally associated with malignant disease or tuberculosis. Against tuberculosis is the size and situation of the tumor, the absence of fever, and the presence of leukocytosis; also the patient's age.

Syphilis is suggested by the apparently nodular surface of the mass in the hepatic region. The negative Wassermann reaction tends to

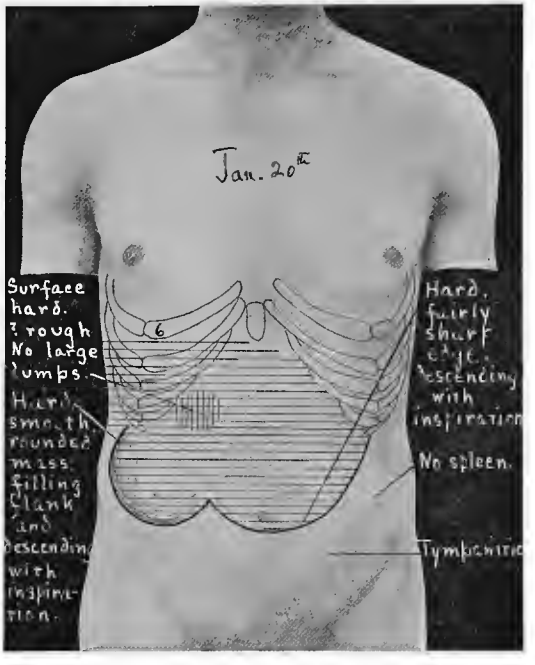
Jan. 20th
Surface hard. ? rough No large lumps.
Hard, smooth rounded mass filling flank and descending with inspiration.
Hard, fairly sharp edge, descending with inspiration
No spleen.
Tympanitic

Fig. 254.—Abdominal mass as outlined on January 20, 1912.

exclude this, but does not absolutely do so. If it were a syphilitic liver, we should expect enlargement of the spleen and possibly some fever.

If all these possibilities are excluded, cancer of the liver remains as the most probable diagnosis. Such cancer is usually secondary to a gastric neoplasm, and the history seems to begin with gastric symptoms. Such a diagnosis will explain everything except the brownish color of the skin. That color is compatible with any of the diagnoses which we have considered, but characteristic of none. It remains unexplained.

Outcome.—Dr. W. M. Conant advised against operative interference. Antisyphilitic medication had no effect. The patient left the hospital, unrelieved, on the 26th.

Case 317

A housewife of fifty-nine entered the hospital October 31, 1911. The patient's chief complaint is of abdominal enlargement and of stomach trouble. Her father died of shock, one brother of enlarged liver and ascites. Two other brothers and one sister died in infancy. Her husband has recently had two operations for rectal fistula. The patient has three living children and has had three miscarriages, but, save for an attack of bronchitis two years ago, has never been sick. She entered the hospital with a diagnosis of "cirrhosis of the liver." She takes tea in very large amounts, often 2 quarts a day. She denies alcohol. The menopause occurred fourteen years ago.

The abdominal enlargement was first noticed six months ago, and her clothes began to seem notably tight about her waist. Since then the abdomen has uniformly and very gradually increased in size. Occasionally she has rather sharp pains of a few minutes' duration, running from the flanks either toward the navel or toward the pelvis. These pains do not appear to be related to food, to the time of day, or to the state of her bowels.

For about six years she has had attacks of what she calls "indigestion," coming from once a month to once in three months, lasting about three days. In these attacks she loses her appetite, has nausea, and usually some vomiting, but no pain or jaundice. These attacks have not increased either in frequency or in severity. In the intervals between them she has occasional epigastric distress and eructations of gas. She has never vomited blood and has never had any morning nausea or vomiting. For the past six months she has noticed slight edema of the lower legs at night and frequent cramps in the calves and thighs, sometimes waking her from sleep. During the past year she has passed urine once to thrice in the night and very frequently in the daytime. Occasionally urine is passed involuntarily. She has no cough, no shortness of breath. Bowels are usually constipated, with occasional attacks of diarrhea. She does not know her exact weight, but thinks she has become a little thin. She has had no fever or night-sweats.

Physical examination showed an obese, nervous old lady. The heart's apex reached 1 cm. outside the midclavicular line. There was a soft systolic murmur, best heard along the left sternal margin. The

aortic second was sharp and accentuated. The radial arteries showed thickening. Systolic blood-pressure, 150 mm. Hg.; diastolic, 80 mm. Hg. Blood and urine normal. Lungs normal. The abdomen was full and distended; tympanitic between the navel and the ensiform. Liver and spleen not felt. At entrance there seemed to be some shifting dulness in the flanks, but the next morning this could not be demonstrated and it was not observed thereafter. The stomach-tube showed no contents in the fasting stomach. Capacity of the organ was 1800 c.c. After a test-meal stomach contents showed free HCl .046; total acidity, .083 per cent. Guaiac negative. Feces negative.

Discussion.—The history is of six months' abdominal enlargement in a woman of fifty-nine with dyspeptic symptoms and slight edema of the lower legs. Physical examination does not demonstrate the presence of any fluid or of any solid tumor in the abdomen. The results of gastric analysis are practically negative. There is no gaseous distention, though a small area of tympany is to be marked out high up above the navel.

Judging from the cramps, the rather high systolic blood-pressure and pulse-pressure, and the thickening of the radial arteries, we may conjecture that she has some arteriosclerosis. That is very natural at her age, but it is not at all probable that this accounts for any abdominal enlargement, although it may well account for abdominal discomfort. On the whole, the best judgment that we could make in this case was that the patient was fat, but otherwise fairly healthy.

Outcome.—The patient went home on the 6th with a diagnosis of obesity. On February 12, 1913, her daughter wrote that she was quantitatively and qualitatively about the same. She still has cramps off and on.

INDEX

[Words and page numbers printed in heavy type correspond to illustrative cases; other words and numbers, to minor discussions.]

Abdominal enlargement, 649–704
Abscess, axillary, 70, 597
pulmonary, 448
after tonsillectomy, 453
of spleen, 584
subdiaphragmatic, 584
Acid-fast organisms, 440
Actinomycosis, 64, 421
Addison's disease, 148, 164, 340
Adenitis, cervical, 393
septic, 389
syphilitic, 47
tuberculous, 401, 402
Adhesions, 346
harmlessness of, 212, 241, 300
Alcoholic neuritis, 465
Alcoholism, 151, 215, 302, 321, 417, **483, 485,** 544, **642**
tremor in, 639
Alternation, 625
Amebic dysentery. See *Dysentery.*
Amœba coli and the pathogenic amebæ, 224
Anemia in cancer, 334
myelophthisic, 579
pernicious, 231, 233, 334, 471, 554, 582, 587, 592, 595, **631**
diagnosis of, 472
edema of face in, 418
pulsating tumors in, 234
secondary, 577, 696
splenic, 367
Aneurysm, 92, 141, 434, 569, **571, 572**
aortic, 566
Angina Ludovici, 429
pectoris, 255
Angioma, 61
Antrum, empyema of, 424
Aortitis, syphilitic, 387, **594,** 602
Aphonia, hysteric, 563
Appendicitis, 197
chronic, 275, **686**
Arhythmia, 622–638
causes of, 622, 624
sinus, 623, **636**
Arm, swelling of, 597–611
causes of, 597
Arteriosclerosis, 154, 162, 165, 317, 320, **487, 488,** 518, 544, **550,** 704
cerebral, 551, 553, 617, 625
Ascites, 17, **649–704**
causes of, 649
fibromyoma of uterus, 655
gaseous distention in, 690, 698
ovarian tumor, 655
rate of accumulation in, 654
Ataxia, vasomotor, 427

Bacillus coli, infection with, 202
Bence-Jones' body, 395
Bilharzia disease, 225, 414. See also *Rectum.*
Bladder, stone in, 504
Blood in stools. See *Melena.*
Blood-pressure, border-line readings of, 480
Bothriocephalus latus, anemia, 595
Brain tumor, 544
Branchial cyst, 375, 376
Bronchitis, 306

Cancer of appendix, 115
of bladder, 196
of cecum, 85, 115
chronicity of, 36
diffuse, of peritoneum, 235
of gall-bladder, 272, **292**
of intestine, 181, 256
multiple, of skin, 62
of ovary, 41
rectal, 409
of sigmoid, 201
of stomach, 100, 103, 235, 268, **329,** 336, **341, 354, 413, 577, 700**

Cancer of thyroid, 380
of Vater's papilla, 282
Cerebellar cyst, 154
tumor, 167
Cerebral tumor, 145, 167, 257, **276**
Cervical rib, 37
Chlorosis, 311, 581, 620
Cirrhosis, 360, 364
hepatic, 609, **670, 673, 676, 680,** 688
hydrothorax in, **670**
Coccidioidal disease, 63
Colitis, 176, 182, 211, 216, **219, 243, 248,** 306
infectious, 200
mucous, 184, 241
tuberculous, 216
ulcerative, 248, 412
Coma, hysteric, 542
Congenital heart disease. See *Heart.*
Constipation, 211, 240, **277, 289**
Cystitis of streptococcus origin, 500

Delirium, 612–621
causes of, 612
in children, 612
postfebrile, 616, 618
tremens, 612
Dementia paralytica, 145
Diabetes, complicating, 540
Diarrhea, 175–249
acute and chronic, 176, 185
alimentary, 207, 215
causes of, 176, 178
infectious, 200
morning, 181
nervous, 194, 206
proctoscopy in, 183
prognosis of, 184
stools in, 183
types and diagnosis, 183
of unknown cause, 214, 246
Diet, bad, 288, 327
in diarrhea, 178
Digestion, inhibition of, 258
Diverticulitis perforating the bladder, 498
Drug eruptions, 419
Dry skin in pyloric stenosis, 338
Duodenal ulcer. See *Peptic ulcer.*
Dysentery, acute bacillary, 488
amebic, 223, **244, 415**
Dyspepsia, 250–349
after forty, causes of, 265
causes of, 250, 257
nervous, 344
Dyspepsia in phthisis, 307, 332
unknown cause, 293, 326

Echinococcus of liver, 29, 132
Edema, angioneurotic, 419, **426**
of face, 417–431
of legs, 465–493
causes of, 465
Elephantiasis, 466, **489**
operation for, 491
Emaciation despite good appetite, 267
Endocarditis, acute, 220
mitral, 235
and aortic, 221, 476
and nephritis, 223
streptococcic, 476, 547, 593
Epilepsy, minor, 542
Erysipelas, 425
Erythema multiforme, 482
nodosum, 60
Exostoses, multiple, 63

Fainting, 541–557
causes of, 541
Fat, intolerance of, 179, **190**
Fecal impaction, 130
Fever after hemorrhage, 314
unknown cause, 296
Fibromyoma of uterus, 28, 31, 346, **695**
uterine, ascites in, 655
Flat-foot, 470
Frequency due to psychic causes, 518
in daytime, 501
from habit, 505
nervous, 501
with antiflexion, 502
Frequent micturition and polyuria, 495–540
causes of, 495

Gall-stones, 116, 255, **274, 318**
Gaseous distention of intestine, 698
Gastric cancer. See *Cancer.*
dilatation, an entity, 271
tests for, 261, 271
symptoms in hydronephrosis, 280
Gland puncture, 374
Glanders, 52, 64
Glands, 369–405
drainage areas, 369
enlarged, 369
septic, 389
and what stimulates them, 374
Glandular enlargements, four types, 373

Glandular tumors, nomenclature of, 374
Glomerulonephritis, chronic, 464, **480, 517**
subacute, 487
Gumma. See *Syphilis.*

Heart disease, congenital, 440
Heat stroke, 150
Hematemesis, 332, **350–368**
causes of, 350
Hemophilia, 358
Hemoptysis, 432–464
causes of, 432
and malingering, 458
from stomatitis, 458
tuberculous, 432, 463
Hemorrhage in **cirrhosis, 361**
Hepatic cirrhosis, 487
Hepatitis, interstitial. See *Cirrhosis.*
Hereditary trophedema, 466
Hoarseness, 559–574
causes of, 559
Hydrocephalus, internal, 359
Hydronephrosis, 280, **503**
intermittent, 51
Hypernephroma, 39, 41, 49, 125, **126,** 382, 387
Hysteria, 153, 157, **271,** 427, **556, 557, 619, 646**
Hysteric aphonia, 559, **563**

INFARCT, pulmonary, 434
Intussusception, 181

JAUNDICE, hemolytic, 110

Kidney, stone in, 119, 288

Labyrinthine disease, 147, 173
Labyrinthitis, specific, 387
Laryngeal syphilis, 562
Laryngitis, 559, 561
psychic factors in, 559
syphilitic, 428. See also *Syphilis.*
Larynx, papilloma of, 567
Lead-poisoning, 164, 256, 286, 320, 640, 688
Leather-bottle stomach, 235
Leprosy, 65
Leukemia, 33, 70, 72, **334**
lymphoid, 383, 386, 398, 579
Leukopenia, 399
Lineæ albicantes, 355, 356
Lipomatosis, 58, **76**
Liver, cirrhosis of, 283, 310, 352, **359,** 466
Liver, corset lobe of, 34
Lumps under skin, 54
Lung, gangrene of, 455
Lymphadenoid tissue, minute collections of, 372
Lymphoblastoma, 47, 69, 72, 74, 90, 127, 189, **192, 378, 381,** 386, **387, 394, 405, 684**
of skin, 61, **130**
types of, 394

Malaria, 621
tertian, 420
Malingering, 460
Mediastinal tumor, 560, **569,** 597, 601
Melena, 406–416
causes of, 406
Ménière's syndrome, 171
Mitral disease, hemoptysis in, 435
stenosis, 235, 352, **629,** 637, **647**
Morphinism, 228
Multiple sclerosis, 640, **648**
Mumps. See *Parotitis.*
Mural thrombi, 518
Myeloma, 125, 382, **396**
Myocardial weakness, 160
Myomalacia, 518
Myositis, 64
Myxedema, 419, 466

Nephritis, 139, 142, 152, 181, 221, 251, **264, 278**
acute, 427, 484, 494
glomerular, 589
amyloid, 306
chronic, 468
vascular, 430
edema of face in, 417
endocarditis, 223
glomerular, 547, **679, 691**
streptococcus, 484
Nephroptosis, 34
Neurasthenia, 193, 323
Neuritis, simple, 644
Neuroblastoma, 390
Neurofibromatosis, 56
Night-sweats, 363

Obesity, 703
Old age, diseases of, 329
Osteitis deformans, 41
Osteomyelitis, 599
Otitis media, 200, **614**
Ovarian tumor, ascites in, 655
Ovary, cancer of, 45

Ovary, cystadenoma of, 31, 43, 344, 668, 682, 696, **699**
fibroma of, 353, **678**

Pallor, 575–596
causes of, 575
Palpitation, 622–638
causes of, 622
Pancreas, cancer of, 75
Paralysis agitans, 640
Parkinson's disease, 640, **643**
Parotitis, 421
septic, 421
Pellagra, 611
Pelvic abscess, retroperitoneal, 499
Peptic ulcer (gastric or duodenal), **259,** 311, **314, 352,** 359, **364,** 365, **546, 591**
Pericarditis, chronic adhesive, 609, 665, **681**
terminal, 518
tuberculous, 606
Periostitis, syphilitic, 58
Peritonitis, chronic, 321
tuberculous, 80, 103, **198, 209,** 493, **509, 675, 679, 686,** 688, **689,** 698
Phantom tumors, 122
Phlebitis, 465, **469, 477,** 597, **598, 601, 602,** 606, 609
Phthisis, 435, 440, 444, 452, 461, 462, 492
Plumbism. See *Lead.*
Pneumaturia, 498
Pneumonia with hemoptysis, 442
Portal thrombosis, 686
Pregnancy, 27, 251, **284,** 417
ectopic, 77
Proctoscopy, 183
Psychic diagnosis, 42
factors in dyspepsia, 257
Psychoneurosis, 323
Psychotherapy, 505
"Ptomain-poisoning," 179, 686
Pulmonary abscess, 448. See also *Abscess.*
apoplexy, 464
embolism, septic, 450
Pyelonephritis, 508
Pylephlebitis, 686
Pyloric spasm, 316
Pyonephrosis, 120, 287

RECTAL stricture, 237
Rectum, bilharziasis of, 414
cancer of. See *Cancer.*
Renal tuberculosis, 513
pain and tumor in, 512
Rest, benefits of, 345
dangers of, 324
Retroversion, vomiting in, 361
Rheumatic nodes, 59
Rib, cervical, 39

SALICYLATES, delirium from, 613
Salvarsan in pernicious anemia, 588
Sarcoma, melanotic, of liver, 124
Sclerosis, multiple, 640
Scurvy, 64
Sepsis, 59
Skin lesions associated with edema, 417
Social maladjustment, 304, 312, 325
Somnolence in trichiniasis, 242
Splenic anemia. See *Anemia, splenic.*
Sputum inoculation, 440, 461
Staphylococcus vaccine, 389
Starvation, 211, 345
causing dyspepsia, 254
Stenosis, mitral, 629, 637
Stockton, C. G., 139
Stokes-Adams' disease, 553
Stomach, cancer of. See *Cancer.*
ulcer of. See *Peptic ulcer.*
Stone in bladder, 504
in kidney, 288
Stools, examination of, 183
pus in, 188
Sunstroke, 150
Surgery, meddlesome, 205, 300
Swelling of arm, 597–611
causes of, 597
of face, 417–431. See also *Edema.*
causes of, 417
Syphilis, 79, 87, 93, 94, 97, 105, 107, 150, 153, 155, 157, 172, 237, 310, 571, 582, **644**
cardiac, hepatic, and cerebrospinal, 481
cerebrospinal, 392
hepatic, 657, 673, **683, 688,** 702
of larynx, 429, 574
renal, 660, **662**
Syphilitic aortitis, 387

Tabes, 228, 255, 291, **316, 322, 348, 363**
surgical blunders in, 229
varieties of bellyache in, 256
Tachycardia, neurotic, 626, **635, 636**
paroxysmal, 623, **627**
Tetany, 269
Thrombosis, cerebral, 620
of inferior cava, 29
portal, 686

Thyroid, cancer of. See *Cancer.*
Thyrotoxicosis, 622, 626, 627, **628, 633, 637**
tremor in, 639
Tobacco, palpitation from, 635
Tonsillar inflammation, origin of, 372
Transfusion, 367, 368
Tremor, 639–648
causes of, 639
senile, 639
Trichiniasis, 241, 422
facial edema of, 418
with general edema, 473
technic of blood examination in, 423
Tuberculin, 326
Tuberculosis, 251, 540
cecal, 186
of ileum, 493
of intestine, 180, **189,** 215, 219
miliary, 159, 169, 492
with mitral stenosis, 438
pulmonary, 307, 321, 326, **332,** 510
renal, 511, 513
of skin, 58
of spine, 326
Tuberculous peritonitis, 80, 103, **198, 209,** 493, **509, 675, 679, 686,** 688, **689,** 698
Tumors, abdominal, 17, 189
diagnosis of, 17–133
phantom, 67, 122
Typhoid fever, 146, 202, 239, 247, 410, 614
infection in gall-bladder, 508
Typhus fever, 202, 419

UREMIA, 618
Urticaria, 60

VARICOSE veins, 465
Vascular crisis, 550, 553
Vertigo, 134–174
aural, 137, **147,** 171, **173**
in brain disease, 136, **162**
causes of, 135
of circulatory origin, 161
in epilepsy, 138
neurotic, 137
pathologic, 136
physiologic, 134
toxic, 139
Vomiting at menstruation, 361
treatment of, 269

SAUNDERS' BOOKS

on

Pathology, Physiology
Histology, Embryology
Bacteriology, Biology

W. B. SAUNDERS COMPANY

WEST WASHINGTON SQUARE PHILADELPHIA

9, HENRIETTA STREET COVENT GARDEN, LONDON

Prentiss' Embryology

Laboratory Manual and Text-Book of Embryology. By CHARLES W. PRENTISS, PH. D., Professor of Microscopic Anatomy, Northwestern University Medical School, Chicago. Large octavo of 400 pages, with 368 illustrations, 50 in colors. Cloth, $3.75 net.

JUST ISSUED

Prof. Prentiss' new work has many features that make it extremely valuable to students and teachers of vertebrate or human embryology. It is the only recent single volume describing *the chick and pig embryos* usually studied in the laboratory; and at the same time it gives a concise, systematic account of human embryology. The descriptions of the embryos to be studied in the laboratory are concise, yet they are profusely illustrated, the majority of the pictures being original.

It is the only comparatively brief text in which a large number of original dissections of pig and human embryos are described and illustrated, and in which directions are given for making dissections of the nervous system, viscera, face, palate, and tongue of these embryos. Of the same embryos from which series of transverse sections have been made, illustrations are given, showing the external form and internal structure. The student will thus be enabled to determine the position and plane of section of each section studied. There are, in addition, original illustrations of the development of the heart, urogenital organs, and nervous system. The book contains 368 illustrations, 50 in colors.

Mallory's Pathologic Histology

Pathologic Histology. By FRANK B. MALLORY, M. D., Associate Professor of Pathology, Harvard University Medical School. Octavo of 677 pages, with 497 figures containing 683 original illustrations, 124 in colors. Cloth, $5.50 net; Half Morocco, $7.00 net.

REPRINTED IN THREE MONTHS

Dr. Mallory here presents *pathology* from the morphologic point of view. He presents his subject biologically, first by ascertaining the cellular elements out of which the various lesions are built up; then he traces the development of the lesions from the simplest to the most complex. He so presents pathology that you are able to trace backward from any given end-result, such as sclerosis of an organ (cirrhosis of the liver, for example), through all the various acute lesions that may terminate in that particular end-result to the primal *cause* of the lesion. The *illustrations* are most beautiful.

Dr. W. G. MacCallum, *Columbia University*

"I have looked over the book and think the plan is admirably carried out and that the book supplies a need we have felt very much. I shall be very glad to recommend it."

Howell's Physiology

A Text-Book of Physiology. By WILLIAM H. HOWELL, PH.D., M. D., Professor of Physiology in the Johns Hopkins University, Baltimore, Md. Octavo of 1020 pages, 306 illustrations. Cloth, $4.00 net.

THE NEW (5th) EDITION

Dr. Howell has had many years of experience as a teacher of physiology in several of the leading medical schools, and is therefore exceedingly well fitted to write a text-book on this subject. Main emphasis has been laid upon those facts and views which will be directly helpful in the practical branches of medicine. At the same time, however, sufficient consideration has been given to the experimental side of the science. The entire literature of physiology has been thoroughly digested by Dr. Howell, and the important views and conclusions introduced into his work. Illustrations have been most freely used.

The Lancet, London

"This is one of the best recent text-books on physiology, and we warmly commend it to the attention of students who desire to obtain by reading a general, all-round, yet concise survey of the scope, facts, theories, and speculations that make up its subject matter."

Mallory and Wright's Pathologic Technique

Fifth Edition

Pathologic Technique. A Practical Manual for Workers in Pathologic Histology, including Directions for the Performance of Autopsies and for Clinical Diagnosis by Laboratory Methods. By FRANK B. MALLORY, M. D., Associate Professor of Pathology, Harvard University; and JAMES H. WRIGHT, M. D., Director of the Pathologic Laboratory, Massachusetts General Hospital. Octavo of 500 pages, with 152 illustrations. Cloth, $3.00 net.

In revising the book for the new edition the authors have kept in view the needs of the laboratory worker, whether student, practitioner, or pathologist, for a practical manual of histologic and bacteriologic methods in the study of pathologic material. Many parts have been rewritten, many new methods have been added, and the number of illustrations has been considerably increased.

Boston Medical and Surgical Journal

"This manual, since its first appearance, has been recognized as the standard guide in pathological technique, and has become well-nigh indispensable to the laboratory worker."

Eyre's Bacteriologic Technic

Bacteriologic Technic. A Laboratory Guide for the Medical, Dental, and Technical Student. By J. W. H. EYRE, M. D., F. R. S. Edin., Director of the Bacteriologic Department of Guy's Hospital, London. Octavo of 520 pages, 219 illustrations. Cloth, $3.00 net.

NEW (2d) EDITION, REWRITTEN

Dr. Eyre has subjected his work to a most searching revision. Indeed, so thorough was his revision that the entire book, enlarged by some 150 pages and 50 illustrations, had to be reset from cover to cover. He has included all the latest technic in every division of the subject. His thoroughness, his accuracy, his attention to detail make his work an important one. He gives clearly the technic for the bacteriologic examination of water, sewage, air, soil, milk and its products, meats, etc. And he gives you good technic—methods attested by his own large experience. To any one interested in this line of endeavor the new edition of Dr. Eyre's work is indispensable. The illustrations are as practical as the text.

McFarland's Pathology

A Text-Book of Pathology. By JOSEPH MCFARLAND, M. D., Professor of Pathology and Bacteriology in the Medico-Chirurgical College of Philadelphia. Octavo of 856 pages, with 437 illustrations, many in colors. Cloth, $5.00 net; Half Morocco, $6.50 net.

THE NEW (2d) EDITION

You cannot successfully treat disease unless you have a practical, *clinical* knowledge of the pathologic changes produced by disease. For this purpose Dr. McFarland's work is well fitted. It was written with just such an end in view—to furnish a ready means of acquiring a thorough training in the subject, a training such as would be of daily help in your practice. For this edition every page has been gone over most carefully, correcting, omitting the obsolete, and adding the new. Some sections have been entirely rewritten. You will find it a book well worth consulting, for it is the work of an authority.

St. Paul Medical Journal

"It is safe to say that there are few who are better qualified to give a résumé of the modern views on this subject than McFarland. The subject-matter is thoroughly up to date."

Boston Medical and Surgical Journal

"It contains a great mass of well-classified facts. One of the best sections is that on the special pathology of the blood."

McFarland's
Biology: Medical and General

Biology: Medical and General.—By JOSEPH MCFARLAND, M. D., Professor of Pathology and Bacteriology in the Medico-Chirurgical College of Phila. 12mo, 457 pages, 160 illustrations. Cloth, $1.75 net.

NEW (2d) EDITION

This work is both a *general* and *medical* biology. The former because it discusses the peculiar nature and reactions of living substance generally; the latter because particular emphasis is laid on those subjects of special interest and value in the study and practice of medicine. The illustrations will be found of great assistance.

Frederic P. Gorham, A. M., *Brown University.*

"I am greatly pleased with it. Perhaps the highest praise which I can give the book is to say that it more nearly approaches the course I am now giving in general biology than any other work."

McFarland's Pathogenic Bacteria and Protozoa

Pathogenic Bacteria and Protozoa. By JOSEPH MCFARLAND, M. D., Professor of Pathology and Bacteriology in the Medico-Chirurgical College of Philadelphia. Octavo of 878 pages, finely illustrated. Cloth, $3.50 net.

NEW (7th) EDITION, ENLARGED

Dr. McFarland has subjected his book to a most vigorous revision, bringing this edition right down to the minute. Important new additions have increased it in size some 180 pages, By far the most important addition is the inclusion of an entirely new section on *Pathogenic Protozoa.* This section considers every protozoan pathogenic to man; and in that same clean-cut, definite way that won for McFarland's work a place in the very front of medical bacteriologies. The illustrations are the best the world affords, and are beautifully executed.

H. B. Anderson, M. D.,
Professor of Pathology and Bacteriology, Trinity Medical College, Toronto.
"The book is a satisfactory one, and I shall take pleasure in recommending it to the students of Trinity College."

The Lancet, London
"It is excellently adapted for the medical students and practitioners for whom it is avowedly written. . . . The descriptions given are accurate and readable."

Hill's Histology and Organography

A Manual of Histology and Organography. By CHARLES HILL, M. D., formerly Assistant Professor of Histology and Embryology, Northwestern University, Chicago. 12mo of 483 pages, 337 illustrations. Cloth, $2.25 net.

JUST ISSUED—THE NEW (3d) EDITION

Dr. Hill's work is characterized by a completeness of discussion rarely met in a book of this size. Particular consideration is given the mouth and teeth.

Pennsylvania Medical Journal
"It is arranged in such a manner as to be easy of access and comprehension. To any contemplating the study of histology and organography we would commend this work."

GET THE BEST

American

THE NEW STANDARD

Illustrated Dictionary

New (7th) Edition—5000 Sold in Two Months

The American Illustrated Medical Dictionary. A new and complete dictionary of the terms used in Medicine, Surgery, Dentistry, Pharmacy, Chemistry, Veterinary Science, Nursing, and kindred branches; with over 100 new and elaborate tables and many handsome illustrations. By W. A. NEWMAN DORLAND, M.D., Editor of "The American Pocket Medical Dictionary." Large octavo, 1107 pages, bound in full flexible leather. Price, $4.50 net; with thumb index, $5.00 net.

IT DEFINES ALL THE NEW WORDS—IT IS UP TO DATE

The American Illustrated Medical Dictionary defines hundreds of the newest terms not defined in any other dictionary—bar none. These new terms are live, active words, taken right from modern medical literature.

It gives the capitalization and pronunciation of all words. It makes a feature of the derivation or etymology of the words. In some dictionaries the etymology occupies only a secondary place, in many cases no derivation being given at all. In the American Illustrated practically every word is given its derivation.

Every word has a separate paragraph, thus making it easy to find a word quickly.

The tables of arteries, muscles, nerves, veins, etc., are of the greatest help in assembling anatomic facts. In them are classified for quick study all the necessary information about the various structures.

Every word is given its definition—a definition that *defines* in the fewest possible words. In some dictionaries hundreds of words are not defined at all, referring the reader to some other source for the information he wants at once.

Howard A. Kelly, M. D., *Johns Hopkins University, Baltimore.*

"The American Illustrated Dictionary is admirable. It is so well gotten up and of such convenient size. No errors have been found in my use of it."

J. Collins Warren, M. D., LL.D., F.R.C.S. (Hon.), *Harvard Medical School*

"I regard it as a valuable aid to my medical literary work. It is very complete and of convenient size to handle comfortably. I use it in preference to any other."

Stengel's Pathology

A Text-Book of Pathology. By ALFRED STENGEL, M. D., Professor of Medicine in the University of Pennsylvania. Octavo volume of 979 pages, with 400 text-illustrations, many in colors, and 7 full-page colored plates. Cloth, $5.00 net; Sheep or Half Morocco, $6.50 net.

FIFTH EDITION, WITH 400 ILLUSTRATIONS

In this work the practical application of pathologic facts to clinical medicine is considered more fully than is customary in works on pathology. While the subject is treated in the broadest way consistent with the size of the book, an effort has been made to present the subject from the point of view of the clinician.

"This volume is intended to present the subject of pathology in as practical a form as possible, and more especially from the point of view of the 'clinical pathologist.' These objects have been faithfully carried out, and a valuable text-book is the result. We can most favorably recommend it to our readers as a thoroughly practical work on clinical pathology."—*The Lancet, London.*

Stiles on the Nervous System

The Nervous System and its Conservation. By PERCY G. STILES, Instructor in Physiology at Harvard University. 12mo of 230 pages, illustrated. Cloth, $1.25 net.

JUST ISSUED

You get chapters on the minute structure, elements of nerve physiology, reflexes, anatomy, afferent nervous system, neuromuscular system and fatigue, autonomic system, the cerebrum and human development, emotion, sleep, dreams, causes of nervous impairment, neurasthenia, hygiene.

Stiles' Nutritional Physiology

Nutritional Physiology. By PERCY GOLDTHWAIT STILES, Instructor in Physiology at Harvard University. 12mo of 295 pages, illustrated. Cloth, $1.25 net.

ILLUSTRATED

This new work expresses the most advanced views on this important subject. It discusses in a concise way the processes of digestion and metabolism. The key-word of the book throughout is "energy"—its source and its conservation.

"It is remarkable for the fineness of its diction and for its clear presentation of the subject, relieved here and there by a quaintly humorous turn of phrase that is altogether delightful."—*Colin C. Stewart, Ph. D., Dartmouth College.*

Jordan's General Bacteriology

A Text-Book of General Bacteriology. By EDWIN O. JORDAN, PH.D., Professor of Bacteriology in the University of Chicago and in Rush Medical College. Octavo of 650 pages, illustrated. Cloth, $3.00 net.

NEW (4th) EDITION

Professor Jordan's work embraces the entire field of bacteriology, the non-pathogenic as well as the pathogenic bacteria being considered, giving greater emphasis, of course, to the latter. There are extensive chapters on methods of studying bacteria, including staining, biochemical tests, cultures, etc.; on the development and composition of bacteria; on enzymes and fermentation-products; on the bacterial production of pigment, acid and alkali; and on ptomains and toxins. Especially complete is the presentation of the serum treatment of gonorrhea, diphtheria, dysentery, and tetanus. The relation of bovine to human tuberculosis and the ocular tuberculin reaction receive extensive consideration.

This work will also appeal to academic and scientific students. It contains chapters on the bacteriology of plants, milk and milk-products, air, agriculture, water, food preservatives, the processes of leather tanning, tobacco curing, and vinegar making; the relation of bacteriology to household administration and to sanitary engineering, etc.

Prof. Severance Burrage, *Associate Professor of Sanitary Science, Purdue University.*

"I am much impressed with the completeness and accuracy of the book. It certainly covers the ground more completely than any other American book that I have seen."

Buchanan's Veterinary Bacteriology

Veterinary Bacteriology. By ROBERT E. BUCHANAN, Ph.D., Professor of Bacteriology in the Iowa State College of Agriculture and Mechanic Arts. Octavo, 516 pages, 214 illustrations. Cloth, $3.00 net.

THE BEST PUBLISHED

Professor Buchanan discusses thoroughly all bacteria causing diseases of the domestic animals. He goes minutely into the consideration of immunity, opsonic index, reproduction, sterilization, antiseptics, biochemic tests, culture-media, isolation of cultures, the manufacture of the various toxins, antitoxins, tuberculins, and vaccines that have proved of diagnostic or therapeutic value. Then, in addition to bacteria and protozoa proper, he considers molds, mildews, smuts, rusts, toadstools, puff-balls, and the other fungi pathogenic for animals.

B. F. Kaupp, D. V. S., *State Agricultural College, Fort Collins.*

"It is the best in print on the subject. What pleases me most is that it contains all the late results of research. It fills a long felt want."

Heisler's Embryology

A Text-Book of Embryology. By JOHN C. HEISLER, M. D., Professor of Anatomy in the Medico-Chirurgical College, Philadelphia. Octavo volume of 435 pages, with 212 illustrations, 32 of them in colors. Cloth, $3.00 net.

THIRD EDITION—WITH 212 ILLUSTRATIONS, 32 IN COLORS

This edition represents all the advances recently made in the science of embryology. Many portions have been entirely rewritten, and a great deal of new and important matter added. A number of new illustrations have also been introduced and these will prove very valuable. Heisler's Embryology has become a standard work.

G. Carl Huber, M. D.,

Professor of Embryology at the Wistar Institute, University of Pennsylania.

"I find this edition of 'A Text-Book of Embryology,' by Dr. Heisler, an improvement on the former one. The figures added increase greatly the value of the work. I am again recommending it to our students."

Böhm, Davidoff, and Huber's Histology

A Text-Book of Human Histology. Including Microscopic Technic. By DR. A. A. BÖHM and Dr. M. VON DAVIDOFF, of Munich, and G. CARL HUBER, M. D., Professor of Embryology at the Wistar Institute, University of Pennsylvania. Handsome octavo of 528 pages, with 361 beautiful original illustrations. Flexible cloth, $3.50 net.

SECOND EDITION, ENLARGED

The work of Drs. Böhm and Davidoff is well known in the German edition, and has been considered one of the most practically useful books on the subject of Human Histology. This second edition has been in great part rewritten and very much enlarged by Dr. Huber, who has also added over one hundred original illustrations. Dr. Huber's extensive additions have rendered the work the most complete students' text-book on Histology in existence.

Boston Medical and Surgical Journal

"Is unquestionably a text-book of the first rank, having been carefully written by thorough masters of the subject, and in certain directions it is much superior to any other histological manual."

Wells' Chemical Pathology

Chemical Pathology.—Being a Discussion of General Pathology from the Standpoint of the Chemical Processes Involved. By H. GIDEON WELLS, PH. D., M. D., Assistant Professor of Pathology in the University of Chicago. Octavo of 616 pages. Cloth, $3.25 net.

NEW (2d) EDITION

Dr. Wells' work is written for the physician, for those engaged in research in pathology and physiologic chemistry, and for the medical student. In the introductory chapter are discussed the chemistry and physics of the animal cell, giving the essential facts of ionization, diffusion, osmotic pressure, etc., and the relation of these facts to cellular activities. Special chapters are devoted to *Diabetes* and to *Uric-acid Metabolism and Gout.*

Wm. H. Welch, M. D.

Professor of Pathology, Johns Hopkins University.

"The work fills a real need in the English literature of a very important subject, and I shall be glad to recommend it to my students."

Lusk's Elements of Nutrition

Elements of the Science of Nutrition. By GRAHAM LUSK, PH. D., Professor of Physiology at Cornell Medical School. Octavo volume of 302 pages. Cloth, $3.00 net.

THE NEW (2d) EDITION—TRANSLATED INTO GERMAN

Prof. Lusk presents the scientific foundations upon which rests our knowledge of nutrition and metabolism, both in health and in disease. There are special chapters on the metabolism of diabetes and fever, and on purin metabolism. The work will also prove valuable to students of *animal dietetics* at agricultural stations.

Lewellys F. Barker, M. D.

Professor of the Principles and Practice of Medicine, Johns Hopkins University.

"I shall recommend it highly to my students. It is a comfort to have such a discussion of the subject in English."

Daugherty's Economic Zoölogy

Economic Zoölogy. By L. S. DAUGHERTY, M. S., Ph. D., Professor of Zoölogy, State Normal School, Kirksville, Mo., and M. C. DAUGHERTY, author with Jackson of "Agriculture Through the Laboratory and School Garden." Part I: *Field and Laboratory Guide.* 12mo of 237 pages, interleaved. Cloth, $1.25 net. Part II: *Principles.* 12mo of 406 pages, illustrated. Cloth, $2.00 net.

ILLUSTRATED

There is no other book just like this. Not only does it give the salient facts of structural zoölogy and the development of the various branches of animals, but also the natural history—the *life and habits*—thus showing the interrelations of structure, habit, and environment. In a word, it gives the principles of zoölogy and *their actual application.* The economic phase is emphasized.
Part I—the *Field and Laboratory Guide*—is designed for practical instruction in the field and laboratory. To enhance its value for this purpose blank pages are inserted for notes.

Drew's Invertebrate Zoölogy

A Laboratory Manual of Invertebrate Zoology. By GILMAN A. DREW, PH. D., Assistant Director at Marine Biological Laboratory, Woods Hole, Mass. With the aid of Former and Present Members of the Zoölogical Staff of Instructors. 12mo of 213 pages. Cloth, $1.25 net.

NEW (2d) EDITION

The subject is presented in a logical way, and the type method of study has been followed, as this method has been the prevailing one for many years.

Prof. Allison A. Smyth, Jr., Virginia Polytechnic Institute
"I think it is the best laboratory manual of zoölogy I have yet seen. The large number of forms dealt with makes the work applicable to almost any locality."

Norris' Cardiac Pathology

Studies in Cardiac Pathology. By GEORGE W. NORRIS, M.D., Associate in Medicine at the University of Pennsylvania. Large octavo of 235 pages, with 85 superb illustrations. Cloth, $5.00 net.

SUPERB ILLUSTRATIONS

The illustrations are superb. Each illustration is accompanied by a detailed description; besides, there is ample letter press supplementing the pictures.

Boston Medical and Surgical Journal

"The illustrations are arranged in such a way as to illustrate all the common and many of the rare cardiac lesions, and the accompanying descriptive text constitutes a fairly continuous didactic treatise."

McConnell's Pathology

A Manual of Pathology. By GUTHRIE MCCONNELL, M. D., Assistant Surgeon, Medical Reserve Corps, U. S. Navy. 12mo of 523 pages, with 170 illustrations. Flexible leather, $2.50 net.

NEW (2d) EDITION

Dr. McConnell has discussed his subject with a clearness and precision of style that make the work of great assistance to both student and practitioner. The illustrations have been introduced for their practical value.

New York State Journal of Medicine

"The book treats the subject of pathology with a thoroughness lacking in many works of greater pretension. The illustrations—many of them original—are profuse and of exceptional excellence."

McConnell's Pathology and Bacteriology

For Dental Students

Pathology and Bacteriology for Dental Students. By GUTHRIE MCCONNELL, M. D., Assistant Surgeon, Medical Reserve Corps, U. S. N. 12mo of 309 pages, illustrated. Cloth, $2.25 net.

JUST ISSUED

This work is written expressly for dentists and dental students, emphasizing throughout the application of pathology and bacteriology in dental study and practice. There are chapters on disorders of metabolism and circulation; retrogressive processes, cell division inflammation and regeneration, granulomas, progressive processes, tumors, special mouth pathology, sterilization and disinfection, bacteriologic methods, specific micro-organisms, infection and immunity, and laboratory technic.

Dürck and Hektoen's Special Pathologic Histology

Atlas and Epitome of Special Pathologic Histology. By DR. H. DÜRCK, of Munich. Edited, with additions, by LUDVIG HEKTOEN, M. D., Professor of Pathology, Rush Medical College, Chicago. In two parts. Part I.—Circulatory, Respiratory, and Gastro-intestinal Tracts. 120 colored figures on 62 plates, and 158 pages of text. Part II.—Liver, Urinary and Sexual Organs, Nervous System, Skin, Muscles, and Bones. 123 colored figures on 60 plates, and 192 pages of text. Per part: Cloth, $3.00 net. *In Saunders' Hand-Atlas Series.*

The great value of these plates is that they represent in the exact colors the effect of the stains, which is of such great importance for the differentiation of tissue. The text portion of the book is admirable, and, while brief, it is entirely satisfactory in that the leading facts are stated, and so stated that the reader feels he has grasped the subject extensively.

William H. Welch, M. D.,

Professor of Pathology, Johns Hopkins University, Baltimore.

"I consider Dürck's 'Atlas of Special Pathologic Histology,' edited by Hektoen, a very useful book for students and others. The plates are admirable."

Sobotta and Huber's Human Histology

Atlas and Epitome of Human Histology. By PRIVATDOCENT DR. J. SOBOTTA, of Würzburg. Edited, with additions, by G. CARL HUBER, M. D., Professor of Histology and Embryology in the University of Michigan, Ann Arbor. With 214 colored figures on 80 plates, 68 text-illustrations, and 248 pages of text. Cloth, $4.50 net. *In Saunders' Hand-Atlas Series.*

INCLUDING MICROSCOPIC ANATOMY

The work combines an abundance of well-chosen and most accurate illustrations, with a concise text, and in such a manner as to make it both atlas and text-book. The great majority of the illustrations were made from sections prepared from human tissues, and always from fresh and in every respect normal specimens. The colored lithographic plates have been produced with the aid of over thirty colors.

Boston Medical and Surgical Journal

"In color and proportion they are characterized by gratifying accuracy and lithographic beauty."

Bosanquet on Spirochaetes

Spirochætes: A Review of Recent Work, with Some Original Observations. By W. CECIL BOSANQUET, M.D., Fellow of the Royal College of Physicians, London. Octavo of 152 pages, illustrated. $2.50 net.

ILLUSTRATED

This is a complete and authoritative monograph on the spirochætes, giving morphology, pathogenesis, classification, staining, etc. Pseudospirochætes are also considered, and the entire text well illustrated. The high standing of Dr. Bosanquet in this field of study makes this new work particularly valuable.

Levy and Klemperer's Clinical Bacteriology

The Elements of Clinical Bacteriology. By DRS. ERNST LEVY and FELIX KLEMPERER, of the University of Strasburg. Translated and edited by AUGUSTUS A. ESHNER, M. D., Professor of Clinical Medicine, Philadelphia Polyclinic. Octavo volume of 440 pages, fully illustrated. Cloth, $2.50 net.

S. Solis-Cohen, M. D.,
Professor of Clinical Medicine, Jefferson Medical College, Philadelphia.
"I consider it an excellent book. I have recommended it in speaking to my students."

Lehmann, Neumann, and Weaver's Bacteriology

Atlas and Epitome of Bacteriology: INCLUDING A TEXT-BOOK OF SPECIAL BACTERIOLOGIC DIAGNOSIS. By PROF. DR. K. B. LEHMANN and DR. R. O. NEUMANN, of Würzburg. *From the Second Revised and Enlarged German Edition.* Edited, with additions, by G. H. WEAVER, M. D., Assistant Professor of Pathology and Bacteriology, Rush Medical College, Chicago. In two parts. Part I.—632 colored figures on 69 lithographic plates. Part II.—511 pages of text, illustrated. Per part: Cloth, $2.50 net. *In Saunders' Hand-Atlas Series.*

Durck and Hektoen's General Pathologic Histology

ATLAS AND EPITOME OF GENERAL PATHOLOGIC HISTOLOGY. By PR. DR. H. DURCK, of Munich. Edited, with additions, by LUDVIG HEKTOEN, M. D., Professor of Pathology in Rush Medical College, Chicago. 172 colored figures on 77 lithographic plates, 36 text-cuts, many in colors, and 353 pages. Cloth, $5.00 net. *In Saunders' Hand-Atlas Series.*

American Text-Book of Physiology **Second Edition**

AMERICAN TEXT-BOOK OF PHYSIOLOGY. In two volumes. Edited by WILLIAM H. HOWELL, PH. D., M.D., Professor of Physiology in the Johns Hopkins University, Baltimore, Md. Two royal octavos of about 600 pages each, illustrated. Per volume: Cloth, $3.00 net; Half Morocco, $4.25 net.

"The work will stand as a work of reference on physiology. To him who desires to know the status of modern physiology, who expects to obtain suggestions as to further physiologic inquiry, we know of none in English which so eminently meets such a demand."—*The Medical News.*

Warren's Pathology and Therapeutics **Second Edition**

SURGICAL PATHOLOGY AND THERAPEUTICS. By JOHN COLLINS WARREN, M. D., LL.D., F. R. C. S. (Hon.), Professor of Surgery, Harvard Medical School. Octavo, 873 pages, 136 relief and lithographic illustrations, 33 in colors. With an Appendix on Scientific Aids to Surgical Diagnosis and a series of articles on Regional Bacteriology. Cloth, $5.00 net; Half Morocco, $6.50 net.

Gorham's Bacteriology

A LABORATORY COURSE IN BACTERIOLOGY. For the Use of Medical, Agricultural, and Industrial Students. By FREDERIC P. GORHAM, A. M., Associate Professor of Biology in Brown University, Providence, R. I., etc. 12mo of 192 pages, with 97 illustrations. Cloth, $1.25 net.

"One of the best students' laboratory guides to the study of bacteriology on the market. . . . The technic is thoroughly modern and amply sufficient for all practical purposes."—*American Journal of the Medical Sciences.*

Raymond's Physiology **New (3d) Edition**

HUMAN PHYSIOLOGY. By JOSEPH H. RAYMOND, A. M., M. D., Professor of Physiology and Hygiene, Long Island College Hospital, New York. Octavo of 685 pages, with 444 illustrations. Cloth, $3.50 net.

"The book is well gotten up and well printed, and may be regarded as a trustworthy guide for the student and a useful work of reference for the general practitioner. The illustrations are numerous and are well executed."—*The Lancet*, London.

Ball's Bacteriology

Seventh Edition, Revised

ESSENTIALS OF BACTERIOLOGY: being a concise and systematic introduction to the Study of Micro-organisms. By M. V. BALL, M. D., Late Bacteriologist to St. Agnes' Hospital, Philadelphia. 12mo of 289 pages, with 135 illustrations, some in colors. Cloth, $1.00 net. *In Saunders' Question-Compend Series.*

"The technic with regard to media, staining, mounting, and the like is culled from the latest authoritative works."—*The Medical Times*, New York.

Budgett's Physiology

New (3d) Edition

ESSENTIALS OF PHYSIOLOGY. Prepared especially for Students of Medicine, and arranged with questions following each chapter. By SIDNEY P. BUDGETT, M. D., formerly Professor of Physiology, Washington University, St. Louis. Revised by HAVAN EMERSON, M. D., Demonstrator of Physiology, Columbia University. 12mo volume of 250 pages, illustrated. Cloth, $1.00 net. *Saunders' Question-Compend Series.*

"He has an excellent conception of his subject. . . It is one of the most satisfactory books of this class"—*University of Pennsylvania Medical Bulletin.*

Leroy's Histology

New (4th) Edition

ESSENTIALS OF HISTOLOGY. By LOUIS LEROY, M. D., Professor of Histology and Pathology, Vanderbilt University, Nashville, Tennessee. 12mo, 263 pages, with 92 original illustrations. Cloth, $1.00 net. *In Saunders' Question-Compend Series.*

"The work in its present form stands as a model of what a student's aid should be; and we unhesitatingly say that the practitioner as well would find a glance through the book of lasting benefit."—*The Medical World*, Philadelphia.

Barton and Wells' Medical Thesaurus

A THESAURUS OF MEDICAL WORDS AND PHRASES. By WILFRED M. BARTON, M. D., Assistant Professor of Materia Medica and Therapeutics, and WALTER A. WELLS, M.D., Demonstrator of Laryngology, Georgetown University, Washington, D. C. 12mo, 534 pages. Flexible leather, $2.50 net; thumb indexed, $3.00 net.

American Pocket Dictionary

New (8th) Edition

DORLAND'S POCKET MEDICAL DICTIONARY. Edited by W. A. NEWMAN DORLAND, M. D., Editor "American Illustrated Medical Dictionary." Containing the pronunciation and definition of the principal words used in medicine and kindred sciences, with 64 extensive tables. 677 pages. Flexible leather, with gold edges, $1.00 net; with patent thumb index, $1.25 net.

"I can recommend it to our students without reserve."—J. H. HOLLAND, M. D., *of the Jefferson Medical College*, Philadelphia.